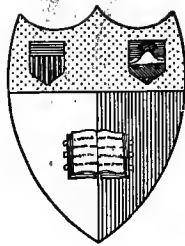


Q128  
Q11  
L1

# QUAIN'S ANATOMY

E. A. SCHÄFER & G. D. THANE



**Cornell University Library**

**Ithaca, New York**

THE  
**CHARLES EDWARD VANCLEEF**  
**MEMORIAL LIBRARY**

BOUGHT WITH THE INCOME OF A FUND GIVEN FOR  
THE USE OF THE ITHACA DIVISION OF  
THE CORNELL UNIVERSITY MEDICAL  
COLLEGE


BY  
**MYNDERSE VANCLEEF**

CLASS OF 1874  
1921

CORNELL UNIVERSITY LIBRARY



3 1924 051 798 001



# Cornell University Library

The original of this book is in  
the Cornell University Library.

There are no known copyright restrictions in  
the United States on the use of the text.



LIBRARY  
OF  
A. T. KERR, JR.  
NO 46.....

QUAIN'S  
=

# ELEMENTS OF ANATOMY

EDITED BY

EDWARD ALBERT SCHÄFER, F.R.S.

PROFESSOR OF PHYSIOLOGY AND HISTOLOGY IN UNIVERSITY COLLEGE, LONDON,

AND

GEORGE DANCER THANE,

PROFESSOR OF ANATOMY IN UNIVERSITY COLLEGE, LONDON.

IN THREE VOLUMES.

VOL. II.—PART II.

ARTHROLOGY—MYOLOGY—ANGEIOLOGY

BY PROFESSOR THANE.

ILLUSTRATED BY 255 ENGRAVINGS,

*Many of which are Coloured.*

REPRINTED FROM THE

**Tenth Edition.**

LONDON:  
LONGMANS, GREEN, AND CO.  
AND NEW YORK: 15 EAST 16<sup>th</sup> STREET.

1894.

GM  
23  
Q21  
1890  
v. 2 pt. 2

Med. 4253

Abram

T. Kenyon

Aug 7, 1897

LONDON:  
BRADDURY, AONEW, & CO. LD., PRINTERS, WHITEFRIARS.



## NOTE CONCERNING THE NOMENCLATURE OF THE MUSCLES.

IN the year 1889 a Commission was nominated by the German Anatomical Society, at the instigation of Professor His of Leipzig, to consider the question of Anatomical Nomenclature, and to prepare a series of names which, it was hoped, would be universally adopted. The Commission has recently issued a report dealing with Myological Nomenclature, but the printing of this Volume was at that time too far advanced to allow of the adoption of the names therein proposed. The chief differences between the names recommended by the Commission and those used, or given as synonyms, in this work are shown in the appended table.

<i>Name used in this Work.</i>	<i>Proposed Name.</i>
Serratus magnus.	Serratus anticus.
Brachialis anticus.	Brachialis internus.
Semilunar fascia of biceps.	Iacertus fibrosus.
Anterior annular ligament of wrist.	Ligamentum carpi volare.
Posterior annular ligament.	Ligamentum carpi dorsale.
Quadriceps extensor eruris.	Quadriceps femoris.
Vastus externus.	Vastus lateralis.
Crureus.	Femoralis.
Vastus internus.	Vastus medialis.
Subcrureus.	Articularis genu.
	Adductor hallucis.
	Caput obliquum.
Adductor hallucis obliquus.	Caput transversum.
Adductor hallucis transversus.	Quadratus plantæ.
Flexor accessorius.	
Anterior annular ligament of ankle.	Ligamentum annulare.
Upper band.	Ligamentum cruciatum.
Lower band.	Ligamentum laciniatum.
Internal annular ligament.	Retinaculum peroneorum superius.
External annular ligament.	
(Fibrous band over peroneal tendons	Retinaculum peroneorum inferius.
on outer side of os calcis).	Epicranius.
Occipito-frontalis.	Galea aponeurotica.
Epicranial aponeurosis.	Orbicularis oculi.
Orbicularis palpebrarum.	Pars palpebralis.
Palpebral portion.	Pars orbitalis.
Orbital portion.	Pars lacrymalis.
Tensor tarsi.	
Compressor naris.	Nasalis.
Depressor alæ nasi (outer part). }	Depressor septi.
Depressor alæ nasi (inner part). }	Quadratus labii superioris.
	Caput angulare.
Levator labii superioris alæque nasi.	Caput infraorbitale.
Levator labii superioris proprius.	Caput zygomaticum.
Zygomaticus minor.	
Levator labii inferioris.	Mentalis.
Rectus capitis anticus major.	Longus capitis.
Rectus capitis anticus minor	Rectus capitis anticus
Erector spinæ.	Sacro-spinalis.

## NOMENCLATURE OF MUSCLES.

<i>Name used in this Work.</i>	<i>Proposed Name.</i>
Ilio-costalis.	Ilio-costalis lumborum.
Accessorius ad ilio-costalem.	Ilio-costalis dorsi.
Cervicalis ascendens.	Ilio-costalis cervicis.
Longissimus dorsi.	Longissimus dorsi.
Transversalis cervicis.	Longissimus cervicis.
Trachelo-mastoid.	Longissimus capitis.
External abdominal ring.	Annulus inguinalis cutaneus.
Upper pillar.	Crus superius.
Lower pillar.	Crus inferius.
Semilunar fold of Douglas,	Linea Douglasii.
(Outer border of aponeurosis of trans-	
versalis muscle).	Linea Spigelii.
Internal abdominal ring.	Annulus inguinalis abdominalis.

# CONTENTS OF PART II.

	PAGE	PAGE
<b>ARTHEROLOGY.</b>		
<b>THE ARTICULATIONS IN GENERAL</b> . . . . .	147	
Various Forms of Joints . . . . .	147	
Various Kinds of Movement . . . . .	151	
<b>ARTICULATIONS OF THE TRUNK AND HEAD</b> . . . . .	151	
Articulations of the Vertebral Column . . . . .	151	
Articulations of the Atlas, Axis, and Occipital Bone . . . . .	155	
Articulations of the Thorax . . . . .	158	
Temporo-Maxillary Articulation . . . . .	162	
<b>ARTICULATIONS OF THE UPPER LIMB</b> . . . . .	164	
The Scapulo-Clavicular Arch . . . . .	164	
Sterno-Clavicular Articulation . . . . .	164	
Scapulo-Clavicular Articulation . . . . .	164	
Ligaments of the Scapula . . . . .	166	
The Shoulder-Joint . . . . .	166	
Articulations of the Bones of the Forearm . . . . .	169	
The Elbow-Joint . . . . .	170	
The Wrist-Joint and Articulations of the Carpus . . . . .	172	
Radio-Carpal Articulation . . . . .	172	
Carpal Articulations . . . . .	173	
Carpometacarpal and Intermetacarpal Articulations . . . . .	175	
Metacarpophalangeal and Interphalangeal Articulations . . . . .	176	
<b>ARTICULATIONS OF THE PELVIS</b> . . . . .	177	
Articulation of the Pelvis with the last Lumbar Vertebra . . . . .	177	
Articulations of the Sacrum and Coccyx, and of the Pieces of the Coccyx . . . . .	178	
Sacro-Iliac Articulation . . . . .	178	
Sacro-Sciatic Ligaments . . . . .	179	
Pubic Articulation . . . . .	180	
<b>ARTICULATIONS OF THE LOWER LIMB</b> . . . . .	181	
The Hip-Joint . . . . .	181	
The Knee-Joint . . . . .	183	
Tibio-Fibular Articulations . . . . .	189	
The Ankle-Joint . . . . .	190	
Articulations of the Foot . . . . .	192	
Articulations of the Calcaneum, Astragalus, and Navicular Bone . . . . .	192	
Calcaneo-Cuboid Articulation . . . . .	193	
Articulations of the Navicular, Cuboid, and Cuneiform Bones . . . . .	194	
Articulation of the Tarsus with the Metatarsus . . . . .	195	
Intermetatarsal Articulations . . . . .	196	
Metatarsophalangeal and Interphalangeal Articulations . . . . .	197	
<b>MYOLOGY.</b>		
<b>THE MUSCLES IN GENERAL</b> . . . . .	199	
<b>FASCIÆ</b> . . . . .	202	
<b>MUSCLES AND FASCIÆ OF THE UPPER LIMB</b> . . . . .	203	
Between the Trunk and Upper Limb posteriorly . . . . .	203	
Between the Trunk and Upper Limb anteriorly . . . . .	208	
Muscles and Fasciæ of the Shoulder . . . . .	214	
Muscles and Fasciæ of the Upper Arm . . . . .	218	
Muscles and Fasciæ of the Forearm . . . . .	222	
Pronator and Flexor Muscles . . . . .	223	
Supinator and Extensor Muscles . . . . .	229	
Muscles and Fasciæ of the Hand . . . . .	235	
Muscles of the Thumb . . . . .	236	
Muscles of the Little Finger . . . . .	237	
Interosseous Muscles . . . . .	238	
Actions of the Muscles of the Forearm and Hand . . . . .	240	
<b>MUSCLES AND FASCIÆ OF THE LOWER LIMB</b> . . . . .	241	
Fasciæ of the Hip and Thigh . . . . .	241	
Muscles of the Hip . . . . .	243	
Posterior Femoral or Hamstring Muscles . . . . .	250	
Anterior Muscles of the Thigh . . . . .	251	
Internal Femoral or Adductor Muscles . . . . .	255	
Muscles and Fasciæ of the Leg . . . . .	257	
Anterior Region . . . . .	259	
External Region . . . . .	260	
Posterior Region . . . . .	261	
Muscles and Fasciæ of the Foot . . . . .	268	
Dorsal Muscle . . . . .	269	
Plantar Muscles . . . . .	269	
First layer of Muscles . . . . .	269	
Second layer . . . . .	271	
Third layer . . . . .	271	
Fourth layer . . . . .	272	
Actions of the Muscles of the Leg and Foot . . . . .	273	
<b>MORPHOLOGY OF THE LIMB-MUSCLES</b> . . . . .	274	
Table of Muscular Homologies in the Upper and Lower Limbs . . . . .	277	
<b>MUSCLES AND FASCIÆ OF THE HEAD AND NECK</b> . . . . .	278	
Epicranial Region . . . . .	278	
Auricular Muscles . . . . .	280	
Muscles of the Eyelids and Eyebrows . . . . .	281	
Muscles of the Nose . . . . .	283	
Muscles of the Lips and Mouth . . . . .	285	
Muscles of the Orbit . . . . .	289	
Muscles of Mastication . . . . .	293	
Subcutaneous Muscle of the Neck . . . . .	295	
Muscles and Fasciæ of the Neck anteriorly . . . . .	296	
Infrahyoid Muscles . . . . .	299	
Suprahyoid Muscles . . . . .	301	
Muscles of the Tongue . . . . .	303	
Muscles of the Pharynx . . . . .	305	

	PAGE
Muscles of the Soft Palatæ . . . . .	307
Deep Lateral and Prevertebral Muscles of the Neck . . . . .	309
MUSCLES AND FASCIAE OF THE TRUNK . . . . .	311
Dorsal Muscles and Fasciæ . . . . .	311
Muscles of the Thorax . . . . .	319
The Diaphragm . . . . .	322
Movements of Respiration . . . . .	325
Muscles and Fasciæ of the Abdomen . . . . .	327
Lining Fascia of the Abdomen . . . . .	336
Muscles and Fasciæ of the Perineum and Pelvis . . . . .	337
Fasciæ of the Perineum . . . . .	337
Fasciæ of the Pelvis . . . . .	339
Muscles: A. in the Male . . . . .	341
B. in the Female . . . . .	346
MORPHOLOGY OF THE FASCIAE AND MUSCLES OF THE TRUNK AND HEAD . . . . .	347

### ANGIOLOGY.

THE HEART . . . . .	351
The Pericardium . . . . .	352
Form and Position of the Heart . . . . .	354
Cavities of the Heart . . . . .	356
Relation of its parts to the Thoracic Wall . . . . .	365
Intimate Structure of the Heart . . . . .	367
Myocardium . . . . .	368
Epicardium . . . . .	372
Endocardium . . . . .	373
Dimensions and Weight of the Heart . . . . .	374
Recent Literature of the Heart . . . . .	375
BLOOD-VESSELS; ARTERIES AND VEINS . . . . .	377
PULMONARY ARTERY AND VEINS . . . . .	378
SYSTEMIC ARTERIES . . . . .	380
AORTA . . . . .	380
Ascending Aorta . . . . .	381
Coronary Arteries . . . . .	382
Arch of the Aorta . . . . .	383
Varieties of the Aorta, &c. . . . .	384
BRANCHES OF THE ARCH OF THE AORTA . . . . .	388
Innominate Artery . . . . .	388
Common Carotid Arteries . . . . .	388
Surgical Anatomy of the Common Caro- tid Artery . . . . .	392
External Carotid Artery . . . . .	393
Branches . . . . .	394
Internal Carotid Artery . . . . .	407
Branches . . . . .	408
Distribution of the Cerebral Arteries . . . . .	413
Subclavian Arteries . . . . .	415
Branches . . . . .	419
Surgical Anatomy of the Subclavian Arteries . . . . .	429
Axillary Artery . . . . .	431
Branches . . . . .	432
Surgical Anatomy of the Axillary Artery . . . . .	435
Brachial Artery . . . . .	436
Branches . . . . .	437
Surgical Anatomy of the Brachial Artery . . . . .	441
Ulnar Artery . . . . .	442
Branches . . . . .	442
Superficial Palmar Arch . . . . .	446
Radial Artery . . . . .	447
Branches . . . . .	448
Deep Palmar Arch . . . . .	451
Surgical Anatomy of the Radial and Ulnar Arteries . . . . .	453

	PAGE
DESCENDING THORACIC AORTA . . . . .	454
Branches . . . . .	454
ABDOMINAL AORTA . . . . .	456
A.—Visceral Branches of the Abdominal Aorta . . . . .	458
B.—Parietal Branches of the Abdominal Aorta . . . . .	467
Minute Anastomoses of the Visceral and Parietal Branches of the Abdo- minal Aorta . . . . .	469
Common Iliac Arteries . . . . .	469
Surgical Anatomy of the Common Iliac Artery . . . . .	471
Internal Iliac Artery . . . . .	471
Hypogastric Artery . . . . .	473
Branches of the Internal Iliac Artery . . . . .	473
External Iliac Artery . . . . .	482
Branches . . . . .	483
Surgical Anatomy of the External Iliac Artery . . . . .	485
Femoral Artery . . . . .	485
Branches . . . . .	488
Surgical Anatomy of the Femoral Artery . . . . .	492
Popliteal Artery . . . . .	493
Branches . . . . .	494
Surgical Anatomy of the Popliteal Artery . . . . .	496
Posterior Tibial Artery . . . . .	496
Branches . . . . .	496
Plantar Arteries . . . . .	498
Anterior Tibial Artery . . . . .	500
Dorsal Artery of the Foot . . . . .	502
Surgical Anatomy of the Arteries of the Leg . . . . .	504
MORPHOLOGY OF THE ARTERIAL SYSTEM . . . . .	504
SYSTEMIC VEINS . . . . .	508
Veins of the Heart . . . . .	509
SUPERIOR VENA CAVA . . . . .	510
Innominate Veins . . . . .	510
Veins of the Head and Neck . . . . .	513
Venous Circulation within the Cranium . . . . .	519
Veins of the Brain . . . . .	519
Venous Sinuses of the Cranium . . . . .	521
Ophthalmic Veins . . . . .	524
Veins of the Diploe . . . . .	525
Emissary Veins . . . . .	526
Veins of the Upper Limb . . . . .	526
Superficial Veins . . . . .	527
Deep Veins . . . . .	529
Subclavian Vein . . . . .	530
Azygos Veins . . . . .	530
Veins of the Spine . . . . .	532
INFERIOR VENA CAVA . . . . .	534
Common Iliac Veins . . . . .	536
Veins of the Lower Limb and Pelvis . . . . .	536
Superficial Veins of the Lower Limb . . . . .	537
Deep Veins of the Lower Limb . . . . .	538
External Iliac Vein . . . . .	539
Veins of the Pelvis . . . . .	539
Internal Iliac Vein . . . . .	539
PORTAL SYSTEM OF VEINS . . . . .	541
MORPHOLOGY OF THE VENOUS SYSTEM . . . . .	544
ABSORBENT VESSELS . . . . .	546
Thoracic Duct . . . . .	547
Right Lymphatic Duct . . . . .	548
Lymphatics of the Lower Limb . . . . .	548
Lymphatics of the Pelvis and Abdomen . . . . .	550
Lymphatics of the Thorax . . . . .	554
Lymphatics of the Upper Limb . . . . .	556
Lymphatics of the Head and Neck . . . . .	558
INDEX AND GLOSSARY TO VOLUME II. . . . .	561

# ARTHROLOGY.

By G. D. THANE,

## THE ARTICULATIONS IN GENERAL.

**VARIOUS FORMS OF JOINTS.**—The name of articulation, synonymous with joint, is given in descriptive anatomy to the connection subsisting in the recent skeleton between any of its denser component parts, whether bones or cartilages. In all instances some softer substance intervenes between the bones, uniting them together, or clothing the surfaces which are opposed; but the manner in which the several pieces of the skeleton are thus connected varies to a great degree, both as to the nature of the uniting substances, and the extent of movement which they allow. In some instances, as in the cranial bones, the closeness of the apposition, the unevenness of the fitting surfaces or edges, and the small amount and dense nature of the intervening substance admit of no perceptible movement. In other instances of continuous union the extremities of the bones are placed at such a distance, and the intervening substance is so yielding, that bending or other movements may take place. But in the greater number of articulations the opposed surfaces of bone are not united with each other, but are free, and are covered with plates of smooth cartilage, the surfaces of which fit more or less accurately together, while the bones are held together by ligamentous structures placed in the vicinity of the joint. In such articulations the bones are capable of gliding or moving upon each other, the extent and directions of the movements varying with the shape of the opposed cartilaginous surfaces, and the form and attachments of the ligamentous and other bands which unite them. According to differences of the kind now adverted to the various articulations of the body are classified as follows:—

**A. SYNARTHROSIS OR CONTINUOUS ARTICULATION.**—The adjacent osseous surfaces are directly united by some interposed substance.

1. **Synchondrosis.**—A thin layer of cartilage is interposed between the bones, to which it adheres closely on each side. This articulation is essentially of a transitory nature; being usually converted into bony union (*synostosis*) before adult age is reached. It occurs between the different portions of bones developed in cartilage, as in the vertebræ, in the long bones of the limbs, and in the bones of the base of the skull.

2. **Suture.**—In this form of articulation, which is met with only in the skull, the bones are separated by a thin layer of fibrous tissue continuous with the periosteum. It also exhibits a tendency to pass over into synostosis, but in a variable degree at different places, and at a later period than the cartilaginous union (p. 62). The suture is *serrated* or *dentated* when the contiguous margins of the bones are subdivided or broken up into projecting points and recesses by which they fit very closely to one another, as in the borders of most of the tabular bones of the cranium. The *squamous* or *scaly suture* is that in which, as in the union of the temporal with the parietal

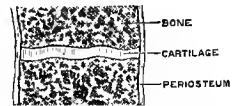


Fig. 169.—SCHEME OF A SYNCHONDROSIS. (G. D. T.)

bone, the edges are thinned and bevelled, so that one overlaps the other to a considerable extent. *Harmonic suture* or *harmonia* is the term employed to denote simple apposition of comparatively smooth surfaces or edges, as in the case of the vertical plate of the palate and the superior maxillary bones; and the term

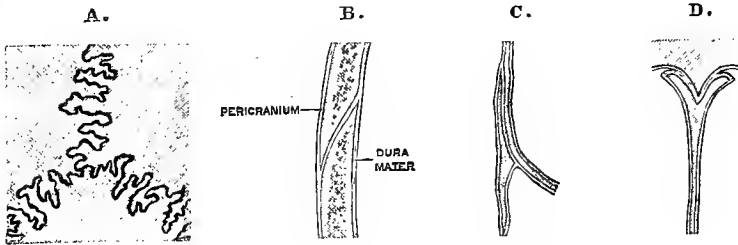


Fig. 170.—VARIOUS FORMS OF SUTURE. (G. D. T.)

A, dentated; B, squamous; C, harmonic; D, grooved. B, C, and D, in section.

*grooved suture* or *schindylesis* is applied to that kind of union in which one bone is received into a groove in another, as occurs with the rostrum of the sphenoid bone and the vomer.

3. **Symphysis.**—The bones are united by a plate or disc of fibro-cartilage of considerable thickness, and of a more or less complex structure, as in the articulations between the bodies of the vertebræ, and between the two pubic bones.<sup>1</sup>

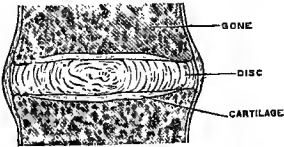


Fig. 171.—SCHEME OF A SYMPHYSIS. (G. D. T.)

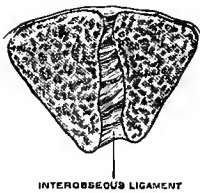


Fig. 172.—SCHEME OF A SYNDESOMOSIS. (G. D. T.)

4. **Syndesmosis.**—The bony surfaces are united by an interosseous ligament, as in the lower tibio-fibular articulation. Union by interosseous membrane is also a form of syndesmosis, in which, the bones being more widely separated, the intervening ligament is extended and assumes the membranous form. In the hand and foot the lateral connections of many of the carpal and tarsal, as well as of the metacarpal and metatarsal bones are partly syndesmosis, the synovial joints extending over only a small part of the adjacent surfaces.

Synchondroses and sutures are immoveable articulations, but in symphyses and syndesmoses, which may be classed together as partially moveable articulations, a certain amount of play is allowed, varying in extent and direction according to the thickness of the uniting substance and the nature of the other connections formed by the articulating bones.

B. **DIARTHROSIS OR DISCONTINUOUS ARTICULATION.**—This division includes the complete joints, with synovial cavities separating the articular surfaces of the bones, and is attended with considerable yet varying degrees of mobility. In this form of joint plates of cartilage cover the articular parts of the bones and present within the joint free surfaces of remarkable smoothness, and these surfaces are lubricated by the synovial fluid secreted from the delicate membrane which lines the fibrous

<sup>1</sup> This form of articulation is sometimes regarded as a third primary division, under the name of *amphiarthrosis*.

coverings and all other parts of the articular cavity except those formed by cartilage. This membrane is continuous with the margin of the articular cartilages, and along with them completely encloses the joint-cavity. The bones are united by fibrous tissue in the various forms of ligaments, such as membranous capsules, flat bands, or rounded cords. These ligaments, it is true, are not always so tight as to maintain the bones in close contact in all positions of the joint, but are rather tightened in some positions and relaxed in others, so that in many cases they are to be looked

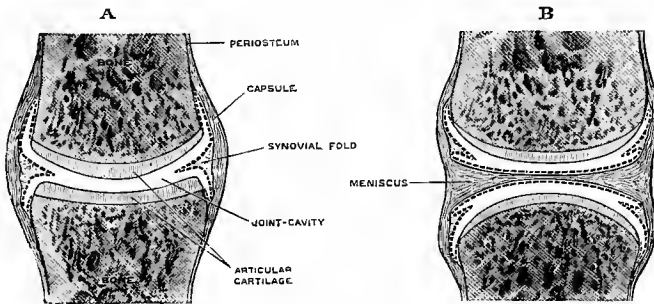


Fig. 173.—SCHEMES OF DIARTHRODIAL JOINTS; A, SIMPLE; B, COMPOUND. (G. D. T.)

The synovial membrane is represented by a dotted line. In the natural condition the opposed surfaces are in contact.

upon chiefly as controllers of movements. The bones are likewise held together in diarthrodial joints by atmospheric pressure, and by the surrounding muscles. The following forms of diarthrodial joint are distinguished:—

1. **Gliding joint** (Arthrodia).—The articular surfaces are nearly flat and admit of only a limited amount of gliding movement, as in most of the articulations of the carpus and tarsus, and in the joints between the articular processes of the vertebræ.

2. **Hinge-joint** (Ginglymus).—The movements are only those of flexion and extension, the articular surfaces being either approximately cylindrical, or more frequently the one pulley-shaped (trochlear) and the other correspondingly ridged. To this group belong the humero-ulnar articulation, the ankle-joint, and the interphalangeal articulations.

3. **Condyloid joint** (Condylarthrosis).—The articular surfaces are spheroidal and allow of all varieties of angular movement, together with circumduction, as in the metacarpo- and metatarso-phalangeal articulations.

4. **Saddle-joint**.—The movements allowed are similar to those in a condyloid joint, but the articular surfaces are reciprocally saddle-shaped, the convexity being directed from within out on the one bone and from before back on the other, as in the articulation of the first metacarpal bone with the trapezium.

5. **Ball and socket joint** (Enarthrosis).<sup>1</sup>—The articular surfaces are approximately spherical, and movement can take place freely in any direction, as in the shoulder and hip-joints.

6. **Pivot-joint** (Trochoides).—Rotation only is allowed, the articular surfaces being cylindrical, or portions of a cone, as in the atlanto-axial and radio-ulnar articulations.

The hinge and pivot-joints are uniaxial articulations, the movements taking place around an axis which is essentially transverse in the hinge-joint, although never precisely at right

<sup>1</sup> The name *arthrodia* is sometimes given to this form of articulation.

angles to the shafts of the two bones forming the articulation, and longitudinal in the pivot-joint. The condyloid and saddle-joints are biaxial, movement being permitted around two primary horizontal axes at right angles to one another, and necessarily also around any intermediate axis; while in the ball and socket joint a third vertical axis is added, so that movement may take place in any direction about a point in the centre of the spherical head in which the three orthogonal axes intersect each other.

There are, moreover, certain special cases of articulations which cannot strictly be included in any of the foregoing groups, for example, the humero-radial articulation and the knee-joint, in both of which movements proper to a hinge-joint and a pivot-joint are permitted.

In most diarthrodial joints the opposed articular surfaces correspond in shape and curvature, whence they are said to be *congruent*; in some cases, however, the cartilage-covered surfaces are *incongruent*, differing markedly in form. But even among the articulations with so-called congruent surfaces there are frequently slight differences of curvature, the convex surface for example being a curve of shorter radius than the concave surface, so that the opposed surfaces are never in contact over their whole extent. In such cases the area of contact is slightly increased under the influence of pressure owing to the yielding of the articular cartilage, and the small intervals left are occupied by synovial fluid and by folds of the synovial membrane which project from the periphery of the articulation. In the more marked degrees of incongruence larger folds containing fat fill the angular spaces left by the separation of the articular surfaces in different positions of the joint; and similar adipose folds or pads are often found within the capsule, corresponding to hollows formed by the bones in the neighbourhood of the articular surfaces. Lastly, incongruence of articular surfaces is also compensated in some instances by the interposition of an *interarticular plate* or *meniscus* of fibro-cartilage (*fibro-plate*—Cleland), which may be imperfect, having a crescentic or annular form, or may constitute a disc entirely separating the articular surfaces, thus giving rise to a compound joint, with two distinct synovial cavities (fig. 173, B).

**Development of articulations.**—Synarthrosis is the primary form of articulation, the adjacent skeletal elements at their first appearance being everywhere connected by indifferent embryonic tissue, and diarthrosis arises by the formation of a cleft in this intermediate substance. Synchondrosis results from the appearance and growth of distinct ossifications in a continuous cartilaginous mass, and suture in a similar way from the approximation of bones developed in a membranous blastema. Synostosis takes place when the ossification extends through the thin intervening layer of the original matrix. In symphysis and syndesmosis the connecting tissue undergoes conversion into the fibro-cartilaginous disc or interosseous ligament respectively. In the compound form of diarthrosis the interposed tissue becomes converted into the meniscus, on each side of which a cleft appears. Transitional forms of articulation between synarthrosis and diarthrosis also occur, an imperfect joint-cavity being frequently developed by absorption of the central portion of the disc, in the symphysis pubis for example, and according to Luschka regularly in the intervertebral discs. (For details as to the histological changes in the development of the joints, as well as of the microscopic structure of their constituent parts, reference must be made to the sections on Embryology and Histology in Vol. I.)

**Morphology of ligaments.**—The capsular ligaments investing diarthrodial articulations may be looked upon as representing a prolongation of the periosteum from one bone to another. The articular ligaments to which special names are given are for the most part portions of the capsule characterized by variations in thickness and the development of definite tracts of fibres. But in addition to these there are bands of different origin occurring either in the neighbourhood of joints, or uniting more distant portions of bone. Such bands may be derived from muscles, in the form of expansions from, or more or less separated portions of the tendons, or as parts of the muscular sheets which have undergone fibrous change in consequence of alteration or loss of function; or they may represent skeletal parts which, although indicated in the fœtus, do not attain full development, as seen in the stylohyoid ligament and the internal lateral ligament of the lower jaw; or they may be specialized portions of fascia, as the stylo-maxillary ligament, and the supraspinous and interspinous ligaments of the vertebræ. The annular ligaments of the wrist and ankle, as well as various



loops and retinacula binding down tendons, also belong to the last category.<sup>1</sup> (On this subject see J. B. Sutton, Journ. Anat., xviii—xxii, and "Ligaments, their Nature and Morphology," London, 1887.)

**VARIOUS KINDS OF MOVEMENT.**—The various movements of the bones in diarthrodial joints are distinguished by different terms, such as angular movement, circumduction, rotation, and gliding; but it is proper to remark that although different kinds of movement, answering to these several terms, may readily be recognised, yet in many cases several kinds of movement are combined in one joint, and they also run into one another in great variety.

**Angular movement** is movement in such a manner as to increase or diminish the angle between two bones, so that they shall lie more or less nearly in a straight line. The different kinds of angular movement are designated by different terms according to the directions in which they take place with reference to the limb or body: thus *flexion* and *extension* indicate angular movements about a transverse axis, which have the effect of bending or straightening parts upon one another or upon the trunk; *adduction* and *abduction* indicate angular movement to and from the median plane of the body, or, when fingers and toes are referred to, these terms are generally used to denote movement to and from the middle line of the hand or foot.

**Circumduction** is the movement performed when the shaft of a long bone or a part of a limb describes a cone, the apex of which is placed in or near the joint at one extremity of the bone, while the sides and base of the cone are described by the rest of the moving part.

**Rotation** signifies movement of a bone round a longitudinal axis without any great change of situation.

**Gliding** is applied to that kind of movement in which the surfaces of adjacent bones are displaced without any marked angular or rotatory motion, as in the movement of flat surfaces over each other in some of the carpal and tarsal articulations, or in the movement of advance and retreat of the lower jaw.

Although the term *gliding movement* is used in the restricted sense indicated above, yet it is to be observed that the movement between opposed articular surfaces is almost always purely of a gliding nature, and that only in one or two instances, such as in the movement of the patella on the femur, is the gliding associated with a limited degree of rolling movement, by which different parts of the two surfaces are brought successively into contact in the manner of a wheel rolling on the ground: to this form of movement the name of *coaptation* has been given.

## I.—THE ARTICULATIONS OF THE TRUNK AND HEAD.

### THE ARTICULATIONS OF THE VERTEBRAL COLUMN.

The moveable vertebræ are connected together by elastic discs interposed between the bodies, by synovial joints between the articular processes, and by ligaments.

The **intervertebral discs** are plates of composite structure placed between the bodies of the vertebræ from the axis to the sacrum. Each is composed of a fibro-laminar part externally, and of a pulpy substance in the centre.

The laminar part forms more than half of the mass. The laminæ are arranged concentrically, and consist mainly of parallel bundles of fibres running obliquely between the vertebræ and attached firmly to both, the direction of the fibres being reversed in successive layers: some fibres also run nearly horizontally. The outer-

<sup>1</sup> The name of *ligament* is also given in descriptive anatomy to various structures in no way connected with the joints or skeleton, such as folds of serous membranes and the remains of obliterated vessels.

Missing Page

Missing Page

dorsal region, largest and strongest in the loins, where a band of nearly horizontal fibres extends on each side from the fore part of the upper border of one spine to the hindmost part of the lower border of the spine above.

The **supraspinous ligament** consists of bundles of longitudinal fibres, which connect the summits of the spinous processes, and form a continuous cord from the seventh cervical vertebra to the sacrum. The superficial fibres pass down from a given vertebra to the third or fourth below it; those more deeply seated reach only from one to the next, or the second below it.

The **ligamentum nuchæ** replaces the supraspinous and interspinous ligaments in the neck. Its superficial part, which forms a continuation of the supraspinous

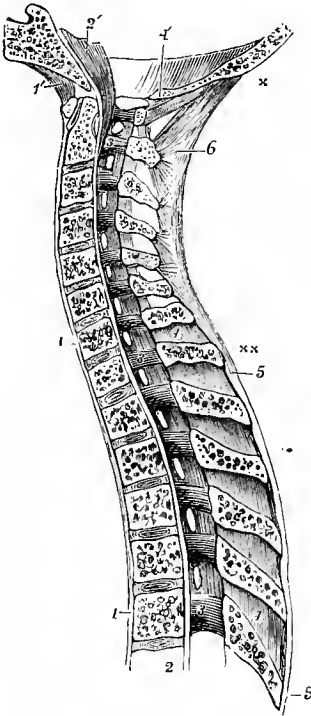


Fig. 178.—SAGITTAL SECTION OF THE UPPER PART OF THE VERTEBRAL COLUMN, AND PART OF THE OCCIPITAL BONE, SHOWING THE ARTICULATIONS. (Allen Thomson, after Arnold.)

1, 1, anterior common ligament; 1', anterior occipito-atlantal ligament; 2, from this figure upwards the posterior common ligament; 2', the continuation of the preceding or posterior occipito-axial ligament lying on the basilar process of the occipital bone; 3, 3, 3, these figures are placed on the inside of the arches of the 2nd cervical and 1st and 6th dorsal vertebrae; the ligamenta subflava are seen stretching between the laminae; 4, 4, placed upon two of the interspinous ligaments; 4', divided edge of the occipital bone behind the foramen magnum, and below it, the posterior occipito-atlantal ligament; 5, 5, supraspinous ligament; 6, ligamentum nuchæ; x, its upper extremity at the external occipital protuberance; x x, its lower extremity terminating in the supraspinous ligament.

ligament, is thick and extends from the spine of the seventh cervical vertebra to the external occipital protuberance. From this a thin median septum is continued forwards to the external occipital crest and the spines of the upper vertebrae, as well as into the intervals between the latter. The ligament consists in man mainly of white fibrous tissue; but in the lower animals it is a strong elastic structure which supports the head.

The supra- and interspinous ligaments, together with the ligamentum nuchæ, are derived from the median dorsal intermuscular septum. In the lumbar region the spinous processes of adjacent vertebrae sometimes become united by synovial articulations near their free extremities.

The **intertransverse ligaments** are unimportant bands extending between the transverse processes. In the lumbar region they are membranous and correspond to the anterior superior costo-transverse ligaments of the ribs; in the mid-dorsal region there are small rounded bundles taking the place of the intertransverse muscles of the lower spaces; and in the upper dorsal and cervical regions they are generally wanting.

**Movements.**—The movements of flexion and extension of the vertebral column are freely allowed in the cervical and lumbar regions, but in the dorsal are limited by the small amount of intervertebral substance and the imbrication of the laminae. The greatest bending backwards is permitted in the cervical, the greatest bending forwards in the lumbar region, especially between the last three vertebrae. Movements in other directions are determined chiefly by the articular processes. In the dorsal region the articular surfaces of each vertebra lie in the arc of a circle the centre of which is in front, between the bodies of the vertebrae,

and round this centre a certain degree of rotation is permitted. In the lumbar region, the centre of the circle in which the articular surfaces lie is placed behind, so that rotation is prevented; the articular processes, however, permit of lateral flexion, and by combination of this with antero-posterior flexion, some degree of circumduction is produced. The articular surfaces of the cervical vertebrae, being oblique and placed in nearly the same transverse plane, allow neither pure rotation nor pure lateral flexion. They permit, besides forward and backward motion, only one other, which is rotatory round a median axis, directed obliquely from above and behind downwards and forwards—the inferior articular process of one side gliding upwards and forwards on the opposing surface, and that of the other side gliding downwards and backwards, by which a combination of lateral flexion and rotation is obtained.

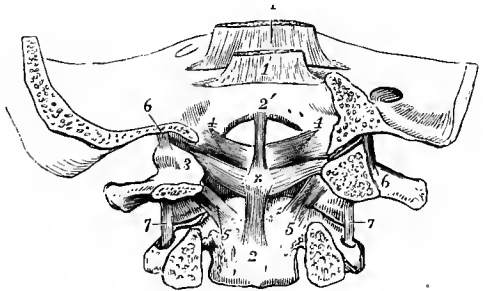
#### THE ARTICULATIONS OF THE ATLAS, AXIS, AND OCCIPITAL BONE.

The atlas, axis, and occipital bone are connected by synovial articulations and ligaments, without the presence of intervertebral discs.

Two pairs of **synovial articulations**, surrounded by **capsular ligaments**, connect the lateral masses of the atlas with the superior articular surfaces of the

Fig. 179.—CORONAL SECTION OF THE LOWER PART OF THE OCCIPITAL BONE, AND THE FIRST TWO VERTEBRÆ, BEHIND THE ARTICULATIONS. (Allen Thomson, after Arnold.)  $\frac{1}{2}$

1, 1, posterior occipito-axial ligament turned up in two layers; 2, 2, vertical part, and 3, 3, transverse or principal part of the cruciform ligament; ×, over the neck of the odontoid process; 4, 4, lateral odontoid or check ligaments; 5, 5, accessory ligaments of the atlanto-axial capsules; 6, 6, capsular ligaments of the condylar articulations; 7, 7, capsular ligaments of the atlanto-axial articulations.

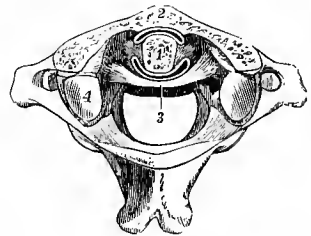


axis and with the condyles of the occipital bone. The atlanto-axial capsule is strengthened at the inner and posterior part by an *accessory ligament*, directed downwards and inwards to the body of the axis near the base of the odontoid process.

The **transverse ligament of the atlas** is a strong and thick band, which extends across the ring of the atlas, and retains the odontoid process in its place.

Fig. 180.—HORIZONTAL SECTION THROUGH THE ODONTO-ATLANTAL ARTICULATION. (Allen Thomson.)  $\frac{1}{2}$

1, cut surface of the odontoid process; 2, cut surface of the anterior arch of the atlas; 3, transverse ligament; between 1 and 2, the anterior synovial cavity, and between 1 and 3, the posterior synovial cavity of the articulation; 4, is placed on the back part of the left superior articular process of the atlas; the anterior part has been partly removed by the section. For the sake of distinctness, the synovial spaces are represented wider than natural.



It is attached on each side to the tubercle below the inner border of the superior articular process. It is arched backwards behind the neck of the odontoid process, and is broadened out in its central part. From the middle of its posterior surface a short thin bundle of fibres passes down to be attached to the body of the axis, while another passes up to the basilar process. These form, with the transverse portion, the figure of a cross, and from this arrangement is derived the term *cruciform*, which is sometimes applied to the transverse ligament and its appendages together.

Two **synovial cavities** are placed one in front of and the other behind the odontoid process; the first of these is situated between the process and the anterior arch of the atlas; the other, which is the more extensive of the two, is between the process and the transverse ligament.

The **lateral or alar odontoid or check ligaments** are two short but very

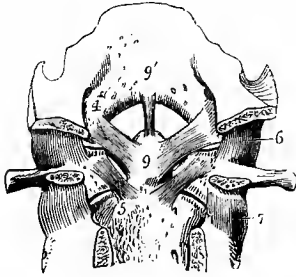


Fig. 181.—TRANSVERSE SECTION SIMILAR TO THAT SHOWN IN FIG. 179, THE CRUCIFORM LIGAMENT HAVING BEEN REMOVED. (Allen Thomson.)  $\frac{1}{2}$

4, alar odontoid ligament; 5, accessory atlanto-axial ligament; 6, 7, capsular ligaments of the occipito-atlantal and the atlanto-axial articulations; 9, odontoid process; 9, 9', middle odontoid ligament.

strong bundles of fibres, which extend from the sides of the summit of the odontoid process outwards and a little upwards to be implanted into the rough impression on the inner side of each

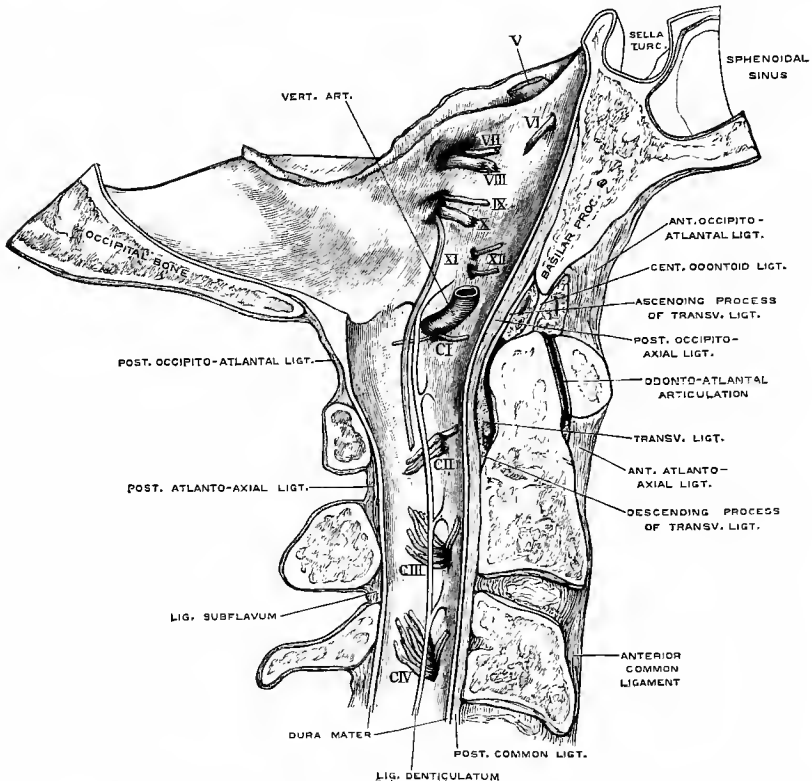


Fig. 182.—MEDIAN SECTION OF THE FIRST THREE CERVICAL VERTEBRÆ AND PART OF THE OCCIPITAL BONE, WITH THEIR LIGAMENTS, &c. (Drawn by T. W. P. Lawrence.)

V to XII, fifth to twelfth cranial nerves; C I to C IV, first to fourth cervical nerves.

condyle of the occipital bone. Some of the upper fibres of the two ligaments are usually continuous across the middle line.

The **middle odontoid or suspensory ligament** is a small cord which passes

directly upwards from the summit of the odontoid process to the centre of the anterior margin of the foramen magnum.

The central odontoid ligament is developed around the notochord in the interval between the basioccipital and first vertebral centrum, and may therefore be said to represent an intervertebral disc. The transverse ligament of the atlas and the lateral odontoid ligaments are derived from ligamenta conjugalια costarum (p. 159).

The **posterior occipito-axial ligament** is a strong wide band, covering the cruciform and odontoid ligaments. It is attached above in the basilar groove of the occipital bone, and below to the body of the axis; many of the superficial fibres are prolonged into the posterior common ligament, of which it forms the continuation upwards.

The **anterior occipito-atlantal ligament** extends from the anterior border of the occipital foramen, between the condyles, to the anterior arch of the atlas.

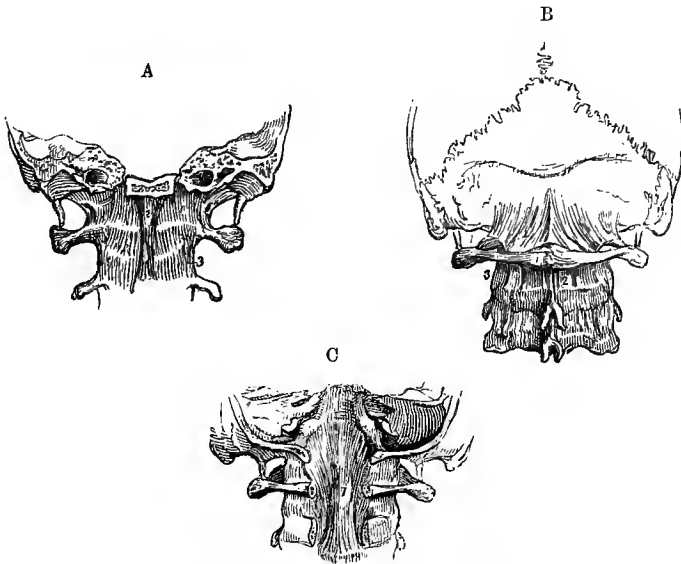


Fig. 183.—THE LIGAMENOUS STRUCTURES WHICH SURROUND THE ARTICULATIONS OF THE OCCIPUT AND TWO UPPER VERTEBRÆ.  $\frac{1}{2}$

A, the lower part of the skull sawn transversely through the basilar process, with the atlas and axis, viewed from before. 1, anterior occipito-atlantal ligament; 2, accessory occipito-atlantal ligament; 3, anterior atlanto-axial ligament.

B, the lower part of the skull, with three adjacent vertebrae, viewed from behind. 1, posterior occipito-atlantal ligament; 2, posterior atlanto-axial ligament.

C, the occipital bone sawn transversely through the foramen magnum, and a part of the arches of the atlas and axis removed, so as to show the posterior occipito-axial ligament.

It is thin and membranous; but in the median line it is strengthened by an *accessory ligament*, thick and round, placed in front of it, which is sometimes described as the commencement of the anterior common ligament.

The **anterior atlanto-axial ligament**, likewise thin and membranous, except in the middle, where it is similarly thickened by a prolongation of the anterior common ligament, extends from the anterior arch of the atlas to the body of the axis.

The **posterior occipito-atlantal ligament**, thin and membranous, is attached superiorly to the margin of the occipital foramen behind the condyles, and inferiorly

to the adjacent border of the arch of the atlas: it is closely united to the dura mater. A small band on each side forms an arch between the back of the vertebral groove and the posterior end of the superior articular process of the atlas, thus completing a foramen through which pass the vertebral artery and the suboccipital nerve. This arch is not unfrequently ossified (p. 8).

The **posterior atlanto-axial ligament**, similar to the preceding, connects the neural arch of the atlas with that of the axis, in the place of ligamenta subflava. It is perforated on each side by the second cervical nerve.

**Movements.**—The atlanto-axial articulation is so constructed that the head, together with the atlas, is rotated on the axis, the odontoid process serving as a pivot. The rotation is limited by the check ligaments: its extent is about 30° to either side. The occipito-atlantal articulation takes no part in rotation, but allows the head to be freely raised or depressed upon the vertebral column. When the atlas is placed symmetrically over the axis, it is seen that the opposing articular surfaces, instead of fitting one to the other, come very slightly into contact, the surface of the axis presenting an antero-posterior convexity, to which there is no corresponding concavity presented by the atlas; but a slight rotation brings the bones into a stable position, in which the anterior half of one articular surface of the axis and the posterior half of the other are laid closely against the atlas. It will also be found that a small amount of oblique motion between the atlas and occipital bone is permitted, by which the anterior half of one condyle and the posterior part of the other may be rested together on the atlas, and that that is the position of greatest stability. This oblique position is that into which the bones are brought when there is any lateral flexion of the column, as is the case in the most natural and easy attitudes.

#### THE ARTICULATIONS OF THE THORAX.

The articulations of the ribs with the vertebræ are divided into *costo-central* and *costo-transverse*. Anteriorly the costal cartilages are connected to the sternum by

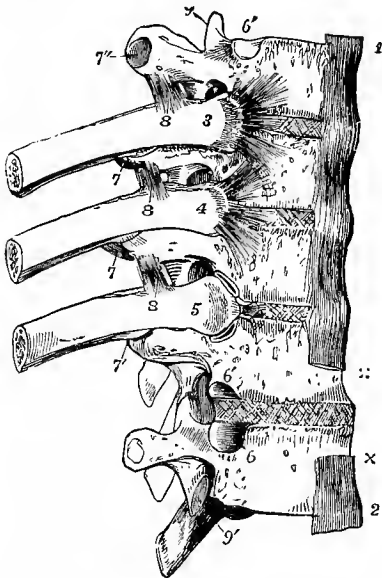


Fig. 184.—THE 5TH, 6TH, 7TH, 8TH, AND 9TH DORSAL VERTEBRÆ, WITH PARTS OF THE 6TH, 7TH, AND 8TH RIBS, FROM THE RIGHT SIDE AND FRONT. (Allen Thomson.)  $\frac{1}{3}$

The 9th rib has been removed to show the articular surfaces of the vertebræ corresponding to it; 3 and 4, the heads of the 6th and 7th ribs, from which the stellate ligaments are seen spreading over the two adjacent vertebral bodies and intervertebral substance; 5, the head of the 8th rib, from which the stellate ligament has been removed, so as to expose the upper and lower synovial cavities, and between them the interarticular ligament; 6, lower, and 6', upper facet of the costo-central articulation; 7, posterior costo-transverse ligament; 7', the costo-transverse synovial cavity; 7'', the costo-transverse articular facet; 8, anterior superior costo-transverse ligament; 9, superior articular process of the 5th vertebra; 9', inferior of the 9th.

the *chondro-sternal articulations*, and with one another by the *interchondral articulations*. The three portions of the breast-bone are united by the *sternal articulations*.

The **COSTO-CENTRAL ARTICULATION** unites the head of the rib, in most instances, with the bodies of two vertebræ by two distinct

synovial joints, supported by ligaments as follows.

The **anterior costo-central** or **stellate ligament** consists of fibres which radiate from the head of the rib to the body of its proper vertebra, to the intervertebral disc, and to the body of the vertebra above. Short fibres surround the remaining portion of the articulation and complete a *capsule* to the joint.



The **interarticular ligament** is a thin and short band of fibres, which passes transversely from the ridge separating the two articular surfaces on the head of the rib to the intervertebral disc, and divides the articulation into two parts, each lined by a separate synovial membrane. The ligament does not exist in the articulations of the first, eleventh, or twelfth ribs, as these ribs are each attached to only one vertebral body by a single synovial joint.

**Conjugal ligament.**—In many mammals there is a band known as the *ligamentum conjugale costarum* uniting the heads of opposite ribs across the back of the intervertebral disc. This ligament is represented in man by fibres passing from the hinder part of the neck of the rib through the intervertebral foramen to the back of the intervertebral disc and the corresponding process of the posterior common ligament of the vertebræ (*lig. conjugale colli costæ*—Luschka). According to Sutton the conjugal ligament is distinct in the human fœtus from the seventh month, and the interarticular ligament is derived from its outer end.

The **COSTO-TRANSVERSE ARTICULATION** unites the tuberosity of the rib to the corresponding transverse process by a simple synovial joint, and ligaments pass from the tuberosity and neck of the rib to the transverse processes of its proper vertebra and of the vertebra above.

The **posterior costo-transverse ligament** is a distinct band extending outwards from the posterior part of the summit of the transverse process to the rough

Fig. 185.—HORIZONTAL SECTION OF A DORSAL VERTEBRA, WITH THE ADJACENT PORTIONS OF TWO RIBS. (R. Quain.)  $\frac{3}{4}$

1, rib; 2, transverse process; 3, anterior costo-central ligament; 5, posterior costo-transverse ligament; 6, middle costo-transverse ligament.

external part of the tuberosity of the rib.

The **middle or interosseous costo-transverse ligament** consists of a series of short parallel fibres, which

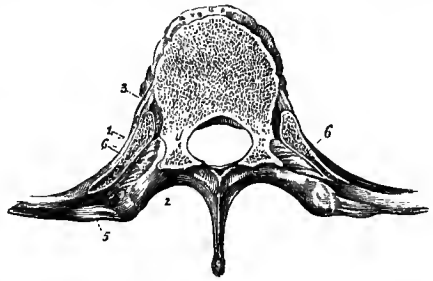
unite the neck of the rib to the anterior surface of the contiguous transverse process. These fibres are seen on removing by horizontal section a portion of the rib and transverse process, and forcibly drawing the one from the other.

The **superior costo-transverse ligaments** are two in number, anterior and posterior. The *anterior* is a flattened band composed of fibres which pass from a ridge on the upper border of the neck of the rib upwards and outwards to the lower margin of the transverse process next above it. Its internal margin is thickened and free; externally it is continued into the posterior intercostal aponeurosis, which occupies the hinder portion of the intercostal space. The *posterior* is a smaller and less regular fasciculus extending from the neck of the rib upwards and inwards to the base of the transverse process and the outer side of the lower articular process of the vertebra above. These ligaments are wanting to the first rib.

A third ascending band, external to the last, is sometimes present, running from the outer part of the tuberosity of the rib to the tip of the transverse process above.

There are no synovial joints between the lowest two ribs and the transverse processes, and the posterior and middle costo-transverse ligaments are represented by a single band.

The **CHONDRO-STERNAL ARTICULATIONS**, situated between the inner extremities of the cartilages of the sternal ribs and the corresponding fossæ in the margins of the sternum, are, with the exception of the first, small synovial joints, surrounded



by short capsules, which are most developed in front and behind, and thus form *anterior* and *posterior ligaments*. The fibres of the anterior ligament radiate from the extremity of the cartilage to the anterior surface of the sternum, where they interlace with those of the opposite side, and are blended with the tendinous fibres of origin of the pectoralis major muscle; the fibres of the posterior ligament are similarly disposed, but are not so thick or numerous. In the second articulation the synovial cavity is divided into two by a short *interarticular ligament*, passing horizontally between the end of the costal cartilage and the fibro-cartilaginous layer uniting the manubrium to the body of the sternum; and similar divisions sometimes exist in the succeeding joints. The synovial cavity is frequently wanting

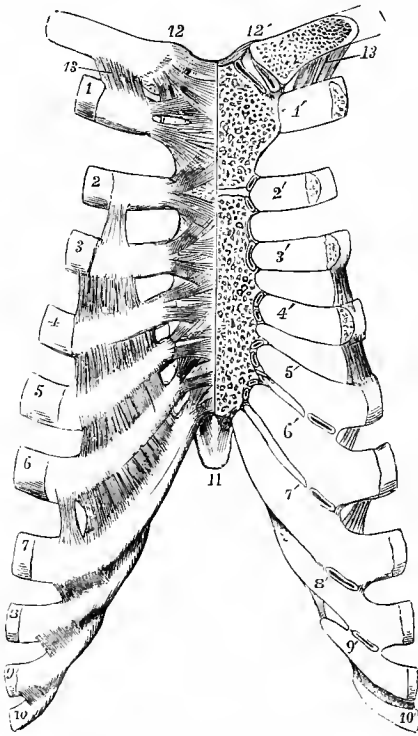


Fig. 186.—ARTICULATIONS OF THE STERNUM, CLAVICLE, AND RIBS, SEEN FROM BEFORE. (Allen Thomson, after Arnold.)  $\frac{1}{3}$

On the right side the anterior ligaments are shown; on the left side, the front parts of the clavicle, sternum and costal cartilages have been removed so as to display the articular cavities. 1 to 10, the anterior extremities of the ribs from the first to the tenth inclusive, on the right side; 1' to 10', the costal cartilages of the left side from the first to the tenth; at 1', the direct union of the first costal cartilage with the sternum is shown; at the sternal ends of the cartilages marked 2' to 7', the small synovial cavities are opened; between the costal cartilages on the right side the anterior intercostal aponeuroses are shown stretching over the intercostal spaces; and on the left side, by a section, small synovial cavities are shown between the adjacent edges of the costal cartilages from the 5th to the 9th; on the front of the right half of the sternum the radiating anterior chondro-sternal ligaments are shown; 11, ensiform process; 12, 12', interclavicular ligament; and below 12, the anterior sterno-clavicular ligament; below 12', the sterno-clavicular articulation is opened, showing the inter-articular fibro-cartilage and double synovial cavity; 13, the costo-clavicular or rhomboid ligament.

in the articulations of the sixth and seventh cartilages. The cartilage of the first rib is almost always directly united to the sternum.

A variable fasciculus of fibres connecting the cartilage of the seventh rib and sometimes likewise that of the sixth, with the xiphoid cartilage, is called the *costo-xiphoid ligament*.

The **INTERCHONDRAL ARTICULATIONS** are synovial joints formed by the processes on the adjacent margins of some of the costal cartilages, viz., from the fifth (sometimes the sixth) to the eighth or ninth, surrounded by short capsules. The joints are strengthened anteriorly by oblique ligamentous fibres, derived from the anterior intercostal aponeuroses which occupy the fore parts of the intercostal spaces.

**Connection of the ribs with the cartilages.**—The external extremities of the cartilages are fixed into the oval depressions on the ends of the ribs, and the union receives support from the periosteum.

A synovial joint is occasionally formed between the first rib and its cartilage, or in the outer part of the cartilage when ossification around the latter is far advanced. (Luschka, "Die anomalen Articulationen des ersten Rippenpaares," Wiener Sitzungsber., 1860; W. A. Lane, Guy's Hosp. Reports, xliii.)

**STERNAL ARTICULATIONS.**—The manubrium and body of the sternum are united by a symphysis, the disc being composed of a layer of cartilage above and below, with a central fibro-cartilaginous stratum, in which a cavity is frequently formed. The articulation is farther supported by anterior and posterior ligamentous fibres, which have chiefly a longitudinal direction, and are most developed on the back of the sternum. The whole sternum is much strengthened by thick periosteum and the radiating fibres of the chondro-sternal ligaments already mentioned. A layer

Fig. 187.—DIAGRAM OF FIRST AND SEVENTH RIBS, IN CONNECTION WITH THE SPINE AND THE STERNUM, SHOWING HOW THE LATTER IS CARRIED UPWARDS AND FORWARDS IN INSPIRATION. (G. D. T.)

The expiratory position is indicated by continuous lines, the inspiratory by broken lines.

of cartilage intervenes between the body and ensiform process so long as they are not united by bone.

**Movements of the ribs.**—The chief movement of the ribs generally is one of rotation, upwards and downwards, about an axis which is directed obliquely outwards and backwards, as well as mostly somewhat downwards, passing through the costo-central articulation and the neck of the rib, and a little in front of the costo-transverse joint. Owing to the downward inclination of the ribs as they extend forwards, their anterior ends when elevated also advance, so that the front wall of the chest is carried upwards and forwards in inspiration, thus increasing the sagittal

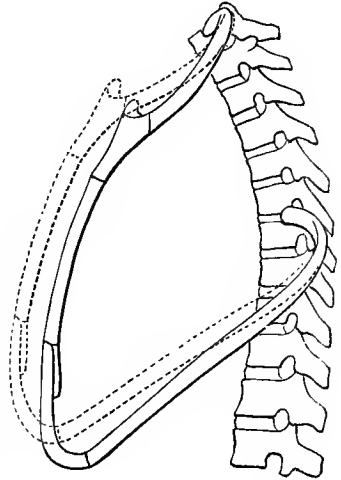
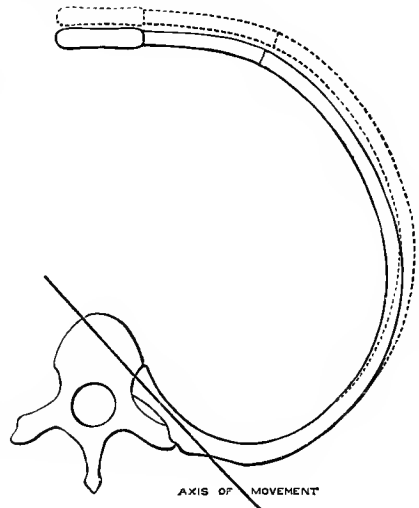


Fig. 188.—DIAGRAM OF THE FIFTH THORACIC VERTEBRA AND COSTAL ARCH, PROJECTED ONTO A HORIZONTAL PLANE, TO SHOW THE AXIS OF MOVEMENT OF THE RIB, AND THE MANNER IN WHICH THE SAGITTAL AND CORONAL DIAMETERS OF THE THORAX ARE INCREASED. (G. D. T.)

The continuous lines indicate the position in expiration, the broken lines in inspiration.

diameter of the thorax. At the same time, by reason of the obliquity of the axis, the anterior and lateral parts of the ribs move outwards, giving rise to the so-called eversion of the ribs, and the transverse diameter of the cavity is increased. This lateral movement of the fore part of the rib is accompanied by an opening out of the angle between the rib and its costal cartilage. The degree of lateral expansion is necessarily proportionate to the obliquity of the axis of movement. In the first rib the axis is nearly transverse, and thus, while a considerable degree of elevation is permitted, the eversion is but slight. In proceeding downwards the transverse processes of the vertebræ and the necks of the ribs become more inclined backwards, so that the obliquity of the axis increases, and the outward movement becomes more extensive. In the upper six ribs, the convex tuberosities of which are received into small hollows on the corresponding transverse processes, this rotation is the only movement allowed; but from the seventh to the tenth the costo-transverse joints have nearly plane articular surfaces, the vertebral facets being placed at the upper and fore part of the extremity of the transverse process, and these ribs move backwards as well as



upwards in inspiration, forwards and downwards in expiration. The last two ribs, forming no costo-transverse articulations, move freely backwards and forwards, while the up and down movement is more limited: the twelfth rib in inspiration is drawn backwards and rather downwards. When the vertebral column is extended, the ribs are raised and separated; and when the column is bent forwards, the ribs are depressed and brought together. The combined movements of the chest-walls in respiration will be considered with the actions of the thoracic muscles.

#### TEMPORO-MAXILLARY ARTICULATION.

The articular surfaces of this joint are the condyle of the lower jaw, which is approximately a portion of a cylindrical body, with its axis directed from without

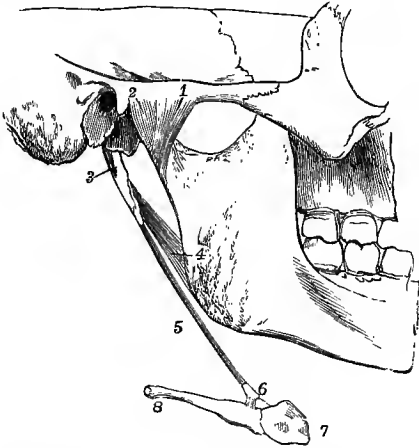


Fig. 189.—A PORTION OF THE SKULL WITH THE LOWER JAW AND HYOID BONE, SEEN FROM THE OUTER SIDE. (Allen Thomson, after Arnold.)  $\frac{1}{2}$

1, external lateral ligament of the temporo-maxillary articulation; 2, a part of the capsule of the joint; 3, styloid process; 4, stylo-maxillary ligament; 5, stylo-hyoid ligament; 6, lesser cornu of the hyoid bone with some short ligamentous fibres attaching it to, 7, the body, and 8, the great cornu.

inwards and slightly backwards, and the surface of the squamous portion of the temporal bone extending over the part of the glenoid fossa in front of the Glaserian fissure and the articular eminence formed by the anterior root of the zygoma. The two are markedly incongruent, and the temporal surface is much larger than that of the inferior maxilla. The incongruence is compensated by the interposition of a meniscus

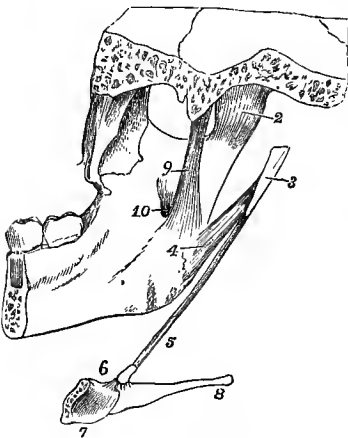


Fig. 190.—A PORTION OF THE SKULL AND LOWER JAW WITH HALF THE HYOID BONE, SEEN FROM THE INSIDE. (Allen Thomson.)  $\frac{1}{2}$

The numbers are the same as in fig. 189; 3, styloid process, detached from the skull; 7, posterior surface of the right half of the body of the hyoid bone; 9, internal lateral ligament of the temporo-maxillary joint; 10, inferior dental foramen.

which divides the joint into an upper and a lower synovial cavity. The layer clothing the articular surfaces of the bones is composed of fibro-cartilage.

The **external lateral ligament** is a short fasciculus of fibres, attached above to the lower border and the tubercle of the zygoma; and below to the external surface and posterior border of the neck of the lower jaw, its fibres being directed downwards and backwards. Scattered ligamentous fibres cover the synovial membrane in front, on the inside, and behind, forming a thin and loose capsule round the joint.

The **internal lateral ligament** is a flat, thin band, placed at some distance from the joint. It extends from the spinous process of the sphenoid bone down-

wards and a little forwards, to be attached to the lingula and the lower border of the inferior dental foramen. Between it and the lower jaw are placed the external pterygoid muscle, the internal maxillary vessels, the auriculo-temporal nerve, and the inferior dental vessels and nerve.

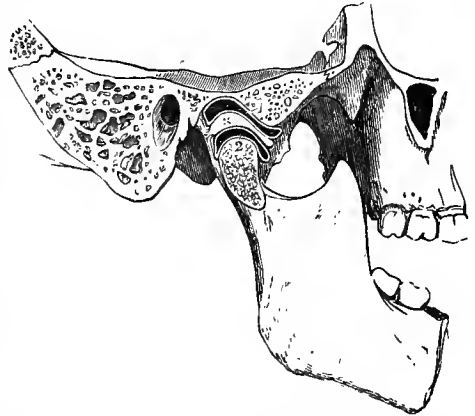
The internal lateral ligament is formed in the tissue surrounding a part of Meckel's cartilage (p. 78).

The **interarticular disc** or **meniscus** is a thin plate of fibro-cartilage placed between the articular surfaces of the bones. It is of an oval form, broadest transversely, thickest posteriorly, and thinnest at its centre, where it is sometimes perforated. The inferior surface, which is in contact with the condyle, is concave; the superior is concavo-convex from before backwards, conforming with the articular surface of the temporal bone. Its circumference is attached closely to the capsule, and anteriorly a part of the external pterygoid muscle is inserted into it.

**Synovial sacs.**—The synovial sac between the interarticular disc and the glenoid cavity is larger and looser than that which is interposed between the disc

Fig. 191.—SAGITTAL SECTION OF THE TEMPORO-MAXILLARY ARTICULATION OF THE RIGHT SIDE. (Allen Thomson.)  $\frac{3}{4}$

1, is placed close to the articular eminence, and points to the superior synovial cavity of the joint; 2, is placed close to the articular surface of the condyle of the lower jaw, and points to the inferior synovial cavity of the joint; x, is placed on the thicker posterior portion of the interarticular disc.



and the condyle of the jaw. When the fibro-cartilage is perforated, the upper and lower synovial cavities necessarily communicate with each other.

The **stylo-maxillary ligament** is the name given to a strong band of the cervical fascia extending from the styloid process to the angle and posterior border of the ramus of the jaw, where it is inserted between the masseter and internal pterygoid muscles. It separates the parotid from the submaxillary gland.

It may be proper also to mention here the **stylo-hyoid ligament**, a thin fibrous cord, which passes from the point of the styloid process to the lesser cornu of the hyoid bone, and suspends that bone from the styloid process. A considerable portion of the stylo-hyoid ligament is sometimes converted into bone in the human subject, and in many animals it is naturally osseous, constituting the *epihyal bone*.

**Movements.**—The jaw is capable of movements of elevation and depression, and of protrusion and retraction; but it is to be observed that when the jaw is depressed, as in opening the mouth, the condyle advances from the glenoid cavity so as to be placed on the articular eminence in front of it. The movements which take place in the superior and inferior compartments of the joint are of different kinds. In the upper the fibro-cartilage glides forwards and backwards on the temporal bone; in the lower compartment the condyle rotates on a transverse axis against the fibro-cartilage. In opening the mouth the two movements are combined; the jaw and fibro-cartilage together move forwards and rest on the convex root of the zygoma, while at the same time the condyle revolves on the fibro-cartilage. The point of least movement corresponds approximately to the position of the inferior dental foramen, so that stretching of the inferior dental nerve is avoided. When the lower incisors are protruded beyond those of the upper jaw, the movement is confined chiefly

to the upper articulation; and when the same movement is alternately performed in the joints of opposite sides a horizontal oblique or grinding motion is produced. The fibres of the external lateral ligament remain tight in opening the mouth, owing to the descent of the condyle when it passes forwards on to the articular eminence.

## II.—THE ARTICULATIONS OF THE UPPER LIMB.

### THE SCAPULO-CLAVICULAR ARCH.

The supporting arch of the upper limb has only one point of attachment to the skeleton of the trunk, namely, at the sterno-clavicular articulation, the scapula being connected with the trunk only by muscles.

The clavicle articulates at its inner end with the first piece of the sternum, and is connected by ligaments also to its fellow of the opposite side and to the first rib. At its outer end it is united to the scapula.

**STERNO-CLAVICULAR ARTICULATION.**—The articular surface of the inner end of the clavicle is considerably larger than the opposing surface of the sternum, and the investing layer of both surfaces is composed mainly of fibro-cartilage. The joint is surrounded by a fibrous capsule, which is of considerable thickness in front and behind, forming anterior and posterior ligaments, but very thin at the lower and outer part, between the inner end of the clavicle and the first rib-cartilage. Between the two bones an interarticular fibro-cartilage is interposed.

The **anterior sterno-clavicular ligament**, broad and consisting of parallel fibres, passes from the front of the inner extremity of the clavicle, downwards and inwards, to the anterior surface of the manubrium.

The **posterior sterno-clavicular ligament**, on the posterior aspect of the joint, is of similar conformation to the anterior ligament, but is not so strongly marked.

The **interclavicular ligament** is a dense fasciculus of fibres passing between the sternal ends of the clavicles. It dips downwards in the middle, where it is attached to the interclavicular notch of the sternum.

The **interarticular fibro-cartilage**, nearly circular in form, and thicker above and at its margins than at the centre, is interposed between the articular surfaces of the two bones. Superiorly it is attached to the upper part of the inner extremity of the clavicle, and inferiorly to the cartilage of the first rib. In the latter situation it is thin and prolonged outwards, beneath the lower border of the clavicle.

**Synovial cavities.**—There are two synovial cavities in this articulation, one on each side of the interarticular fibro-cartilage. The outer one is the more extensive, and is continued a short distance below, between the clavicle and first costal cartilage.

The interarticular fibro-cartilage is occasionally defective or wanting, in which case there is only one synovial cavity. The interclavicular ligament and interarticular fibro-cartilages together represent the episternal bone of monotremes and lizards.

The **costo-clavicular** or **rhomboid ligament** may be regarded as an accessory ligament of the sterno-clavicular articulation. It is attached inferiorly to the cartilage of the first rib near its sternal end, and passes obliquely upwards, backwards and outwards, to be fixed to a rough impression on the under surface of the clavicle near the sternal end. The ligament is sometimes hollow, containing a bursa.

**SCAPULO-CLAVICULAR ARTICULATION.**—At its outer end the clavicle is connected to the acromion and coracoid processes of the scapula.

The **acromio-clavicular articulation** is a synovial joint uniting the outer extremity of the clavicle with the inner edge of the acromion. Both articular surfaces are covered with fibro-cartilage. The articulation is supported above by a thick and broad *superior ligament*, and below by an *inferior ligament* which is very thin. A small *interarticular fibro-cartilage* is sometimes present. It is wedge-shaped, attached by its base to the superior ligament, and projects only a short distance between the articular surfaces. In rare cases it effects a complete division of the joint.

The **coraco-clavicular ligament**, which connects the clavicle with the coracoid process of the scapula, is divisible into two parts. The *conoid ligament*, which is the posterior and internal fasciculus, broad above, narrow below, is attached inferiorly to the inner part of the root of the coracoid process, and superiorly to the conoid

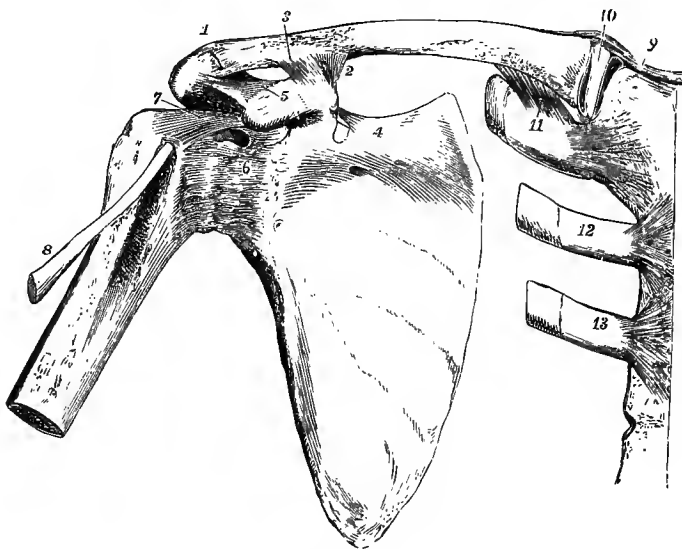


Fig. 192.—VIEW FROM BEFORE OF THE ARTICULATIONS OF THE SHOULDER-BONES. (Allen Thomson.) †

1, acromio-clavicular articulation ; 2, conoid, and 3, trapezoid part of the coraco-clavicular ligament ; 4, near the suprascapular ligament ; 5, on the coracoid process, points to the coraco-acromial ligament ; 6, capsular ligament of the shoulder-joint ; 7, coraco-humeral ligament ; above 6, an aperture in the capsular ligament through which the synovial membrane is prolonged under the tendon of the subscapularis muscle ; 8, tendon of the long head of the biceps muscle ; 9, right half of the interclavicular ligament ; 10, interarticular fibro-cartilage of the sterno-clavicular articulation ; 11, costo-clavicular ligament ; 12 and 13, cartilage and small part of the second and third ribs attached by their anterior chondro-sternal ligaments.

tubercle of the clavicle: its fibres are directed backwards and upwards. The *trapezoid ligament*, the anterior or external fasciculus, slopes upwards, backwards and outwards from the posterior half of the upper surface of the coracoid process to the trapezoid line, on which it is inserted into the clavicle. In the angle between the conoid and trapezoid ligaments there is frequently a synovial bursa.

A complete synovial joint is occasionally formed between the clavicle and the first rib-cartilage internally, or between the clavicle and the coracoid process externally.

**Movements, &c.**—The clavicle is firmly bound down at its inner end in the sterno-clavicular articulation, and upon this as a centre it can be moved upwards and downwards, forwards and backwards, or in any intermediate direction, necessarily carrying with it the scapula, which glides in a corresponding direction over the thoracic wall. The scapula farther undergoes a movement of rotation, by which the acromion is raised and the glenoid cavity

directed upwards when the arm is elevated, and the reverse when the arm is depressed. A limited degree of rotation of the clavicle upon its long axis is also permitted, the anterior surface turning upwards as the arm is raised.<sup>1</sup> The movements of the bones are limited, not so much by the forms of the articular surfaces, as by the costo-clavicular and coraco-clavicular ligaments, and the position of the thoracic wall. When the clavicle is forcibly depressed, as in lifting a heavy weight, it presses upon the first rib, its sternal end rises, and the interarticular fibro-cartilage and interclavicular ligament, as well as the anterior and posterior ligaments, are put upon the stretch. The interarticular fibro-cartilage also resists pressure from the shoulder conveyed through the clavicle, and prevents that bone from being displaced inwards. The rhomboid ligament limits upward and backward movements of the clavicle. The acromio-clavicular joint is loose and allows of considerable play, by which the angle between the spine of the scapula and the clavicle is altered as the shoulder is moved; and the scapula is supported on the clavicle principally by the strong coraco-clavicular ligament, the conoid division of which suspends the scapula from the clavicle, while the trapezoid portion is tightened when the shoulder is pressed inwards.

**LIGAMENTS OF THE SCAPULA.**—The **coraco-scapular** or **suprascapular ligament** is a thin, flat band of fibres attached by its extremities to the opposite margins of the notch at the root of the coracoid process, which it thus converts into a foramen for the transmission of the suprascapular nerve, the corresponding artery most commonly passing above it. This ligament is sometimes converted into bone. There is generally a second smaller band below the nerve, close to the bottom of the notch, on the ventral aspect of the bone.

The **coraco-acromial ligament**, triangular in shape, is attached by its broader extremity to the outer edge of the coracoid process, and by the narrower to the tip of the acromion. It consists of strong anterior and posterior bands, with a thinner central part near the coracoid process, where it is sometimes perforated by a prolongation of the tendon of the pectoralis minor. Its inferior surface looks downwards upon the shoulder-joint, the superior is covered by the deltoid muscle. From its outer border a thin fascial layer is continued downwards over the subacromial bursa and the shoulder-joint. The ligament forms with the coracoid and acromion processes an arch which gives support and protection to the shoulder-joint.

**Spino-glenoid ligament** (fig. 193).—This is composed of irregular and lax fibrous bundles which pass from the outer edge of the spine to the back of the head of the scapula, bridging over the suprascapular vessels and nerve as they lie in the acromio-scapular notch. It is often wanting.

#### THE SHOULDER-JOINT.

In this articulation the large and hemispherical head of the humerus is opposed to the much smaller surface of the glenoid cavity of the scapula. The bones are retained in position, not by the direct tension of ligaments, which would restrict too much the movements of the joint, but by surrounding muscles and atmospheric pressure.

The **capsular ligament** (fig. 192, 6) is attached to the scapula round the margin of the glenoid cavity, and to the humerus at the place where the neck springs from the tuberosities and shaft. It extends farthest down the humerus on the inferior aspect, and is strongest on the superior aspect. It is so lax that the humerus separates from the glenoid cavity as soon as its muscular connections are detached. Above and behind, the capsule is strengthened by the tendons of the supraspinatus, infraspinatus, and teres minor muscles, which are intimately connected with it as they pass over the joint to reach the great tuberosity of the humerus. In front the tendon of the subscapularis muscle comes into contact with the synovial membrane, which is prolonged upon it through an oval opening in the capsule. The insertion of the

<sup>1</sup> Cleland, Journ. Anat., xviii, 277.



capsule is likewise interrupted opposite the bicipital groove, to give passage to the long tendon of the biceps muscle.

The **coraco-humeral ligament** is a strong wide band extending obliquely over the upper part of the articulation; it springs from the root and outer border of the coracoid process beneath the coraco-acromial ligament, and thence passes to the neck of the humerus above the great tuberosity, being intimately connected with the capsule.

The coraco-humeral ligament represents a detached portion of the tendon of the pectoralis minor muscle. There is sometimes a small band passing from the coracoid process with this ligament to the upper and hinder margin of the head of the scapula, and known as the *coraco-glenoid ligament*.

**Gleno-humeral ligaments.**—These are three bands of fibres in the inner and fore part of the capsule, which project towards the interior of the joint, and are best seen when the

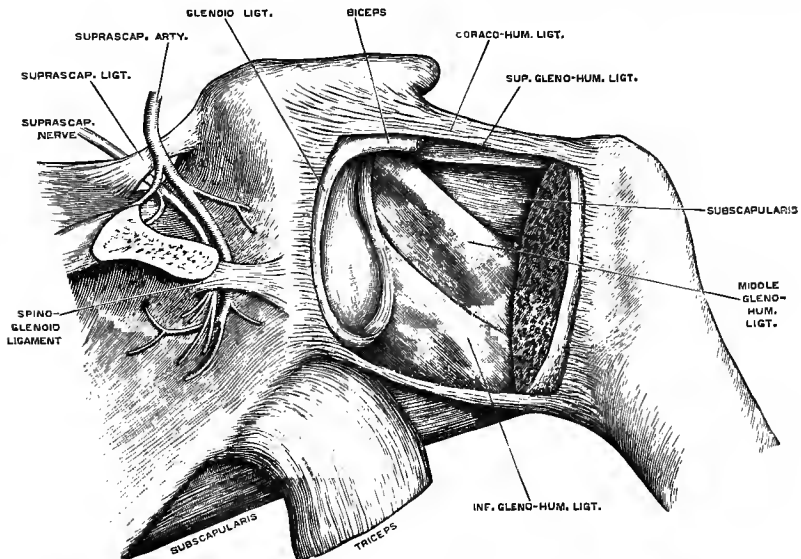


Fig. 193.—RIGHT SHOULDER-JOINT OPENED FROM BEHIND, TO SHOW THE GLENO-HUMERAL LIGAMENTS. (G. D. T.)

The hinder part of the capsule has been removed, the head of the humerus sawn off, and the tendon of the biceps divided near its origin.

articulation is opened from behind. The *superior* extends from the upper end of the anterior margin of the glenoid cavity, along the inner edge of the biceps tendon, to the inner margin of the upper end of the bicipital groove, where there is sometimes a notch in the edge of the articular surface; it is supposed to represent the interarticular ligament of the hip-joint. The *middle* springs from the glenoid margin with the foregoing, and is directed downwards and outwards to the inner side of the small tuberosity of the humerus, forming the lower boundary of the aperture through which the synovial membrane reaches the tendon of the subscapularis muscle. And the *inferior*, the strongest of the three, takes a similar course from the middle of the anterior margin of the glenoid fossa to the lower part of the neck of the humerus, where it is attached between the subscapularis and teres minor muscles.

The **transverse humeral ligament** is a small band, forming a continuation of the capsular ligament of the shoulder, which bridges over the bicipital groove between the tuberosities of the humerus, and thus completes a canal for the long tendon of the biceps muscle. (C. Gordon Brodie, Journ. Anat., xxiv, 247.)

The **glenoid ligament** is a fibrous band, about two lines thick, which is fixed to the edge of the glenoid fossa, and thus deepens the cavity. The upper part of it is

connected with the tendon of the long head of the biceps muscle, which is also attached at the upper end of the glenoid fossa, within the capsule of the joint.

The **synovial membrane** is reflected uninterruptedly from the margin of the glenoid cavity on the inner surface of the fibrous capsule to the humerus, but its form is complicated by its relation to the tendons of the biceps and subscapularis muscles.

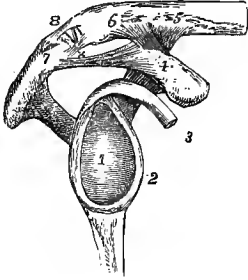


Fig. 194.—VIEW OF THE GLENOID CAVITY AND LIGAMENTS BETWEEN THE SCAPULA AND CLAVICLE OF THE RIGHT SIDE.  $\frac{1}{3}$

1, glenoid fossa, its cartilaginous surface; 2, glenoid ligament; 3, tendon of the biceps muscle in connection with the upper part of the glenoid ligament; 4, upper surface of coracoid process; 5 and 6, on the adjacent part of the clavicle; 4 to 5, the conoid; 4 to 6, the trapezoid portion of the coraco-clavicular ligament; 7, apex of the acromion process; 4 to 7, coraco-acromial ligament; 8, acromio-clavicular articulation, which is open anteriorly, showing a wedge-shaped interarticular fibro-cartilage attached above to the superior acromio-clavicular ligament; x, inferior acromio-clavicular ligament.

The long tendon of the biceps muscle, traversing the joint in its course from the upper end of the glenoid cavity to the bicipital groove, is enclosed in a tubular sheath, formed by a process of the synovial membrane, which is continued down upon it into the osseo-fibrous canal between the tuberosities of the humerus, and is thence reflected upwards lining the canal, to become continuous with

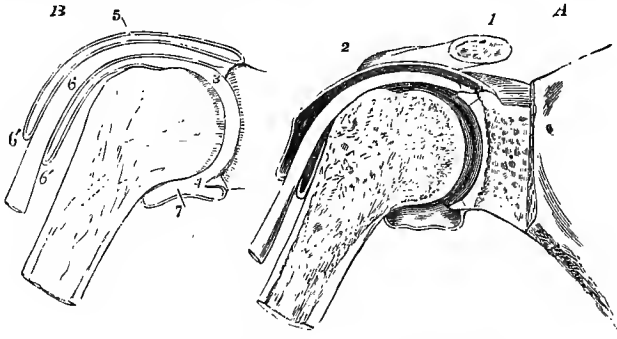


Fig. 195.—A, SECTION THROUGH THE SHOULDER-JOINT, TENDON OF THE BICEPS AND BICIPITAL GROOVE, SHOWING SOMEWHAT DIAGRAMMATICALLY THE SYNOVIAL CAVITY OF THE JOINT, &C. (Allen Thomson.)  $\frac{1}{3}$

B, OUTLINE OF THE SAME, TO SHOW THE REFLECTION OF THE SYNOVIAL MEMBRANE OVER THE TENDON.

1, outer part of the clavicle; 2, its acromial end; 3, cavity of the shoulder-joint close to the upper part of the head of the scapula, where there are seen the section of the cartilages on the head of the humerus and in the glenoid cavity, the glenoid ligament and the origin of the tendon of the biceps muscle; 4, glenoid ligament in the lower part of the cavity; 5, upper part of the capsular ligament and synovial membrane; 6, tendon of the biceps as it passes out of the joint into the bicipital groove; 6', 6', tubular prolongation of the synovial membrane round the tendon; 7, reflection of the synovial membrane on the humerus within the lower part of the capsular ligament.

the synovial membrane of the capsule in such a manner as to preserve the integrity of the membrane. The bursal prolongation of the synovial membrane under the tendon of the subscapularis muscle is of variable extent, sometimes projecting but slightly, sometimes forming a considerable pouch on the venter of the scapula.

**Subacromial bursa.**—Superficial to the muscles covering the top of the joint is a large bursa, which facilitates the movements of the upper end of the humerus beneath the acromion process, the coraco-acromial ligament, and the deltoid muscle.

**Movements.**—The shoulder-joint, being a ball and socket joint, allows of angular movement in all its varieties, as well as of rotation. The freedom of movement in different directions is determined by the extent of the humeral articular surface and the length of the capsule. In extreme positions the neck of the humerus meets the fibrous margin of the glenoid cavity on the side towards which the movement takes place, and the capsule is stretched on the opposite side of the joint. In flexion the humerus is carried forwards and inwards, in extension backwards and outwards, the head of the bone revolving upon an axis which is nearly perpendicular to the centre of the glenoid cavity; in abduction and adduction the arm moves in directions at right angles to the foregoing, the axis being horizontal and parallel to the surface of the glenoid fossa. The range of movement of the humerus upon the scapula in passing from extreme adduction to extreme abduction is but little more than 90°, and in the direction of flexion and extension is still less. The greater freedom of movement enjoyed by the arm, which can be raised from the body until it is directed nearly vertically upwards, is due to rotation of the scapula (p. 165), which always accompanies these movements of the shoulder-joint, the glenoid cavity being turned upwards when the arm is elevated, and sinking again as the limb is depressed. In rotation the humerus revolves about its long axis; the whole range of the movement is about a quarter of a circle. The arch formed by the acromion, the coracoid process, and the coraco-acromial ligament, lined by the subacromial bursa, forms a sort of secondary socket in which the extremity of the humerus, covered by the tendons inserted into the great tuberosity, revolves, and against which it is pressed when the weight of the body is made to rest upon the arms. (C. W. Cathcart, *Journ. Anat.*, xviii, 211; Cleland, *ib.*, 275.)

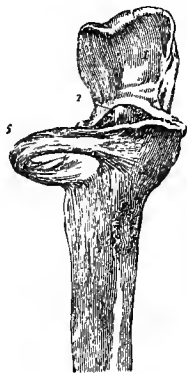#### THE ARTICULATIONS OF THE BONES OF THE FOREARM.

The bones of the forearm are united by a superior and an inferior articulation and an interosseous membrane.

In the **SUPERIOR RADIO-ULNAR ARTICULATION** the head of the radius is received into the small sigmoid cavity of the ulna and is held in position by the **annular** or **orbicular ligament**. This ligament is a strong band of fibres attached to the

Fig. 196.—THE UPPER PART OF THE ULNA, WITH THE ORBICULAR LIGAMENT. (R. Quain.)  $\frac{1}{2}$

1, upper division of the sigmoid surface on the olecranon; 2, extremity of the coronoid process; 5, orbicular ligament.



ulna in front and behind, at the extremities of the small sigmoid cavity, and forming about four-fifths of a ring which encircles the head of the radius and binds it firmly in its situation. The external lateral ligament of the elbow is inserted into its outer surface; its deep surface is smooth, and is lined by the synovial membrane of the elbow joint.

**INFERIOR RADIO-ULNAR ARTICULATION.**—The connection between the sigmoid cavity of the radius and the lower end of the ulna is effected by means of a fibro-cartilage, a synovial sac, and some scattered ligamentous fibres in front and behind. The **triangular fibro-cartilage** is a thick plate attached by its base to the border separating the carpal from the ulnar articulating surface of the radius; and by its apex to a depression at the root of the styloid process of the ulna, and to the outer side of that process. Its upper surface looks towards the ulna, its lower towards the lunar bone, and it separates the inferior radio-ulnar articulation from the wrist-joint. The **synovial sac**, which is very loose, extends upwards between the radius and ulna, and horizontally inwards between the ulna and triangular fibro-cartilage. When the fibro-cartilage is perforated, as is frequently the case, this synovial cavity communicates with that of the wrist-joint.

The **interosseous membrane** or **ligament** of the forearm is a strong fibrous membrane, the fibres of which are directed for the most part obliquely downwards and

inwards, from the interosseous border of the radius to that of the ulna. Its superior border is placed about an inch below the tuberosity of the radius, leaving an open space above (*hiatus interosseus*) through which the posterior interosseous vessels pass. This space is bounded above by the **oblique ligament**, a flattened bundle of fibres

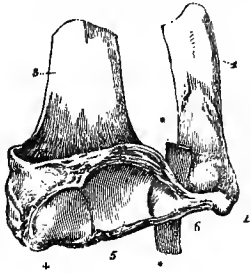


Fig. 197.—THE LOWER PARTS OF THE RADIUS AND ULNA, WITH THE TRIANGULAR FIBRO-CARTILAGE CONNECTING THEM. (R. Quain.)  $\frac{2}{3}$

1, ulna; 2, its styloid process; 3, radius; 4, articular surface for the scaphoid bone; 5, that for the lunar bone; 6, lower surface of the triangular fibro-cartilage; \* \*, a piece of whalebone passed between the fibro-cartilage and the ulna.

directed downwards from the outer part of the tuberosity of the ulna, to be attached to the radius close below the tuberosity: it varies much in size, and is frequently wanting. Other small bundles of fibres, having the same direction as the oblique ligament, are often to be found at intervals, decussating with the fibres of the interosseous ligament on its posterior surface.

**Movement of the radius on the ulna.**—The disposition of the annular ligament allows the head of the radius to rotate freely within it, while the lower end of the radius, being bound by the triangular fibro-cartilage to the styloid process of the ulna, undergoes, in addition to the rotation, a movement of circumduction round that point, by which the hand is brought into the prone or the supine position. Thus in pronation and supination the radius describes a part of a cone, the axis of which extends from the centre of the head of the radius to the styloid process of the ulna. The range of movement between the radius and ulna is rather less than  $180^{\circ}$ . Accompanying the movement of the radius in the pronation and supination of the hand, there is generally a less extensive movement of circumduction on the part of the ulna in a direction opposite to that in which the lower end of the radius travels. The circumduction of the ulna is produced by a slight degree of flexion or extension, together with a corresponding lateral movement, having their seat in the articulation of the elbow, and is not accompanied by any appreciable rotation of this bone. (J. Heiberg, "Ueber die Drehungen der Hand," 1854, and *Journ. Anat.*, xix; T. Dwight, *Journ. Anat.*, xix; C. W. Cathcart, *Journ. Anat.*, xix.)

#### THE ELBOW-JOINT.

The lower extremity of the humerus is in contact with the ulna and radius at the elbow, and forms with them a hinge-joint. The great sigmoid cavity of the ulna articulates with the trochlea of the humerus, so as to admit of flexion and extension; while the cup-shaped depression on the head of the radius can in addition turn freely on the rounded capitellum. In the sigmoid cavity the articular cartilage is usually wanting over a narrow area which extends across a central constriction produced by a marginal notch on each side between the olecranon and the coronoid process. The fibrous capsule surrounding the joint is thickened on the two sides, forming strong lateral ligaments, and the thinner portions in front and behind are known as the anterior and posterior ligaments. The orbicular ligament of the superior radio-ulnar articulation, which has already been described, is also a part of this capsule.

The **internal lateral ligament**, triangular in shape, consists of anterior and posterior thickened bands, and an intermediate thinner part. The anterior band springs from the lower and fore part of the internal condyle of the humerus, and is inserted into the coronoid process, along the inner margin of the sigmoid cavity. The posterior part, broader and stronger, passes from the under and back part of the condyle to the inner border of the olecranon; and the intermediate fibres are

connected with a small transverse band, which bridges over the notch between the olecranon and the coronoid process.

The **external lateral ligament**, intimately connected with the tendinous attachment of the extensor muscles, is shorter and narrower than the internal. It is attached

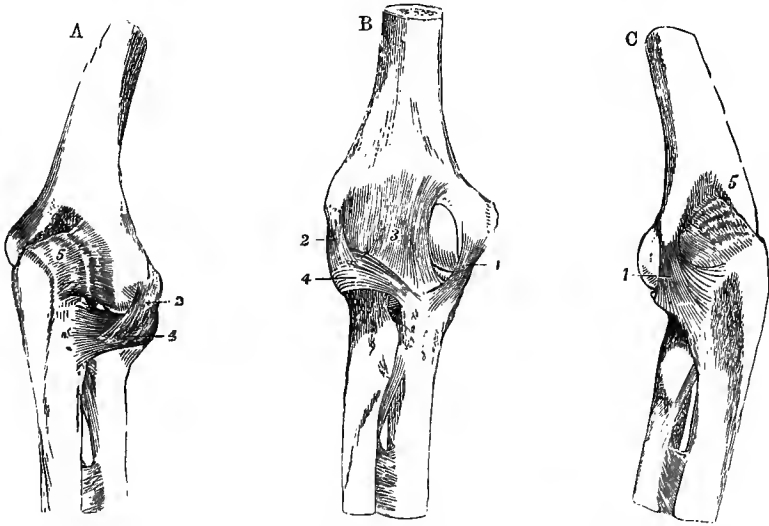
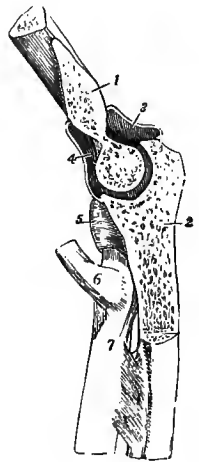


Fig. 198.—LIGAMENTS OF THE ELBOW-JOINT. (Allen Thomson.)  $\frac{1}{3}$

A, from the outer side and behind ; B, from the front ; C, from the inner side and behind. 1, internal lateral ligament ; 2, external lateral ; 3, the middle strongest part of the anterior ligament ; 4, orbicular ligament ; 5, posterior ligament, represented as wrinkled from relaxation in extension. In these figures the oblique ligament and upper part of the interosseous membrane are also represented below the elbow-joint.

Fig. 199.—SAGITTAL SECTION OF THE ELBOW-JOINT THROUGH THE GREAT SIGMOID CAVITY OF THE ULNA AND THE TROCHLEAR SURFACE OF THE HUMERUS. (Allen Thomson.)  $\frac{1}{3}$

1, cut surface of the humerus ; 2, that of the ulna ; 3, posterior part, and 4, anterior part of the synovial cavity of the joint ; 5, orbicular ligament ; 6, tendon of the biceps muscle ; 7, is at the lower end of the oblique ligament.



superiorly to a depression below the external condyle of the humerus, and inferiorly becomes blended with the orbicular ligament, on the surface of which its fibres can be followed forwards and backwards to the extremities of the small sigmoid cavity of the ulna.

The **anterior ligament** consists of a thin sheet of fibres, strongest in its middle part, extending downwards from above the coronoid and radial fossæ of the humerus to the coronoid process of the ulna and the orbicular ligament. It is covered, except at its outermost part, by the brachialis anticus muscle, which is closely attached to it near the coronoid process.

The **posterior ligament**, very thin and weak, consists of loose and irregular fibres passing transversely across the olecranon fossa of the humerus, and from the sides of that fossa to the olecranon process, thus completing the capsule of the joint behind. Externally a rather stronger band extends from a slight depression behind the capitellum to the posterior border of the small sigmoid cavity of the ulna. The

posterior ligament is supported, and drawn up during extension of the joint, by the triceps muscle which is closely adherent to it near the insertion into the ulna.

The **synovial membrane** extends upwards on the humerus so far as to line the fossæ for the coronoid and olecranon processes, and is loose and vascular in the latter positions. It is also prolonged round the neck of the radius, and lines the annular ligament. A small crescentic fold projects between the marginal part of the head of the radius and the capitellum. Between the posterior ligament and the synovial membrane is a mass of fat projecting into the olecranon fossa, and two smaller pads are placed beneath the anterior ligament over the coronoid and radial fossæ.

**Movements.**—Flexion and extension are the chief movements which take place between the humerus and ulna; and in the perfect limb these are arrested, flexion by the meeting of the soft parts of the arm and forearm, extension by the tightening of the ligaments and muscles on the front of the joint, before the coronoid and olecranon processes meet the bottom of their respective fossæ on the humerus. The movements take place upon an axis which is inclined at an angle of about  $84^\circ$  with the shaft of the humerus above and that of the ulna below, so that while in the extended position of the joint these bones form an obtuse angle open outwards, they are placed nearly opposite one another when the elbow is bent.<sup>1</sup> The inner lip of the trochlea, being prominent in front, forms an expansion which corresponds to an inward projection of the coronoid part of the ulnar surface; while the outer lip of the trochlea, being enlarged at the upper and back part, forms a surface which is only in use in complete extension, and which then corresponds to a surface on the outer aspect of the olecranon, which comes into contact with no other part of the humerus. Owing to a slight degree of incongruence, the surface of the sigmoid cavity and the opposed portion of the trochlear surface of the humerus are not in accurate contact over their whole extent, and a very limited amount of lateral motion on the part of the ulna is allowed. In flexion and extension the radius moves by its cup-shaped head upon the capitellum, and on the groove between that eminence and the trochlea by a ridge internal to the cup. It is most completely in contact with the humerus in the position of semi-flexion and semi-pronation.

#### THE WRIST-JOINT AND ARTICULATIONS OF THE CARPUS.

The **RADIO-CARPAL ARTICULATION**, or wrist-joint, is formed between the radius and triangular fibro-cartilage above, and the scaphoid, lunar and pyramidal bones below. The superior surface is concave both transversely and from before backwards; the inferior surface is correspondingly convex, and is prolonged farther down upon the carpal bones behind than in front. The articular surface of the radius is subdivided into two parts by a linear elevation; an outer, triangular, for the scaphoid, and an inner, quadrilateral, which, together with the triangular fibro-cartilage, corresponds to the lunar bone. The small articular surface of the pyramidal is in most cases in contact with a portion of the capsule of the joint. The latter is rather loose, and is divided into two lateral, anterior and posterior ligaments.

The **internal lateral ligament** is a rounded cord passing downwards from the styloid process of the ulna to the pyramidal bone, and by its anterior fibres to the pisiform bone.

The **external lateral ligament** extends from the styloid process of the radius to a depression on the scaphoid bone between the radial articular surface and the tuberosity.

The **anterior ligament**, broad and membranous, consists partly of fibres which have a nearly transverse direction, partly of others which diverge as they descend from the anterior border of the radius to the scaphoid, lunar, and pyramidal bones; some of them are continued to the os magnum. On the inner side a strong bundle springs from the root of the styloid process of the ulna and passes to the pyramidal and lunar bones.

<sup>1</sup> Braune and Kyrklund, Arch. f. Anat., 1879.

The **posterior ligament** extends obliquely downwards and inwards, from the extremity of the radius to the posterior surface of the first row of the carpal bones, especially the pyramidal bone ; its fibres are prolonged some distance on the surface of the carpal bones.

The **synovial membrane** is simple and lines the ligaments between the articular surfaces.

**THE CARPAL ARTICULATIONS.**—The bones of the carpus, the pisiform excepted, are so arranged in two rows, that while only slight movement can take place between the members of each row, a considerable amount of movement is possible between the two rows. The surface presented by the first row to the second is concave both transversely and from before backwards in the greater part of its extent, but in its outer part it is formed by the convex part of the scaphoid bone. The opposing surface of the second row is concavo-convex from without inwards, the concavity

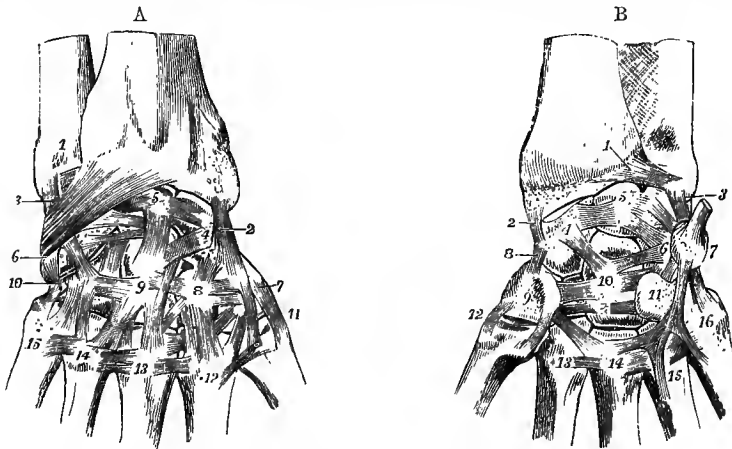


Fig. 200, A.—DORSAL VIEW OF THE LIGAMENTS OF THE WRIST-JOINT, AND OF THE CARPAL AND CARPO-METACARPAL ARTICULATIONS. (Allen Thomson, after Arnold.)  $\frac{1}{2}$

1, lower part of the ulna ; 2, external lateral ligament of the wrist-joint ; 3, internal ; near it descending obliquely to 6, from the radius, the dorsal radio-carpal ligament ; 4 to 5, dorsal ligaments of the first row ; 4, is on the scaphoid, 5, on the lunar bone ; 6, pyramidal bone ; 7, trapezium ; 8, trapezoid ; 9, os magnum ; 10, unciform ; 11 to 15, metacarpal bones ; 7 to 8, 8 to 9, and 9 to 10, dorsal ligaments of the second row of carpal bones ; 4 to 8, 4 to 9, 5 to 9, and others, dorsal ligaments between the first and second row ; 8 to 12, 9 to 13, and others, dorsal ligaments from the second row to the metacarpal bones ; between the metacarpal bones, from 12 to 15, the dorsal intermetacarpal ligaments.

Fig. 200, B.—PALMAR VIEW OF THE LIGAMENTS OF THE WRIST-JOINT, AND OF THE CARPAL AND CARPO-METACARPAL ARTICULATIONS. (Allen Thomson.)  $\frac{1}{2}$

The anterior radio-carpal ligament has been removed : 1, anterior ligament of the lower radio-ulnar articulation ; 2, external, and 3, internal lateral ligament of the wrist-joint ; 4, scaphoid bone ; 5, lunar ; 6, pyramidal ; 7, pisiform, with the tendon of flexor carpi ulnaris attached ; 4 to 5, and 5 to 6, palmar ligaments of the first row ; 8, external lateral ligament between the first and second rows of carpal bones ; 9, trapezium (the trapezoid is not numbered) ; 10, os magnum ; 11, hook of the unciform bone ; 9 to 10, 10 to 11, and others, palmar ligaments of the second row ; 4 to 10, and 6 to 10, some of the palmar ligaments uniting the two rows, converging on the os magnum ; 7 to 11, pisi-uncinate ligament ; 7 to 16, pisi-metacarpal ligament ; 12, external ligament of the first carpo-metacarpal articulation ; 13, 14, 15, 16, the proximal ends of the second to the fifth metacarpal bones, on which the palmar transverse ligaments are shown.

being formed by the trapezium and trapezoid, the convexity by the os magnum and unciform bone.

In the **transverse carpal articulation** the two rows of carpal bones are united by dorsal, palmar, and lateral ligaments. The *lateral ligaments* are placed

one at the radial, the other at the ulnar border of the carpus; the former connects the scaphoid bone with the trapezium, the latter the pyramidal with the unciform. The *dorsal ligaments* consist of fibres passing in various directions; the *palmar ligaments* are chiefly composed of fibres converging towards the os magnum.

The **bones of the first row**, the pisiform bone excepted, are united by interosseous and by dorsal and palmar ligaments. The *interosseous ligaments*, placed on the sides of the lunar bone on a level with its superior surface, connect it with the scaphoid and pyramidal bones, thus completing the inferior wall of the radio-carpal joint. The *dorsal* and *palmar ligaments* extend transversely on the dorsal and palmar surfaces from the scaphoid bone to the lunar, and from the lunar to the pyramidal.

The **bones of the second row** are connected by similar means. The *dorsal* and *palmar ligaments* pass transversely between the contiguous bones. The *inter-*

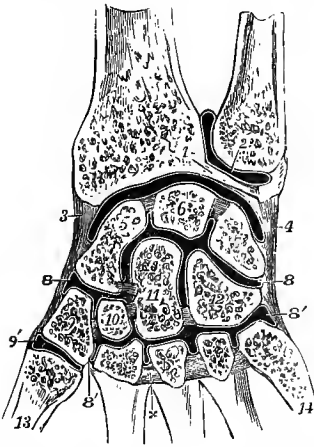


Fig. 201.—CORONAL SECTION OF THE INFERIOR RADIO-ULNAR, RADIO-CARPAL, INTERCARPAL, AND CARPO-METACARPAL ARTICULATIONS. (Allen Thomson.)  $\frac{1}{2}$

1, triangular fibro-cartilage; 2, placed on the ulna, points to the synovial cavity of the inferior radio-ulnar articulation; 3, external lateral, and 4, internal lateral ligament, and between them the synovial cavity of the wrist; 5, scaphoid bone; 6, lunar; 7, pyramidal; 8, 8, upper portion, and 8', 8', lower portion of the general synovial cavity of the intercarpal and carpo-metacarpal articulations; between 5 and 6, and 6 and 7, the interosseous ligaments are seen separating the carpal articular cavity from the wrist-joint; between the four carpal bones of the lower row, and between the magnum and scaphoid, the interosseous ligaments are also shown; the upper division of the synovial cavity communicates with the lower between 10 and 11, and between 11 and 12; x, marks one of the three interosseous metacarpal ligaments; 9', separate synovial cavity of the first carpo-metacarpal articulation; 13, first, and 14, fifth metacarpal bone.

NOTE.—It is to be observed that in this figure, and in others of a like kind which represent the joint-cavities, the white or black lines indicating the synovial membranes are, for the sake of clearness, generally represented as passing over the surfaces of the articular cartilages, although this is not the case in nature. These lines therefore must be held to represent merely the whole continuity of the articular or, as they are often called, the synovial surfaces.

*osseous ligaments* are generally three (but sometimes only two) in number, a strong ligament being placed between the os magnum and unciform bone, another between the trapezoid and trapezium, and a slender ligament between the os magnum and trapezoid. A small interosseous ligament is also found sometimes between the os magnum and the scaphoid (fig. 201).

The **synovial cavity** of the carpal articulations is extensive and complicated. Passing between the two rows of carpal bones, it sends upwards two processes between the three bones of the first row, and downwards three between the four bones of the second row. It is farther continued below into the inner four carpo-metacarpal and three intermetacarpal articulations. In some rare cases there is continuity with the synovial cavity of the wrist-joint, by deficiency of one of the interosseous ligaments between the upper carpal bones.

The **pisiform bone** is articulated with the pyramidal bone by a thin fibrous capsule, lined by synovial membrane. Inferiorly, two strong bands descend from it, the *pisi-uncinate ligament* to the hook of the unciform bone, and the *pisi-metacarpal ligament* to the base of the fifth metacarpal, and sometimes also to other metacarpal bones; superiorly it receives the tendon of the flexor carpi ulnaris muscle. The synovial cavity is usually distinct, but it sometimes communicates with that of the radio-carpal articulation.

The **anterior annular ligament** of the wrist is a strong and thick band,



which extends from the prominences made by the trapezium and scaphoid bone on the radial side of the carpus, directly across to the pisiform bone and unciform process, and converts the transverse arch of the carpus into a ring through which the flexor tendons of the digits pass into the hand.

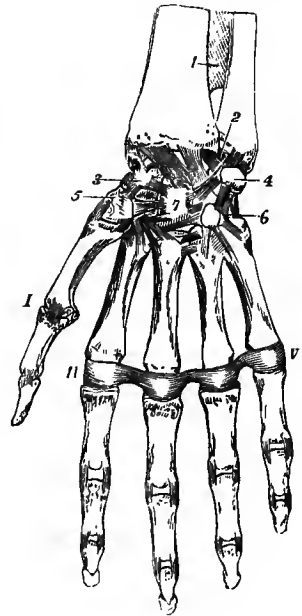
The **posterior annular ligament**, placed at the back of the wrist, is only a thickened part of the aponeurosis of the forearm. It extends from the lower part of the radius, at its outer border, to the inner part of the pyramidal and pisiform bones, and serves to bind down the extensor tendons.

#### THE CARPO-METACARPAL AND INTERMETACARPAL ARTICULATIONS.

The **four inner metacarpal bones** are bound together at their distal extremities by fibres passing between the palmar ligaments of the metacarpo-phalangeal articulations, and constituting the *transverse metacarpal ligament*. At their proximal

Fig. 202.—GENERAL VIEW OF THE ARTICULATIONS OF THE WRIST AND HAND FROM BEFORE.  $\frac{1}{2}$

1, lower part of the interosseous membrane; 2, and from that point across the lower end of the radius, the anterior radio-carpal ligament; 3, scaphoid bone; 4, pisiform; 5, trapezium; 6, unciform; 7, os magnum, with most of the deeper ligaments uniting these bones; I, first metacarpo-phalangeal articulation with its external lateral ligament; II to V, transverse metacarpal ligament; in the several interphalangeal articulations of the fingers the lateral ligaments are shown; in the thumb the external only is visible.



extremities they are united to one another and to the carpal bones in articulations, the common synovial lining of which is derived from that of the intercarpal joint. In these articulations the four metacarpal bones are bound together by three *dorsal*, and three *palmar*, and by strong *interosseous ligaments*. The second, third and fourth metacarpal bones are united to the carpus by *dorsal ligaments*, of which each bone receives two, viz., the second from the trapezium and trapezoid, the third from the trapezoid and os magnum, and the fourth from the os magnum and unciform, and by *palmar ligaments*, one to each bone, but which are not so well defined and less constant. The fifth metacarpal bone is united to the unciform bone by a thin capsule which surrounds the articulation except on the outer side. There is likewise an *interosseous* band in one part of the carpo-metacarpal articulation, connecting the lower and contiguous angles of the os magnum and unciform to the adjacent angle of the third metacarpal bone. This ligament sometimes separates the cavity between the unciform and two inner metacarpal bones from the rest of the joint.

The **first metacarpal bone** is articulated with the trapezium by a capsular investment, which is thickened behind and on the outer side, and is lined by a distinct synovial membrane.

## THE METACARPO-PHALANGEAL AND INTERPHALANGEAL ARTICULATIONS.

The rounded head of each metacarpal bone is received into the slight hollow in the base of the first phalanx, and the bones are maintained in position by two lateral ligaments and an anterior ligament.

The **lateral ligaments** are strong bands springing from the tubercle and depression on each side of the head of the metacarpal bone, and passing downwards and forwards to the contiguous margin of the phalanx. The anterior fibres are directed almost horizontally forwards and join the palmar ligament of the articulation.

The **anterior** or **palmar ligament**, or rather **fibrous plate**, occupies the interval between the lateral ligaments on the palmar aspect of each joint; it is a

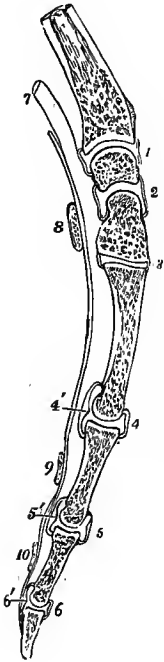


Fig. 203.—SAGITTAL SECTION THROUGH THE LOWER PART OF THE RADIUS, LUNAR BONE, OS MAGNUM, METACARPAL BONE AND PHALANGES OF THE MIDDLE FINGER, TO SHOW THE SHAPE OF THE ARTICULAR SURFACES AND THE SYNOVIAL CAVITIES BETWEEN THESE SEVERAL BONES. (Allen Thomson.)  $\frac{1}{3}$

1, synovial cavity of the wrist-joint; 2, intercarpal cavity; 3, carpometacarpal cavity; 4, metacarpophalangeal cavity; 5 and 6, interphalangeal cavities; 4', 5', and 6', the palmar fibrous plates which are attached to the bases of the several phalanges; 7, indicates the place of the tendons of the long flexor muscles; 8, section of the anterior annular ligament; 9, and 10, transverse retinacula, or vaginal ligaments of the flexor tendons on the first and second phalanges.

thick and dense fibrous structure, which is firmly united to the phalanx but loosely adherent to the metacarpal bone. It is continuous at each side with the lateral ligament, so that the three form one undivided structure which covers the joint, except on the dorsal aspect. Its palmar surface is grooved for the flexor tendon, the sheath of which is connected to it at each side; the other surface, looking to the interior of the joint, is lined by synovial membrane, and supports the head of the metacarpal bone. In the joint of the thumb there are two sesamoid bones, one situated at each side, which are connected with its ligaments.

A **synovial membrane** is present in each joint, and invests the surface of the ligaments which connect the bones.

The **interphalangeal articulations** differ from the foregoing only in the shape of the articular surfaces (see p. 105).

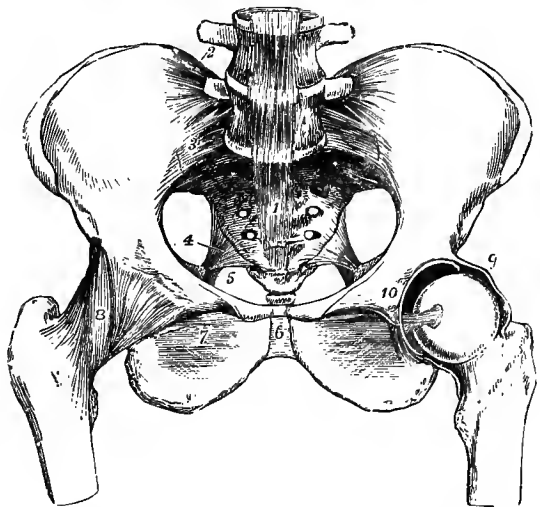
**Movements of the wrist and fingers.**—The movements taking place at the wrist have their seat partly in the radio-carpal, partly in the transverse carpal articulation. Flexion is the freest movement, but a considerable degree of over-extension is also permitted. The hand can also be moved laterally, and to a greater extent inwards (adduction or ulnar flexion) than outwards (abduction or radial flexion). According to Henke and Langer both radio-carpal and transverse carpal articulations are essentially hinge-joints, the axes of which are oblique in opposite directions, that of the first joint extending from the styloid process of the radius to the pisiform bone, and that of the transverse carpal joint from the tuberosity of the scaphoid to the dorsum of the pyramidal bone. Flexion and extension are accordingly the result of simultaneous movements in the two joints in the same direction. While abduction is produced by flexion in the radio-carpal joint combined with extension in the transverse carpal joint, and adduction by extension in the radio-carpal joint with flexion in the transverse carpal joint. Side to side movement is permitted only to a very slight extent in the radio-carpal joint. (Henke, "Handbuch der Anatomie und Mechanik der Gelenke," 1863; Langer, "Lehrbuch der Anatomie.")

The kind of movement which is allowed between the several carpal and metacarpal bones is best illustrated by placing the hand in such a position that the weight of the body is rested upon the open palm. The metacarpal range, which naturally is concave towards the palm, is flattened; and the interosseous and palmar metacarpal ligaments are thus tightened, while a slight separation of the opposed surfaces of the bones takes place; so also the palmar carpo-metacarpal ligaments are tightened, and both palmar and interosseous ligaments of the second range of carpal bones. The convex part of the os magnum and unciform bone, fitted in these circumstances into the concavity of the first range, is a little wider than the part usually in contact with it; and thus, while the bones of the second range are separated from the palmar side, those of the first range are pressed still more apart from the distal aspect. The whole arrangement secures elasticity. The fourth and especially the fifth metacarpal bones are not so tightly bound to the carpus as the second and third, and can therefore be moved to some extent forwards (opposition), thus making the hand narrower and deepening the hollow of the palm: these bones move in this way very distinctly in shutting the hand, so that the back is then rendered more convex, and the tips of the fingers are brought more closely together. At the interphalangeal articulations the only movements allowed are flexion and extension, while over-extension is prevented by the ligamentous structures in front of the joints. At the metacarpo-phalangeal articulations of the fingers abduction and adduction are also allowed, chiefly in the extended position. In the articulation of the metacarpal bone of the thumb with the trapezium all kinds of angular movement are allowed, but owing to the shape of the articular surfaces the movement of flexion is accompanied by a certain amount of rotation of the metacarpal bone on its long axis, by which the thumb is turned towards the fingers, thus giving rise to the so-called opposition. The metacarpo-phalangeal articulation of the thumb allows of only a limited amount of flexion and extension.

### III.—THE ARTICULATIONS OF THE PELVIS.

ARTICULATION OF THE PELVIS WITH THE LAST LUMBAR VERTEBRA.—The fifth lumbar is united to the first sacral vertebra by anterior and posterior ligaments of the bodies, capsular ligaments of the articular processes, ligamenta subflava of

Fig. 204.—ARTICULATIONS OF THE PELVIS AND HIP-JOINT, SEEN FROM BEFORE. THE ANTERIOR HALF OF THE CAPSULAR LIGAMENT OF THE LEFT HIP-JOINT HAS BEEN REMOVED, AND THE FEMUR ROTATED OUTWARDS. (Allen Thomson.)  $\frac{1}{4}$



1, 1, anterior common ligament of the vertebræ passing down to the front of the sacrum; 2, ilio-lumbar ligament; 3, anterior sacro-iliac ligament; 4, placed in the great sacro-sciatic foramen, points to the small sacro-sciatic ligament; 5, a portion of the great sacro-sciatic ligament; 6, anterior ligament of the symphysis pubis; 7, obturator membrane; 8, capsular ligament of hip-joint; the figure is placed on its ilio-femoral band; 9, upper part of the divided capsular ligament of the left hip-joint near the place of its attachment to the border of the acetabulum; 10, placed on the os pubis of the left side above the transverse ligament of the acetabular notch. The head of the femur is withdrawn partially from the socket, so as to show the interarticular ligament stretched from the transverse ligament.

the arches, interspinous and supraspinous ligaments, and by an intervertebral disc, all of which are similar to those between the vertebræ above. It is also attached to the pelvis by two other ligaments, as follows.

The **lateral lumbo-sacral ligament** is a variable fasciculus, passing from the

lower border of the transverse process of the last lumbar vertebra obliquely downwards to the lateral part of the base of the sacrum; its fibres diverge as they descend, and some of them join the anterior sacro-iliac ligament.

The **ilio-lumbar ligament** is a strong band passing outwards and somewhat backwards from the summit of the transverse process of the last lumbar vertebra to the iliac crest of the hip-bone; it is inserted into the latter above the back part of the iliac fossa, where its fibres expand somewhat, so as to give it a triangular form.

The lateral lumbo-sacral ligament represents an anterior superior costo-transverse ligament: the ilio-lumbar ligament is a thickening of the anterior layer of the fascia lumborum.

**ARTICULATIONS OF THE SACRUM AND COCCYX, AND OF THE PIECES OF THE COCCYX.**—The sacrum and the coccyx are united by an *intervertebral disc*; by an *anterior ligament*, a thin layer of fibres forming a continuation of the anterior

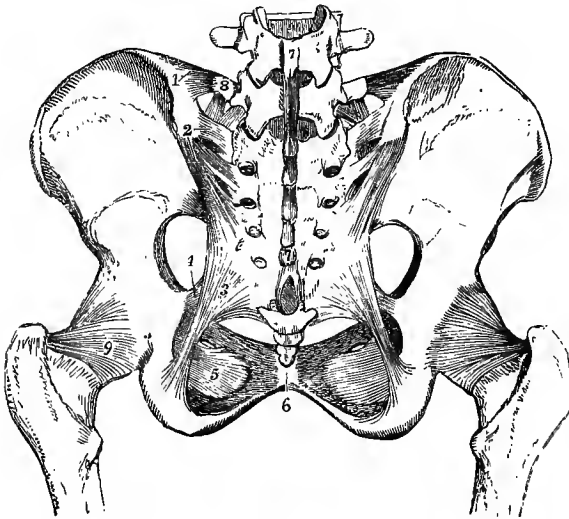


Fig. 205.—LIGAMENTS OF THE PELVIS AND HIP-JOINT SEEN FROM BEHIND, FROM A FEMALE SUBJECT. (Allen Thomson.) †

1, ilio-lumbar ligament; 2, posterior sacro-iliac ligaments, the short and the oblique; 3, great sacro-sciatic ligament; 4, small sacro-sciatic ligament; 5, obturator membrane; 6, posterior ligament of symphysis pubis; 7, 7, continuation of supraspinous ligament from the lower lumbar vertebrae over the sacral spines; 8, transverse process of last lumbar vertebra, from which the lateral lumbo-sacral ligament is seen descending; 9, capsular ligament of the hip-joint; the figure is placed on the ischio-capsular band.

common ligament of the vertebrae; by a *posterior ligament*, more strongly

developed, which descends from the margin of the inferior orifice of the sacral canal to the back of the coccyx; by *interarticular ligaments* between the cornua of the two bones; and by *lateral ligaments*, passing on each side from the lower lateral angle of the sacrum to the transverse process of the first piece of the coccyx. The pieces of the coccyx, so long as they remain separate, are connected by fibro-cartilaginous discs and prolongations of the above-mentioned anterior and posterior ligaments.

A distinct cavity is stated by Cruveilhier to be present in the centre of the disc between the sacrum and coccyx in those cases in which the coccyx is freely moveable. This is in conformity with the observations of Luschka on the other intervertebral discs. After middle life, the union between the pieces of the coccyx is usually ossific; and the coccyx may then also become united to the sacrum. The union of the coccyx is less frequent in the female than in the male; and the mobility of the coccyx seems to increase during pregnancy.

From the tip of the coccyx a fibrous band passes to the integument, which is often, especially in the infant, marked by a depression (*foveola coccygea*) at this spot.

The **SACRO-ILIAIC ARTICULATION** is formed between the auricular surfaces of the sacrum and ilium, which are covered each with a layer of cartilage, that on the sacrum being the thicker, and closely applied together, but are not usually directly

united. In some cases, however, the two surfaces are connected in part of their extent by fine transverse fibres; while on the other hand, it not unfrequently happens, especially in advanced life, that the surfaces become rough and irregular, and are separated by small spaces containing glairy fluid. The bones are united by anterior and posterior sacro-iliac ligaments, and the articulation receives additional support from the great and small sacro-sciatic ligaments.

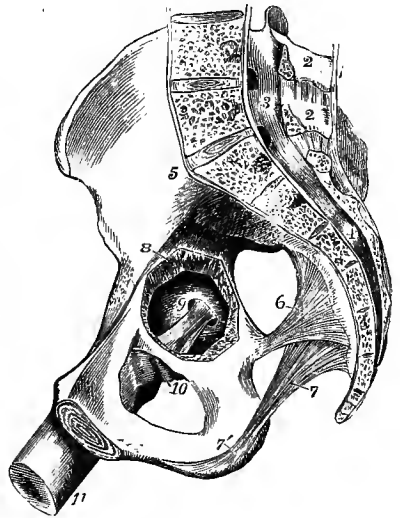
The **anterior sacro-iliac ligament** consists of thin irregular fibres passing between the sacrum and hip-bone on their iliac and pelvic surfaces.

The **posterior sacro-iliac ligament** consists of a large number of strong irregular bundles extending from the rough space above the auricular surface of the ilium, downwards and inwards to the depressions on the back of the lateral mass of the sacrum. A superficial band, passing nearly vertically downwards from the posterior superior iliac spine to the third and fourth pieces of the sacrum, is distinguished as the *long* or *oblique sacro-iliac ligament*.

THE SACRO-SCIATIC LIGAMENTS.—The **posterior** or **great sacro-sciatic ligament**, broad and triangular, assists in bounding the lower aperture of the pelvis.

Fig. 206.—RIGHT HALF OF A FEMALE PELVIS, SEEN FROM THE INNER SIDE. (Allen Thomson.) ?

1, supraspinous ligament descending to the sacrum from 2, 2, the lumbar spinous processes; 3, 4, lumbar and sacral spinal canal; 5, placed on the ilium above the anterior sacro-iliac ligament; 6, placed in the great sacro-sciatic foramen, points to the small sacro-sciatic ligament; 7, great sacro-sciatic ligament, with 7', its falciform process; 8, aperture where a portion of the wall of the cotyloid cavity has been removed, so as to give a view from the inside of the head of the femur; 9, interarticular ligament put upon the stretch, the femur being partially flexed and adducted; 10, inner part of the capsular ligament relaxed; 11, shaft of the femur.



Its base is attached to the posterior inferior iliac spine and to the side of the sacrum and coccyx; while its apex is fixed along the inner margin of the ischial tuberosity, where it expands somewhat, and sends forwards along the margin of the ischial ramus a *falciform process* the border of which is continuous with, and forms the inferior attachment of, the obturator fascia. Some of the superficial fibres of the ligament are continued over the tuberosity into the tendon of the long head of the biceps muscle.

The **anterior** or **small sacro-sciatic ligament**, much shorter and thinner than the preceding, in front of which it lies, is also triangular in form, and is attached by its base to the side of the sacrum and coccyx, where its fibres are united with those of the great ligament, and by its apex to the spine of the ischium. The deep surface of this ligament is blended with the coccygeus muscle.

The great sacro-sciatic ligament represents the proximal portion of the tendon of the long head of the biceps muscle, which has formed an attachment to the ischial tuberosity. The small sacro-sciatic ligament is formed by fibrous degeneration of the superficial part of the coccygeus muscle.

**Foramina.** Between the great sacro-sciatic ligament and the hip-bone is a large space subdivided by the small sacro-sciatic ligament. The part which lies above this ligament is named the *great sacro-sciatic foramen*. It transmits the

pyriformis muscle, the gluteal, sciatic, and pudic vessels and nerves, and the nerves to the obturator internus and quadratus femoris muscles. The part between the greater and lesser sacro-sciatic ligaments, much smaller and bounded in front by the smooth surface between the spine and tuberosity of the ischium, is the small *sacro-sciatic foramen*, through which pass the obturator internus muscle, the pudic vessels and nerve, and the nerve to the obturator internus.

The **PUBIC ARTICULATION**, or *symphysis pubis*, is the connection of the pubic bones in front, and is effected by an interpubic disc and ligaments. The *interpubic disc* consists of a layer of cartilage on each side, closely adherent to the bony surfaces, and an intermediate stratum of fibrous tissue and fibro-cartilage. The intermediate layer is thicker in front than behind, and generally contains a fissure towards the upper and back part, which sometimes extends through the whole depth of the articulation (fig. 207). The ligaments are named *anterior*, *posterior*, *superior*, and *inferior*. The *anterior pubic ligament* is of considerable thickness; it consists of deep fibres passing transversely between the bones at the front of the disc, and superficial, oblique, interlacing fibres derived mainly from the tendons of the obliquus externus and rectus muscles of the abdomen, as well as of the superficial adductors of the thigh. The *superior* and *posterior ligaments* consist of only a few fibres on the upper and back parts of the articulation. The *inferior* or *subpubic ligament*, thick and triangular, is attached to the inferior rami of the pubic bones, giving smoothness and roundness to the subpubic angle, and forming part of the outlet of the pelvis.

The fissure in the interpubic disc appears to be formed during life by the softening and absorption of the fibro-cartilage. It is not usually found before the seventh year, it increases in extent with advancing age, and is more constant and of larger size in the female than in the male. Its greater development in the female sex may be in part due to the pressure exerted upon the joints of the pelvis during parturition, but it is not a regular accompaniment or a direct consequence of pregnancy.

The **obturator membrane**, or *ligament*, is a fibrous septum attached to the border of the thyroid foramen, which it closes, except at the obturator groove, where a small oval canal is left for the obturator vessels and nerve. The membrane is fixed accurately to the bony margin at the outer side of the foramen, but to the posterior surface at the inner side. The obturator muscles are attached to its surfaces.

**Movements and mechanism.**—In ordinary circumstances there is very little movement allowed between the bones of the pelvis. In the erect posture the sacrum is inclined so much backwards that none of the advantage of the key-stone of an arch is obtained by the tapering of its form from base to apex. It is only by the sinuosities of its auricular surfaces that it directly presses on the hip-bones; and as the width of the bone rather diminishes towards the dorsal surface, the principal strain is borne by the posterior sacro-iliac ligaments, from which the sacrum is in great measure suspended (see fig. 207). As the base of the sacrum, in the upright posture, projects forwards much beyond the auricular surface (cf. fig. 14 and 18), this bone will necessarily have a disposition to rotate about the place of support under the influence of the pressure of the superposed column, the upper extremity tending to sink and the lower extremity to rise. This tendency is restrained by the sacro-sciatic ligaments, which tie the lower end of the sacrum to the ischium. The ilio-lumbar ligament acts similarly in supporting the base of the column, and it also serves to prevent the fifth lumbar vertebra from slipping forwards over the oblique base of the sacrum. The space which might be gained by the small amount of movement allowed between the bones of the pelvis in the ordinary state is increased during parturition in this way, that the fore part of the sacrum being pressed backwards, the wider part of the wedge formed by this bone is forced farther between the hip-bones so as to separate them to a greater degree, and thus to increase the capacity of the pelvis. It is thought also by some that during pregnancy a slight amount of separation may occur at the symphysis pubis from relaxation of the connecting parts.

## IV.—THE ARTICULATIONS OF THE LOWER LIMB.

## THE HIP-JOINT.

This is a ball and socket joint, in which the globular head of the femur is received into the acetabulum or cotyloid cavity of the hip-bone. The articular portion of the acetabulum is a horseshoe-shaped, cartilage-covered surface, broader above and behind than in front, and folded round the fossa acetabuli which, extending from the cotyloid notch to the bottom of the cavity, is occupied by adipose tissue covered with synovial membrane, the so-called synovial or Haversian gland. The articular surface of the femur presents a little behind and below its centre a pit in which the interarticular ligament is attached.

The **cotyloid ligament** forms a thick fibro-cartilaginous ring round the margin of the acetabulum, increasing the depth of its cavity, and bridging over

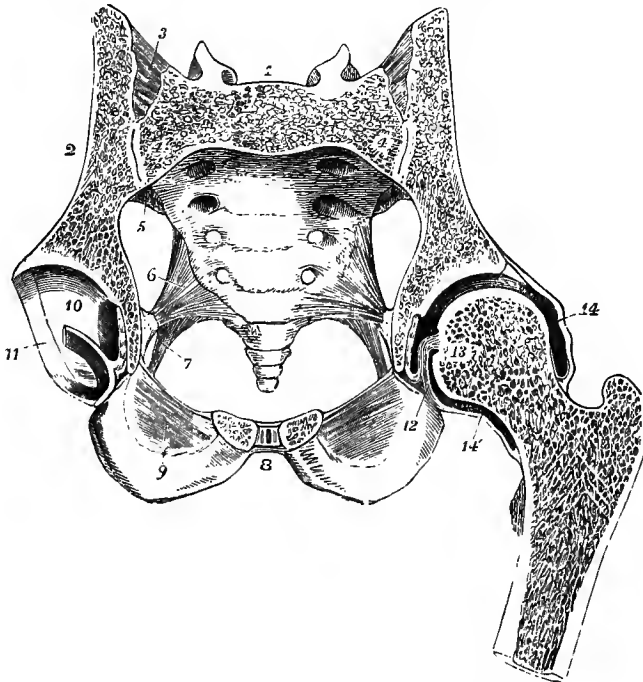


Fig. 207.—TRANSVERSE OBLIQUE SECTION OF THE PELVIS AND HIP-JOINT, CUTTING THE FIRST SACRAL VERTERRA AND THE SYMPHYSIS PUBIS IN THEIR MIDDLE, FROM A MALE SUBJECT OF ABOUT NINETEEN YEARS OF AGE. (Allen Thomson.)  $\frac{1}{2}$

1, first sacral vertebra; 2, ilium; 3, posterior sacro-iliac ligament; 4, cavity of the sacro-iliac articulation; 5, anterior sacro-iliac ligament; 6, small sacro-sciatic ligament; 7, great sacro-sciatic ligament; 8, placed in front of the symphysis pubis, in the cut surface of which the small median cavity, the adjacent cartilaginous plates, and the anterior and posterior ligamentous fibres are shown; 9, lower part of the obturator membrane; 10, cartilaginous surface of the cotyloid cavity, through the middle of the incision passes transversely, dividing the interarticular ligament and the fat in the fossa acetabuli; 11, cotyloid ligament; 12, interarticular ligament connected with the transverse part of the cotyloid ligament; 13, placed on the cut surface of the head of the left femur near the depression where the interarticular ligament is attached; 14, 14', upper and lower parts of the capsular ligament.

the deficiency in its border. Its external surface is in contact with the capsular ligament; the internal closely embraces the head of the femur, and both are covered by the synovial membrane. Its fibres do not run parallel to the circum-

ference of the cotyloid cavity, but pass obliquely from without inwards over its margin, one extremity being attached to the outer, the other to the inner surface.

At the cotyloid notch the fibres of the ligament are continued from side to side, so as to render the circumference complete, and deeper transverse fibres are super-added, from which circumstance, as well as from being stretched across from one margin of the notch to the other, this part is called the *transverse ligament*. Beneath it an interval is left for the admission of the articular vessels.

The **interarticular** or **round ligament** (*ligamentum teres*) is a variable fasciculus surrounded by synovial membrane, attached by one extremity, which is round, in the fossa in the head of the femur; by the other, which is broad and flat, to the transverse ligament and the margins of the cotyloid notch, the strongest fibres passing to the ischial border. It rests on the fat in the fossa acetabuli.

The **capsular ligament** surrounding the joint is attached above to the margin of the cotyloid cavity, and below to the neck of the femur. At its cotyloid attachment the capsule arises, above and behind, from the bony margin outside the attachment of the cotyloid ligament, having its inner surface in close contact with that ligament; in front it arises from the outer aspect of the cotyloid ligament near its base, and at the notch it is similarly attached to the transverse ligament. At its femoral attachment the capsule extends anteriorly to the intertrochanteric line, superiorly to the root of the great trochanter, posteriorly and inferiorly to the junction of the middle and external thirds of the neck. The fibres of which the capsule consists run in two directions, circularly and longitudinally. The circular fibres are most distinct at the lower and posterior part of the capsule, where they are collected into a band about half an inch in breadth, which embraces the neck of the femur; above and in front they spread out and become interwoven with the deeper layers of the strongly developed longitudinal fibres, by which they are thus concealed. The longitudinal fibres on the posterior aspect of the joint are almost absent, being represented only by a few scattered fibres which support the synovial membrane, and attach the circular fibres to the neck of the femur. In other parts of the capsule the longitudinal fibres form thick bands, certain of which from their greater size and strength are distinguished as accessory ligaments. The most important of these is formed on the antero-superior aspect of the capsule and is known as the *ilio-femoral ligament* (fig. 204, 8). This springs above from the lower part of the anterior inferior iliac spine, and behind this from an impression on the bone immediately above the margin of the acetabulum; the fibres diverge and form two strong bands, the inner of which passes almost vertically to the lower part of the anterior intertrochanteric line, the outer to the upper part of the same line and the adjacent part of the neck of the femur. Between the two bands is a thinner part of the capsule; but it not unfrequently happens that the division is not marked, so that the ligament forms one flat triangular band, attached by its base to the whole length of the anterior intertrochanteric line.<sup>1</sup> At the lower and hinder part of the joint, a broad and strong band of fibres, the *ischio-capsular ligament*, passes from the furrow on the ischium below the acetabulum to end in the circular fibres. In front and below may be also found a number of scattered fibrous bundles, which converge to the capsule from the ilio-pectineal eminence, from the obturator crest, and from the obturator membrane, constituting the *pubo-femoral ligament*. Besides these the capsule receives above other strengthening bands from the tendon of the posterior head of the rectus femoris, and from the *gluteus minimus*.

From the inside of the capsule the innermost fibres are reflected upwards from

<sup>1</sup> The outer or upper of these bands is sometimes described separately as the *ilio-trochanteric ligament*; and the whole structure is frequently designated by surgeons the Y ligament of Bigelow.



their insertion upon the neck of the femur to the articular cartilage, forming a surface partly level and partly raised into longitudinal folds called *retinacula*.

The **synovial membrane** of the joint is reflected from the neck of the femur to the inner surface of the capsule, thence to the inner surface of the cotyloid ligament and to the pad of fat in the bottom of the acetabulum, from which it is farther prolonged as a tubular investment upon the interarticular ligament. It sometimes communicates, through an opening in the anterior wall of the capsule between the ilio-femoral and pubo-femoral ligaments, with a synovial bursa placed beneath the tendon of the ilio-psoas muscle.

**Movements.**—The movements allowed at the hip-joint are flexion, extension, abduction, adduction, circumduction, and rotation. Extension is limited by the anterior fibres of the capsular ligament and the inner band of the ilio-femoral ligament: flexion, when the knee is bent, is limited only by the contact of the thigh with the abdomen, but when the knee is extended the movement is arrested earlier by the hamstring muscles. Abduction is controlled by the pubo-femoral band, by the lower part of the capsule, and by the upper border of the neck of the femur coming into contact with the margin of the socket formed by the cotyloid ligament; adduction by the outer band of the ilio-femoral ligament, and by the upper part of the capsule. Rotation outwards is checked mainly by the outer part of the ilio-femoral ligament, inwards by the ischio-capsular ligament, the hinder part of the capsule, and the muscles at the back of the joint. The whole extent of the movement of rotation is less than the sixth of a circle. The interarticular ligament is put upon the stretch when the hip is partly flexed, and the thigh then adducted (fig. 206) or rotated out, but it is in many cases so slender that it can have very little influence upon the mechanism of the joint. The ilio-femoral ligament is so strong that it is but rarely broken in dislocations of the hip, and advantage is taken of this circumstance in attempting to reduce the displacement by manipulation. During the swinging antero-posterior movements of the femur, as in walking or running, the head of the bone revolves on a horizontal axis without any tendency to escape from the socket, but in the lateral movements and in rotation the articular surface of the head projects beyond the margin of the acetabulum on the opposite side to that towards which the movement is taking place. In the erect attitude a vertical line passing through the centre of gravity of the trunk falls behind the centres of rotation in the hip-joints; the pelvis therefore tends to fall backwards by over-extension of the hip-joints, but as this is prevented by the tightening of the capsule in front, the trunk is supported upon the thigh-bones in great measure without muscular effort by virtue of this mechanism of the joint.

#### THE KNEE-JOINT.

The articular surfaces of this complicated joint are the condyles of the femur and the condylar surfaces of the tibia, with interposed fibro-cartilages, the articulating surface of the patella, and the patellar surface of the femur. The action is mainly that of a hinge-joint. The joint is strengthened superficially by fibrous coverings derived from the surrounding tendons and aponeuroses. The ligamentous structures of the joint are the following.

The **internal lateral ligament**, long and flat, connects the internal tuberosity of the femur with the inner part of the shaft of the tibia, on which it descends to beyond the level of the tubercle: some of the deeper fibres are also inserted into the internal fibro-cartilage and the margin of the inner tuberosity. The tendon of the semimembranosus muscle passes to its insertion beneath the posterior border of the ligament, to which it sends a few fibres; and below the inner tuberosity the lower internal articular vessels are placed between the ligament and the bone.

The **external lateral ligament** is a rounded cord, which extends from the external tuberosity of the femur to the head of the fibula. Its internal surface lies upon the tendon of the popliteus muscle and the inferior external articular vessels. The tendon of the biceps flexor cruris muscle is divided into two by this ligament, and between the ligament and the tendon there is frequently a synovial bursa. Farther back is another less constant band, the *short external lateral ligament*, which springs from the external condyle of the femur in connection with the outer head of the gastrocnemius, and terminates below on the styloid process of the fibula.

The internal lateral ligament is derived from the tendon of the adductor magnus muscle; the external represents the detached femoral origin of the peroneus longus (Sutton).

The **posterior ligament** is broad and membranous, and passes from the upper edge of the intercondylar fossa of the femur to the posterior margin of the head of the tibia. It is in great part formed by an expansion from the tendon of the semi-membranosus, which is directed upwards and outwards towards the external condyle of the femur and the outer head of the gastrocnemius muscle.

The **ligamentum patellæ**, or **infrapatellar tendon** of the quadriceps extensor cruris muscle, is a strong flat band, attached above to the apex and lower border of

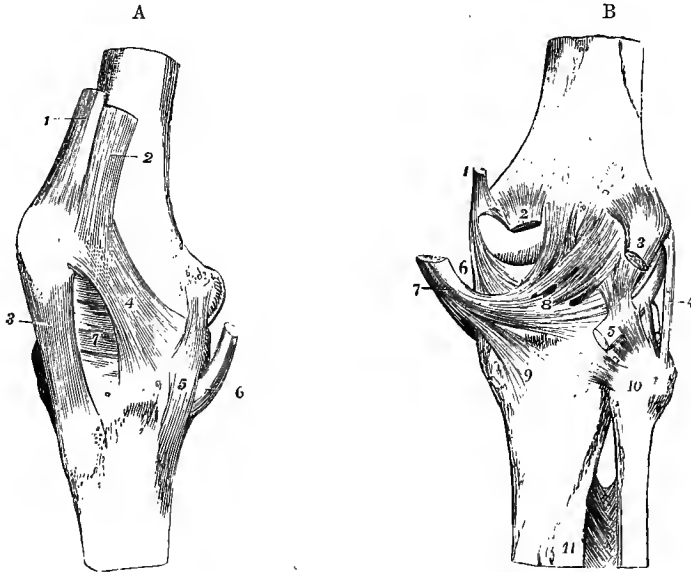


Fig. 208, A.—RIGHT KNEE-JOINT, FROM THE INNER SIDE AND ANTERIORLY. (Allen Thomson.)

1, tendon of the rectus muscle near its insertion into the patella; 2, insertion of the vastus internus into the rectus tendon and side of the patella; 3, ligamentum patellæ descending to the tubercle of the tibia; 4, capsular fibres forming a lateral ligament of the patella prolonged in part from the insertion of the vastus internus downwards towards the inner tuberosity of the tibia; 5, internal lateral ligament; 6, tendon of the semimembranosus muscle. (After Arnold.)

Fig. 208, B.—RIGHT KNEE-JOINT FROM BEHIND. (Allen Thomson.)

1, insertion of the tendon of the adductor magnus; 2, origin of the inner head of the gastrocnemius muscle; 3, outer head of the same; 4, external lateral ligament; 5, tendon of the popliteus muscle; 6, part of internal lateral ligament; 7, tendon of the semimembranosus muscle; 8, posterior ligament, spreading outwards from the tendon; 9, expansion of the popliteal fascia downwards from the same, represented as cut short; 10, on the head of the fibula, marks the posterior superior tibio-fibular ligament; 11, upper part of the interosseous membrane with the foramen at the upper end for the anterior tibial vessels.

the patella, and below to the tubercle of the tibia. Between the tibia and the ligament, near its insertion, is placed a synovial bursa.

The **crucial ligaments**, placed in the centre of the joint, pass from the sides of the intercondylar fossa to the spaces in front of and behind the spine of the tibia. They decussate somewhat like the lines of the letter X. The *anterior* or *external ligament* is fixed by its lower extremity to the inner part of the depression before the spine of the tibia, and by its upper extremity it is inserted into the inner and hinder part of the external condyle of the femur; hence its direction is upwards, back-

wards, and outwards. The *posterior* or *internal ligament*, stronger but shorter than the anterior, is attached below to the floor of the popliteal notch of the tibia, and above to the lower part of the outer surface of the internal condyle, as well as to the adjacent fore part of the intercondylar fossa of the femur; its fibres are directed upwards and a little forwards and inwards.

The **semilunar fibro-cartilages** are two crescent-shaped plates, placed on the articulating surfaces of the head of the tibia, and interposed between these and the condyles of the femur. They have each a smooth free surface above and below, and a convex border, which is thick, while the concave border is thinned to a fine edge; and the part of the articular surface of the tibia within the concave

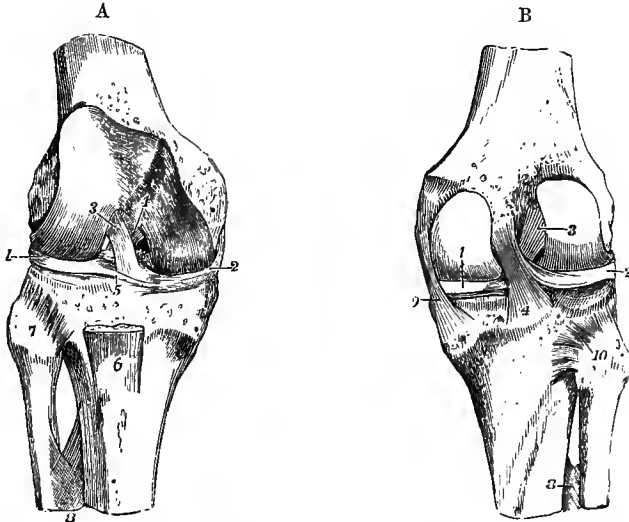


Fig. 209, A.—THE KNEE-JOINT, OPENED FROM BEFORE, TO SHOW THE CRUCIAL LIGAMENTS AND SEMILUNAR FIBRO-CARTILAGES. (Allen Thomson.)  $\frac{1}{2}$

1, external, 2, internal semilunar fibro-cartilage; 3, on the outer condyle of the femur, points to the anterior crucial ligament; 4, placed on the line separating the patellar surface from the inner condylar surface of the femur, points to the posterior crucial ligament; 5, transverse ligament of the semilunar fibro-cartilages; 6, part of the ligamentum patellæ; 7, on the head of the fibula, points to the anterior superior tibio-fibular ligament; 8, upper part of the interosseous membrane, showing the perforation for the anterior tibial vessels.

Fig. 209, B.—THE KNEE-JOINT, OPENED FROM BEHIND, SO AS TO EXPOSE THE CRUCIAL LIGAMENTS AND SEMILUNAR FIBRO-CARTILAGES. (Allen Thomson.)  $\frac{1}{2}$

1, internal, 2, external semilunar fibro-cartilage; 3, anterior, 4, posterior crucia. ligament; farther up is seen the accessory band from the external semilunar fibro-cartilage; 8, upper part of the interosseous membrane; 9, internal lateral ligament; 10, placed on the head of the fibula and the external fibro-cartilage (2) is seen the surface of the tibia upon which the semilunar cartilage descends in flexion, and where a communication sometimes takes place between the synovial cavities of the knee-joint and of the tibio-fibular articulation.

border of each cartilage is left uncovered. At their extremities they are fibrous, and are firmly fixed to the head of the tibia, while by their circumference they are connected with the fibrous capsule of the joint.

The **internal semilunar fibro-cartilage** forms about a semicircle; its anterior extremity is small and pointed, and is inserted into an impression at the fore and inner part of the hollow before the spine of the tibia; its posterior end is attached

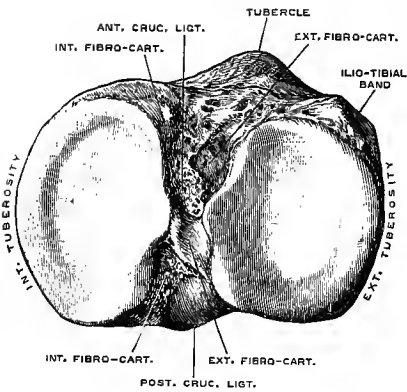


Fig. 210.—UPPER EXTREMITY OF THE RIGHT TIBIA, FROM ABOVE. (Drawn by T. W. P. Lawrence.)  $\frac{3}{4}$

In front of the outer tubercle of the spine, and immediately external to the anterior attachment of the external semilunar fibro-cartilage, is seen the small facet which comes into contact with the outer condyle of the femur in extension of the knee-joint.

to the inner edge of the hollow behind the spine, in front of the posterior crucial ligament.

The **external semilunar fibro-cartilage** forms nearly a complete circle; its two extremities are fixed, one in front of, the other between the points of the spine of the tibia, and are so close at their in-

sertion that they may be said to be interposed between the attachments of the internal semilunar plate. Its external border is in contact behind with the tendon of

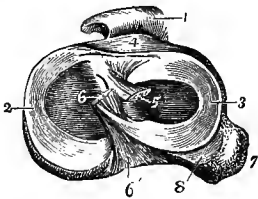


Fig. 211.—VIEW OF THE SEMILUNAR FIBRO-CARTILAGES OF THE RIGHT KNEE-JOINT, FROM ABOVE, WITH THE CRUCIAL LIGAMENTS DIVIDED, AND THE LIGAMENTUM PATELLE TURNED FORWARDS. (Allen Thomson.)  $\frac{3}{4}$

1, ligamentum patellæ; 2, inner, 3, outer fibro-cartilage; 4, placed on the tibia in front of the transverse ligament; 5, cut end of the anterior crucial ligament; 6, cut end of the posterior crucial ligament, from which a band is seen descending to the outer fibro-cartilage; 6', tibial attachment of the posterior crucial ligament; 7, head of the fibula; 8, cartilage-covered surface of the tibia, which extends for some way

downwards towards the tibio-fibular articulation.

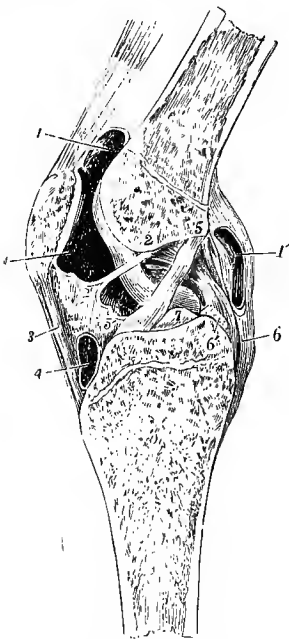


Fig. 212.—SAGITTAL SECTION OF THE LEFT KNEE-JOINT, SEEN FROM THE OUTER OR LEFT SIDE. (Allen Thomson.)  $\frac{3}{4}$

The section is made somewhat obliquely a little to the outside of the middle, so as to preserve entire the crucial ligaments with their attachments: it is from a young subject of eighteen or nineteen years. 1, 1, the upper portion of the synovial cavity extending upwards between the extensor tendon and the femur; 1', an aperture made into the posterior portion of the synovial cavity; 2, 2', mucons ligament; 3, ligamentum patellæ; 2', 3, infrapatellar synovial fatty cushion; 4, bursa above the insertion of the ligamentum patellæ into the tubercle of the tibia; 5, 5', anterior crucial ligament; 5', points also to the internal semilunar fibro-cartilage within the joint; 6, lower part of the posterior crucial ligament, the upper part of which is towards 2; 6', the accessory band joining the external semilunar fibro-cartilage, which is cut short; 7, spine of the tibia.

the popliteus muscle, and is therefore separated by this from the fibrous capsule. From the posterior extremity of this fibro-cartilage a ligamentous band ascends, to be attached to the inner condyle of the femur in connection, either in front or behind, with the posterior crucial ligament.

**Transverse ligament.**—Towards the front of the joint the convex borders of the semilunar fibro-cartilages are connected by a slight transverse band which receives this name. Its thickness varies much in different bodies, and it is sometimes wanting.

**Capsular membrane.**—Under this name is described the fibrous membrane which invests the joint in the intervals between the stronger bands which have been named ligaments. It is incomplete, not extending underneath the tendon of the extensor muscle. Between the sides of the patella and the femur it consists of fibres connected with the insertions of the vasti muscles and with the fascia lata, and thus forms the structures which have been called *lateral patellar ligaments*. Posteriorly it is thin, covering the condyles of the femur beneath the gastrocnemius muscle, and it frequently presents an aperture beneath the inner head of that muscle, through which the bursa under the semimembranosus tendon is put into communication with the joint-cavity.

The **synovial membrane** is the largest in the body. Traced downwards from the femur on either side of the joint, it may be followed along the capsule to the

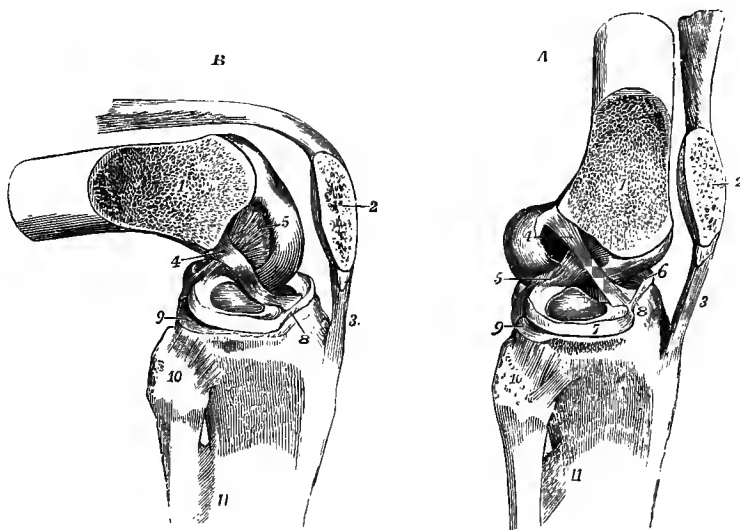


Fig. 213.—THE SUPERFICIAL PARTS OF THE KNEE JOINT REMOVED, AND THE EXTERNAL CONDYLE OF THE FEMUR SAWN OFF OBLIQUELY, TOGETHER WITH HALF THE PATELLA, SO AS TO EXPOSE BOTH THE CRUCIAL LIGAMENTS TOGETHER. (Allen Thomson.)  $\frac{1}{2}$

In A, the parts are in the position of extension, in B, that of flexion, the figures being designed to show the different states of tension of the crucial ligaments in these positions. 1, sawn surface of femur; 2, sawn surface of patella; 3, ligamentum patellæ; 4, anterior or external crucial ligament, tense in A, and relaxed in B; 5, posterior or internal crucial ligament, partly relaxed in A, tense in B; 6, internal, and 7, external semilunar fibro-cartilage; 8, transverse ligament; 9, articular surface of the tibia, extending behind the external semilunar fibro-cartilage; 10, on the head of the fibula, points to the anterior superior tibio-peroneal ligament; 11, upper part of the interosseous membrane.

upper surfaces of the semilunar fibro-cartilages, round the free borders of those structures to their inferior surfaces, and thence to the tibia. The crucial ligaments are invested in front by a reflected portion of the membrane continued forwards from the posterior wall of the joint. Between the tibia and patella the synovial membrane lies upon a large pad or cushion of fat, on the surface of which it forms two lateral folds (*alar ligaments*) which pass to the side and upwards along the lower border of the articular surface of the patella, while from the middle of the pad it sends backwards a variably developed process, the *mucous ligament*, through the joint to the front of the intercondylar fossa. Above the patella the synovial membrane extends upwards for a short distance under the extensor tendon, and the pouch thus formed communicates in most cases more or less freely with a bursa situated here between the tendon and the anterior surface of the femur.

**Movements, &c.**—In order to explain the nature of the movements, it is necessary to state some considerations with regard to the relations of the several parts of the knee-joint to each other. The knee-joint may be regarded as consisting of three articulations conjoined, viz., that between the patella and femur, and two others, one between each condyle of the femur and the tibia. In many mammals the synovial membranes of these three joints are either completely distinct or communicate with each other by only small openings. In the human subject the mucous ligament is an indication of this separation of the synovial cavities of the inner and outer joints, and the crucial ligaments may be looked upon as the external and internal lateral ligaments of those two joints respectively. On the cartilage-covered articular surface of the femur also a corresponding subdivision into three parts is to be recognised, the trochlear surface for the patella being separated from the convex tibial surfaces by two shallow transverse grooves which receive the fibro-cartilages in the extended position of the joint; but along the inner margin of the intercondylar fossa there is marked off from the rest of the internal condyle a narrow semilunar facet which is in contact with the innermost facet of the patella in extreme flexion.

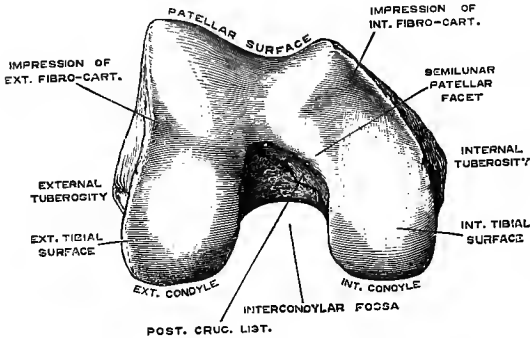


Fig. 214.—LOWER EXTREMITY OF THE RIGHT FEMUR, FROM BELOW. (Drawn by T. W. P. Lawrence.)  $\frac{3}{4}$

it would be, were the movement one of gliding only, but exhibits on each side of the vertical ridge three very slightly depressed surfaces, separated by two slight transverse elevations, and along the inner margin a seventh area, upon which the transverse lines do not encroach. When the knee is extended, and the patella drawn upwards by the extensor muscles, the two inferior facets of the patella are in contact with the upper margin of the

The movement of the patella on the femur is one partly of gliding, partly of coaptation. This is illustrated by a careful examination of the articular surface of the patella, which is not uniformly curved from above downwards, as

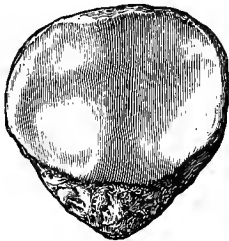


Fig. 215.—RIGHT PATELLA, FROM BEHIND. (Drawn by T. W. P. Lawrence.)  $\frac{3}{4}$

The articular surface is seen, divided by a ridge into a smaller internal and a larger external part. On each of these three facets may be recognised, of which the middle is the largest and the lower the smallest, while along the inner margin there is a narrow seventh facet.

trochlear surface; in semiflexion the middle facets only are in contact with the femur; in greater flexion, the superior parts of the patella are in contact with the lower parts of the trochlear surface; and in extreme flexion the patella, which has been gradually turned outwards by the increasing prominence of the inner condyle, rests by its innermost facet against the semilunar surface on the outer margin of the internal condyle, and by its upper and outer facet on the fore part of the external condyle.

The articulation between each condyle and the opposed almost flat surface of the tibia, while resembling, is not exactly a hinge-joint, and extension and flexion, the movements of which it is capable, are produced by a combination of gliding, rolling, and rotation. If the condyles of the femur be examined as they rest upon the tibia in the flexed position of the joint, it will be seen that the inner condyle is longer than the outer, and that its anterior portion inclines obliquely outwards to reach the patellar surface. In the movement of extension the condyles move parallel to one another, both gliding and rolling until extension is nearly completed, and then, the anterior part of the rolling surface of the external condyle having already come into full contact with the tibia, the inner condyle continues to glide backwards, bringing its oblique anterior part into contact with the tibia, so that the femur is rotated inwards on the tibia. Similarly, the beginning of flexion is accompanied by a rotation outwards of the femur, or inwards of the tibia. In complete extension the lateral ligaments, the posterior ligament, and the anterior crucial ligament are tight, while the

posterior crucial ligament is in part relaxed; in flexion, the posterior crucial ligament only is tightened, the others being relaxed. Over-extension is prevented, not only by the tension of the ligaments, but also by the anterior portions of the semilunar fibro-cartilages being pressed into the grooves of the femoral articular surface, and the anterior margin of the intercondylar fossa meeting the lower end of the anterior crucial ligament. In the last stage of the movement of extension the inner part of the outer groove of the femur plays over a special facet of the tibia in front of the outer tubercle of the spine (fig. 210). In extension of the joint no rotation of the leg is possible; in the flexed condition a considerable amount is allowed. Rotation out is checked by the internal lateral ligament, in by the anterior crucial ligament: the whole range of movement, when the knee is bent to a right angle, is on an average about  $40^\circ$ ; but it varies much in different individuals. The semilunar fibro-cartilages, being loosely attached to the head of the tibia, move forwards in extension and backwards in flexion of the joint; and farther, as the condyles rolling upon the tibia present successively to the condylar surfaces of that bone portions having different curvatures, each cartilage, like a moveable wedge, is contracted round the condyle during flexion of the joint and expanded during extension. The mass of fat below the patella serves to fill up the space between the ligamentum patellæ and the bones, and adapts itself to the varying form of this interval during the movements of the joint, the alar ligaments projecting upwards into the angle between the lower part of the patellar surface and the femur.

In the erect attitude, the knee-joint, like the hip, is maintained in the fully extended position in great measure without muscular effort; but there is some difference of opinion as to the manner in which this is effected. According to the one view, which is supported by Humphry and Langer, the line of gravity of the body falls in front of the axis of movement of the knee-joint, and the tendency is thus to over-extension, which is resisted by nearly all the ligaments of the articulation. On the other hand H. Meyer holds that the line of gravity falls slightly behind the axis of movement, and that the stability of the knee depends mainly upon the association of rotation with the beginning of flexion; for, while the tibia is fixed by its connection with the foot, the femur is prevented from rotating outwards by the ilio-femoral ligament, which in its turn is kept tense by the weight of the body acting on the hip-joint. Rotation between the tibia and femur being thus impossible, flexion cannot take place, and the knee-joint is fixed until by a slight bending at the hip-joint the ilio-femoral ligament is relaxed. Additional support is also given to the knee-joint by the tension of the ilio-tibial band of the fascia lata (pp. 242 and 249). (H. Meyer, Müller's Archiv, 1853; Goodsir, "Anatomical Memoirs," ii, 220, 231; Langer, Sitzungsber. d. Acad. der Wissensch. Wien, 1858, and "Lehrb. d. Anat.;" Humphry, "A Treatise on the Human Skeleton;" Henke, Zeitschr. für rat. Med., viii, 1859; R. Bruce Young, On the grooves of the femur and locking of the knee-joint, in "Memoirs and Memoranda in Anatomy," 1889.)

#### THE TIBIO-FIBULAR ARTICULATIONS.

The tibia and fibula form articulations at their upper and lower extremities, and their shafts are united by an interosseous membrane.

**Upper tibio-fibular articulation.**—The superior extremities of the bones present two flattened oval articular surfaces, retained in close contact by thin *anterior* and *posterior superior tibio-fibular ligaments*, both of which pass downwards and outwards from the external tuberosity of the tibia to the head of the fibula. The synovial cavity of this joint not unfrequently communicates posteriorly with that of the knee.

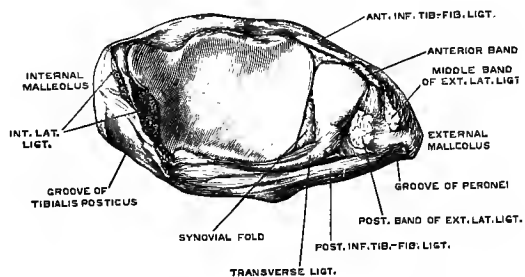


Fig. 216.—INFERIOR EXTREMITIES OF THE LEFT TIBIA AND FIBULA, FROM BELOW, SHOWING THE UNITING LIGAMENTS AND THE FORMATION OF THE SOCKET OF THE ANKLE-JOINT. (Drawn by T. W. P. Lawrence.)

The **interosseous membrane** or **ligament**, which connects the shafts of the tibia and fibula, passes between the external border of the tibia and the interosseous

ridge of the fibula (fig. 142), and is composed for the most part of parallel fibres running outwards and downwards, only a few fibres crossing in a different direction. It presents superiorly an elongated opening for the transmission of the anterior tibial vessels, and inferiorly a small interval is left between it and the lower articulation for the passage of the anterior peroneal vessels.

**Lower tibio-fibular articulation.**—The inferior extremities of the tibia and fibula articulate by surfaces which for the most part are rough and bound together by ligament, but at their lower part, for a distance of about a quarter of an inch, are smooth and lined by synovial membrane. The tibial surface is concave, the fibular is correspondingly convex. The strong short fibres which pass obliquely between the opposed surfaces form the *inferior interosseous ligament* (fig. 219, 4). The *anterior ligament* (fig. 222, 2) is a flat band of fibres, extended obliquely over the lower part of the bones, the direction of its fibres being downwards from the tibia to the fibula. The *posterior ligament* is similarly disposed behind the articulation. The *transverse* or *inferior ligament* is a short but thick band of yellowish fibres under cover of the posterior ligament; it runs horizontally from the hinder border of the lower articular surface of the tibia to the contiguous part of the external malleolus, and closes the angular interval between the bones.

The *synovial cavity* of this articulation is an extension of that of the ankle-joint.

#### THE ANKLE-JOINT

In this articulation, which is a hinge-joint, the inferior extremities of the tibia and fibula are united so as to form a three-sided hollow, which embraces the astragalus: the socket is completed behind by the transverse ligament of the inferior tibio-fibular articulation. The articular surface of the astragalus occupies the upper

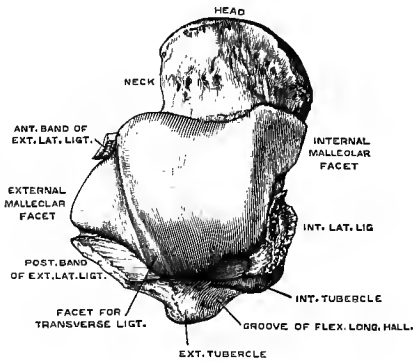


Fig. 217.—THE ASTRAGALUS FROM ABOVE, SHOWING THE ARTICULAR SURFACE AND THE ATTACHMENTS OF THE LATERAL LIGAMENTS OF THE ANKLE-JOINT. (Drawn by T. W. P. Lawrence.) §

surface of the body, and is continued downwards on each side of the bone for the corresponding malleolus. The inner margin of the superior surface is nearly straight; the outer margin is convex, and inclined inwards posteriorly, thus making the surface narrower behind than in front. Between the upper and the external surfaces posteriorly is a narrow triangular facet which plays against the transverse tibio-fibular ligament. The capsule of the articulation is divided into the following ligaments:—

The **internal lateral** or **deltoid ligament** (fig. 221, 1) is a broad layer of fibres, which radiate from the internal malleolus to the tarsal bones. The hinder part is thick

and short, and descends from the notch at the lower border of the malleolus to the inner surface of the astragalus. The fore part, thinner and more expanded, extends from the tip and anterior border of the malleolus to the sustentaculum tali of the os calcis, the internal calcaneo-navicular ligament, and the dorsal surface of the navicular bone.

The **external lateral ligament** (fig. 222, 4, 5, 6) consists of three distinct bands disposed in different directions. 1. The *middle band* descends from the



extremity of the fibula, to the external surface of the os calcis. 2. The *anterior band* passes obliquely forwards and inwards from the fore part of the outer malleolus to the body of the astragalus in front of its external malleolar surface; it is the shortest of the three. 3. The *posterior band*, the strongest of the three, passes almost

Fig. 218.—THE LOWER TIBIO-FIBULAR ARTICULATION AND ANKLE-JOINT FROM BEHIND. (Allen Thomson.)  $\frac{1}{3}$

1, interosseous membrane; 2, posterior ligament of the lower tibio-fibular articulation; 3, internal lateral ligament of the ankle-joint; 4, posterior, and 5, middle bands of the external lateral ligament of the ankle-joint; 6, external, and 7, posterior astragalo-calcaneal ligaments.

horizontally inwards from the pit on the inner side of the malleolus to the external tubercle of the astragalus, and the surface between the latter and the fibular articular facet.

The **anterior ligament** is a thin and lax membrane which passes from the anterior margin of the lower end of the tibia to the upper aspect of the head of the astragalus. Beneath it is a cushion of fat which rests in the hollow of the neck of the astragalus.

The **posterior ligament** is fixed to the tibia and astragalus near their articular surfaces. Its fibres are weak, and run chiefly inwards, radiating from the external malleolus upwards to the tibia and downwards to the astragalus.

The **synovial cavity** of the ankle-joint extends upwards for about a quarter of an inch into the lower tibio-fibular articulation. On the outer side of the entrance to this recess the synovial membrane forms a small fold containing fat, which occupies

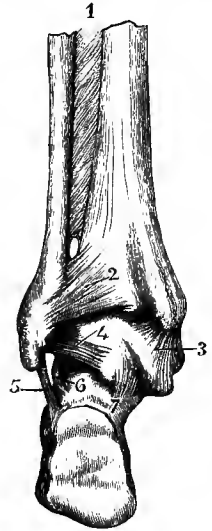
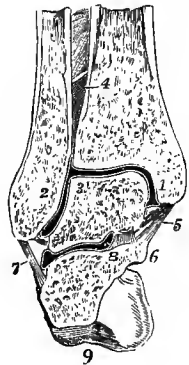


Fig. 219.—CORONAL SECTION OF THE RIGHT ANKLE-JOINT NEAR ITS MIDDLE, AND OF THE POSTERIOR ASTRAGALO-CALCANEAL ARTICULATION, VIEWED FROM BEFORE. (Allen Thomson.)  $\frac{1}{3}$

1, internal, 2, external malleolus; 3, placed on the astragalus at the angle between its superior and its external surfaces; 4, inferior interosseous tibio-fibular ligament; 5, internal lateral ligament of the ankle-joint; 6, sustentaculum tali; 7, calcaneo-fibular or middle part of the external lateral ligament; 8, inner part of the interosseous astragalo-calcaneal ligament; 9, tuberosity of the calcaneum.

the angular interval between the three bones, and is carried upwards between the tibia and fibula when the external malleolus is forced outwards in flexion of the ankle-joint. At the front and back of the joint are larger synovial folds projecting between the tibia and astragalus.



**Movements, &c.**—The movements of the ankle-joint are flexion, in which the toes are raised towards the leg, and extension, in which the toes are depressed and the foot brought into the line of the leg. The whole range of movement does not exceed  $90^\circ$ . Although the horizontal surfaces of both the tibia and astragalus are broader in front than behind, the malleoli are in contact with the sides of the astragalus in all positions of the joint, a slight degree of lateral movement of the external malleolus being permitted by the inferior tibio-fibular ligaments and the elasticity of the shaft of the fibula. When the joint is bent the wide part of the astragalus is pushed back into the socket, and the external malleolus is forced outwards; whereas in extension the external malleolus follows the curve of the outer surface of the astragalus, being drawn inwards mainly by the posterior band of the external lateral ligament. In this way a certain amount of spring is given to the articulation. In the mid-position of the joint,

when the ligaments are least stretched, a limited degree of lateral motion is allowed under the influence of external force, but it is probable that such movements do not occur naturally. In the erect attitude the line of gravity of the body falls slightly in front of the ankle-joint, and a certain amount of muscular effort is required to maintain the position of the leg-bones; but stability is to some extent secured by the obliquity of the axis of the ankle-joint, which forms with its fellow, owing to the outward direction of the foot, an angle, open backwards, of about  $130^{\circ}$ .

#### THE ARTICULATIONS OF THE FOOT.

**ARTICULATIONS OF THE ASTRAGALUS WITH THE CALCANEUM AND NAVICULAR BONE.**—The astragalus is connected with the calcaneum by two synovial articulations, viz., by a posterior one peculiar to those two bones, and by an anterior one common to them with the navicular bone. Two strong ligaments also unite the navicular bone to the calcaneum.

**Astragalo-calcaneal ligaments.**—The *interosseous ligament* (fig. 223), broad and strong, passes downwards from the groove between the anterior and posterior

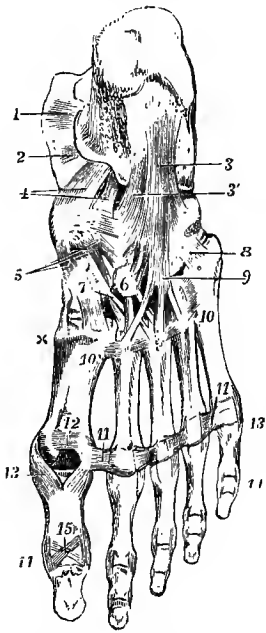


Fig. 220.—LIGAMENTS OF THE FOOT, SEEN FROM BELOW.  
(Allen Thomson.) }  
}

1 and 2, portions of the internal lateral ligament of the ankle-joint; 3, long, and 3', short plantar ligaments; 4, internal calcaneo-navicular ligament; 5, three naviculo-cuneiform ligaments; 6, is placed upon the external cuneiform bone, towards which is seen coming from behind a cubo-cuneiform ligament; 7, is placed upon the internal cuneiform bone; from 6 and 7, are seen passing forwards the plantar cuneo-metatarsal ligaments; x, part of the first dorsal cuneo-metatarsal ligament; 8, plantar band from cuboid to fifth metatarsal bone; 9, fibres prolonged from the long plantar ligament, forming the sheath of the peroneus longus tendon; 10, 10, between these figures the plantar intermetatarsal ligaments; 11, 11, transverse metatarsal ligament; 12, intersesamoid ligament; 13, 13, between these figures are seen the five pairs of internal and external lateral metatarso-phalangeal ligaments; 14, 14, between these figures are seen the five pairs of internal and external lateral interphalangeal ligaments of the first series; those of the second series have no figure placed to mark them; 15, plantar ligament of the interphalangeal articulation of the great toe.

articular surfaces of the astragalus to the similar groove between the corresponding articular surfaces of the calcaneum. The *posterior ligament* (fig. 221, 3), thin and membranous, consists of short fibres which radiate from the external tubercle of the astragalus to the adjacent upper and inner part of the calcaneum. A

small *internal ligament* (fig. 221, 2) runs forwards from the internal tubercle of the astragalus to the back of the sustentaculum tali, its upper fibres being continued into the internal calcaneo-navicular ligament. There is also an inconstant *external ligament* (fig. 218, 6), a slight fasciculus of fibres which descends from the outer surface of the astragalus to the outer side of the calcaneum, parallel with the middle division of the external lateral ligament of the ankle-joint. It may be farther observed, that those portions of the lateral ligaments of the ankle-joint which pass down over the astragalus to the os calcis assist in uniting these two bones.

**Calcaneo-navicular ligaments.**—The *internal or inferior ligament* is a broad and thick band, in great part fibro-cartilaginous, which occupies the interval between the sustentaculum tali and the navicular bone on the plantar aspect and inner border of the foot. Its lower part springs from the anterior margin of the sustentaculum tali, and is directed forwards and inwards to the inferior surface of the navicular bone. Continuous with this, the fibres of the upper part of the liga-

ment run from the inner extremity of the sustentaculum, in a radiating manner forwards and upwards, to be fixed to the back of the tuberosity and the inner part of the upper surface of the navicular bone, being joined by the anterior fibres of the deltoid ligament of the ankle-joint, which descend from the internal malleolus. The deep surface of the ligament is smooth and forms a part of the articular socket for the head of the astragalus. On the superficial aspect of the upper portion of the ligament is another smooth surface where the tendon of the tibialis posticus is in contact with it. The ligament occasionally contains an ossification. The *external* or *superior calcaneo-navicular ligament* (fig. 222, 8 ; 223) forms the external boundary of the socket just mentioned, and lies deeply at the anterior part of the fossa (sinus tarsi) between the astragalus and os calcis. Its fibres, very short, are directed

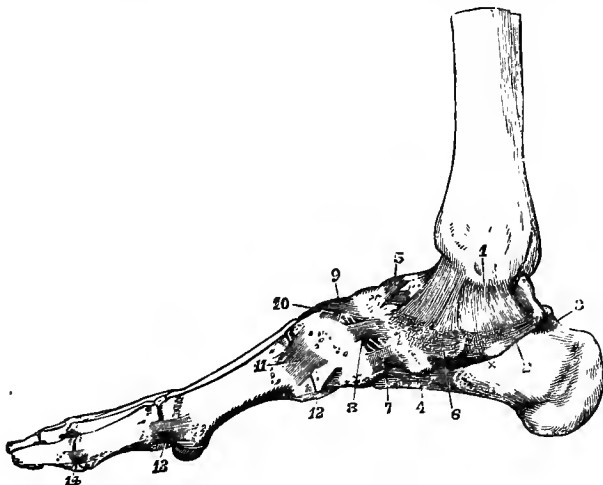


Fig. 221.—LIGAMENTS OF THE FOOT, FROM THE INNER SIDE. (Allen Thomson.)  $\frac{1}{2}$

1, internal lateral ligament of the ankle ; x, below the sustentaculum tali, showing part of the internal lateral ligament descending upon it ; 2, internal, and 3, posterior astragalo-calcaneal ligaments ; 4, part of the long and short plantar ligaments seen from the inside ; 5, astragalo-navicular ligament ; 6, superior part of the internal calcaneo-navicular ligament, with the cartilaginous surface for the tibialis posticus tendon ; 7, 8, first, 9, second dorsal naviculo-cuneiform ligaments ; 10, intercuneiform, or transverse dorsal cuneiform, between the first and second cuneiform bones ; 11, first dorsal tarso-metatarsal ligament ; 12, first plantar tarso-metatarsal ; 13, internal lateral metatarso-phalangeal ; the internal sesamoid bone is seen below ; 14, internal lateral interphalangeal ligament of the first toe.

from behind forwards and inwards between the contiguous extremities of the bones. They are attached posteriorly to the foremost part of the upper surface of the os calcis between the articular surfaces for the astragalus and cuboid, and anteriorly to the outer side of the navicular bone.

The **astragalo-navicular ligament**, a membranous band situated on the dorsum of the foot, consists of two portions which converge as they pass forwards from the head of the astragalus to the upper surface of the navicular bone, and completes the fibrous capsule of the astragalo-calcaneo-navicular joint, formed in the rest of its extent by the internal and external calcaneo-navicular ligaments.

The two *synovial cavities* of these articulations are separated by the interosseous ligament (fig. 223): the posterior belongs to the astragalo-calcaneal joint, the anterior to the astragalo-calcaneo-navicular articulation.

**CALCNEO-CUBOID ARTICULATION.**—The calcaneum is united to the cuboid bone by a synovial joint with surrounding ligaments.

The *inferior ligament* consists of two distinct layers, of which one is superficial, the other deep-seated. The superficial part, called the *long plantar ligament* (fig. 220, 3), is the longest of the tarsal ligaments. Its fibres, attached behind to the inferior surface of the calcaneum as far as the anterior tubercle, pass forwards, and are attached in greater part to the ridge on the under surface of the cuboid bone; but some of them are continued onwards to the bases of the third, fourth and fifth metatarsal bones, covering the tendon of the peroneus longus muscle. The deep-seated part, or *short plantar ligament* (fig. 220, 3'), lies close to the bones, being separated from the superficial part by some areolar tissue. Its breadth is considerable, its length scarcely an inch. One extremity is attached to the front of the ante-

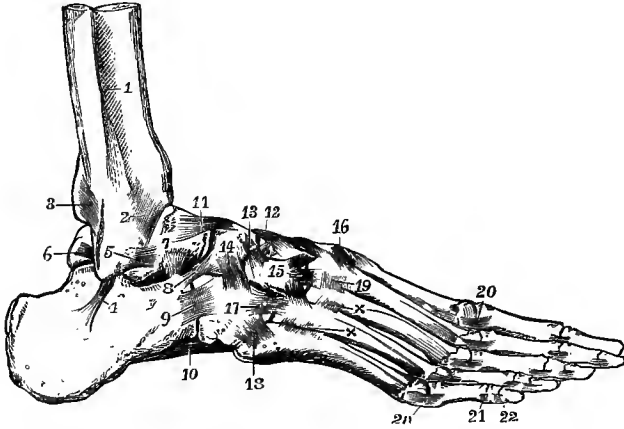


Fig. 222.—LIGAMENTS OF THE FOOT, FROM THE OUTER AND DORSAL ASPECT. (Allen Thomson.)  $\frac{1}{3}$

1, lower part of the interosseous membrane; 2, anterior inferior tibio-peroneal ligament; 3, posterior inferior tibio-peroneal ligament; 4, middle, 5, anterior, and 6, posterior parts of the external lateral ligament of the ankle-joint; 7, is placed above the interosseous astragalo-calcaneal ligament; 8, external calcaneo-navicular; 9, dorsal calcaneo-cuboid; 10, part of the long plantar or inferior calcaneo-cuboid; 11, astragalo-navicular; 12 and 13, second and third naviculo-cuneiform, and between them one of the intercuneiform ligaments; 14, superior naviculo-cuboid; 15, placed on the external cuneiform bone, points to the cuneo-metatarsal ligaments from that bone to the second, third, and fourth metatarsal bones; 16, cuneo-metatarsal ligament, from the first cuneiform to the second metatarsal bone; between 15 and 16, are seen the cuneo-metatarsal ligaments which converge from the three cuneiform bones on the second metatarsal; 17, 18, cubo-metatarsal ligaments; 19 and x x, dorsal intermetatarsal ligaments; 20, lateral metatarso-phalangeal; 21, 22, lateral interphalangeal.

rior tubercle of the calcaneum, the other, somewhat expanded, to the depressed surface of the cuboid bone behind the ridge.

The *dorsal* or *superior ligament* is a flat band, connecting the upper surfaces of the calcaneum and the cuboid bone.

The *internal* or *interosseous ligament* is placed deeply in the hollow between the astragalus and os calcis, and is closely connected with the external calcaneo-navicular ligament.

This joint has a separate *synovial cavity*.

The name **transverse tarsal articulation** is given to the interrupted line of articulation crossing the foot between the astragalus and os calcis behind, the navicular and cuboid in front.

ARTICULATIONS OF THE NAVICULAR, CUBOID, AND CUNEIFORM BONES, ONE WITH ANOTHER.—**Naviculo-cuboid articulation**.—The navicular and cuboid bones are connected by a *dorsal ligament*, composed of short fibres, extending obliquely between the two bones; a *plantar ligament*, consisting of transverse fibres;

and a strong *interosseous ligament*, which intervenes between their contiguous surfaces. When the bones touch, which is not always the case, they present two small articulating surfaces, which are covered with cartilage and have between them an offset of the adjacent naviculo-cuneiform synovial cavity.

**Naviculo-cuneiform articulation.**—The navicular articulates with the three cuneiform bones by the smooth facets on its anterior surface, forming one continuous joint. They are united by *dorsal ligaments*, passing from the upper surface of the navicular to the first, second and third cuneiform bones, and by *plantar ligaments*, which are similarly disposed on the under surface of the bones, but these are continuous with, or offsets from, the tendon of the tibialis posticus muscle.

**Cubo-cuneiform articulation.**—The cuboid and the external cuneiform bones are connected by a *dorsal ligament*, which is a thin fasciculus of transverse fibres ;

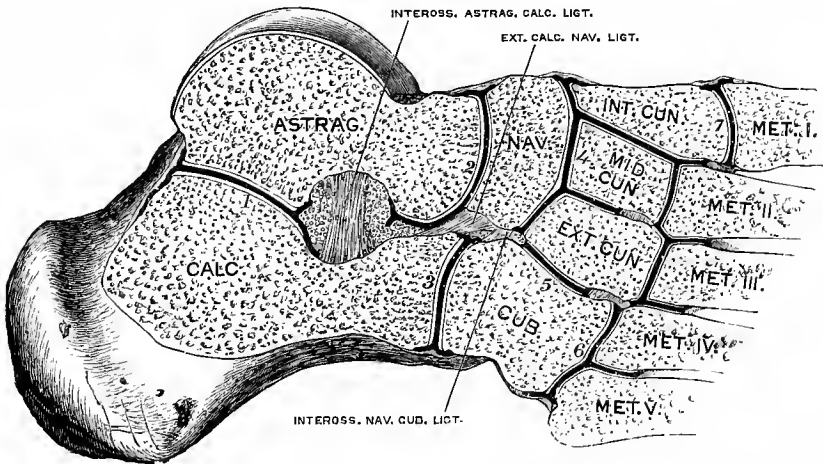


Fig. 223.—SECTION OF THE FOOT, SHOWING THE SYNOVIAL CAVITIES OF THE TARSAL AND TARSO-METATARSAL ARTICULATIONS. (G. D. T.)

The section is carried nearly vertically through the astragalus, obliquely upwards and inwards across the other bones. 1, posterior astragalo-calcaneal articulation ; 2, astragalo-calcaneo-navicular articulation ; 3, calcaneo-cuboid articulation ; 4, naviculo-cuneiform articulation, the common synovial cavity extending forwards to the articulations between the cuneiform and the second and third metatarsal bones ; 5, cubo-cuneiform articulation (this is frequently continuous with the foregoing) ; 6, cubo-metatarsal articulation (this sometimes communicates with the adjoining cuneo-metatarsal joint) ; 7, internal cuneo-metatarsal articulation.

a *plantar ligament*, the fibres of which are also transverse and rather indistinct ; and a bundle of *interosseous* fibres. Between the two bones an articulation is formed by cartilaginous surfaces ; it is provided sometimes with a separate synovial sac, at others with an offset from that which belongs to the naviculo-cuneiform articulation.

The **three cuneiform bones** are connected by transverse *dorsal ligaments* and strong *interosseous* fibres, the latter being their most efficient uniting structures. The synovial cavity of the naviculo-cuneiform articulation sends forwards two processes between these bones.

**ARTICULATIONS OF THE TARSUS WITH THE METATARSUS.**—The four anterior bones of the tarsus, viz., the three cuneiform and the cuboid, articulate with the metatarsal bones ; and as the first and third cuneiform bones project beyond the middle one, and the third cuneiform beyond the cuboid bone, the anterior surface of the tarsus is very irregular. The first metatarsal bone articulates with the

internal cuneiform ; the second is wedged in between the first and third cuneiform, and rests against the second ; the third metatarsal bone articulates with the extremity of the external cuneiform ; and the last two with the cuboid bone, the fourth having also usually an articulation with the external cuneiform. The articulations are synovial joints, and the bones are held in contact by dorsal, plantar, and interosseous ligaments.

The *dorsal tarso-metatarsal ligaments* (fig. 222) are flat thin bands of parallel fibres, which pass from behind forwards, connecting the contiguous extremities of the bones before mentioned. Thus the first metatarsal bone receives a broad thin band from the corresponding cuneiform bone ; the second receives three, which converge to its upper surface, one passing from each cuneiform bone ; the third has one from the external cuneiform bone ; and, finally, the last two are bound by a fasciculus to each from the cuboid bone, and by fibres from the external cuneiform to the fourth metatarsal bone. The *plantar ligaments* are less regular ; the bands of the first and second metatarsal bones are more strongly marked than the corresponding ligaments on the dorsal surface ; and those of the fourth and fifth, which are merely a few scattered fibres passing from the cuboid, receive support from the prolongation of the long plantar ligament, forming the sheath of the peroneus longus tendon. Ligamentous bands stretch in an oblique direction from the internal cuneiform to the second and third metatarsal bones ; and others, less developed, run nearly transversely from the external cuneiform to the fifth metatarsal.

The *interosseous ligaments* run forwards between the bones, and from their strength and deep position oppose great resistance to the knife in separating the metatarsus from the tarsus. *a.* The *internal* and largest of these extends from the outer side of the first cuneiform bone to the neighbouring side of the second metatarsal, close to the articular surface. *b.* The *middle*, which is the smallest, and is less constant than the others, passes from the external cuneiform to the outer side of the second metatarsal bone. *c.* The *external* connects the outer side of the external cuneiform to the same side of the third metatarsal bone.

*Synovial cavities.*—There are three synovial cavities in this irregular series of articulations. *a.* One is between the internal cuneiform and the first metatarsal bone ; the joint formed between these two bones is altogether separate and out of the range of the rest. *b.* A second synovial cavity is between the cuboid and the fourth and fifth metatarsal bones, and sends a small process forwards between the latter bones. *c.* The third or middle one is placed between the middle and external cuneiform and the second and third metatarsal bones, and is prolonged between the two last-named bones, as well as between the third and fourth metatarsal bones. This cavity generally communicates between the internal and middle cuneiform bones with that of the naviculo-cuneiform articulation.

**INTERMETATARSAL ARTICULATIONS.**—The metatarsal bones are bound together at their tarsal and digital ends ; very firmly in the former, and loosely in the latter situation.

The tarsal ends of the four outer bones articulate with each other, having lateral cartilaginous surfaces, between which processes are sent forwards from the outer two synovial cavities of the tarso-metatarsal articulations, and they are connected by dorsal, plantar, and interosseous ligaments. The *dorsal* and *plantar ligaments* are short transverse bands stretching across the four metatarsal bones from one to another. The *interosseous ligaments*, lying deeply between the bones, connect the rough parts of their lateral surfaces ; they are of considerable strength and firmness. Between the first and second metatarsal bones there is often a bursa, corresponding to a small articular facet on the base of the former bone, while on the latter there is

only an indistinct smooth surface covered by synovial membrane (see figs. 152 and 154): this bursa may communicate with the first cuneo-metatarsal joint. †

**Transverse metatarsal ligament.**—The digital extremities or heads of the metatarsal bones are loosely connected by a transverse band, which is identical in its arrangement with the corresponding structure in the hand, with this exception, that it is attached to the great toe, whereas in the hand the transverse metacarpal ligament does not reach the thumb.

**METATARSO-PHALANGEAL AND INTERPHALANGEAL ARTICULATIONS.**—The heads of the metatarsal bones are connected with the small concave articular surfaces of the first phalanges by two *lateral ligaments*, an *inferior ligament*, which is developed into a thick *fibrous* or *sesamoid plate*, and a synovial membrane,—all being closely similar to the corresponding parts of the hand. In the first metatarso-phalangeal articulation the sesamoid plate is divided into two parts, which are fully ossified, forming the sesamoid bones. These are held together by strong transverse ligamentous fibres, and being provided with cartilaginous surfaces, move upon the corresponding grooved cartilaginous surfaces of the head of the first metatarsal bone.

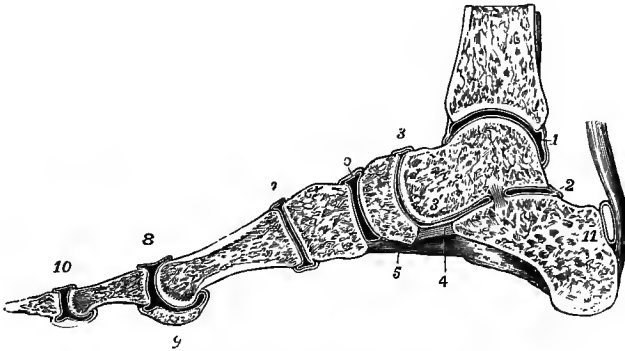


Fig. 224.—SAGITTAL SECTION OF THE ANKLE-JOINT AND ARTICULATIONS OF THE RIGHT FOOT, A LITTLE TO THE INSIDE OF THE MIDDLE OF THE GREAT TOE. (Allen Thomson.)  $\frac{1}{2}$

1, synovial cavity of the ankle-joint; 2, posterior astragalo-calcaneal articulation; 3, 3', astragalo-calcaneo-navicular articulation: the interosseous ligament is seen separating 2 from 3'; 4, inferior calcaneo-navicular ligament; 5, part of the long plantar ligament; 6, naviculo-cuneiform articulation; 7, first cuneo-metatarsal articulation; 8, first metatarso-phalangeal articulation; 9, section of the inner sesamoid bone; 10, interphalangeal articulation; 11, placed on the calcaneum, indicates the bursa between the upper part of the tuberosity of that bone and the tendo Achillis.

The articulations of the phalanges with one another are also constructed on the same plan as those of the superior extremity. In each the bones are held in contact by two *lateral ligaments* and an *inferior ligament* or *fibrous plate*; and each of the cavities is lined by a synovial membrane.

**Mechanism and movements.**—In the mechanism of the foot a longitudinal and a transverse arch are to be recognized, both of them capable of being flattened somewhat by pressure from above, thus securing elasticity. The longitudinal arch, as analyzed by v. Meyer, is formed primarily by the calcaneum, astragalus, cuboid, navicular, external cuneiform and third metatarsal bones, the external cuneiform being wedged in between the navicular and cuboid, and the third metatarsal being firmly united at its base by strong ligaments, so that very little movement is allowed. To the slender anterior pillar of the arch lateral supports are added, the fourth and fifth metatarsal bones on the outer side, the second and first metatarsal bones on the inner side, which are capable of greater movement, can be adjusted to the form of the supporting surface, and are brought into play according as the weight is thrown on the one or the other side of the foot. The first metatarsal bone and the great toe have their chief use in progression. In making a step, as the heel of the

supporting foot leaves the ground, the outer side of the foot is raised, the weight is thrown onto the second, and then the first metatarsal bone, and the propulsion is completed by the flexion of the phalanges of the great toe. The longitudinal arch is supported by the strong plantar ligaments, especially the calcaneo-navicular and calcaneo-cuboid, assisted by the plantar fascia and the muscles of the sole. The transverse arching of the foot is most marked in the line of the tarso-metatarsal articulations, and is maintained by the plantar and interosseous ligaments. The weight of the body in standing, especially when the heel is raised from the ground, tends to spread out the metatarsal bones at their distal extremities, and to flatten the transverse arch, which recovers its position when the pressure is removed.

The chief movements taking place between the tarsal bones are those of *inversion* and *eversion* of the foot, which have their seat mainly in the astragalo-calcanean and transverse tarsal articulations. In inversion the fore part of the foot is depressed and carried inwards, the longitudinal arch is increased, and the outer part of the foot descends more than the inner, so that the sole is turned to some extent inwards. In eversion these actions are reversed, and the foot resumes its normal position. The movement between the astragalus and calcaneum is a rotation about an axis which is directed obliquely from the upper and inner part of the neck of the astragalus, backwards, downwards, and outwards, to the lower and outer part of the tuberosity of the os calcis, so that in inversion the posterior articular surface of the os calcis glides forwards and downwards beneath the astragalus, the sustentaculum tali moves backwards and upwards, and the anterior extremity of the bone is carried slightly inwards. The navicular and cuboid bones are moved at the same time downwards and inwards over the fore part of the astragalus and calcaneum respectively. The movement is assisted by a slight amount of gliding between the anterior tarsal bones, and between these and the metatarsal bones. Inversion of the foot is commonly associated with extension, and eversion with flexion of the ankle-joint. The metatarsal bones are capable of only a limited amount of movement, by which they are carried downwards and brought together (opposition), or raised and separated. This movement is necessarily freest in the first and fifth metatarsal bones, while the third moves hardly at all. It is, however, to be remarked that the movement of the first and second metatarsal bones does not wholly take place between them and the corresponding cuneiform bones, but to a considerable extent also in the naviculo-cuneiform articulations. The movements of the metatarso-phalangeal and interphalangeal articulations are similar to those of the corresponding joints of the fingers, but are more restricted in their extent. In the condition of rest the metatarso-phalangeal articulations of the smaller toes are slightly over-extended, while the interphalangeal joints are somewhat flexed. (G. H. v. Meyer, "Statik und Mechanik des menschlichen Fusses," 1886.)



# MYOLOGY.

By G. D. THANE.

## THE MUSCLES IN GENERAL.

UNDER this section will be brought the description of most of the Voluntary or Skeletal Muscles of the body, the exceptions being certain intrinsic muscles of the auditory apparatus, of the tongue, and of the larynx, which will be considered in connection with the organs of which they form part. Along with the muscles the Fasciæ and Aponeuroses by which they are invested will be described.

The voluntary muscles are for the most part placed in close relation with the endoskeleton, being attached to the bones or other hard parts, and moving these in different directions by their contractions. There are, however, some muscles which may be looked upon as belonging to the cutaneous system, or exoskeleton, and there are a few others which are connected with the viscera. The muscles are all symmetrical, and, with the exception of the sphincters and one or two others, are in pairs.

The total number of voluntary muscles may be stated at 311, there being some variation above or below that number according as certain muscular parts are regarded as separate and independent muscles or only as portions of others. They naturally fall into the following great divisions, viz. :—

A. In the axial part of the body.

1. The muscles of the head and front of the neck = 82.
2. The muscles of the vertebral column and back of the neck = 60.
3. The muscles of the thorax = 42.
4. The muscles of the abdomen = 14.

B. In the limbs.

5. The muscles of the upper limb = 59.
6. The muscles of the lower limb = 54.

In this enumeration the muscles of one side only are reckoned, the intrinsic muscles of the ear, tongue and larynx are included, and various short muscles serially repeated, such as the intercostals, levatores costarum, interspinales, &c., are counted separately, while the erector spinæ and quadriceps extensor cruris are regarded as single muscles.

In the detailed description of the muscles the foregoing divisions will be generally followed, but it may be expedient occasionally to deviate from the strictly systematic arrangement, in so far as may conduce to facility in study and convenience in dissection.

Each muscle constitutes a separate organ, composed chiefly of a mass of the contractile fibrous tissue which is called muscular, and of other tissues and parts which may be looked upon as accessory. Thus the muscular fibres are connected together in bundles or fasciculi (see General Anatomy), and these fasciculi are again embedded in and united together by a quantity of connective tissue, forming the *perimysium*,

and the whole muscle is enclosed in an external sheath of the same material—the *epimysium* (Schäfer). Many of the muscles are connected at their more or less tapering extremities with tendons by which they are attached to the bones or hard parts; and tendinous bands frequently run to a considerable length either on the surface of a muscle or between its fibres. There is indeed great variety in the relation of the muscular and tendinous portions, and but few muscles are entirely destitute of some tendinous element in their composition.

Farther, blood-vessels are largely distributed in the substance of a muscle, carrying the materials necessary for its nourishment and chemico-vital changes, and there are also lymphatic vessels, at least in the perimysium and the tendons. Nerves ramify through every muscle, and by means of these the muscular contractions are called forth and a low degree of sensibility is conferred upon the muscular substance.

The muscles vary much in their individual forms. Some are broad and thin, others are more or less elongated straps, and others are cylindrical or fusiform masses of various thickness; hence some of the various names applied to them, such as long and short, square, round, rhomboid, &c. Not unfrequently two or more muscular parts run into one, as in the bicipital, tricipital, or quadricipital forms. In other instances muscles, beginning as single masses, become divided at their remote ends into two or more muscular or tendinous slips. A division of a muscle in its length into two parts by an intermediate tendon gives the form called digastric or biventral, and there are some muscles in which a greater number of parts are thus separated by what are called tendinous inscriptions or intersections.

In the description of the muscles it is customary to state the attachments of their opposite ends under the names of *origin* and *insertion*, the first term being usually applied to the more fixed, or in the case of the limbs the proximal extremity, and the second to the more moveable or distal attachment; but it is often difficult to lay down a rule for the correct use of these terms, and in the great majority of instances it is of importance to consider the action of a muscle as it may affect the motions of the parts attached not to one only but to both of its extremities.

The study of the actions of the muscles either singly or in groups, though strictly a physiological subject, cannot be separated from their anatomical description. With respect to this the following general principles ought to be kept in view. 1st. That the force exerted by any muscle during its contraction is in proportion to the *number* of muscular elements or fibres composing the muscle. 2nd. That the extent of motion, in so far as it merely depends on the shortening of the fibres of the muscle, is in proportion to the *length* of the fasciculi. And 3rd. That the direction of the force produced by a contracting muscle is in the line of the axis of the whole muscle if it run straight between its opposite points of attachment, but in the line of the portion attached to the moving part if the muscle or its tendon be bent in its course. In most instances of such deflection from the straight course the muscles or their tendons run in loops or in grooves somewhat after the manner of a pulley. The loops are either fibrous or fibro-cartilaginous. In the pulley-like disposition of tendons running over bones, there are frequently fibrous or cartilaginous or bony nodules developed at the place of bending of the tendons. The name *sesamoid*, originally given to the small bones developed in some of the digital tendons, has been applied generally to all similar intratendinous structures.

It is farther to be observed that the direction in which the muscular fasciculi run in a muscle is very frequently not that of the axis of the muscle, nor do they in the great majority of instances extend from end to end in a muscle. On the contrary, the muscular fasciculi are much oftener comparatively short, and are attached within the length of the muscle to prolongations of the main tendons or

to other tendinous bands which intersect its substance; and thus the muscular fibres run into these tendinous parts with various degrees of obliquity to the axis of the muscle.

The muscular flesh forms a large proportion of the weight of the whole body. The following has been calculated for a man of 150 lb. weight from the tables of G. v. Liebig:<sup>1</sup> skeleton, 28 lb.; muscles, 62 lb.; viscera (with skin, fat, blood, &c.), 60 lb.

**General morphology.**—It is obvious that the disposition of the muscles, as a whole and in groups, originally bears a close relation to the plan of vertebrate organization in the skeleton. This is very perceptible in the earlier stages of foetal development and in the lowest vertebrate animals. In fishes especially, and partly in amphibia, the muscles present a remarkable degree of vertebrate segmentation, the greater part of the muscles of the trunk being subdivided into zones, *myomeres* or *myotomes*, by membranous partitions, *myocommata* or *sclerotomes*, which extend transversely through the walls of the trunk, and in which the neural arches of the vertebræ and the costal arches are developed. In the higher animals and in man, together with the greater specialization of muscles in connection with the development of limbs, great deviations from the primitive muscular type in the trunk have occurred, and it becomes extremely difficult to trace the morphological relations of many of the muscles in the axial part of the body. It is indeed only in the deeper muscles of the vertebral column and of the ribs that the vertebrate subdivision and relation remain in any degree apparent. In the more superficial muscles, and more especially in the muscles of the limbs, where the direction of the fibres is generally outwards from the trunk, portions of the myomeres run together so as to form muscles of greater or less length, in which all appearance of vertebrate division is effaced. In their more general relations to the trunk of the body two sets of the muscles may be distinguished as *epaxial* and *hypaxial*, according as they lie above or below the embryonic vertebral axis and the plane of its lateral extension. The *hypaxial* or *sub-vertebral* muscles, comparatively little developed in man, comprise chiefly the prevertebral muscles of the neck with a part of the diaphragm. Of the *epaxial* muscles a *dorso-lateral* division consists mainly of the long and short extensor muscles of the spine and head; while a *ventro-lateral* division consists both of such ventral longitudinal muscles as the genio-hyoid, sterno-hyoid, and rectus abdominis, and of the lateral, obliquely directed, sterno-mastoid, scalene, intercostal, and abdominal muscles. The muscles of the limbs are also primarily derived from this great ventro-lateral muscle. They may be distinguished as *extrinsic* when attached partly to the limbs and partly to the trunk, and as *intrinsic* when wholly attached to the bones of the limbs and their arches.

To these morphological relations farther reference will hereafter be made under the several large divisions of the muscles. (See Humphry, "Observations in Myology," &c., 1872, and in various papers in the Journ. of Anat.; Huxley, "Anat. of Verteb. Animals;" Mivart, "Lessons in Elementary Anatomy;" Wiedersheim, "Lehrb. d. vergl. Anat. d. Wirbelthiere.")

**Homologies and varieties.**—It follows from what has been stated above, that homologous correspondence can be traced between the individual muscles and groups of muscles of man and those of animals. But as the form and attachments of the muscles are subject to very great variation in different animals, as well as to occasional varieties in the same species, the determination of the special homologies is attended in many cases with great difficulty, and is still very imperfect. Many varieties have also been observed in the human body, and it is interesting to notice that these varieties are found to reappear generally in the same form, or in modifications of it which indicate relations to a typical or fundamental structure; and that many of them are thus more or less repetitions of forms known to exist in different species of the lower animals. (Consult Wood in Proceedings of Roy. Soc., 1864-68; Macalister's Catalogue of Muscular Anomalies, in Trans. Roy. Irish Acad., 1872; Wenzel Gruber, in Mem. of the Petersburg Acad., Virchow's Archiv, and "Beobachtungen aus der menschlichen und vergleichenden Anatomie"; Henle's "Handbuch," "Muskellehre," 2nd Ed., 1871; Krause, "Handbuch," 3rd Ed., vol. iii, 1880; Testut, "Les anomalies musculaires chez l'homme expliquées par l'anatomie comparée," 1884.)

<sup>1</sup> Archiv f. Anat. u. Physiol., 1874. The weights of the several muscles in a number of subjects of both sexes and at various ages are given by F. W. Theile, "Gewichtsbestimmungen zur Entwicklung des Muskelsystems und des Skelettes beim Menschen," Nova Acta d. k. Leop.-Carol. Akad. d. Naturf., Band xlv, Nr. 3, Halle, 1884.

## FASCIÆ.

The term **fascia** is applied to parts presenting a membranous disposition of reticulated or felted fibrous tissue. These structures are usually distinguished as the *superficial* and the *deep*; the former consisting of looser and finer material, and passing by their slenderer kinds into the looser varieties of connective tissue; while the latter, denser in character, frequently exhibit more or less regular arrangements of strong white fibres, giving them a shining appearance, and are often termed *aponeuroses*.

**Superficial fascia.**—Under this name, or as *subcutaneous fascia*, is described the layer of loose tissue of varying density, which is placed immediately beneath the skin, all over the body. It is the web which contains the subcutaneous fat, the *panniculus adiposus*, and in some regions superficial muscles, which constitute the *panniculus carnosus*. From the subcutaneous tissue of the eyelids, however, as well as from that of the penis and scrotum, adipose matter is entirely absent. Beneath the fatty layer of the superficial fascia, which is immediately subcutaneous, there is generally another layer of the same structure, comparatively devoid of adipose tissue, in which the trunks of the subcutaneous vessels and nerves are found. When the subcutaneous fat becomes absorbed, the stroma in which it was deposited is still left, and its meshes approach one another, so that in lean subjects a more fibrous condition of the superficial fascia is found than in others.

**Deep fasciæ and aponeuroses.**—Under the name of deep fascia is comprehended that stronger layer of fibrous or connective tissue which, lying close to the muscles, invests them, or dips between them, and forms a nearly continuous covering of the body beneath the superficial fascia. It is chiefly to the stronger parts of this fascia that the name of aponeuroses has been given. Those covering the muscles have been named *aponeuroses of investment*, to distinguish them from proper tendinous expansions, or *aponeuroses of insertion*, of muscles. This distinction, however, is far from being universally applicable: aponeuroses of insertion are often continued into aponeuroses of investment, as in the instance of the gluteus maximus, or into softer fascia, as at the lateral parts of the occipito-frontal aponeurosis. The principal aponeuroses of investment are those which encase the muscles of the limbs, binding them down in a common sheath, and connected in various places either directly or by septa with the bones. Parts of the deep fasciæ in the vicinity of the larger joints, as at the wrist and ankle, become strengthened into tight transverse bands which serve to hold the tendons close to the bones, and hence receive the name of *retinacula* or *annular ligaments*.

**Synovial sacs and sheaths: bursæ mucosæ.**—In various situations where the tendons of muscles pass over the prominences of bones, or run in fibrous sheaths, synovial cavities exist, either of a vesicular or tubular form, thus forming the *synovial bursæ* or *sheaths*. In many such instances a true synovial membrane appears to cover the adjacent surfaces, and diminishes their friction in moving on each other. In other places less defined spaces exist in the connective tissue between parts of the tendons or fasciæ, and occasionally between parts of the skin and the harder or more prominent structures on which they lie. In some of these subcutaneous bursæ a distinct synovial membrane cannot be found; and there are probably gradations of transition between these bursal spaces and those which are lined by synovial membrane. Some of the synovial sacs and sheaths of tendons in the vicinity of joints communicate freely with the articular cavities. (See Gen. Anat., Vol. I.)

## I.—THE MUSCLES AND FASCIÆ OF THE UPPER LIMB.

A certain number of muscles situated superficially on the trunk pass to the bones of the shoulder and to the humerus, so as to attach the upper limb to the body. These muscles, from their position, form a division of the muscles of the trunk, but considered with reference to their destination and action they may be held as belonging to the upper limb, and will therefore be so described in the present section. The muscles referred to are, posteriorly, the trapezius, the latissimus dorsi, the rhomboidei, and the levator anguli scapulæ, and, anteriorly, the two pectoral muscles, the subclavius, and the serratus magnus. Along with them might also be included the clavicular part of the sterno-cleido-mastoid muscle and the omo-hyoid; but as these last have important relations with parts situated in the neck, they are more conveniently described among the muscles of that region.

## BETWEEN THE TRUNK AND THE UPPER LIMB POSTERIORLY.

**FASCIÆ.**—The **superficial fascia** covering the muscles which pass from the trunk to the shoulder and upper limb posteriorly forms a layer of considerable strength with embedded fat lying beneath the skin: it is continuous with that of the neck above, that of the axilla and breast in front, and that of the abdomen and hips below.

The **deep fascia of the back** forms a dense fibrous layer closely investing the superficial muscles to which it furnishes sheaths: at the outer margins of the trapezius and latissimus dorsi muscles it is continuous with the deep fasciæ of the neck, axilla, breast, and abdomen, and turns round beneath the edges of the muscles so as to complete their sheaths and separate them from the subjacent layer of muscles. It is attached to the skeleton along the line of the spines of the vertebræ, to the occipital bone, the spine of the scapula, and the crest of the ilium.

In the loins there is a strong, flat, shining tendinous structure called the *lumbar aponeurosis*, to which the latissimus dorsi and other muscles are attached posteriorly; but this will be most conveniently described along with the muscles of the trunk.

**MUSCLES.**—The **trapezius** muscle (*cucullaris*) arises by a thin aponeurosis from the protuberance of the occipital bone, and the inner third of its superior curved line, from the ligamentum nuchæ, and from the spines of the last cervical and all the dorsal vertebræ, as well as from the supraspinous ligament. From this extended line of origin the fibres converge to their insertion: the superior fibres, descending and turning forwards in the neck, are inserted into the outer third of the clavicle at its posterior border; the succeeding fibres pass transversely to the inner border of the acromion process and upper border of the spine of the scapula; while the inferior fibres, ascending obliquely, terminate in a triangular flat tendon which glides over the smooth area at the base of the spine of the scapula, and is inserted into the rough prominence near the root of the spine. The greater part of the line of origin presents only very short tendinous fibres, but opposite the seventh cervical spine, and for the distance of several vertebræ above and below that point, a flat tendon extends outwards, widest at the middle of the space and narrowing towards the upper and lower ends, so that the aponeuroses of the two muscles taken together have an elliptical form. The fibres of origin from the occipital bone have little or no tendinous lustre. The muscles of the two sides have together the form of a four-sided figure, or shawl or cowl, pointing downwards: hence the name of *cucullaris* which has been given to it.

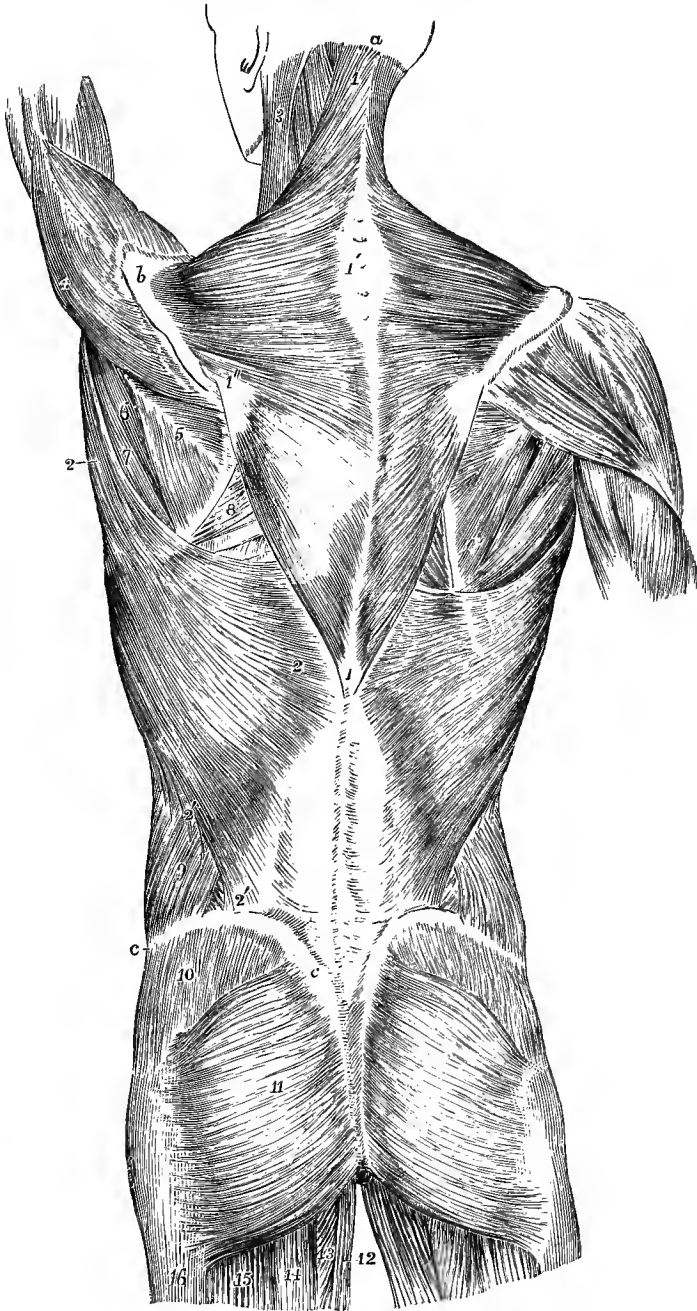


Fig. 225.—SUPERFICIAL MUSCLES OF THE TRUNK, SHOULDER AND HIP, VIEWED FROM BEHIND.  
(Allen Thomson.)  $\frac{1}{3}$

$\alpha$ , external occipital protuberance;  $b$ , acromion;  $c$ , crest of ilium; 1, trapezius; 1', oval tendon of the two muscles in the upper dorsal and lower cervical region; 1'', triangular tendon of insertion; 2, latissimus dorsi; 2', 2'', its costal origins and its origin from the crest of the ilium; 1, 2',  $c$ , tendon of latissimus dorsi blended with the posterior layer of the lumbar aponeurosis; 3, sterno-mastoid; 4, deltoid; 5, infraspinatus; 6, teres minor; 7, teres major; 8, rhomboideus major; below this on the

left side is seen a triangular space bounded by the rhomboid, trapezius, and latissimus dorsi muscles, in which parts of the sixth and seventh ribs are exposed; 9, back part of the external oblique muscle of the abdomen; between 9 and 2', a small part of the internal oblique; 10, part of the gluteus medius covered by the fascia lata; 11, gluteus maximus; 12, gracilis; 13, small part of the adductor magnus; 14, semitendinosus; 15, biceps; 16, fascia lata covering the vastus externus.

**Relations.**—The trapezius is superficial in its whole extent: it lies over the splenius, a part of the complexus appearing above the splenius, the levator anguli scapulae, the rhomboidei, the supraspinatus, and small portions of the infraspinatus and latissimus dorsi. The spinal accessory nerve and the superficial cervical artery pass into it on its deep surface.

**Varieties.**—The trapezius is subject to considerable variations in its attachments: it is not unfrequently shorter than above described, and the number of dorsal vertebrae with which it is connected is sometimes diminished to eight or even fewer. Its occipital attachment may be wanting; and occasionally a separation exists between its cervical and dorsal portions, a condition which is frequent in the lower animals. More extensive deficiencies, and complete absence of the muscle have also been observed. The insertion into the clavicle is sometimes continued forwards to meet the sterno-mastoid muscle.

A vestige of the panniculus carnosus superficial to the trapezius has been recorded in a few instances.

The **latissimus dorsi** muscle arises by tendinous fibres from the spinous processes of the lower six or seven dorsal vertebrae, and from the posterior layer of the lumbar aponeurosis, through the medium of which it is attached to the lumbar and sacral spines and the back part of the iliac crest; it also arises by short tendinous fibres for an inch or more from the iliac crest in front of the outer margin of the lumbar aponeurosis, and from the last three or four ribs by narrow fleshy slips which interdigitate with the lower attachments of the external oblique muscle of the abdomen. The fibres at the upper part are the shortest, and pass almost horizontally outwards over the lower angle of the scapula, from which they often receive a small slip of fleshy fibres; those lower down become longer and pass more obliquely upwards; finally, those which are attached to the ribs ascend almost vertically. By this convergence the fibres of the muscle come to form a narrow band of some thickness, which, accompanying the teres major towards the axilla, winds round the lower and outer border of that muscle so as finally to be placed in front of it. It terminates in a flat tendon of less than an inch and a half in breadth, which is adherent at its lower border to that of the teres major, but is again detached from it previous to its insertion, a synovial bursa intervening between them. The tendon is attached to the floor of the bicipital groove of the humerus, a little higher than the insertion of the teres major. From this twisting of the muscle upon itself, the anterior surface of the tendon is continuous with the posterior surface of the rest of the muscle.

**Relations.**—The latissimus dorsi is subcutaneous, except at its origin from the dorsal vertebrae, where it is covered by the trapezius, and at its insertion, where it is crossed by the axillary vessels and the nerves of the brachial plexus. It rests on part of the rhomboideus major and infraspinatus, on the teres major, serratus posticus inferior, vertebral aponeurosis, lower ribs and external intercostal muscles, and the posterior borders of the external and internal oblique muscles.

Between the adjacent borders of the latissimus dorsi, trapezius, and rhomboideus major, there is left, when the scapula is drawn forwards, a triangular area in which a portion of one or two ribs and of an intercostal space becomes superficial; this is taken advantage of for the purpose of auscultation.

**Varieties.**—The number of dorsal vertebrae to which the latissimus dorsi is attached varies from four to seven or eight, and the number of the costal attachments is also inconstant, being frequently diminished and more rarely increased: the iliac origin is occasionally wanting. Muscular bands (*axillary arches*) are sometimes seen to pass from this muscle near its insertion across the great vessels and nerves to the fore part of the axilla, where they terminate variously, in the tendon of the greater pectoral, in the coraco-brachialis muscle, the biceps, or in the fascia: their nerve of supply is usually derived from the internal anterior thoracic, but it has been seen coming from the nerve of Wrisberg, or intercosto-humeral. A slip passing from the costal origin of the latissimus to the coracoid process represents a form of the *costo-coracoid* muscle (p. 209). From the lower border of the tendon a muscular slip is

occasionally given downwards to the long head of the triceps, to the fascia, or to the internal intermuscular septum of the arm, corresponding to the *dorso-epitrochlearis* muscle of apes and many other mammals: a vestige of this muscle is generally present in man as a fibrous band




Fig. 226.—SUPERFICIAL VIEW OF THE MUSCLES OF THE TRUNK, SHOULDER AND HIP. (Allen Thomson, after Bourgery.)  $\frac{1}{2}$

o, external occipital protuberance; C, transverse process of the atlas; D, first dorsal vertebra; L, first lumbar vertebra; S, first piece of the coccyx; Co, first piece of the coccyx; a, acromion; b, base of the scapula; i, crest of the ilium; 1, sterno-mastoid muscle; 2, splenius; 3, 3', upper and lower ends of the line of origin of the trapezius muscle; 3'', triangular tendon attached to the inner end of the spine of the scapula; +, half of the oval tendon in the lower cervical and upper dorsal region; 4, 4'', latissimus dorsi; 4''', line along which the latissimus dorsi takes origin from the lumbar fascia; 5, infraspinatus; 6, teres minor; 7, teres major; 8, deltoid; 9, external oblique muscle of the abdomen; 10, gluteus medius, covered by the fascia lata; 11, 11', line of origin of the gluteus maximus from the posterior part of ilium to the coccyx; 11'', its insertion into the fascia lata over the great trochanter; 11''', a part of its insertion into the femur; 12, biceps; 13, semi-tendinosus; 14 adductor magnus; 15, gracilis.

passing from the lower border of the tendon of the latissimus to the fascia of the arm and the long head of the triceps.

The **rhomboideus minor**, a comparatively narrow muscle, arises from the spinous processes of the seventh cervical and first dorsal vertebrae and from the ligamentum nuchæ. It inclines downwards and outwards, and is inserted into the base of the scapula opposite the triangular surface at the commencement of the spine.

The **rhomboideus major**, much broader than the preceding muscle, lies immediately below and in contact with it. It arises from the spinous processes of the four or five upper dorsal vertebrae and the supraspinous ligament, and is inserted into that part of the base of the scapula which is included between the spine and the inferior angle. A considerable part of the attachment at the insertion is only by firm connective tissue, and the greater portion of the fibres, instead

of being fixed directly to the bone, end in a tendon which is connected to the scapula near the lower angle; in consequence of this arrangement, the muscle may in part be separated from the bone without division of its



muscular or tendinous fibres, and must therefore act most immediately on the lower angle.

**Relations.**—The greater part of the rhomboidei muscles is covered by the trapezius, a small angular portion only of the rhomboideus major being subcutaneous in the interval

Fig. 227.—DEEPER VIEW OF THE MUSCLES OF THE TRUNK, SHOULDER AND HIP. (Allen Thomson, after Bourguery.)  $\frac{1}{2}$

The trapezius, latissimus dorsi, deltoid, gluteus maximus and external oblique muscles have been removed. The bones are lettered as in the preceding figure.

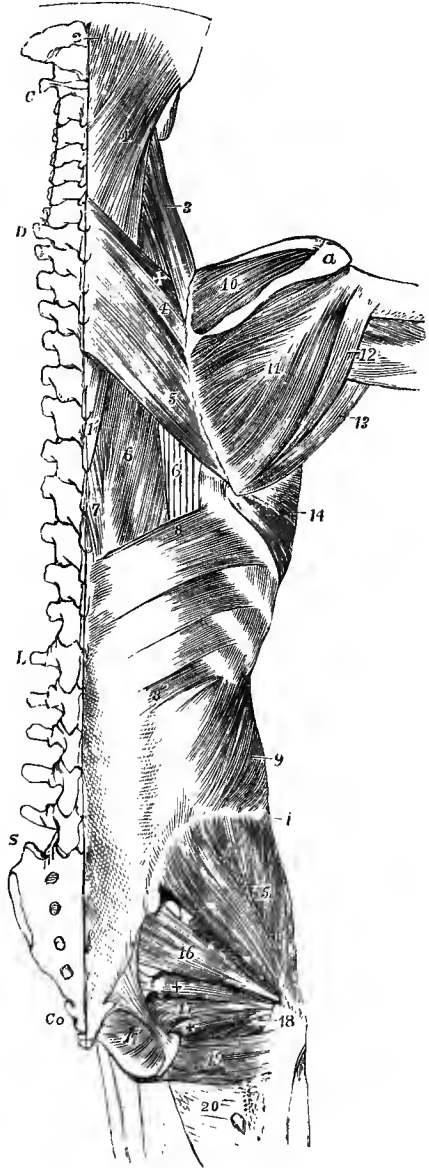
1, splenius capitis; 1', lower end of splenius colli; 2, complexus near its insertion; 3, levator anguli scapulæ; 4, rhomboideus minor; above it +, a part of the serratus posticus superior; 5, rhomboideus major; 6, part of the longissimus dorsi; 6', part of the tendons of insertion of the ilio-costalis; 7, part of the spinalis dorsi; 8, upper, and 8', lower part of the serratus posticus inferior; 9, internal oblique muscle; 10, supraspinatus; 11, infraspinatus; 12, placed upon the long head of the triceps, points to the teres minor; 13, teres major; 14, serratus magnus; 15, gluteus medius; 16, pyramidalis; 17, portion of the obturator internus; + and +, superior and inferior gemelli; 17', the intrapelvic portion of the obturator internus; 18, tendon of the obturator externus passing to its insertion; 19, quadratus femoris; 20, upper part of the adductor magnus.

between the trapezius and latissimus dorsi; the extent of this portion varies with the position of the scapula, being increased when the arm is raised from the side. The rhomboidei cover the greater part of the serratus posticus superior, and the posterior scapular artery descends on their deep surface.

**Varieties.**—Both rhomboid muscles are liable to variations in the extent of their vertebral and scapular attachments. The division between the two is often indistinct, and many authors describe the sheet as one muscle. An additional muscle has been observed running close to the upper border of the minor, from the scapula to the occipital bone, and has been called *rhomboides occipitalis* after a similar muscle occurring in some animals.

The **levator anguli scapulæ** arises by slightly tendinous slips from the posterior tubercles of the transverse processes of the four upper cervical vertebræ, between the attachments of the splenius and scaleni muscles, and forms an elongated fleshy mass which is inserted into the base of the scapula from the spine to the superior angle.

**Relations.**—The levator anguli scapulæ is covered at its origin by the sterno-mastoid, and at its insertion by the trapezius. Between these it is superficial in the posterior triangle of



the neck. It lies over the splenius colli, cervicalis ascendens, posterior scapular artery, and first two ribs.

**Varieties.**—The number of vertebral attachments of the levator anguli scapulæ is subject to frequent variations. A slip has been observed to extend to it from the occipital or from the mastoid process of the temporal bone. It often appears as a divided muscle, the parts connected with the several vertebræ remaining separate, even to the place of insertion. It is occasionally connected by slips with the trapezius, scalene, or serrated muscles, or sends a fasciculus to the first or second rib. In quadrupeds it is united with the serratus magnus, so as to form a single muscle. Appearing as a detached bundle of the levator anguli scapulæ, there is sometimes a muscular slip passing from the transverse processes of one or two upper cervical vertebræ to the outer end of the clavicle, and representing the *levator clavicular* muscle of the lower animals.

**Nerves of the preceding muscles.**—The trapezius muscle receives its nerves from the spinal accessory and from the third and fourth cervical nerves. The latissimus dorsi is supplied by the long subscapular nerve of the brachial plexus (7, 8 c).<sup>1</sup> The nerve of the rhomboid muscles proceeds from the fifth cervical, and the levator scapulæ is supplied from the third, fourth, and fifth cervical nerves.

#### BETWEEN THE TRUNK AND THE UPPER LIMB ANTERIORLY.

**FASCIÆ.**—The **superficial fascia of the pectoral region** encloses the mammary gland, covering it both in front and behind, and sending strong septa in between its lobes. Processes likewise extend forwards from the fascial investment of the gland, between the masses of fat, to the skin and nipple, thus affording support to the gland.

The **deep fascia of the pectoral region** is for the most part thin and unimportant. Covering the pectoralis major, it is attached above to the clavicle and internally to the front of the sternum, while externally and below it becomes continuous with the fascia of the shoulder, of the axilla, and of the side of the chest. As a development of the deep fascia there may be specially noticed the *costo-coracoid membrane*, which is a strong fibrous structure, placed behind the pectoralis major, and attached superiorly to the clavicle in two layers which ensheath the subclavius muscle, and the posterior of which is blended with the front of the sheath of the axillary vessels, derived from the deep fascia of the neck. The strong lower margin of the membrane, distinguished sometimes as the *costo-coracoid ligament*, extends from the coracoid process to the first rib at the origin of the subclavius muscle. From this membrane a thin lamina is prolonged downwards to the pectoralis minor, which it invests; and being continued beyond that muscle, it stretches across as a firm membrane between the pectoralis minor and the short head of the biceps, and ends below by joining the axillary fascia near the lower border of the pectoralis major.

The **axillary fascia** is a strong membrane stretched across the axilla, and so disposed as to maintain the skin in position over that hollow. Beginning at the lower border of the pectoralis major, where it is continuous with the fascia covering that muscle, it is joined by the layer descending from the pectoralis minor, and is by this means drawn upwards into the intermuscular space; thus strengthened it slopes outwards and backwards to the posterior fold of the axilla, where it is continued into the sheaths of the latissimus dorsi and teres major muscles. In the deepest part of the axilla the fascia is perforated by numerous lymphatic vessels. At the outer side, occupied by the large vessels and nerves of the limb, it is continuous with the sheath of the vessels and with the aponeurosis of the arm. The density of this fascia offers a considerable obstacle to the progress of axillary abscesses to the surface.

**MUSCLES.**—The **pectoralis major** muscle consists of two portions, *clavicular* and

<sup>1</sup> The numerals and initial letter indicate the nerves by which the motor fibres leave the spinal cord.

*sterno-costal*, which are separated at their origin by a slight interval opposite the sterno-clavicular articulation, but are united externally at the insertion of the muscle. The clavicular portion arises from an impression occupying the inner half of the anterior surface of the clavicle; the sterno-costal portion from the anterior surface of the sternum, from the cartilages of the upper six ribs, and from the aponeurosis of the external oblique muscle of the abdomen. The fibres of the two portions converge, and form a thick mass which is inserted by a tendon of considerable breadth into the pectoral ridge of the humerus. The tendon of insertion is composed of two layers, which are only united for a limited extent along their lower margins. The anterior layer is formed by the upper sterno-costal fibres, and is also joined on its front surface by the descending clavicular portion of the muscle, the latter being prolonged downwards beyond the level of the sterno-costal fibres and becoming closely united with the tendon of the deltoid. The posterior layer of the tendon is formed by the lower sterno-costal fibres, which turn backwards successively behind the upper part; this layer of the tendon reaches higher on the humerus than the anterior, and from its upper border an expansion is given off, covering the long head of the biceps muscle, to the great tuberosity of the humerus and the capsule of the shoulder-joint, while its deepest fibres are reflected inwards at their attachment to the bone, lining the bicipital groove, and meeting the insertion of the latissimus dorsi. From the lower border of the tendon also a slip is prolonged to the fascia of the arm.

**Relations.**—The folded inferior border of the pectoralis major forms the anterior margin of the axilla; the superior is nearly parallel to that of the deltoid muscle, the two being separated only by a slight interval which becomes wider towards the clavicle, and in which run the cephalic vein and the humeral branch of the acromio-thoracic artery. The anterior surface is subcutaneous in the greater part of its extent, being covered only by some of the fibres of the platysma myoides and by the mamma. The posterior surface rests chiefly on the pectoralis minor, and with that muscle forms the anterior wall of the axilla.

**Varieties.**—The more frequent varieties of this muscle consist in the greater or less extent of its attachments to the ribs or sternum, and the greater or less separation of its clavicular and sterno-costal parts. The clavicular part is occasionally incorporated completely with the deltoid. The tendinous and fleshy fibres of origin of opposite sides sometimes meet and even decussate in front of the sternum. In some instances additional muscular slips take origin from the aponeurosis of the external oblique muscle. Numerous cases are recorded of considerable deficiency or even absence of the sterno-costal portion. Absence of the clavicular part is less frequent. In rare cases the whole muscle has been wanting. The slips of connection with the latissimus dorsi have already been noticed.

*Costo-coracoideus.*—This is a muscular band springing from one or more of the ribs between the origins of the pectoralis major and latissimus dorsi, or from the aponeurosis of the external oblique, and inserted into the coracoid process, either separately, or in conjunction with the pectoralis minor or coraco-brachialis and biceps muscles. It may be represented by a fasciculus given off from the pectoralis major, or from the latissimus dorsi.

*Chondro-epitrochlearis.*—This name has been given to a muscular slip which is occasionally seen, springing from one or two rib-cartilages, or from the aponeurosis of the external oblique, below the pectoralis major, or sometimes given off from the lower border or from the tendon of the muscle itself, and passing to a variable insertion on the inner side of the arm, to the fascia, to the intermuscular septum, or even to the internal condyle of the humerus.

The *sternalis* muscle is a fasciculus not unfrequently present on one or both sides, fleshy in the middle and tendinous at both ends, lying on the surface of the pectoralis major, parallel to the margin of the sternum. It springs below, variably, from the sheath of the rectus and some of the costal cartilages between the third and seventh, and terminates above in the sterno-mastoid, or sternum and upper rib-cartilages, or more rarely in the pectoralis major. When two are present, they frequently unite in front of the manubrium. Its nervous supply is derived from the anterior thoracics, and in some cases also from the intercostals. The sternalis appears to be a displaced portion of the pectoralis major, which has undergone a rotation downwards and inwards. (D. J. Cunningham, Journ. Anat., xxii, 391.)

The **pectoralis minor** muscle arises from the upper margins and slightly from the external surfaces of three ribs near their cartilages—usually the third, fourth, and

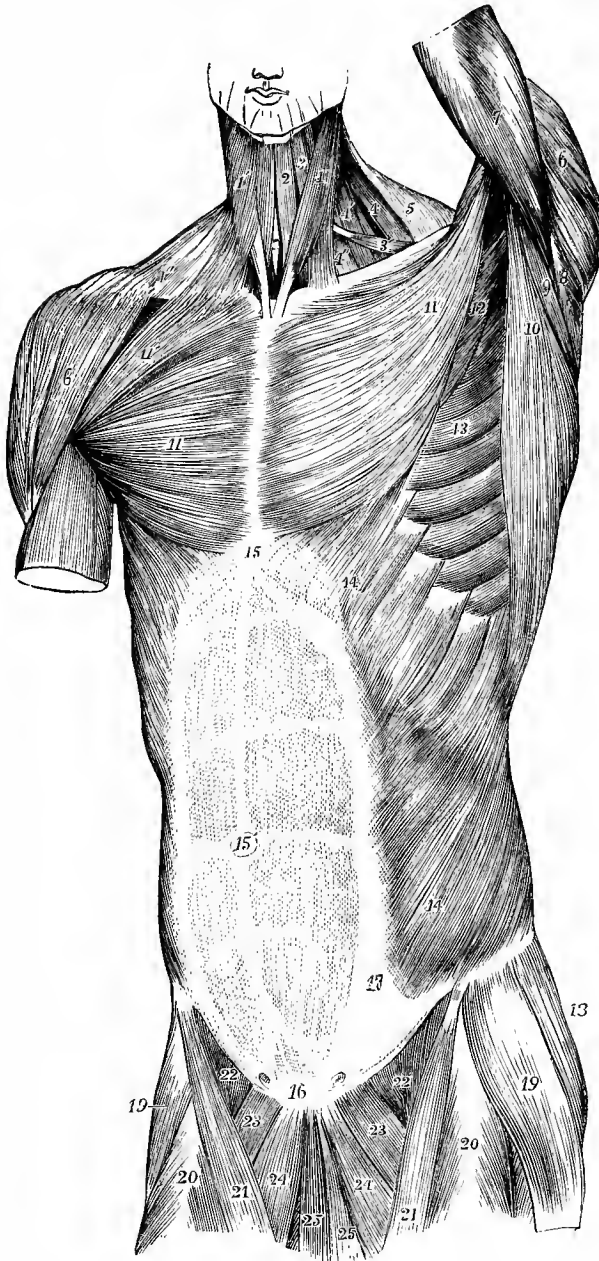


Fig. 228.—SUPERFICIAL VIEW OF THE MUSCLES OF THE TRUNK, FROM BEFORE.  
(Allen Thomson.)  $\frac{1}{2}$

1, sterno-mastoid of the left side ; 1', 1', platysma myoides of the right side ; 2, sterno-hyoid ; 3, anterior, 3', posterior belly of the omo-hyoid ; 4, levator anguli scapulae ; 4', 4'', scalene muscles ; 5, trapezius ; 6, deltoid ; 7, upper part of triceps in the left arm ; 8, teres minor ; 9, teres major ; 10, latissimus dorsi ; 11, pectoralis major ; 11', on the right side, its clavicular portion ; 12, part of pectoralis minor ; 13, serratus magnus ; 14, external oblique muscle of the abdomen ; 15, placed on the ensiform process at the upper end of the linea alba ; 15', umbilicus ; 16, is placed over the symphysis pubis, at the lower end of the linea alba ; above 16, the pyramidal muscles are seen through the abdominal aponeurosis ; 14 to 17, linea semilunaris at the outer border of the rectus muscle, the transverse

tendinous lines of which are seen through the abdominal aponeurosis; 18, gluteus medius; 19, tensor vaginae femoris; 20, rectus femoris; 21, sartorius; 22, femoral part of the ilio-psoas; 23, pectineus; 24, adductor longus; 25, gracilis. On each side of 16, the external abdominal ring is indicated.

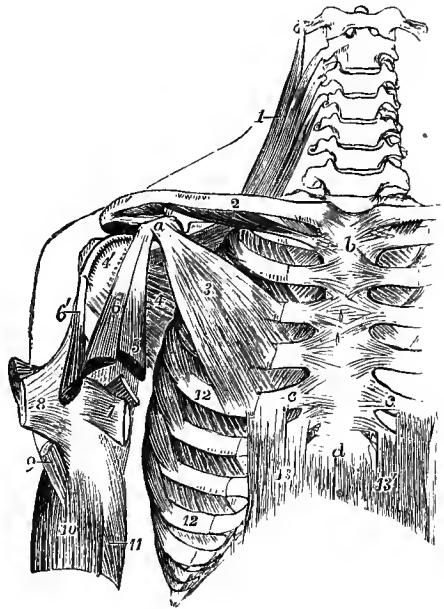
fifth—by tendinous slips which are blended with the anterior intercostal aponeuroses. Its fibres converge to a narrow tendon, which is inserted into the anterior half of the inner border and upper surface of the coracoid process, in contact with the conjoined origin of the coraco-brachialis and biceps muscles.

**Relations.**—This muscle is covered by the pectoralis major, and forms a part of the anterior wall of the axilla. It crosses the axillary vessels and brachial plexus of nerves. When the arm is much raised, a portion of the muscle may be seen projecting beyond the lower margin of the pectoralis major.

**Varieties.**—The pectoralis minor is sometimes found split up or subdivided into as many pieces as it has costal attachments. The place and number of the costal slips are subject to

Fig. 229.—VIEW OF SOME OF THE DEEPER MUSCLES OF THE SHOULDER AND TRUNK, FROM BEFORE. (Allen Thomson.)  $\frac{1}{2}$

On the right side the pectoralis major and external oblique muscles have been removed. *a*, coracoid process; *b*, manubrium; *c*, *c*, cartilages of the fifth ribs; *d*, ensiform process; 1, levator anguli scapulae muscle; 2, on the middle of the clavicle, points to the subclavius muscle; 3, pectoralis minor; 4, subscapularis; 4', its insertion into the small tuberosity of the humerus; 5, coraco-brachialis cut short; 6, coracoid, and 6', glenoid head of the biceps brachii, both cut short; 7, on the tendon of the latissimus dorsi, points by a line to the tendon of the teres major, both cut short and passing to their insertion inside the bicipital groove; 8, folded tendon of the pectoralis major; 9, insertion of the deltoid; 10, brachialis anticus, embracing the insertion of the deltoid; 11, part of the inner head of the triceps, the middle head of which is seen passing behind the tendons of the latissimus and teres; 12, 12, on the fifth and eighth ribs, point to the origin of the serratus magnus; 13, 13', recti abdominis.



slight variation. The tendon of insertion is not unfrequently continued in part or wholly over the coracoid process, from

which it is separated by a bursa, and through the coraco-acromial ligament to the capsule of the shoulder and the great tuberosity of the humerus: this condition is usual in apes. The humeral insertion of the tendon is represented normally by the coraco-humeral ligament (p. 167). The insertion of the pectoralis minor is often connected by aponeurosis with the upper part of the coraco-brachialis; and the two may be more closely united, so that there is only a tendinous intersection between their fibres. Absence of the muscle has been observed, generally in association with defect of the pectoralis major.

The *pectoralis minimus* is a rare supernumerary muscle, extending from the first rib-cartilage to the coracoid process.

The **subclavius** muscle arises by a short thick tendon from the first costal arch at the junction of the rib and cartilage, close in front of the costo-clavicular ligament. From this tendon its fibres pass outwards and upwards, forming a prismatic belly, which is inserted into the groove on the under surface of the clavicle, extending as far as the recess between the conoid and trapezoid parts of the coraco-clavicular ligament.

**Relations.**—The subclavius is encased by the costo-coracoid membrane, and is placed immediately over the great vessels and nerves entering the limb.

**Varieties.**—The subclavius is sometimes found to be without any attachment to the

clavicle, being inserted into the root of the coracoid process; or it may have a double insertion, the upper into the clavicle, the lower into the coracoid process. A part of this muscle, or occasionally an independent fasciculus, may be inserted into the upper border of the scapula, constituting the *sterno-scapular* muscle.

The *sterno-clavicularis* extends from the front of the manubrium to the clavicle between the pectoralis major and costo-coracoid membrane. Intermediate forms between this and the pectoralis minimus (p. 211) are also met with. Similar muscles on the two sides have been seen united by a median tendon in front of the manubrium, thus giving rise to a digastric *interclavicular* muscle.

The **serratus magnus** muscle, placed upon the upper and lateral part of the thorax, between the ribs and the scapula, arises anteriorly from the first eight or nine ribs by as many fleshy slips or digitations, each digitation being attached to the fore part of the outer surface of the corresponding rib, with the exception of the

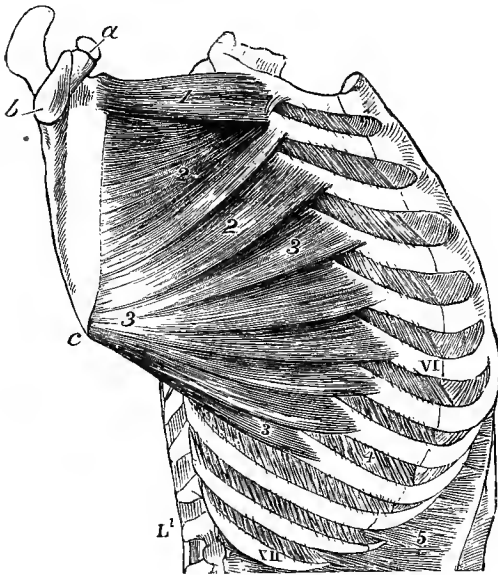


Fig. 230.—LATERAL VIEW OF THE THORAX, SHOWING THE SERRATUS MAGNUS MUSCLE. (Allen Thomson.)  $\frac{1}{2}$

*a*, coracoid process of the scapula; *b*, glenoid cavity; *c*, lower angle; I, VI, XII, first, sixth, and twelfth ribs; 1, upper portion of the serratus magnus attached to the first and second ribs; 2, 2, second or middle portion attached to the second and third ribs; 3, lower or fan-shaped portion attached to the ribs from the fourth to the ninth; 4, external intercostal muscle; 5, costal origins of the transversalis abdominis.

first, which is attached to two ribs. Posteriorly, the muscle, considerably narrowed, is inserted into the line in front of the base of the scapula, and at the upper and lower angles of the bone into the flat surfaces which are excluded from the fossa of the subscapular muscle. The fibres are arranged in three sets, thus:—

*a*, those of the first digitation, springing from the first and second ribs and an intervening aponeurotic arch, form a thick bundle which terminates on the flat area in front of the upper angle of the scapula; *b*, those of the second and third digitations, from the second and third ribs, but especially the first of these, spread out into a triangular layer, the thinnest part of the muscle, and are attached along the line in front of the base of the scapula, extending from the place of insertion of the preceding part nearly to the lower angle of the bone; *c*, the remaining five or six digitations converge in the form of a fan, and terminate posteriorly in a thick mass, which is attached to the flat surface in front of the lower angle of the scapula.

**Relations.**—By its deep surface, the serratus magnus rests on the upper ribs, the intercostal muscles, and part of the serratus posticus superior. Its outer surface is in contact posteriorly with the subscapular and latissimus dorsi muscles, and forms anteriorly the internal wall of the axilla, being subcutaneous in the lower part of its extent.

**Varieties.**—Not unfrequently the muscle receives a slip also from the tenth rib: on the other hand, the highest digitation often has no attachment to the first rib; or one or more of the lower digitations may be absent, so that the muscle does not pass lower than the seventh rib. The muscle has been observed divided into three parts; sometimes the middle part is defective; and in various instances the serratus has been observed united partially with the

levator scapulæ, the external intercostals, or the external oblique. With the levator scapulæ it forms one muscle in many mammals.

**Nerves.**—The nerves which supply the anterior muscles passing from the trunk to the upper limb are all derived from the brachial plexus. The nerve of the subclavius is a small twig from the trunk formed by the fifth and sixth cervical nerves. The large nerve of the serratus magnus, called posterior thoracic, proceeds from the fifth, sixth, and generally also the seventh nerves: the upper division of the muscle is supplied from the fifth nerve; the middle division from the sixth, sometimes also the fifth; and the lower division from the sixth and seventh. The nerves of the pectoral muscles are the two anterior thoracics from the inner and outer cords of the plexus: the clavicular part of the pectoralis major is supplied from the fifth and sixth cervical, the sterno-costal from the lower four cervical and the first dorsal nerves, the upper fasciculi from the higher nerve and *vice versâ*: the pectoralis minor receives its fibres from the seventh and eighth cervical and first dorsal nerves. (On the nerves supplying the muscles of the upper extremity, see W. P. Herringham, Proc. Roy. Soc., xli. 423.)

**Actions of the muscles passing between the trunk and upper limb.**—Considered with reference to the movements of the limb upon the trunk, it is to be observed that the muscles passing to the scapula are so disposed that each one, while drawing that bone in a definite direction over the thorax, also tends to impart to it a movement of rotation, and that in order to produce the simple gliding movements, upwards and downwards, forwards and backwards, various combinations are necessary, as is explained in detail below.

The superior fibres of the *trapezius* elevate the clavicle and scapula; the middle fibres acting on the acromion have also some elevating action, but tend rather to carry back the scapula towards the spine; the inferior part of the muscle acting upon the spine of the scapula would of itself depress that bone while it carries it inwards towards the dorsal spines, but acting in concert with the upper two-thirds of the muscle, a rotation is produced in the scapula round a central point, in such a manner that while the acromion is somewhat raised and carried towards the dorsal spines, the upper angle of the scapula is depressed, and the lower angle is carried outwards and elevated.

The *levator anguli scapulæ* and *rhomboidei* elevate the superior angle and base of the scapula, thus counteracting the rotating action of the trapezius. By their action, in combination with the upper fibres of the trapezius, the scapula is raised without rotation, while the middle and lower portions of the trapezius with the rhomboidei draw the scapula backwards and inwards, towards the dorsal spines. The rhomboidei muscles are the special antagonists of the serratus magnus.

The *subclavius* depresses the clavicle, and may also act as a support to the sterno-clavicular articulation.

The *pectoralis minor* draws the coracoid process downwards and forwards, and tends to throw the lower angle of the scapula backwards. It acts with the serratus magnus in drawing forwards the scapula, with the subclavius and lower part of the trapezius in depressing the shoulder, and with the levator and rhomboidei in producing downward rotation of the scapula when the arm is brought to the side.

The *serratus magnus* muscle, by withdrawing the base of the scapula from the spinal column, enables the arm when raised from the shoulder to be still farther outstretched, as in the movement termed extension in fencing: it comes powerfully into action in all movements of pushing. Its lower portion likewise combines with the trapezius in rotating the scapula upwards in elevation of the arm.

The *latissimus dorsi* carries the elevated arm downwards and backwards, rotating it at the same time inwards. Acting through the humerus, it also assists in drawing the shoulder downwards and backwards.

The *pectoralis major*, while it combines with the latissimus dorsi in depressing the humerus from the abducted position, opposes that muscle by drawing the limb forwards. The lower part of the muscle acts most efficiently in adducting, the succeeding fasciculi draw the arm more forwards, and the clavicular portion is mainly a flexor of the shoulder-joint, raising the arm in a direction forwards and inwards.

Considered as acting on the trunk from the upper limb in a fixed condition, these muscles all tend to draw the trunk of the body towards the limb, as in climbing, or other like efforts. The latissimus dorsi muscles carry the body upwards and forwards, as in the use of crutches. The pectorales are also muscles of forced inspiration, tending to raise the ribs, more especially when the shoulders are fixed and the arms are elevated; and it is thought by some that the lowest slips of the serratus magnus may have a similar action when the scapula is fixed by the muscles passing to it from the spine posteriorly and superiorly. The upper parts of both trapezii acting on the occipital bone aid in extending the head on the vertebral column; and if one muscle only acts, it aids in rotating the head.

## THE MUSCLES AND FASCIAE OF THE SHOULDER.

**FASCIAE.**—The **deep fascia** binds together the muscles of the shoulder with considerable firmness, and over the back part of the deltoid and infraspinatus muscles assumes a tendinous appearance. A strong and somewhat isolated portion, bound down to the vertebral and axillary margins of the scapula, covers the infraspinatus and teres minor muscles as far as they are left uncovered by the deltoid. On reaching the posterior border of the deltoid muscle, this aponeurosis divides into two layers, of which the deeper is continued beneath the deltoid to the shoulder-joint, and the more superficial forms the thin aponeurotic covering of that muscle, becoming more and more slender as it passes forwards, and is attached to the lower border of the spine.

**MUSCLES.**—The **deltoid** muscle is of a triangular form and coarsely fasciculated, and extends from the most prominent part of the shoulder downwards for half the length of the upper arm. It takes origin in an extended line which may be divided into three portions, viz., an anterior from the front of the external third of the clavicle, a middle from the point and outer edge of the acromion, and a posterior from the lower border of the spine of the scapula as far back as the triangular surface at its inner end. The fasciculi from these several parts converge as they descend, and are inserted by a strong thick tendon into the deltoid eminence on the outer side of the humerus.

The three parts composing the deltoid muscle differ in the disposition of their muscular fasciculi and tendons. The anterior and posterior portions are composed of parallel fasciculi which, arising from the clavicle by short tendinous fibres, and by longer ones from the spine of the scapula, are inserted into the outer surface of the marginal parts of the inferior tendon. In the acromial portion, while some of the muscular fibres spring directly from the bone, yet most of them arise in a penniform manner from the sides of three or, more frequently, four tendinous septa, which pass downwards into the substance of the muscle. These oblique fibres, running nearly parallel to each other, are inserted in a similar manner into the sides of two or, more frequently, three septa which pass from below upwards and alternate with the upper septa. The oblique fibres from the outside of the first and fourth upper septa are inserted into the marginal parts of the main tendon. There are besides wedge-shaped bundles of muscular fibres, arising directly from the acromion in the intervals between the penniform bundles, which are inserted into the tips of the lower tendinous septa, and others which, springing from the ends of the upper tendinous septa, are directly inserted into the humerus between the lower septa. The main tendon of insertion spreads from below upwards for some distance on the deep surface of the muscles.

**Relations.**—The anterior border of the deltoid is in contact with the pectoralis major below, but separated from it by a small interval above: the cephalic vein, with a small artery, lies between the two muscles. In contact with the deep surface is the large bursa which separates this muscle and the acromion from the shoulder-joint and the muscles supporting it. The deltoid muscle covers the origins of the biceps and coraco-brachialis, the insertions of the supraspinatus, infraspinatus and teres minor muscles, and parts of the long and outer heads of the triceps, as well as the circumflex vessels and nerve.

**Varieties.**—The deltoid muscle is not subject to great varieties. One of the commonest is a greater degree of subdivision of its parts than usual. Another is the continuation into it of fibres from the trapezius, as in animals wanting the clavicle. Occasionally the anterior part is closely united in its whole length with the great pectoral muscle. Additional slips have been observed springing from the vertebral border of the scapula, from the infraspinous fascia, and from the axillary border of the scapula, and joining the hinder part of the muscle, or expanding in the fascia covering it. Its insertion varies sometimes in extent. A remarkable prolongation of its tendon on the radial border of the forearm, as far as the insertion of the supinator longus, seems to repeat the tensor plicæ alaris of the bird (Macalister).

The **supraspinatus** muscle arises from the supraspinous fossa of the scapula to within a short distance of the neck of the bone, and from an aponeurosis by which it is covered. Its fibres converge beneath the acromion to a tendon, which adheres to the capsule of the shoulder-joint and to the tendon of the infraspinatus



Fig. 231. — SUPERFICIAL MUSCLES OF THE SHOULDER AND UPPER LIMB, FROM BEFORE. (Allen Thomson.)  $\frac{1}{2}$

1, pectoralis major, its sterno-costal portion; 1', its clavicular portion; 2, deltoid, its clavicular part; 2', its acromial part; 3, biceps brachii; 3', its tendon of insertion; 3'', its aponeurotic slip; 4, brachialis anticus; 4', its inner and lower portion; 5, long head of the triceps; 5' inner head of the same, seen arising from behind the intermuscular septum. The explanation of the remaining references will be found in the description of fig. 235.

muscle, and is inserted into the upper of the three facets on the great tuberosity of the humerus.

The **infraspinatus** muscle is of a triangular form, and occupies the greater part of the infraspinous fossa. It arises from the fascia covering it, from the under surface of the spine, and from the inner two-thirds of the dorsal surface of the scapula in the fossa, except those parts at the lower angle and along the axillary border, to which the *teres* muscles are attached. The fibres converge to a tendon which, concealed at first within the substance of the muscle, is inserted into the middle facet of the great tuberosity of the humerus.

**Relations.**—The *supraspinatus* muscle is covered by the trapezius and the acromion process. The suprascapular nerve and vessels pass beneath it.

The *infraspinatus* muscle is bound down by the aponeurosis which superiorly and externally divides so as to enclose the deltoid muscle. It is covered by the deltoid at its upper and outer part, by the trapezius at its upper and inner part, and by the *latissimus dorsi* at its lower angle; in the intermediate portion it remains superficial. A small bursa is sometimes present between the tendon and the capsule of the shoulder-joint.

**Varieties.**—The *supraspinatus* is very constant in its form and attachments. A slip has been seen passing from its tendon to the tendon of the *pectoralis major* and the pectoral ridge of the humerus. The *infraspinatus* muscle is sometimes inseparably united with the *teres minor*.

The **teres minor** muscle is placed along the lower border of the *infraspinatus*, and is intimately connected with that muscle. It arises from a narrow obliquely grooved surface on the dorsum of the scapula close to the axillary border, and from aponeurotic septa

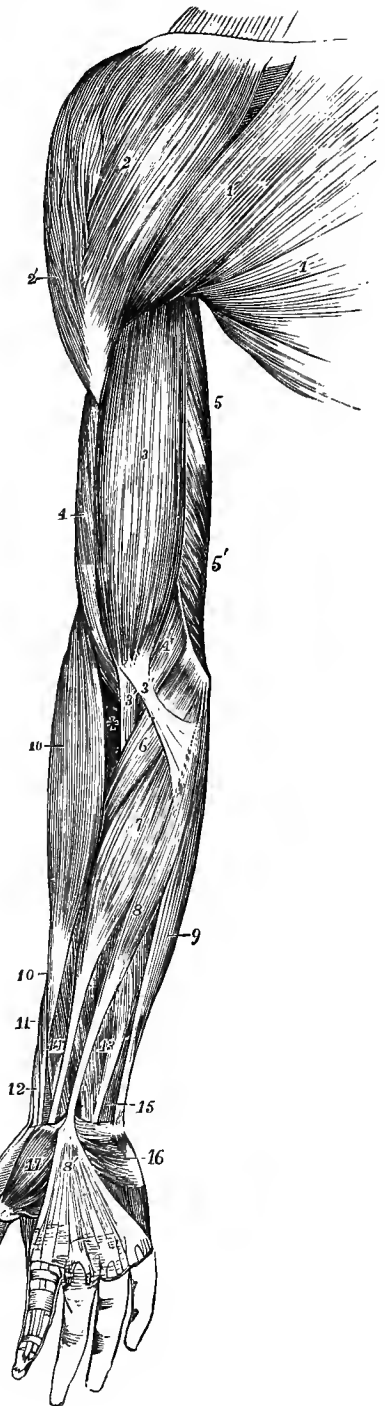
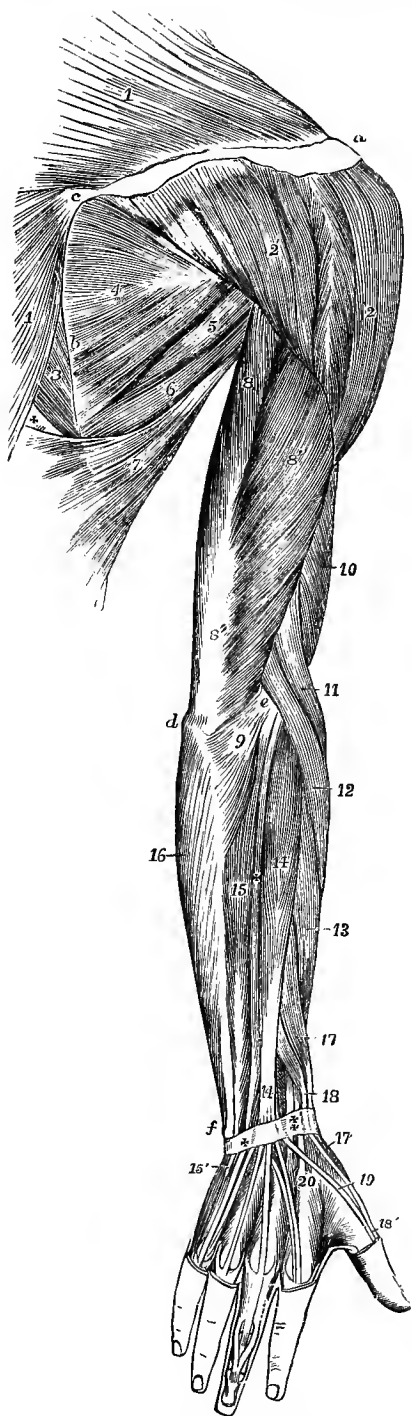


Fig. 232.—SUPERFICIAL MUSCLES OF THE SHOULDER AND UPPER LIMB, SEEN FROM BEHIND. (Allen Thomson.)  $\frac{1}{2}$



*a*, acromion; *b*, base of the scapula; *c*, tendon of the trapezius muscle over the triangular surface of the spine of the scapula; *d*, olecranon; *e*, external condyle; 1, trapezius; 2, acromial part of deltoid; 2', the part of the same muscle rising from the spine of the scapula; 3, rhomboideus major; 4, infraspinatus; 5, teres minor; 6, teres major; 7, latissimus dorsi; +, space between the trapezius, rhomboid and latissimus muscles; 8, long head of triceps; 8', its outer head; 8'', its tendon; 9, anconeus; 10, part of the brachialis anticus; 11, supinator longus; 12, extensor carpi radialis longior. The explanation of the remaining references will be found in the description of fig. 238.

between it and the infraspinatus and teres major muscles, and is inserted by tendon into the greater tuberosity of the humerus, immediately below the infraspinatus, and by fleshy fibres into the bone for a short distance lower down.

**Relations.**—This muscle is partly covered behind by the deltoid, and in front is in contact with the long head of the triceps and the capsule of the shoulder-joint. The dorsal scapular artery passes between it and the bone. At its lower border is the teres major, separated in part by the long head of the triceps. A bursa is sometimes found between the tendon and the bone.

The **teres major** muscle arises from the flat oval surface on the dorsum of the scapula near its inferior angle, slightly from the axillary border of the bone, and from the septum between it and the teres minor and infraspinatus muscles. It is inserted by a flat tendon, about two inches wide, into the inner border of the bicipital groove of the humerus, behind and in contact with the tendon of the latissimus dorsi, to which it is adherent for a short space: close to the insertion, however, the tendons of these muscles are separated by a small bursa. There is sometimes another bursa between the tendon of the teres major and the humerus. The fibres run longitudinally in the muscle.

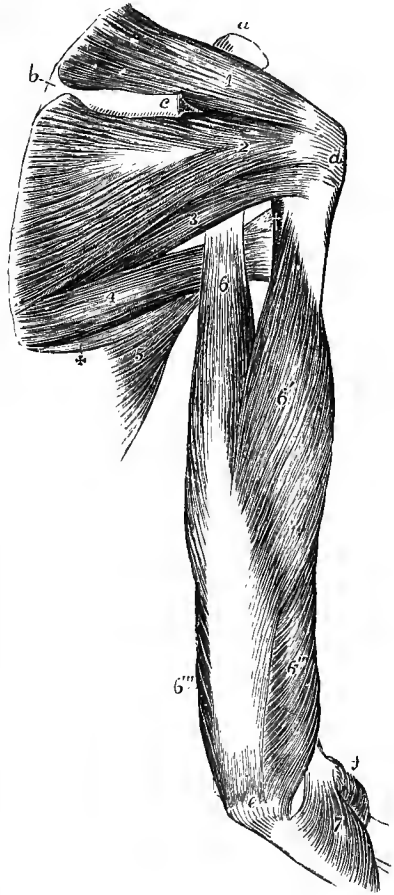
**Relations.**—Posteriorly this muscle is covered at its lower part by the latissimus dorsi, and at its upper part it is crossed by the long head of the triceps. The lower border is surrounded obliquely by the latissimus dorsi; and the anterior surface is concealed in the upper part of its extent by the tendon of that muscle. The upper border of the muscle forms the

margin of a triangular space, of which the other sides are the upper part of the humerus, and the axillary border of the scapula, covered before by the subscapular and behind by the teres minor muscles; this triangle is divided by the long head of the triceps into an external, quadrilateral, and an internal, triangular compartment. Through the quadrilateral space pass backwards the posterior circumflex vessels and the circumflex nerve; and in the triangular subdivision the dorsal branch of the subscapular artery passes round the margin of the scapula into the infraspinous fossa.

**Varieties.**—The teres major muscle is sometimes found connected with the fasciculus of the latissimus dorsi arising from the same part of the scapula. A slip from this muscle has been observed joining the long head of the triceps, and also one descending upon the fascia of the upper arm externally.

Fig. 233.—MUSCLES OF THE RIGHT SHOULDER AND ARM, SEEN FROM BEHIND. (Allen Thomson.)  $\frac{1}{4}$

The acromion process and a part of the spine of the scapula, with the deltoid muscle, have been removed. *a*, coracoid process; *b*, triangular surface at the root of the spine; *c*, is close to the cut portion of the spine; *d*, great tuberosity; *e*, olecranon; *f*, is close to the external condyle and head of the radius; 1, supraspinatus; 2, infraspinatus; 3, teres minor; below the figure is the triangular space; 4, teres major; 5, part of latissimus dorsi; +, slip from the inferior angle of the scapula; †, on the edge of the humerus, points to the tendon of the latissimus dorsi and the quadrangular space; 6, scapular head of the triceps, passing above between the teres major and minor; 6', external head; 6'', part of the muscle arising below the spiral groove, belonging to the internal head; 6''', inner part of the internal head; 7, anconeus.



The **subscapularis** muscle (fig. 234, 5) arises partly by muscular and partly by tendinous fibres from the venter of the scapula, with the exception of the neck and the spaces occupied by the serratus magnus, but including the groove along the axillary border of the bone. The greater number of its fibres unite into a broad tendon which is inserted into the impression on the small tuberosity of the humerus; some of the lower fibres, however, are directly inserted into the bone for a short distance farther down. Three or four tendinous septa, attached to the ridges of the subscapular fossa, pass outwards in the origin of the muscle, others are prolonged inwards from the tendon of insertion, and fleshy fasciculi pass obliquely between the two sets.

**Relations.**—The tendon of the subscapularis is incorporated with the capsule of the shoulder-joint, and between its upper border and posterior surface, and the coracoid process and neck of the scapula is a bursa usually communicating with that joint. There is sometimes another bursa intervening between the anterior surface of the muscle and the upper ends of the biceps and coraco-brachialis muscles. Anteriorly the muscle is in contact at its origin with the serratus magnus, and is covered at its insertion by the coraco-brachialis and biceps, while in the interval between it forms part of the posterior wall of the axilla.

**Varieties.**—The varieties hitherto observed in this muscle are not considerable. A small additional muscle is sometimes found, passing from the upper part of the axillary border of the scapula to be inserted, at the lower margin of the subscapularis, into the capsular liga-

ment, or into the humerus near the inner margin of the bicapital groove, the *subscapulo-capsularis* or *subscapularis minor*.

**Nerves.**—The *supraspinatus* and *infraspinatus* muscles receive their nerves from the suprascapular branch which proceeds from the fifth and sometimes the sixth cervical nerves. The other muscles of this group are all supplied with nerves from the posterior cord of the brachial plexus, as follows: the *deltoid* (5, 6 c) and *teres minor* (5 c) through the circumflex nerve, the *subscapularis* (5, 6 c) through the upper and lower subscapular nerves, and the *teres major* (6, 7 c) through the lower subscapular nerve.

**Actions.**—The acromial portion of the *deltoid* raises the arm from the side, abducting the humerus as far as the structure of the shoulder-joint permits, viz., through about 90°. It is associated in its action with the *serratus magnus* and *trapezius*, which rotate the scapula upwards at the same time; and it may be remarked that the insertion of the latter muscle corresponds almost exactly in extent to the origin of the *deltoid*, so that the two muscles may be considered continuous in structure as well as in action. The anterior part of the *deltoid* combines with the *pectoralis major* to draw the humerus forwards; the posterior assists in drawing it backwards. The *supraspinatus*, *infraspinatus* and *subscapularis* muscles being placed more closely round the joint, when acting in concert with the *deltoid*, probably give steadiness and precision, while the *deltoid* gives the main elevating force to the movement. The *supraspinatus* simply abducts: the *infraspinatus* and *subscapularis* carry the arm backwards or forwards when it is raised, and rotate it outwards or inwards when hanging by the side. The *teres major* rotates the raised humerus inwards, the *teres minor* outwards; acting together, they assist in depressing the arm. The *deltoid* muscle superficially, and the *supra-* and *infraspinatus* muscles, the *teres minor* and *subscapularis*, more deeply, afford important protection to the shoulder-joint, and by their tension prevent displacement of the head of the humerus.

#### THE MUSCLES AND FASCIÆ OF THE UPPER ARM.

**FASCIÆ.**—The **aponeurosis of the arm** is composed chiefly of transverse fibres, held together by others having an oblique or longitudinal direction; it is thin over the *biceps* muscle, stronger where it covers the *triceps*, and particularly dense as it approaches the outer and inner condyles of the humerus. It is pierced on the inner side of the limb by the *basilic vein*, close below the middle of the arm. It is attached to the condyles and supracondylar ridges of the humerus by the two processes next to be described.

The **external** and **internal intermuscular septa** are two fibrous partitions which bind the aponeurosis of the arm to the humerus, and with which the neighbouring muscles of the arm are intimately connected. The external intermuscular septum extends upwards from the outer condyle along the outer supracondylar ridge to the hinder part of the insertion of the *deltoid*, from which it receives tendinous fibres. It is pierced from behind forwards by the *musculo-spiral nerve* and *superior profunda artery*. The internal septum, much stronger, extends along the line from the inner condyle to behind the insertion of the *coraco-brachialis* muscle. It is pierced near the elbow, from before backwards, by the anastomotic branch of the *brachial artery*. The *internal brachial ligament* of Struthers<sup>1</sup> is a fibrous band connected with the internal intermuscular septum, which extends from the inner side of the humerus, below the insertion of the *teres major*, to the internal condyle. The *ulnar nerve* and *inferior profunda artery* pass backwards between this band and the intermuscular septum.

At the level of the elbow the aponeurosis is closely united to the periosteum covering the subcutaneous parts of the bones, viz., the condyles of the humerus and the olecranon process of the ulna; and it is strengthened in front and behind by tendinous fibres sent from the *biceps* and *triceps* muscles. There is generally a bursa in the subcutaneous tissue over the olecranon, and occasionally one over the internal condyle. A bursa over the external condyle is of rare occurrence.

**MUSCLES.**—The **coraco-brachialis** muscle, elongated in form, arises from the tip of the coracoid process of the scapula, between the *pectoralis minor* and the short

<sup>1</sup> "Anatomical and Physiological Observations," 1854, p. 208.

head of the biceps, with which latter it is for some distance conjoined in a common tendon. The lower end of the muscle is inserted into the inner border of the humerus near its middle, on a linear impression of from one to two inches in length, between the origins of the triceps and the brachialis anticus. Higher up, some of its fibres are frequently inserted into a fibrous band which is prolonged upwards, forming an arch over the latissimus dorsi and teres major tendons, to be attached to the humerus close below the small tuberosity.

**Relations.**—This muscle is usually pierced by the musculo-cutaneous nerve; its outer border is overlapped by the biceps muscle, and its inner is in contact with the brachial artery, by which it is crossed obliquely near its insertion. It lies in front of the tendons of the subscapularis, latissimus dorsi, and teres major, and is covered in great part by the deltoid and pectoralis major muscles.

**Varieties.**—This muscle is subject to considerable varieties, which seem to indicate, according to Wood, that it consists typically of three parts, viz., 1, a superior short one arising from the coracoid process, or near it, and running over the subscapularis muscle, to be inserted close below the small tuberosity of the humerus; 2, a middle part corresponding most nearly to that usually described in human anatomy, of intermediate size, and placed between the first and third; 3, an inferior part, which is the longest and most superficially placed, and descends to the inner condyle, or near it, and in many instances is inserted into a supracondylar process. The middle division of the muscle is most constant in man, but is generally accompanied by a part of the third, the musculo-cutaneous nerve passing between them. The first and third constitute the most marked varieties in man, and all three are found in various forms and degrees of development in different animals. The innermost fibres of the muscle are sometimes inserted into the internal intermuscular septum, or the internal brachial ligament; and a fasciculus has been observed joining the inner head of the triceps. (Wood, Journ. Anat., i. 45.)

The **biceps flexor cubiti** muscle has two heads of origin: one of these, the *internal* or *short head*, arises conjointly with the coraco-brachialis from the coracoid process of the scapula by a tendon which is soon continued into muscle; the other, the *long head*, arises from the scapula at the upper end of the glenoid cavity, within the capsule of the shoulder-joint, by a rounded tendon which is continuous on each side with the glenoid ligament; and this tendon, passing over the head of the humerus, leaves the joint by the bicipital groove, gradually enlarging into the fleshy head as it descends. The two muscular heads meet, and becoming closely applied together, form an elongated and thick belly, occupying the middle and lower parts of the arm: a little above the bend of the elbow, the muscle suddenly becomes narrower, and is continued into the thick tendon of insertion. This tendon, slightly twisted upon itself as it descends, is inserted into the rough posterior portion of the tuberosity of the radius, being separated from the anterior smooth surface of that process by a synovial bursa. There is often a second bursa on the inner side of the tendon, between it and the bicipital hollow of the ulna. From the inner side of the tendon and lower part of the muscle a strong flat aponeurotic band, called the *semilunar fascia*, passes downwards and inwards, and becomes blended with the deep fascia of the forearm over the muscles arising from the internal condyle.

**Relations.**—Concealed above by the deltoid and pectoralis major muscles, the fleshy belly of the biceps forms in the rest of its extent the prominence of the front of the arm. It lies in its upper part on the humerus, and in its lower on the brachialis anticus; by its inner margin it is in contact in its upper half with the coraco-brachialis, and in its lower with the brachial artery. Its inferior tendon passes backwards between the supinator longus and pronator teres muscles, and the semilunar fascia is stretched across the brachial vessels and median nerve.

**Varieties.**—The biceps is one of the most variable muscles in the body. The commonest variety is the occurrence of a third head (10 per cent.), which arises from the humerus in more or less close connection with the brachialis anticus and the insertion of the coraco-brachialis, and is inserted into the coracoid portion of the muscle and the semilunar fascia: this head lies generally on the outer side of the brachial artery, but has sometimes been found covering the vessels. Less frequently an additional head springs from the outer side of the

humerus, from the bicipital groove, or from the great tuberosity. In rarer cases two supplementary heads are present, arising from different parts of the humerus; and in a few instances three supplementary heads have been seen, making a five-headed muscle. Occasionally a fleshy slip is given off from the inner border of the muscle to the internal intermuscular septum, or to the internal condyle, passing over the brachial artery; and fasciculi have been seen passing to the pronator teres and to the brachialis anticus. In a few cases absence of the long head has been observed; in others this head has been found to be attached in the bicipital groove, not extending to the scapula.

The long head of the biceps was originally extra-articular, and its position within the joint has been acquired by a gradual sinking through the capsule, various stages of which

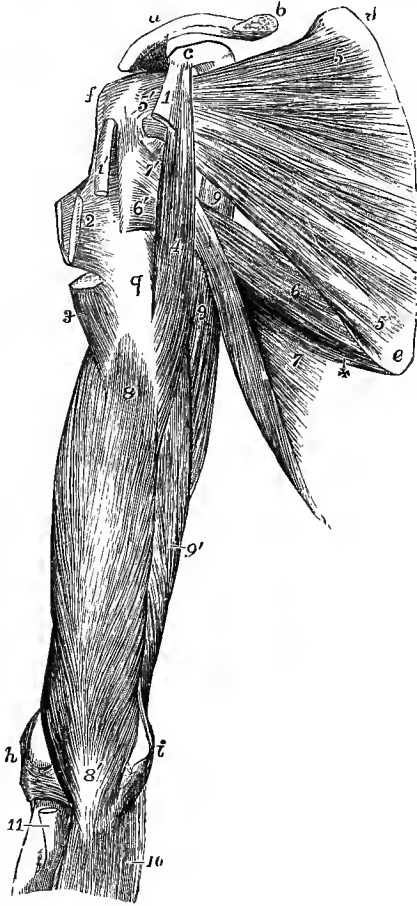


Fig. 234.—DEEP VIEW OF THE MUSCLES OF THE RIGHT SHOULDER AND ARM, FROM BEFORE. (Allen Thomson.)  $\frac{1}{2}$

*a, b*, outer half of the clavicle; *c*, coracoid process; *d* and *e*, triangular spaces at the upper and lower angles of the scapula on its anterior surface to which the serratus magnus is attached; *f*, great tuberosity; *g*, surface of the humerus below the bicipital groove; *h*, outer, and *i*, inner condyle; 1, cut coracoid head, and 1', cut glenoid tendon of the biceps muscle; 2, double tendon of insertion of the pectoralis major, from which a prolongation is seen running up to the capsule of the shoulder; 3, insertion of the deltoid; 4, coraco-brachialis; 5, 5', subscapularis; 5', its insertion into the small tuberosity; 6, teres major; 6', its insertion behind and below the latissimus dorsi; 7, part of the latissimus dorsi; +, slip from the inferior angle of the scapula; 7', insertion of the tendon, after winding round the teres major, in front of and higher than that muscle; 8, 8', brachialis anticus; 9, 9', long head of the triceps, at the upper part seen in the interval between the teres major and subscapularis muscles; 9', inner head; 10, flexor profundus digitorum; 11, tendon of insertion of the biceps.

are represented by the condition in different animals. At the same time it has become covered over by the coraco-humeral ligament derived from the tendon of the pectoralis minor. In the human foetus of the third month the tendon is attached to the capsule by a fold of synovial membrane, which disappears in the fourth month.<sup>1</sup> The semilunar fascia of the biceps is probably the representative of an ulnar division of the superficial flexor mass; it corresponds to the fascial insertion of the biceps of the lower limb.

The **brachialis anticus** muscle arises from the lower half of the front of the humerus and from the intermuscular septa of the arm. At the upper part of its origin it embraces the insertion of the deltoid by two angular fleshy processes, the inner of which is short and thin, while the outer extends upwards, occupying the larger division of the spiral groove, as far as the upper limit of the deltoid emience (fig. 91); it reaches downwards to the capsule of the elbow-joint, and inwards to the internal supracondylar ridge and the intermuscular septum in its whole extent; on its outer side it is separated from the intermuscular septum in the greater part of its length by the supinator longus and extensor carpi radialis longior, and only arises from it for a short distance at its upper end. It is closely adherent to the anterior

<sup>1</sup> Welcker, "Die Einwanderung der Bicepssehne in das Schultergelenk," Arch. f. Anatomie, 1878, 20.

ligament of the elbow-joint, and terminates below in a thick mass which is inserted into the inner part of the rough triangular surface on the front of the coronoid process and the tuberosity of the ulna.

**Relations.**—This muscle lies immediately behind and projects on each side of the biceps. It supports the brachial vessels and median nerve. On the outer side the musculo-spiral nerve lies upon it, under cover of the supinator longus.

**Varieties.**—The most frequent varieties of this muscle consist in its subdivision into two or sometimes more parts; its union with neighbouring muscles, such as supinator longus, pronator teres or biceps; insertion of a slip from it into the semilunar fascia; and occasionally into the radius.

The **triceps extensor cubiti** (figs. 232, 233) occupies the whole posterior brachial region. The muscle consists of three separate portions or heads, which are united below in a common tendon occupying the posterior surface of the mass from the middle of the arm to the elbow, where it terminates by being inserted into the olecranon process of the ulna. The *middle* or *long head* arises from the rough triangular impression on the lower part of the neck, and the adjacent portion of the axillary border of the scapula, by a tendon which spreads over the surface of the muscular structure proceeding from it. This head forms the middle and superficial part of the muscle, and its fibres end on the inner margin of the common tendon. The *external head* takes origin by tendinous and fleshy fibres from the upper and outer part of the posterior surface of the humerus, extending from the insertion of the teres minor downwards as low as the groove of the musculo-spiral nerve, and from an aponeurotic arch formed by the external intermuscular septum as it crosses this groove: its fibres, which are comparatively short, descend obliquely to be inserted into the upper end and outer border of the tendon. The *internal* or *deep head*, the shortest of the three, arises from the whole extent of the posterior surface of the humerus below the spiral groove, on the inner aspect of the arm reaching by a pointed process as high as the insertion of the teres major; it also arises from the internal intermuscular septum in all its length, and from the inferior portion of the external septum. Some of its lower fibres are inserted immediately into the olecranon, but the greater part of them join the deep surface of the common tendon. The insertion of the common tendon takes place mainly into the tuberosity of the olecranon; but from its outer side a considerable band is prolonged downwards over the anconeus, blending with the fascia of the forearm, in which the fibres can be followed to the posterior border of the ulna.

**Relations.**—The long head of the triceps lies between the two teres muscles above, and is closely connected to the capsule of the shoulder-joint. The musculo-spiral nerve and the superior profunda artery are deeply imbedded in the muscle, and in the spiral groove pass between the inner and outer heads.

In many cases there is a small bursa above the olecranon, either between the tendon of the triceps and the posterior ligament, or more frequently in the deep part of the tendon itself. A bursa behind the internal condyle, beneath the inner edge of the triceps and the ulnar nerve, is of rare occurrence. (Gruber, "Die Bursæ mucosæ cubitales," 1866.)

**Varieties.**—The most frequent varieties of the triceps muscle are the following, viz.:—1, an additional or fourth head arising from the inner part of the humerus, above or near the inner head; and 2, a slip of connection between the triceps and the latissimus dorsi, corresponding with the *dorso-epitrochlearis* or *accessorius tricipitis* which is common among quadrumana, and exists in many other mammals.

**Subanconeus.**—On removing the triceps from the lower part of the humerus, a few muscular fibres are sometimes found passing from that part of the bone to the capsule of the elbow-joint. These fibres, which are analogous to the subcreureus in the lower limb, have been described as distinct from the triceps under the name subanconeus.

The **anconeus** muscle (fig. 232, 9), although placed chiefly below the elbow and in the forearm, is intimately connected with the triceps, and may be appropriately associated in description with that muscle. It arises by a narrow tendon from an

impression on the lower and posterior part of the external condyle of the humerus (fig. 93). From this the fibres diverge, the upper being transverse, the rest passing downwards with increasing degrees of obliquity, and are inserted into the olecranon on its radial aspect, and into the adjacent impression on the upper third of the shaft of the ulna (fig. 95). Its superior fibres are parallel to the lowest fibres of the internal head of the triceps, and are generally continuous with them.

**Relations.**—This muscle is subcutaneous in its whole extent. Its deep surface is in contact with the supinator brevis and the external lateral ligament of the elbow-joint.

**Varieties.**—The anconeus varies chiefly in being more or less united to the triceps or the extensor carpi ulnaris.

**Nerves.**—The coraco-brachialis (7 c) receives a branch from the outer cord of the brachial plexus, the biceps (5, 6 c) is supplied by the musculo-cutaneous nerve, and the brachialis anticus (5, 6 c) mainly by the musculo-cutaneous, but also by a small twig from the musculo-spiral nerve. The triceps (7, 8 c) and the anconeus (7, 8 c) receive their nerves from the musculo-spiral.

**Actions.**—The *biceps* muscle raises the arm at the shoulder and flexes the elbow-joint; the short head of the biceps draws the arm inwards as well as upwards, as does also the *coraco-brachialis*. If the biceps be called into action when the hand is in pronation, its first effect, from its insertion into the back part of the tuberosity of the radius, is to produce supination of the forearm. The biceps also makes tense the fascia of the forearm. The *brachialis anticus* is a simple flexor of the elbow. The external and internal heads of the *triceps* are simple extensors of the elbow-joint; the long head, while it assists in extending the elbow, also tends to depress the arm on the scapula. The *anconeus* acts with the triceps in extending the elbow, and draws the ulna outwards in pronation of the hand (p. 170).

#### THE MUSCLES AND FASCIAE OF THE FOREARM.

**FASCIA.**—The **superficial fascia of the forearm** is most distinct opposite the bend of the elbow, where the superficial veins contained between its laminae are numerous and large. In the palm of the hand the subcutaneous tissue forms a firm connecting medium between the skin and a strong aponeurosis named the palmar fascia; it consists of a network of fibres passing between those two structures, dividing the subcutaneous fat into small granular masses, and preventing the skin from shifting to any considerable extent.

The **aponeurosis of the forearm**, like that of the arm, is composed principally of transverse fibres, strengthened, however, by longitudinal and oblique fibres descending from the condyles of the humerus, from the olecranon, from the semi-lunar fascia of the biceps, and from the tendon of the triceps. It is attached along the subcutaneous margin of the ulna, and may be conveniently divided into an anterior and a posterior part.

The *anterior part* of the aponeurosis of the forearm is much weaker than the membrane on the posterior aspect of the limb. It is continued below into the anterior annular ligament of the wrist. Over the hollow immediately below the bend of the elbow, it presents a small oval aperture for the transmission of a short communicating branch between the superficial and the deep veins of the forearm. It increases in density towards the hand, and a little above the wrist affords a sheath to the tendon of the long palmar muscle, which passes over the annular ligament to be inserted into the narrow end of the palmar fascia. Several white lines seen on the surface of the fascia near the elbow mark the position of the septa between the origins of the muscles descending from the inner condyle, which are continuous with it, and which, together with the adjacent portions of the fascia, give origin to the muscular fibres. Between the superficial and the deep flexor muscles, another layer of fascia is stretched from side to side; it is stronger below than above, where it generally consists of little more than thin connective tissue.

The *anterior annular ligament* of the carpus, previously described at p. 174, is



continuous at its upper margin with the fascia of the forearm, and receives some fibres from the tendon of the flexor carpi ulnaris: its anterior surface and lower margin are connected with the palmar fascia, and give origin in part to most of the short muscles of the thumb and little finger. This structure may be considered in some measure as a deep thickened portion of the fascia of the wrist.

The *posterior portion* of the aponeurosis of the forearm, much thicker than the anterior, is intimately connected with the strong septa between the several superficial muscles, and sends off transversely a thin membrane to separate the superficial from the deeper group of muscles. Approaching the back of the wrist, the transverse fibres increase in number and strength, and these, being stretched somewhat obliquely from the anterior margin of the radius on one side to the pyramidal and pisiform bones and the palmar fascia on the other, constitute the *posterior annular ligament* of the carpus. This structure is attached not only to the points now indicated, but is likewise connected to the several longitudinal ridges on the posterior surface of the radius, and thus converts the intermediate grooves into osseo-fibrous canals which lodge the tendons of the extensor muscles. There are six separate spaces so enclosed, and each is lined by a distinct synovial sac. The outermost space corresponds with the groove on the outer side of the radius, and gives passage to the extensores ossis metacarpi and brevis pollicis; the next three, placed on the back of the radius, give passage respectively to the two radial carpal extensors, to the extensor longus pollicis, and to the common extensor of the fingers, with the extensor indicis; between the radius and ulna is the compartment for the extensor minimi digiti; and corresponding to the groove on the back of the ulna is that for the extensor carpi ulnaris.

#### PRONATOR AND FLEXOR MUSCLES.

The eight muscles on the front and inner part of the forearm are disposed in two sets, five being superficial, the others more deeply seated.

The SUPERFICIAL GROUP of muscles comprehends the pronator radii teres, flexor carpi radialis, palmaris longus, flexor carpi ulnaris, and flexor sublimis digitorum. These five muscles are intimately united at their origin from the inner condyle, being attached to this by a common tendon which gives fibres to each, and also sends septa between them.

The **pronator radii teres** muscle, the most external of the group, arises by two heads: one, large and superficial, is derived from the upper part of the inner condyle of the humerus, and from the common tendon above mentioned; also from the fascia and the intermuscular septum on its inner side. The second head, a thin fasciculus deeply placed, comes from the inner margin of the coronoid process, and joins the other at an acute angle. The fleshy belly thus formed proceeds outwards and downwards, and ends in a flat tendon which turns over the radius, and is inserted into a rough impression at the middle of the outer surface of that bone.

**Relations.**—The pronator teres is placed superficially in the greater part of its extent; but towards its insertion it is crossed by the radial vessels and nerve, and covered by the supinator longus muscle. The ulnar border is in contact with the flexor carpi radialis and flexor sublimis digitorum: the radial border forms the inner boundary of the angular space at the bend of the arm, in which are placed the brachial vessels, the median nerve, and the tendon of the biceps muscle. The pronator teres lies over the brachialis anticus and the radial origin of the flexor sublimis digitorum; the ulnar artery passes behind the whole muscle, and the median nerve between its two heads.

**Varieties.**—The coronoid head is sometimes absent. In other cases the muscle is prolonged farther than usual by a slip arising from the intermuscular septum above the inner condyle of the humerus, or from the supracondylar process when that is present. This

peculiarity is sometimes associated with a change in the direction of the brachial artery. An additional head of origin from the biceps or from the brachialis anticus has also been observed.

The **flexor carpi radialis** muscle arises from the inner condyle by the common tendon, from the fascia of the forearm, and from the intermuscular septa placed between it and the pronator teres on one side, the palmaris longus on the other, and

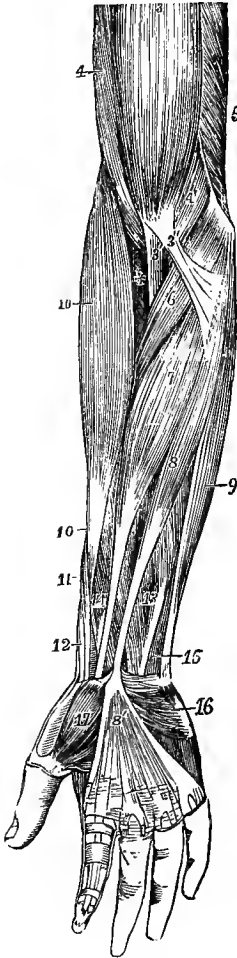


Fig. 235.—SUPERFICIAL MUSCLES OF THE FOREARM AND HAND, SEEN FROM THE FRONT. (Allen Thomson.)  $\frac{1}{2}$

3, biceps; 3', its tendon of insertion; 3'', its aponeurotic slip; 4, brachialis anticus; 4', its inner and lower portion; 5', inner head of the triceps; 6, pronator radii teres; 7, flexor carpi radialis; 8, palmaris longus, passing at 8' into the palmar aponeurosis; 9, flexor carpi ulnaris; 10, 10, supinator longus; between 10 and 3', +, supinator brevis; 11, extensor ossis metacarpi pollicis; 12, extensor brevis pollicis; 13, lower part of the flexor sublimis digitorum; 14, flexor longus pollicis; 15, small part of the flexor profundus digitorum; 16, palmaris brevis, lying on the muscles of the little finger; 17, abductor pollicis.

the flexor sublimis behind. The fleshy fibres end a little below the middle of the forearm in a flat tendon, which occupies a special compartment in the outer part of the anterior annular ligament of the wrist, and running through a groove in the trapezium, to which it is bound by a fibrous sheath lined by a synovial membrane, is inserted into the base of the second metacarpal bone, a small slip being generally sent to the base of the third.

**Relations.**—The muscle lies immediately under the fascia until its tendon sinks beneath the annular ligament. In the lower half of the forearm the radial artery is placed to the outer side of the tendon.

**Varieties.**—At its origin the flexor carpi radialis has been observed receiving an additional slip from the tendon of the biceps, the semilunar fascia, the coronoid process of the ulna, or the anterior oblique line of the radius. Its insertion is subject to frequent varieties, taking place partly into the annular ligament, the trapezium, or into the fourth metacarpal bone as well as the second and third. Absence of the muscle has also been met with.

The **palmaris longus**, the smallest muscle of this group, is placed between the flexores carpi radialis and ulnaris, resting on the flexor sublimis: it arises from the inner condyle, the fascia and the intermuscular septa, forming a small muscular belly, which soon ends in a long slender tendon, inserted into the palmar fascia near the middle of the wrist, and often sending a slip to the abductor pollicis muscle.

**Varieties.**—This is probably the most variable muscle in the body. It is wanting to the extent of about ten per cent. of the bodies examined. It is subject to many variations of form; e.g., the fleshy fibres may occupy the middle of the muscle, which then commences and ends by an elongated tendon; or the muscular structure may be placed towards the lower end, the upper part being tendinous; or the whole muscle may be reduced to a mere tendinous band. A digastric muscle has also been observed. It is sometimes represented by a slip from the flexor carpi ulnaris or flexor sublimis digitorum. Occasionally there are two long palmar muscles, one having the ordinary shape, while the other has one of the forms above referred to. An additional origin has been seen from the coronoid process, or from the radius.

Among the varieties that have been observed in its mode of termination are insertion, partial or complete, into the fascia of the forearm, into the tendon of the flexor carpi ulnaris and the pisiform bone, into the scaphoid, and into the muscles of the little finger.

The palmaris longus muscle with the central portion of the palmar fascia are derived from a superficial flexor of the fingers, which has become reduced in association with the greater development and differentiation of the flexores sublimis and profundus digitorum.

The **flexor carpi ulnaris**, the innermost muscle of the superficial group, arises by two heads, the one of which forms the hindmost part of the common tendon from the inner condyle of the humerus, while the other is attached to the inner side of the olecranon, and to the posterior border of the ulna for the upper two-thirds of its length, by an aponeurosis which is inseparably connected with the investing aponeurosis of the limb. The muscular fibres, passing downwards and forwards from this long line of origin, terminate in a tendon which descends along the anterior margin of the muscle, and is inserted into the pisiform bone: this tendon is prolonged by means of the pisi-metacarpal and pisi-uncinate ligaments to the fifth metacarpal and unciform bones, and a small band passes to the anterior annular ligament.

**Relations.**—This muscle rests on the flexor profundus digitorum. The ulnar nerve and the posterior ulnar recurrent artery pass between the two heads of origin, and the nerve is then covered by the muscle as far as the wrist, as are also the ulnar vessels below the middle of the forearm.

**Varieties.**—An additional slip of origin from the inner side of the coronoid process is often present. Partial insertion into the annular ligament, the fourth or the fifth metacarpal bone, has also been observed.

The *epitrochleo-anconeus* is a small muscle frequently present, arising from the back of the inner condyle, and inserted into the olecranon; it lies over the ulnar nerve, from which it receives a twig. It is generally represented by a band of transverse fibres in the fascia.

The **flexor sublimis digitorum** or **flexor perforatus**, the superficial flexor of the fingers, is a broad flat muscle placed behind the preceding muscles. It arises by a thick strong head from the inner condyle and the fibrous septa common to it and the other muscles, from the internal lateral ligament, and from the inner margin of the coronoid process; and by a thin flat portion from the anterior oblique line and part of the anterior border of the radius. It is divided inferiorly into four parts, ending in as many tendons, which pass to be inserted into the second phalanges of the four inner digits. These tendons pass under the annular ligament of the wrist in pairs, the anterior pair consisting of those for the middle and ring fingers, the posterior of those for the index and little fingers.

In the palm of the hand the tendons diverge, and each, accompanied by a tendon of the flexor profundus, enters a fibrous sheath which binds both tendons down to the palmar surface of the phalanges. Opposite the first phalanx the tendon of the flexor sublimis divides into two parts, which fold closely round the tendon of the deep flexor, and are reunited by their margins behind it: the two portions of the tendon thereafter separating, pass to be inserted one on each side into a ridge at the middle of the lateral border of the second phalanx.

The arrangement of the tendons of the flexor sublimis digitorum beneath the annular ligament corresponds to a division of the muscle into two layers, which can be readily separated almost up to the origin from the internal condyle. The superficial layer springs from the condyle by a tendinous lamina which forms part of the common tendon: its fleshy mass is divided below into two bellies, from which the tendons to the middle and ring fingers proceed: the middle finger part receives the radial head, while the ring finger tendon is joined by a slip from the deep division of the muscle. The deep layer has the construction of a digastric muscle: it has a broad origin, for the most part by fleshy fibres, from the internal condyle, the anterior band of the internal lateral ligament, and the inner margin of the coronoid process, as well as from the deep surface of the tendon of the superficial layer and the adjacent margin of the condylar tendon of the flexor carpi ulnaris: the fibres form a conical belly, which terminates in a flat-cylindrical tendon above the middle of the forearm.

From this tendon there arise, 1, a fleshy slip to join the ring finger tendon, 2, a belly which terminates in the index finger tendon, and 3, a small belly furnishing the little finger tendon. Of the four tendons, that to the middle finger is the largest, and that to the little finger much the smallest. A slender fasciculus usually passes from the outer part of the condylo-ulnar head of the muscle to the beginning of the tendon of the flexor longus pollicis.

**Relations.**—In the forearm the flexor sublimis is for the most part concealed by the pronator teres, flexor carpi radialis and palmaris longus; but between the last muscle and the flexor carpi ulnaris a narrow strip is superficial from the internal condyle down to the

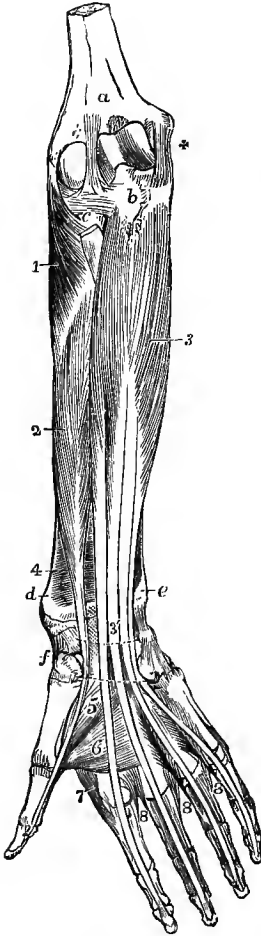


Fig. 236.—DEEP ANTERIOR MUSCLES OF THE FOREARM.  
(Allen Thomson.)  $\frac{1}{2}$

The superficial muscles of the forearm and hand, together with the lumbricales, have been removed, and the place of the anterior annular ligament of the carpus is marked by two dotted lines. *a*, surface of the humerus above the coronoid process; *b*, coronoid process of the ulna; *c*, head of the radius covered by the orbicular ligament; +, internal lateral ligament of the elbow-joint; *d*, lower end of the radius; *e*, that of the ulna; *f*, scaphoid and trapezium bones; 1, supinator brevis; 2, flexor longus pollicis; 3, flexor profundus digitorum; 3', its tendons, where they are about to pass under the annular ligament; 4, pronator quadratus on the lower part of the radius; 5, adductor obliquus, and 6, adductor transversus pollicis; 7, first dorsal interosseous muscle; 8, in the second space, is placed between the first palmar and the second dorsal interosseous muscles; in the third space, between the third dorsal and the second palmar; in the fourth space, between the fourth dorsal and the third palmar. (For the lumbricales, see figs. 237 and 242.)

annular ligament. Its radial origin is crossed by the radial vessels. It rests on the flexor longus pollicis and flexor profundus digitorum, the median nerve, which passes between the two heads, and the ulnar vessels. In the palm of the hand, its tendons are covered by the palmar fascia, the superficial palmar arterial arch, and the branches of the median nerve; and they lie in front of the accompanying tendons of the flexor profundus.

**Varieties.**—Absence of the radial head has been observed. In some cases the slip from the deep part of the muscle forms the chief part of the ring finger division; or there may be also a slip from the deep part to the middle finger tendon. An accessory slip is sometimes present, passing from the tuberosity of the ulna to the index and middle finger portions. The little finger portion of the muscle is occasionally absent, and has been seen replaced by a slip arising from the ulna, or from the annular ligament and palmar fascia, or by a slip from the flexor profundus, or by the fourth lumbrical muscle. A slip is frequently given from the inner head of the muscle to the flexor profundus.

The DEEP-SEATED MUSCLES of the front of the forearm are the flexor profundus digitorum, flexor longus pollicis, and pronator quadratus.

The **flexor profundus digitorum** or **flexor perforans**, a large and thick muscle, arises from the inner and anterior surfaces of the ulna for three-fourths of its length, from the ulnar half of the interosseous membrane for the same distance, and from the aponeurosis attaching the flexor carpi ulnaris to the ulna. It divides inferiorly into four tendons, only one of which, that for the index finger, is distinct from the others above the wrist—the rest being connected together as far as the palm. In the palm the tendons, as they diverge, give origin to the lumbricales muscles. In front of the fingers they are bound to the first and second phalanges by the sheath common to them and the perforated tendons. Opposite the first

phalanx the tendon of each finger passes through the opening formed for its transmission in the tendon of the flexor sublimis, and it is inserted into the base of the last phalanx.

The index finger portion of the muscle is usually separate throughout: it arises mainly from the interosseous membrane, and only to a slight extent from the adjacent part of the ulna. The middle and ring finger portions arise in close connection chiefly from the anterior surface of the ulna, but also from the inner surface of the bone and the aponeurosis of the flexor carpi ulnaris near the elbow, and by a few fibres from the interosseous membrane below. The little finger portion arises from the hinder part of the inner surface of the ulna and the aponeurosis of the flexor carpi ulnaris. Between the ring and little finger portions a considerable part of the inner surface of the ulna is free from muscular attachment.

**Relations.**—The upper extremity of the flexor profundus embraces the insertion of the brachialis anticus. In the forearm the muscle is covered by the flexor carpi ulnaris and flexor sublimis digitorum, and on it lie the median nerve and the ulnar vessels and nerve. The external border is adjacent to the flexor longus pollicis, from which it is separated on the interosseous membrane by the anterior interosseous vessels and nerve.

The **lumbricales** muscles are four tapering fleshy fasciculi, passing from the tendons of the flexor profundus to the tendons of the common extensor. Each

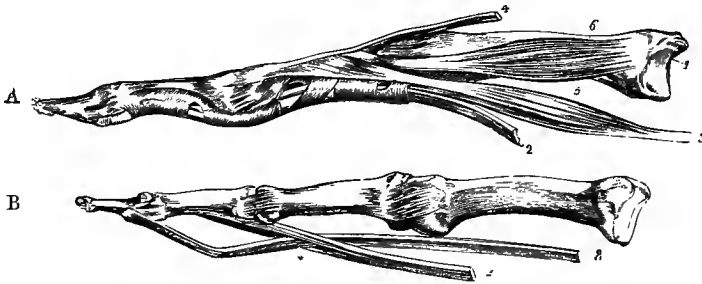


Fig. 237.—BONES OF TWO FINGERS, WITH THE INSERTIONS OF THE TENDONS. (R. Quain.)

In A, the tendons of the flexor muscles are bound to the bones by the fibrous sheath. In B, the sheath has been removed, as well as the vincula accessoria; 1, metacarpal bone; 2, tendon of the flexor sublimis; 3, tendon of the flexor profundus; \*, perforation of the sublimis by the profundus tendon; 4, tendon of the extensor communis digitorum; 5, lumbricalis muscle; 6, one of the interosseous muscles.

muscle arises by fleshy fibres from the outer or radial border of one of the deep flexor tendons, and in the case of the two inner muscles also from the ulnar border of the second and third; proceeding downwards and then backwards on the radial sides of the fingers, each is inserted into the expansion of the extensor tendon on the dorsal aspect of the metacarpal phalanx.

**Varieties.**—The index finger portion of the flexor profundus often receives fibres from the upper part of the radius, close to the interosseous membrane. The muscle may be joined by a slip given off from the inner head of the flexor sublimis, or arising separately from the internal condyle of the humerus or the coronoid process of the ulna: in some cases this slip constitutes an accessory muscle, which joins very variously one or more of the perforating tendons. A connection with the flexor longus pollicis is not unfrequent, generally in the form of a slip passing from that muscle to the index finger tendon of the flexor profundus.

Varieties of the lumbricales muscles are of frequent occurrence. Their number is occasionally diminished to three, or even to two, and in rare instances is increased to five or six. The destination of one or two of them is often changed, and one finger (most frequently the middle or ring) has sometimes two inserted into it. Lastly, one muscle may be inserted into two fingers. The fourth has been observed to take the place of the fourth perforated tendon of the flexor sublimis.

**Synovial bursa.**—The tendons of both the superficial and deep flexors are enveloped beneath the annular ligament in a large and loose synovial sac, which extends upwards to the level of the radio-carpal articulation, while downwards it is prolonged along the inner tendons to the beginning of the digital sheath of the little finger, into which in most cases it

opens. The tendons of the ring and little fingers are most extensively surrounded by the synovial membrane, and those of the index and middle fingers are but slightly in relation with it. A sagittal septum, placed behind the median nerve, separates this sac from that investing the tendon of the flexor longus pollicis. In exceptional cases an intermediate sac is formed on the deep flexor tendon of the index finger; or there may be separate sheaths on the superficial flexor tendons of the index and middle fingers. In the infant, the digital synovial sheaths, including that of the thumb, are at first distinct from the sacs beneath the annular ligament. (A. v. Rosthorn, Langenbeck's Arch. f. klinische Chirurgie, xxxiv, 1887.)

The *sheaths of the flexor tendons*, by which they are bound down to the fingers, are formed opposite the shafts of the first and second phalanges by strong tendinous-looking bands of transverse fibres, *vaginal ligaments*, attached to the rough margins of the palmar surfaces of the phalanges. Opposite the joints, flexion is allowed by the substitution for those bands of a thin membrane, strengthened by oblique decussating fibres. The tendinous sheath has a synovial lining, which gives a separate investment to each tendon.

The synovial membrane forms small folds (*vincula accessoria tendinum*) between the tendons and the bones. There are two sets of these; the one, *ligamenta brevia*, broad and membranous, passing between the tendons near their insertion and the lower part of the phalanx immediately above; the other, *ligamenta longa*, slender and less constant bands, joining the tendons at a higher level. Contained in the ligamentum breve of the deep flexor is a small band of yellow elastic tissue (*vinculum subflavum*), which stretches from the tendon to the head of the second phalanx, and may assist in drawing down the tendon after flexion of the fingers (J. Marshall, Brit. and For. Med. Chir. Rev., 1853).

The **flexor longus pollicis** muscle, placed side by side with the flexor profundus digitorum, arises from the anterior surface of the radius, extending from the oblique line to the edge of the pronator quadratus, and from the adjacent part of the interosseous membrane; and in the majority of instances it receives also a distinct fleshy and tendinous slip, springing in common with the flexor sublimis digitorum from the inner condyle or the coronoid process. The muscle ends in a tendon which passes behind the annular ligament of the wrist close to the trapezium, turns outwards between the outer head of the flexor brevis and the adductor obliquus pollicis, and lying in the groove between the sesamoid bones, finally enters a canal similar to those of the other flexor tendons, to be inserted into the base of the second phalanx of the thumb.

As the tendon of the muscle passes under the annular ligament it is surrounded by a synovial sac, which is continued below into the digital sheath, and occasionally communicates above with the bursa of the common flexor tendons.

**Varieties.**—The flexor longus pollicis is sometimes connected by a slip with the flexor sublimis or profundus, or the pronator teres. A tendon of insertion into the index finger has been observed, as also a slip to the first lumbricalis.

The complete separation of the flexor longus pollicis is characteristic of man. In other Primates it is variously united with the flexor profundus digitorum.

The **pronator quadratus**, placed close to the bones behind the last two muscles, arises from the pronator ridge and the adjoining inner part of the anterior surface of the ulna in its lower fourth; its fibres cross the lower part of the forearm, some transversely and others obliquely, and they are inserted for a slightly shorter distance into the fore part and inner side of the radius.

**Varieties.**—The pronator quadratus is subject to varieties, chiefly as follows:—1, it may be entirely absent, but this is rare; 2, it is subdivided into two layers, or occasionally into three; 3, it extends farther upwards on the bones of the forearm than usual; 4, it is prolonged downwards on the carpus, in some cases as a radio-carpal, and in others as an ulno-carpal muscle.

The *radio-carpus* or *flexor carpi radialis brevis* is an additional small muscle not unfrequently seen, arising from the radius, usually from the anterior border and surface above the pronator quadratus, and very variably inserted below, into the annular ligament,

the trapezium, magnum, or some other part of the carpus, or into one or more of the metacarpal bones.

**Nerves.**—The pronator and flexor muscles of the forearm receive their nerves mostly from the median, only one, the flexor carpi ulnaris (8 c, 1 d), being wholly, and another, the flexor profundus digitorum (8 c, 1 d), in part supplied from the ulnar nerve by branches entering them near the elbow. The pronator radii teres (6 c), flexor carpi radialis (6 c), palmaris longus, and the condylo-ulnar head of the flexor sublimis digitorum (7, 8 c, 1 d) receive branches from the median in the neighbourhood of the elbow, while the radial head and the index finger belly of the flexor sublimis have separate twigs from the same trunk. The flexor longus pollicis (8 c, 1 d), pronator quadratus (8 c, 1 d), and outer half of the flexor profundus digitorum are supplied by the anterior interosseous branch of the median. The outer two lumbricales are innervated by the median, and the inner two by the ulnar.

#### SUPINATOR AND EXTENSOR MUSCLES.

The muscles of this group are, like those of the front of the forearm, divided into a superficial and a deep group.

The **SUPERFICIAL MUSCLES** are seven in number, viz., the supinator longus, the extensores carpi radiales longior and brevior, the extensor communis digitorum, extensor minimi digiti, extensor carpi ulnaris, and anconeus. The last muscle has already been described in connection with the triceps (p. 221).

The **supinator radii longus** muscle (brachio-radialis) arises from the upper two-thirds of the external supracondylar ridge of the humerus, and from the external intermuscular septum. Its fibres form a thin fleshy mass, which descends on the outer and anterior part of the limb to about the middle of the forearm, where it ends in a flat tendon, which is inserted into an impression on the outer side of the lower end of the radius, near the base of the styloid process.

**Relations.**—This muscle is covered only by skin and fascia, except at its insertion, where two of the extensor tendons of the thumb lie over the tendon. Above, the brachialis anticus is in contact with its inner surface, the musculo-spiral nerve being interposed, and the long radial extensor is beneath it. It forms the outer boundary of the triangular space at the bend of the elbow, and in the forearm it rests upon the supinator brevis, pronator teres, flexor sublimis digitorum, and the radial vessels and nerve.

**Varieties.**—The supinator longus is often united at its origin with the brachialis anticus. The tendon is occasionally divided into two or even three slips, which are inserted either together or at some distance from each other. In rare cases complete doubling of the muscle has been seen. Insertion, partial or complete, into the middle of the radius, fasciculi to the tendon of the biceps, the tuberosity or anterior oblique line of the radius, slips of communication with the extensor carpi radialis longior or extensor ossis metacarpi pollicis, and absence of the muscle have also been observed.

The **extensor carpi radialis longior** muscle arises from the lower third of the external supracondylar ridge of the humerus, and from the external intermuscular septum: a few fibres also spring from the outer side of the common tendon of the extensor muscles. Its muscular belly ends above the middle of the forearm in a flat tendon, which passes, conjointly with that of the following muscle, in the outermost of the grooves on the posterior surface of the radius, and is inserted into the base of the second metacarpal bone.

The **extensor carpi radialis brevior** muscle arises from the outer condyle of the humerus by a tendon common to it and the following muscles, from the intervening fibrous septa, from the fascia covering it, and from the external lateral ligament of the elbow-joint. Its muscular belly ends in a tendon, which, descending with that of the extensor longior, passes through the same groove of the radius with it, and is inserted into the base of the metacarpal bone of the middle finger.

**Relations.**—Of the two foregoing muscles the extensor longus is the more superficial. The extensor brevis covers the supinator brevis and the insertion of the pronator radii teres. The tendons of these muscles are crossed obliquely above the annular ligament by the

extensors of the metacarpal bone and first phalanx of the thumb, a bursa being interposed, and below the ligament by the tendon of the long extensor of the thumb. A small bursa is placed under each tendon close to its insertion, and occasionally there is another between the origin of the shorter muscle and the supinator brevis. The synovial sheath surrounding the tendons beneath the annular ligament communicates with that of the extensor longus pollicis at the spot where the latter tendon crosses.

**Varieties.**—The two foregoing muscles are subject to a similar variation in being, one or other of them, split up into two or sometimes three tendons previous to insertion, the tendons

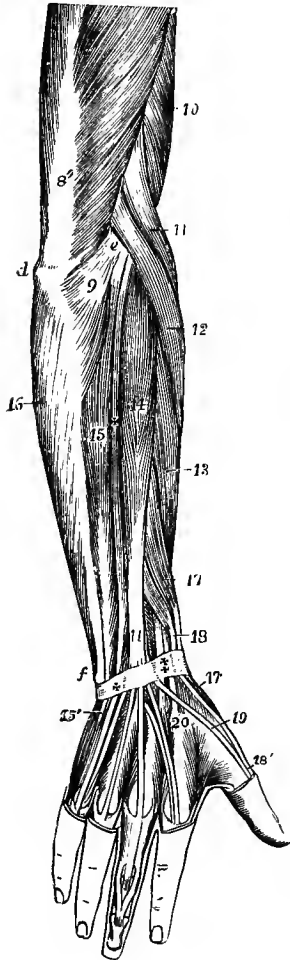


Fig. 238.—SUPERFICIAL MUSCLES OF THE FOREARM AND HAND, SEEN FROM BEHIND. (Allen Thomson.)  $\frac{1}{2}$

*d*, olecranon; *e*, external condyle; *f*, lower end of ulna; 8'', tendon of triceps; 9, anconeus; 10, part of brachialis anticus; 11, supinator longus; 12, extensor carpi radialis longior; 13, ——— brevis; 14, extensor communis digitorum; 15, extensor carpi ulnaris; 15', its insertion into the fifth metacarpal bone; +, between 14 and 15, extensor minimi digiti; 16, origin of the flexor carpi ulnaris by an aponeurosis from the back of the ulna, 17, extensor ossis metacarpi pollicis; 17', its insertion into the first metacarpal bone; 18, extensor brevis pollicis; 18', its insertion into the first phalanx; + and ‡, posterior annular ligament; at †, the tendons of the long and short radial extensors; at +, the tendon of the extensor minimi digiti; 19, tendon of extensor longus pollicis; 20, is placed on the proximal end of the second metacarpal bone, close to the insertion of the radial extensors of the carpus: in the hand, the dorsal interosseous muscles are shown, and on the middle finger the insertion of the extensor tendon.

of either muscle being inserted into both the second and third metacarpal bones: occasionally a slip passes also to the fourth metacarpal bone. The two muscles have been seen united, so that a single fleshy belly gives off two tendons. Cross slips from one muscle to the other are of frequent occurrence, and may be regarded as imperfect forms of the following muscle.

The *extensor carpi radialis intermedius* is rare as a distinct muscle arising independently from the humerus, but is not unfrequent as a slip derived from one or both of the normal radial extensors: it is inserted below into the second or third metacarpal, or into both of these bones.

The *extensor carpi radialis accessorius* is an additional muscle sometimes met with, arising from the humerus with or below the extensor carpi radialis longior, and inserted most frequently into the metacarpal bone of the thumb, but sometimes into the abductor pollicis, first dorsal interosseous muscle, or other part. It is represented at times by a slip from the tendon of the extensor longior.

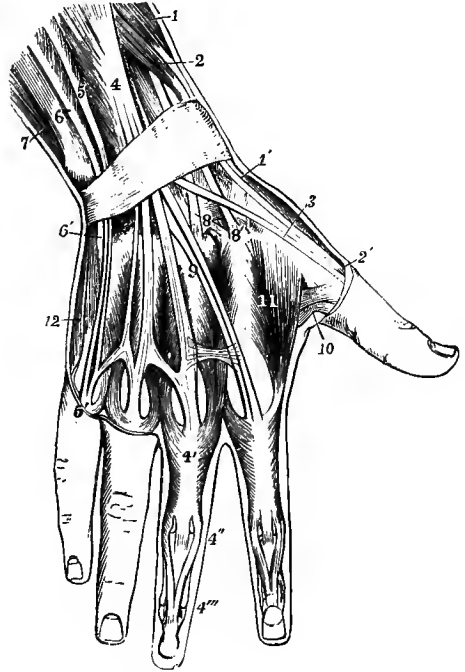
The **extensor communis digitorum** muscle arises from the outer condyle by the common tendon, from the fascia of the forearm, and from the septa between it and the adjoining muscles. The fleshy mass forms three bellies, the innermost of which becomes divided again below, and from each part a tendon proceeds. The four tendons pass under the posterior annular ligament, lying together with the extensor indicis in the broad innermost groove on the back of the radius, and descend on the back of the hand to the fingers. The first and second tendons pass respectively to the index and middle fingers, and are usually connected by a weak band of transverse fibres; the first is accompanied by the tendon of the extensor indicis, the two becoming united opposite the metacarpo-phalangeal articulation. The third tendon runs mainly to the ring finger, but sends a slip to join the tendon of the middle finger.



The fourth tendon lies close to the third, and divides below into two parts, the outer, which is usually the larger, being destined for the ring finger, and uniting with the foregoing tendon over the head of the metacarpal bone, while the inner joins the outer division of the extensor minimi digiti tendon.

On the fingers the tendons have the following arrangement. Opposite the metacarpo-phalangeal articulation the tendon is bound down by bands of transverse fibres, which pass forwards on each side to become continuous with the anterior ligament of the joint. It then expands, and is joined by tendinous slips from the interosseous muscles, and on the radial side also by the tendinous insertion of the lumbrical muscle of the finger, the whole forming an aponeurosis which covers the

Fig. 239.—SUPERFICIAL MUSCLES AND TENDONS ON THE BACK OF THE WRIST AND HAND. (Modified from Bourguery.)  $\frac{1}{3}$



The posterior annular ligament of the wrist is represented. 1, extensor ossis metacarpi pollicis; 1', its insertion; 2, extensor brevis pollicis; 2', its insertion; 3, tendon of extensor longus pollicis; 4, extensor communis digitorum; 4', tendon to the middle finger, receiving the insertion of the second and third dorsal interosseous muscles; 4'', division of the tendon into three portions, of which the median is inserted into the second phalanx, the two lateral passing on to be inserted at 4''', into the terminal phalanx; 5, extensor minimi digiti; 5', its junction with the slip of the common extensor; 6, placed on the lower end of the ulna, points to the extensor carpi ulnaris; 6', insertion of this muscle into the base of the fifth metacarpal bone; 7, part of the flexor carpi ulnaris; 8, placed on the os magnum, points to the insertion of the extensor carpi radialis brevior; 8', placed on the base of the second metacarpal bone, points to the insertion of the extensor carpi radialis longior; 9, tendon of extensor indicis; 10, small part of the adductor pollicis; 11, first dorsal interosseous or abductor indicis: in the other three interosseous spaces are seen in succession, from the radial side inwards, the insertion of the first palmar, second dorsal, third dorsal, second palmar, fourth dorsal, and third palmar interosseous muscles; 12, abductor minimi digiti.

back of the first and second phalanges and ends upon the third phalanx. Over the lower part of the first phalanx the aponeurosis divides into three slips; the central one is much thinner than the others and is inserted into the base of the second phalanx; the two lateral parts, continuing onwards, join together below, and are inserted into the base of the last phalanx. A thin layer of transverse and oblique fibres bridges over the interval between the three parts of the aponeurosis and binds the lateral slips down to the sides of the first interphalangeal articulation.

The index finger portion of the muscle is the most distinct; its fleshy belly is confined to the middle two-fourths of the forearm. The middle finger portion is the strongest; its tendon becomes free from muscular fibres at the middle of the forearm. The fourth tendon is the smallest, and receives fleshy fibres as far as the wrist.

**Varieties.**—The varieties of the extensor communis digitorum resolve themselves chiefly into the following, viz., 1st, the occasional deficiency of one or more of the tendons of insertion, and 2nd, more frequently an increase in their number. This last goes in some instances to the extent of doubling the tendon to each of the fingers, and even of tripling it

to one or two of them. More frequently, however, the increase in number of the tendons is limited to the index or middle finger alone. An additional slip to the thumb is occasionally seen.

The **extensor minimi digiti** is a slender muscle which arises from the fascia of the forearm, and from the intermuscular septa separating it from the extensor communis digitorum and the extensor carpi ulnaris. The tendon in which it ends occupies a groove between the radius and ulna, passing through a special compartment in the annular ligament; on the back of the hand it becomes split into two, the outer division being joined by a slip from the fourth tendon of the common extensor, and both parts end in the dorsal expansion of the little finger, in the formation of which this muscle takes by far the greater share.

**Varieties.**—An origin from the external condyle of the humerus by means of a thin fibrous slip forming part of the common tendon is occasionally present (5 per cent.). The tendon of insertion is sometimes undivided (10 per cent.), or gives a slip to the ring finger (6 per cent.). Absence of the muscle is rare, but fusion of the belly with the extensor communis digitorum is not uncommon (4 per cent.). (Gruber, "Beobachtungen," Heft iii, 1882, and Virchow's Archiv, xcix, 1885.)

The **extensor carpi ulnaris**, the most internal of the muscles descending on the back of the forearm, arises from the external condyle of the humerus by the common tendon, from a strong intermuscular septum on its outer side, and from the fascia of the forearm. The belly of the muscle is in its middle third closely bound down to the posterior border of the ulna by the fascia, and it occasionally receives a few additional fibres from this portion of the bone. The fleshy fibres are collected round a tendon which becomes free a little above the wrist, and runs through a special groove in the carpal end of the ulna and a separate sheath in the annular ligament, to be inserted into the tuberosity on the base of the fifth metacarpal bone. There is sometimes a small bursa beneath the tendon of origin.

**Varieties.**—The extensor carpi ulnaris has been seen—1, double throughout, 2, reduced to a tendinous band, and 3, inserted partially into the fourth metacarpal bone. In very many cases (52 per cent.) a slip is continued from the insertion of the tendon anteriorly, over the opponens minimi digiti, to be inserted into the fascia covering that muscle, the metacarpal bone, the capsule of the metacarpo-phalangeal articulation, or the first phalanx of the little finger. The slip is sometimes joined or replaced by a muscular fasciculus arising from or in the neighbourhood of the pisiform bone. (Gruber, "Beobachtungen," Heft ix, 1889).

The *ulnaris quinti digiti* is a muscle that has been met with once by W. Gruber, arising from the posterior surface of the ulna in its lower half, and inserted into the base of the first phalanx of the little finger. It is occasionally represented by a fasciculus from the belly of the extensor carpi ulnaris, very frequently (44 per cent.) by a dorsal slip from the tendon of that muscle, which may be inserted into either the metacarpal bone or the first phalanx, or may join the extensor tendon of the little finger. (Gruber, "Beobachtungen," Heft v, 1884.)

The DEEP-SEATED MUSCLES on the back of the forearm are five in number, the supinator brevis, the three extensors of the thumb, and the extensor of the index finger.

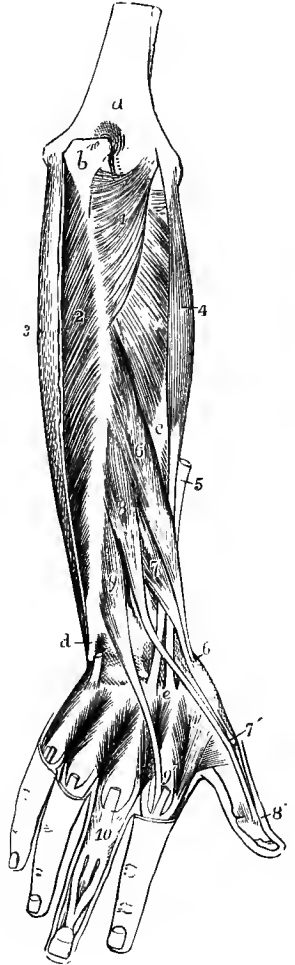
The **supinator radii brevis** muscle arises from the external lateral ligament of the elbow-joint, from the annular ligament of the radius, and from the supinator ridge and the hinder part of the bicipital hollow of the ulna, extending downwards a short distance along the outer border of the bone. The fleshy fibres derived from these points of attachment, as well as from a tendinous expansion on the surface, which can be followed up to the external condyle, pass obliquely round the upper part of the radius, covering it closely except at the inner side, and are inserted into that bone for rather more than a third of its length, reaching down to the insertion of the pronator radii teres, and being limited in front and behind by the anterior

and posterior oblique lines. It is pierced by the posterior interosseous nerve, which effects a more or less complete division of the muscle into two layers.

**Varieties.**—The anterior fibres of the supinator brevis not unfrequently form a detached slip inserted into the orbicular ligament. An accessory fasciculus from the external condyle has been observed, also fibres inserted into the tendon of the biceps, the bursa under that tendon, and the tuberosity of the radius.

Fig. 240.—DEEP POSTERIOR MUSCLES OF THE FOREARM.  
(Allen Thomson.)  $\frac{1}{2}$

*a*, humerus; *b*, olecranon; *c*, radius; *d*, lower part of the ulna, grooved for the tendon of the extensor carpi ulnaris, which is cut short; 1, anconeus; 2, flexor profundus digitorum, exposed by the removal of the aponeurotic tendon of 3, the flexor carpi ulnaris; +, supinator brevis; 4, extensor carpi radialis brevis, and 5, the cut tendon of the extensor carpi radialis longior; *e*, their insertions into the second and third metacarpal bones: 6, extensor ossis metacarpi pollicis; 6', its insertion into the base of the first metacarpal bone; 7, extensor brevis pollicis; 7', its insertion into the base of the first phalanx; 8, extensor longus pollicis; 8', its insertion into the base of the last phalanx; 9, extensor indicis; 9', its junction with the tendon of the common extensor, which is cut short: in the intermetacarpal spaces the four dorsal interosseous muscles are exposed, the tendons of the common extensor having been removed; and at 10, the insertions of the second and third dorsal interosseous muscles, by a triangular expansion, into the tendon of the extensor communis, as well as the mode of insertion of that tendon into the middle and last phalanges, are shown.



The **extensor ossis metacarpi pollicis** muscle (abductor longus pollicis) arises from a narrow oblique impression occupying the upper part of the outer division of the posterior surface of the ulna (fig. 95) below the origin of the supinator brevis, from the middle third of the posterior surface of the radius below the insertion of the same muscle, and from the interosseous membrane between. Thence descending obliquely outwards, it ends in a tendon which passes, in company with the extensor brevis pollicis, through the groove on the outer side of the lower extremity of the radius, and is inserted into the base of the metacarpal bone of the thumb, on its radial side. The tendon is commonly split near its insertion, and one part is often attached to the trapezium.

**Relations.**—The upper part of this muscle is concealed by the common extensor, but it becomes superficial below, and together with the next muscle crosses the tendons of the radial extensors of the carpus, conceals the insertion of the supinator longus, and, below the extremity of the radius, crosses the radial artery. A bursa separates the two extensors of the thumb from the tendons of the radial extensors.

The **extensor brevis pollicis** muscle (ext. primi internodii poll.) lies close to the lower border of the extensor ossis metacarpi, and is much smaller than that muscle; it arises from the interosseous ligament and a small part of the radius below the middle of the forearm; its tendon accompanies that of the extensor ossis metacarpi through the same compartment of the annular ligament, and passes on to be inserted into the proximal end of the first phalanx.

The **extensor longus pollicis** muscle (ext. secundi internodii poll.), much larger than the extensor brevis, which it overlaps, arises immediately below the extensor ossis metacarpi from the outer division of the posterior surface of the ulna for its middle third or more, and from the interosseous membrane for about an inch opposite the lower part of the ulnar attachment. Its fibres end in a tendon which passes through a separate compartment of the annular ligament, occupying the narrow oblique groove in the middle of the posterior surface of the carpal end of the radius, and is inserted into the base of the terminal phalanx of the thumb.

**Relations.**—The fleshy part of this muscle is covered by the extensors of the fingers and the extensor carpi ulnaris. Its tendon becomes superficial immediately above the wrist, and below the annular ligament crosses over those of the radial extensors. At the place of crossing a communication is formed between the two synovial sheaths investing these tendons.

**Varieties.**—The extensor muscles of the thumb are subject to considerable variations, and if all the three muscles be included they seem to occur as often as in one out of every six subjects dissected. The most common occur in the extensor ossis metacarpi, and consist in a more extensive cleavage of the tendon, or even of the whole muscle, into separate parts. The insertion of the distinct tendons takes place either doubly into the first metacarpal bone, or in part into the trapezium, or into the abductor or opponens pollicis muscles. The extensor brevis, which is a muscle peculiar to man, is sometimes absent, being as it were fused with the extensor ossis metacarpi. Its tendon is often united, and inserted in common with that of the long extensor. Doubling of the extensor longus pollicis is not unfrequent, and the ulnar portion of the muscle may then pass beneath the annular ligament with the extensor communis digitorum. A slip from the tendon of the long extensor to the indicator is occasionally seen. A rarer variety, representing a muscle normally existing in the dog and many carnivora, is the presence of an additional extensor between the indicator and the extensor longus pollicis, with a double tendon and insertion into both digits.

The **extensor indicis** or indicator muscle arises from the outer division of the posterior surface of the ulna for a variable extent below the extensor longus

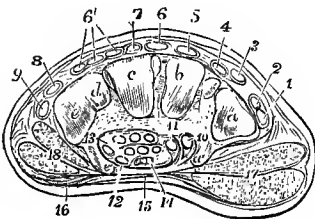


Fig. 241.—TRANSVERSE SECTION OF THE RIGHT HAND BETWEEN THE CARPUS AND METACARPUS. (Allen Thomson.)  $\frac{1}{2}$

*a, b, c, d, e*, articular surfaces of the trapezium, trapezoid, magnum and unciform bones; *a'*, palmar ridge of the trapezium; *e'*, unciform process; between *a'* and *e'*, the cut edge of the annular ligament, sending a process towards the trapezoid at 11, by which the tendon of the flexor carpi radialis is enclosed in the groove of the trapezium; 1, tendon of the extensor ossis metacarpi pollicis; 2, extensor brevis pollicis; 3, extensor longus; 4, extensor carpi radialis longior; 5, brevior; 6, index finger tendon of extensor communis digitorum; 6', remaining tendons; 7, extensor indicis; 8, extensor minimi

digiti; 9, extensor carpi ulnaris; 10, flexor carpi radialis; 11, flexor longus pollicis; 12, the first on the ulnar side of the tendons of the flexor sublimis digitorum; 13, the same of the flexor profundus; 14, median nerve; 15, the palmar aponeurosis stretched across the annular ligament; 16, palmaris brevis; 17, short muscles of the thumb; 18, muscles of the little finger.

pollicis, and slightly from the interosseous membrane at its lower part. The tendon passes with the common extensor through a compartment of the annular ligament, comes in contact with the tendon from that muscle destined for the index finger, and unites with it to form the expansion already described.

**Varieties.**—This muscle is but rarely absent. Its tendon is frequently double, and one of the parts may pass, although rarely, to the thumb or ring finger, or more commonly (14 per cent.) to the middle finger, leading to the formation of an *extensor medii digiti*, which may occur also as a distinct muscle (2.5 per cent.) arising from the ulna or posterior ligament of the wrist-joint below the indicator. Less frequently an *extensor brevis digitorum manus* is present, arising from the back of the wrist-joint, or from the carpus, or from the bases of some of the metacarpal bones, and sending tendons to one, two, or three fingers. Intermediate

forms between these two muscles are also met with. (Gruber, "Beobachtungen," Heft vi and vii.)

**Nerves.**—The anconeus (7, 8c), supinator longus (6c), and extensor carpi radialis longior (6, 7c) receive branches from the musculo-spiral nerve; the remaining muscles of this group are supplied by the posterior interosseous division of that trunk, the offsets for the extensor carpi radialis brevior (6, 7c) and supinator brevis (6c) arising from the nerve before it pierces the latter muscle, while those for the extensors of the digits, both superficial and deep (7c), as well as the extensor carpi ulnaris (7c), are given off after it appears on the back of the forearm.

#### THE MUSCLES AND FASCIÆ OF THE HAND.

**FASCIÆ.**—The **fascia of the dorsum of the hand**, a thin layer composed mainly of transverse fibres, is prolonged downwards from the lower border of the annular ligament over the extensor tendons, and blends with these on the fingers. Deeper than the extensor tendons thin aponeuroses are stretched over the intermetacarpal spaces, being attached laterally to the bones, and covering the dorsal interosseous muscles to which they are firmly adherent.

The **fascia of the palm** consists of a central part, which is thick and strong, and of two lateral portions, which are very thin and cover the eminences formed by the short muscles of the thumb and little finger. The central portion is that commonly referred to under the name of the *palmar fascia*. Consisting principally of longitudinal fibres which are in largest part continued from the tendon of the palmaris longus, others, however, springing from the front of the annular ligament, it is narrow above and becomes expanded and thinner below. Here it divides into four processes which pass to the bases of the several fingers, and join the commencement of the digital sheaths, sending some fibres also to the integument at the clefts of the fingers, and to the superficial transverse ligament. From the sides of these processes, moreover, offsets are sent backwards to be attached to the transverse metacarpal ligament opposite the lateral margins of the heads of the metacarpal bones, and thus above each finger a short canal is formed, in which the flexor tendons run. In the intervals between the processes some deeper transverse fibres make their appearance, covering the lumbricales muscles and the digital vessels and nerves. At the lower margin of the palm a superficial band of transverse fibres, which stretches across the roots of the four fingers, being contained in the folds of skin at the upper ends of the clefts, is known as the *superficial transverse ligament of the fingers*. There is also deeply placed in the palm a thin layer of fascia which covers the interosseous muscles, and dipping between them, is attached to the palmar ridges of the metacarpal bones, while inferiorly it becomes continuous with the transverse metacarpal ligament. From the deep surface of the palmar fascia a thin septum is sent backwards on each side between the flexor tendons and the thumb and little finger muscles respectively, and these, joining the fascia covering the interosseous muscles, complete a sheath in which the tendons are contained in their passage through the palm.

**Cutaneous ligaments of the phalanges.**—These are fibrous bands which pass from the edges of the phalanges to the skin of the sides of the fingers, and serve the purpose of retaining the skin in position during flexion of the joints. (Cleland, Journ. Anat., xii, 526.)

**MUSCLES.**—Besides the tendons of the long muscles and the lumbricales already described, there are placed in the hand one superficial muscle called palmaris brevis, the short muscles of the thumb and little finger, and the interosseous muscles.

The **palmaris brevis** (fig. 235, 16) is a thin flat subcutaneous muscle, which arises from the inner margin of the palmar fascia and the annular ligament; its fibres pass transversely inwards, and are inserted into the skin along the inner border of the palm.

**Relations.**—The palmaris brevis crosses the muscles of the little finger and covers the ulnar vessels and nerve.

**MUSCLES OF THE THUMB.**—The short muscles of the thumb are five in number, three of which, viz., the abductor, opponens, and flexor brevis, constitute the *thenar eminence*, covering the first metacarpal bone, while the two adductors lie beneath the outer part of the hollow of the palm.

The **abductor pollicis** muscle, superficial and flat, arises mainly from the front of the annular ligament, a few of the outer fibres being attached sometimes to the ridge of the trapezium or the tuberosity of the scaphoid; proceeding downwards and outwards, it is inserted by a tendon into the base of the first phalanx of the thumb at its radial border, and sends a slip to join the tendon of the extensor longus pollicis.

The **opponens pollicis** muscle, placed beneath the abductor, arises from the annular ligament and from the outer side of the ridge of the trapezium, and is inserted into the whole length of the metacarpal bone of the thumb at the radial border, as well as the adjoining part of the palmar surface.

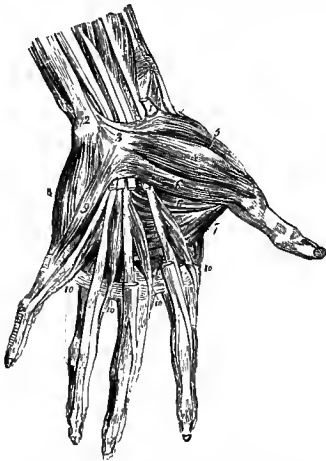


Fig. 242.—MUSCLES AND TENDONS OF THE PALMAR ASPECT OF THE HAND.  $\frac{1}{2}$

Portions of the tendons of the superficial flexor have been cut away to show those of the deep flexor and the lumbricales. 1, tendon of the flexor carpi radialis, cut short; 2, tendon of the flexor carpi ulnaris, inserted into the pisiform bone; 3, anterior annular ligament; 4, abductor pollicis; 5, opponens pollicis; 6, flexor brevis pollicis; 7, adductor transversus pollicis; 8, abductor minimi digiti; 9, flexor brevis minimi digiti; 10, lumbricales.

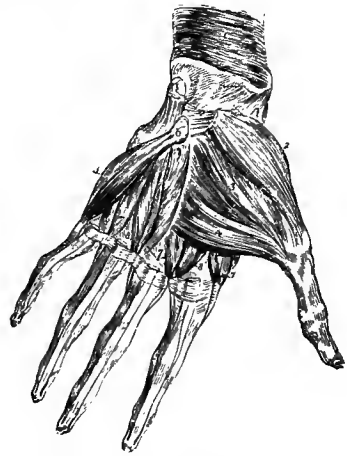

Fig. 243.—DEEP MUSCLES OF THE PALM OF THE HAND.  $\frac{1}{2}$

The abductor pollicis and abductor minimi digiti, together with the anterior annular ligament and the flexor tendons in the palm, have been removed; in the fore finger the tendons of both the superficial and deep flexors remain, in the other fingers only the tendons of the deep flexor. 1, pronator quadratus muscle; 2, opponens pollicis; 3, adductor obliquus pollicis; 4, adductor transversus pollicis; 5, opponens minimi digiti; 6, unciform bone; 7, 8, interosseous muscles.

The **flexor brevis pollicis** muscle consists of two separate parts or heads, outer and inner. The *outer* or *superficial head* (fig. 244) arises from the outer two-thirds of the annular ligament at its lower border, and descends along the outer side of the tendon of the flexor longus pollicis to be inserted into the outer side of the base of the first phalanx of the thumb, having a sesamoid bone developed in it over the head of the metacarpal bone. The *inner* or *deep head* (fig. 245) is very small, and deeply placed between the adductor obliquus and the outer head of the abductor indicis muscle. It arises from the upper part of the first metacarpal bone on the

ulnar side, and is inserted with the adductor obliquus into the inner side of the base of the first phalanx.

The **adductor obliquus pollicis** is the largest of the thumb-muscles. It arises in several slips from the upper ends of the second and third metacarpal bones, the os magnum, the anterior carpal ligaments, and the sheath of the flexor carpi radialis. It passes obliquely downwards on the inner side of the tendon of the long flexor, and is inserted into the inner side of the base of the first phalanx of the thumb, in union with the adductor transversus and the deep head of the flexor brevis. The inner sesamoid bone of the thumb is formed in the tendon of insertion. A considerable fasciculus of the adductor obliquus usually inclines outwards behind the

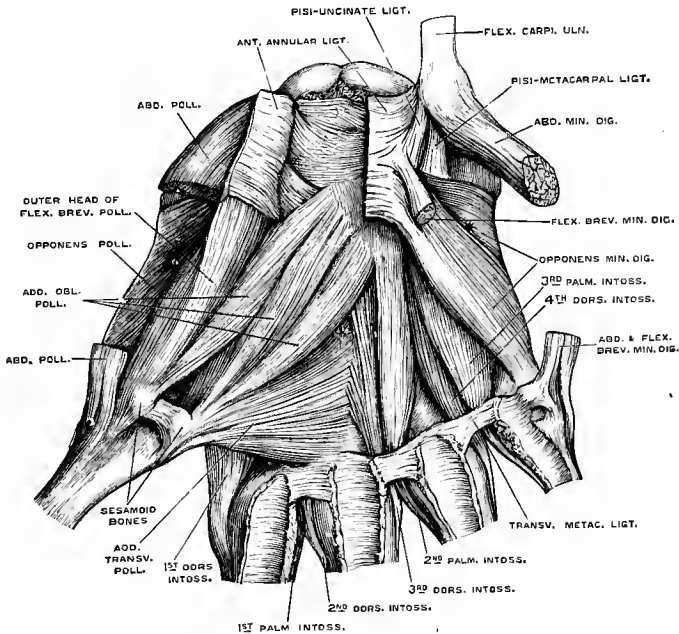


Fig. 244.—DEEP MUSCLES OF THE PALM. (G. D. T.)  $\frac{2}{3}$

The anterior annular ligament has been divided, and its outer part reflected. The middle portions of the abductor pollicis, and of the abductor and flexor brevis minimi digiti have been removed. The opponens minimi digiti consists of two parts, which are separated by a cleft\*, giving passage to the deep branches of the ulnar nerve and vessels; †, interval through which the deep palmar arch passes.

long flexor tendon to join the superficial head of the flexor brevis and the outer sesamoid bone.

It has been customary to describe the adductor obliquus pollicis as the deep head of the flexor brevis. The present description follows the division and nomenclature of Cunningham ("Challenger" Reports, Zoology, xvi; Anatom. Anzeiger, 1887).

The **adductor transversus pollicis** muscle arises from the ridge on the lower two-thirds of the palmar aspect of the third metacarpal bone, and is inserted into the base of the first phalanx of the thumb along with the adductor obliquus and the inner head of the short flexor; from the common insertion a slip is continued to the long extensor tendon of the thumb. The deep palmar arterial arch passes between the two adductors.

**MUSCLES OF THE LITTLE FINGER.**—The fleshy mass at the inner border of the hand (*hypothernar eminence*) consists of three muscles passing to the little finger.

The **abductor minimi digiti** muscle arises by tendinous fibres from the lower border and inner surface of the pisiform bone, and is inserted into the base of the first phalanx of the little finger on the ulnar border, a slip being sent to the extensor tendon on the back.

The **flexor brevis minimi digiti**, separated at its origin from the abductor muscle by a small interval through which pass the deep palmar branches of the ulnar nerve and artery, arises from the front of the annular ligament, and from the tip of the hooked process of the unciform bone, and is inserted into the base of the first phalanx of the little finger, in common with the preceding muscle. This muscle is sometimes absent, or becomes incorporated with the abductor.

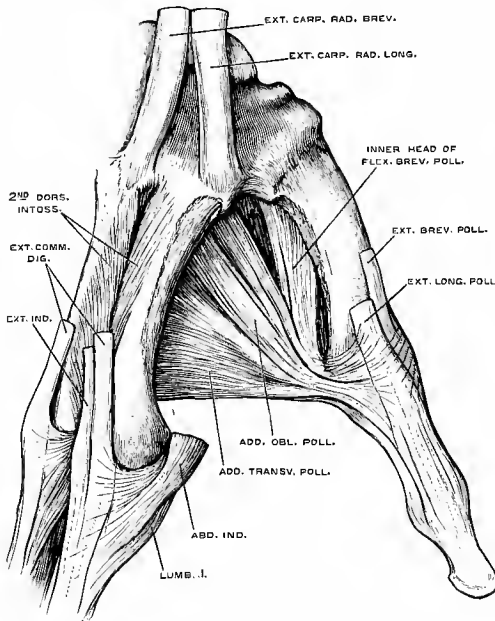


Fig. 245.—DORSAL VIEW OF THE OUTER PART OF THE HAND, SHOWING THE DEEP HEAD OF THE SHORT FLEXOR AND THE ADDUCTORS OF THE THUMB. (G. D. T.) 3

The two heads of the abductor indicis have been taken away; †, interval through which the radial artery passes.

The **opponens minimi digiti** muscle arises from the annular ligament and the unciform process, and is inserted into the ulnar side of the fifth metacarpal bone in all its length. It is usually divided into two parts by a cleft through which the deep branches of the ulnar artery and nerve pass.

The **INTEROSSEOUS MUSCLES** occupy the intervals between the metacarpal bones. They are seven in number, all

of them more or less visible from the palmar aspect, and they are divided into two sets, viz., those which are best seen on the dorsal aspect of the metacarpus, and those which are seen only in the palm. Their disposition is most easily understood by reference to their action.

The **dorsal interosseous** muscles abduct the fingers from the middle line of the hand; they are four in number, one in each of the spaces between the metacarpal bones, and are numbered from without inwards. Each muscle arises from both the metacarpal bones between which it is placed, but most extensively from that supporting the finger upon which it acts, and the fibres converge pinnately to a common tendon in the middle. Each terminates in a tendon which is inserted partly into the base of the first phalanx, and partly into the tendon of the extensor muscle on the dorsum of the same part of the finger. Two of the muscles are inserted into the middle finger and draw it to either side; of the remaining two, one passes to the radial side of the index finger, and the other to the ulnar side of the ring finger; they withdraw those fingers from the middle line of the hand.

The first dorsal interosseous muscle or *abductor indicis* is larger than the others; its outer and larger head of origin arises from the proximal half of the ulnar border of the first metacarpal bone, the inner is attached to the whole length of the second



metacarpal bone, and between these heads there is left superiorly an interval wider than in the other dorsal interosseous muscles.

**Relations.**—Between the heads of the abductor indicis the radial artery passes forwards to the palm of the hand; between those of the other dorsal interosseous muscles small perforating arterial branches are transmitted.

The three **palmar interosseous** muscles are adductors, drawing the index, ring, and little fingers towards the middle line of the hand. They are visible only on the palmar aspect of the hand, each one arising from the corresponding lateral surface of the body of the metacarpal bone of the finger on which it acts: they terminate, like the dorsal muscles, in small tendons inserted partly into the bases of the first phalanges at the side, and partly into the extensor tendons. The first palmar interosseous muscle belongs to the ulnar side of the index finger; the others are placed on the radial sides of the ring and little fingers.

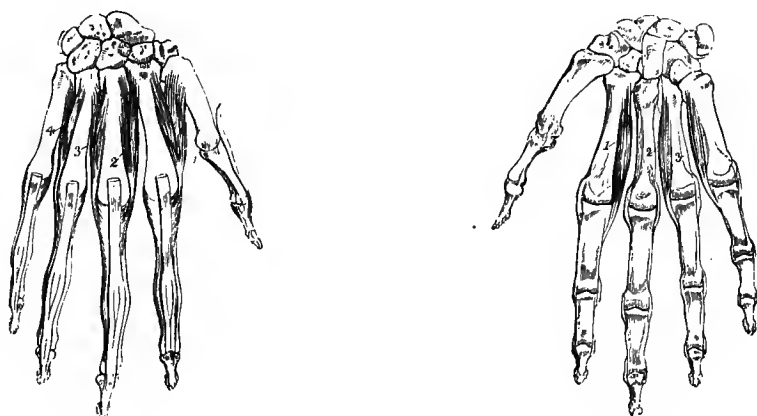


Fig. 246.—THE RIGHT HAND FROM BEHIND, SHOWING THE DORSAL INTEROSSEOUS MUSCLES. (R. Quain.) ?

The tendons of the extensor muscles have been removed as far as the distal ends of the metacarpal bones. 1, 2, 3, and 4, the dorsal interosseous muscles, in order from the radial side inwards; their expanded insertion in connection with the extensor tendons, is shown upon the first phalanges.

Fig. 247.—THE RIGHT HAND FROM BEFORE, SHOWING THE PALMAR INTEROSSEOUS MUSCLES. (R. Quain.) ?

1, 2, 3, refer to the first, second, and third palmar interosseous muscles.

Small bursæ are often present between the tendons of the interosseous muscles and the metacarpo-phalangeal articulations, as well as in the interspaces between the heads of the inner four metacarpal bones.

**Varieties of the short muscles of the hand.**—The palmaris brevis varies greatly in the strength of its muscular fibres, and somewhat also in their length and direction. It is seldom entirely absent. It is sometimes found running into the flexor minimi digiti.

The abductor pollicis is often divided into an outer and an inner part—a condition described by Sæmmerring as normal. Accessory slips are also found joining the muscle, frequently from the tendon of the extensor ossis metacarpi pollicis or palmaris longus, more rarely from the extensor carpi radialis longior (or accessorius), from the styloid process or opponens pollicis. Another slip, which is frequently present, springs from the skin over the upper part of the thenar eminence.

The deep head of the flexor brevis pollicis is sometimes wanting. On the other hand it may be larger than usual, and arise in part from the upper end of the second metacarpal bone.

The two adductors vary in their relative extent and in the closeness of their connection. The adductor obliquus sometimes receives a slip from the transverse metacarpal ligament.

The abductor minimi digiti is found occasionally divided into two or even three slips; in other cases it is united with the flexor brevis. An accessory head is not unfrequently present, arising from the tendon of the flexor carpi ulnaris, the annular ligament, the fascia of the forearm, or the tendon of the palmaris longus. In some cases the additional head arises a considerable distance above the wrist from the intermuscular fascia, under either the flexor carpi ulnaris or flexor carpi radialis, and passing downwards covers the ulnar artery to a greater or less extent, ending in the abductor or occasionally in the flexor minimi digiti. A portion of the abductor minimi digiti is occasionally inserted into the fifth metacarpal bone; or a separate slip may pass from the pisiform bone to this insertion, constituting a *pisiformis* muscle. The *pisiformis* is a small muscle, first described by Calori and found by Gruber to be present in 2·5 per cent. of hands, between the pisiform bone and the hook of the unciform; and the name *pisiformis* may be given to a similar slip inserted into the anterior annular ligament.

The opponens muscles are subject to varieties chiefly affecting their extent, and the degree of their union with or separation from the neighbouring muscles.

The interosseous muscles present some variations, but not of any great magnitude. They are occasionally double in one or more of the spaces. The arrangement which usually exists in the foot, and which is peculiar to man, has also been observed to occur in the hand.

**Nerves of the muscles of the hand.**—The median nerve supplies the abductor pollicis, the opponens, and the outer head of the flexor brevis by a branch (6 c) arising immediately below the annular ligament, and the first two lumbricales muscles by twigs from the third and fourth digital nerves respectively. The ulnar nerve, besides giving a twig to the palmaris brevis, furnishes by its deep palmar division (8 c) branches to the muscles of the little finger, the two internal lumbricales, all the interosseous muscles, the adductors, and the inner head of the flexor brevis pollicis.

**Actions of the muscles of the forearm and hand.**—The muscles of the forearm may be distinguished according to their actions as pronators and supinators, flexors and extensors of the wrist, and long flexors and extensors of the fingers; those of the hand are flexors and extensors, adductors, abductors and opposers of the fingers, the terms adduction and abduction being here used with reference to the middle line of the hand.

*Pronation* is mainly effected by the pronator teres and pronator quadratus; but the flexor carpi radialis also contributes slightly to this movement. The pronator teres is fitted to flex the elbow when pronation has been completed, or when it is prevented by antagonistic muscles, and in this action it receives assistance from the other muscles arising from the internal condyle.

*Supination* is effected principally by the supinator brevis, together with the biceps, the supinator longus having but little influence upon this action. The latter muscle is essentially a *flexor of the elbow*, acting most efficiently when the hand is placed midway between pronation and supination, and tending to bring the hand into that position when it is either fully pronated or supinated. The radial extensors of the wrist assist also in flexing the elbow; the remaining muscles arising from the external condyle aid in extending that joint.

*Flexion of the wrist* is produced by the radial and ulnar flexors of the carpus, and is aided by the flexors of the fingers when the action of those muscles on the fingers is either completed or is opposed by any resistance.

*Extension of the wrist*, in a similar manner, is accomplished not only by the three muscles specially devoted to that function, but also by the extensors of the fingers. The lateral movements of the wrist are produced by the same muscles, acting in different combinations, *abduction* by the radial flexor and extensors, assisted by the extensors of the thumb, and *adduction* by the ulnar flexor and extensor. The flexor carpi radialis and extensor carpi ulnaris act specially on the radio-carpal joint, and the flexor carpi ulnaris and extensores carpi-radiales on the transverse carpal joint (cf. p. 176).

To ensure the efficient action of the long extensor and flexor muscles of the fingers it is necessary that there should be simultaneous action of the flexors and extensors of the wrist respectively; for the wrist-joint must be fixed backwards by its extensors in order that the long flexors of the fingers may act, and the wrist must be fixed forwards by its flexors in order that the long extensors may act upon the fingers.

The *flexor sublimis digitorum* and the *flexor profundus* bend respectively the second and the third phalanges of the fingers, while the *extensor communis* extends chiefly the first phalanx. The four *lumbricales*, on the other hand, and the seven *interosseous* muscles have a double action, in consequence of their insertion, complete or partial, into the expansions of the extensor tendons. This action consists firstly, in the flexion of the fingers at the metacarpo-phalangeal articulations, and secondly, in extension of the second and third phalanges. The *lumbricales* and *interosseous* muscles, therefore, are antagonists to both the long flexors and to the long extensor. This partial and combined action of the long and short muscles upon the fingers, of which the movements made in forming the hair-stroke in writing may be taken as an example, has been well known for a considerable time, especially as regards the *lumbricales*, but it has been confirmed and elucidated as regards the *interosseous* muscles by the electro-physiological

experiments and pathological observations of Duchenne, whose interesting work<sup>1</sup> may be advantageously consulted on these and other muscular movements. Poore attributes to the lumbricales the special function of drawing down and relaxing the flexor tendons, while actively producing extension of the middle and last phalanges through their insertion into the extensor aponeurosis ("The Lancet," Sept. 3, 1881, p. 407).

With respect to the *interosseous* muscles, it is farther to be observed that, besides being flexors of the first and extensors of the second and third phalanges in the manner previously stated, they severally exercise an abducting or adducting action on certain fingers, or direct them away from or towards the middle line of the hand, according to the places of their respective insertions; and thus the four dorsal interosseous muscles are abductors of the index, middle and ring fingers, and the three palmar interosseous muscles are adductors of the index, ring, and little fingers respectively.

While the muscles of the thumb produce for the most part the several movements indicated by their names, these movements, in consequence of the position of the first metacarpal bone, take place in directions which differ from those of the corresponding movements of the fingers. Thus, extension, being movement in the direction of the dorsal surface of the digit, occurs in nearly the same plane as abduction of the fingers; and in abduction, the thumb moving in the direction of its radial border is carried more forwards than outwards. Opposition is produced by the combined action of the *flexor brevis*, the *adductors*, and the *opponens* muscles.

The little finger is withdrawn from the others by its *abductor*, as the ring finger is withdrawn from the middle finger by the fourth dorsal interosseous muscle; and the *abductor* acting with the long flexors, likewise assists the *flexor brevis* in keeping the first phalanx firmly down in grasping. The *opponens* draws forwards the fifth metacarpal bone, so as to render the hand narrower and deepen the hollow of the palm.

While the *palmaris longus* has the effect of tightening the palmar fascia, the *palmaris brevis* draws up and wrinkles the integument over the hypothenar prominence.

## II.—THE MUSCLES AND FASCIÆ OF THE LOWER LIMB.

The muscles which pass between the trunk and the lower limb, viz., the psoas, pyriformis, and part of the gluteus maximus, are so few in number and so intimately connected with others belonging strictly to the limb, that it is unnecessary to describe them as a distinct group, as has been done in the case of the more numerous and considerable muscles which attach the upper limb to the trunk.

### THE FASCIÆ OF THE HIP AND THIGH.

The **superficial fascia** of the lower limb is similar to and continuous with that of other parts of the body. Over the gluteal region it is very thick, and assists in forming the prominence of the buttock. On the front of the thigh it covers the lymphatic glands and the superficial vessels and nerves; it passes freely over Poupart's ligament, becoming continuous with the subcutaneous layer of the abdominal fascia, and internally it passes into the dartos tunic of the scrotum and into the superficial fascia of the perineum. In the neighbourhood of the groin a thin layer of condensed areolar tissue, placed beneath the glands and superficial vessels, can be raised from the surface of the fascia lata, and this is sometimes described separately as a deep layer of superficial fascia. This structure is continued across the saphenous opening of the fascia lata, to the margins of which it is closely attached, and being here perforated by numerous small foramina for the passage of blood-vessels and lymphatics, it receives the name of *cribriform fascia*.

The **deep fascia of the thigh** or **fascia lata** is a strong aponeurotic membrane, consisting of white shining fibrous tissue, and forming a continuous sheath round the limb. It is attached superiorly to the back of the sacrum and coccyx, to

<sup>1</sup> G. B. Duchenne, "Physiologie des Mouvements, &c.," Paris, 1867.

the crest of the ilium; to Poupart's ligament, to the body and rami of the pubis, to the ramus and tuberosity of the ischium, and to the lower margin of the great sacro-sciatic ligament. In the gluteal region it descends on the surface of the gluteus medius muscle as far as the upper border of the gluteus maximus, where it divides into two layers, one of which passes on the superficial, the other on the deep surface of that muscle. After encasing the muscle, the layers unite at its lower and external borders. Over the great trochanter, where the layers unite externally, and where also the fascia is much thickened, the greater number of the fibres of the muscle are inserted between the layers. The thickened portion of the fascia may be traced downwards on the outside of the thigh, from the fore part of the crest of the ilium to the outer tuberosity of the tibia. This *ilio-tibial band* consists of dense glistening parallel fibres, and about the junction of the upper and middle thirds of the thigh it receives also the insertion of the tensor vaginæ femoris muscle. On the rest of the thigh the fascia lata varies in thickness. It is thinnest in the upper and inner part of the thigh, where it covers the adductor muscles. At the knee it is considerably strengthened on each side of the patella by tendinous expansions given off from the lower parts of the vasti muscles, and assists in forming the capsular investment of the joint. This part of the fascia is firmly attached to the head of the tibia and to the lateral margins of the patella, but a superficial layer is given off which extends over the front of the latter bone, a synovial bursa of considerable size being interposed. A second smaller bursa is placed immediately under the skin covering the patella, and the cavities of the two are sometimes continuous through an aperture in the aponeurosis. Other small bursæ are not unfrequently present over the patella or its ligament, or over the tubercle of the tibia. Posteriorly the fascia is continued uninterruptedly over the hamstring muscles and the popliteal space into the fascia of the leg.

On the front of the thigh, a little below and external to the inner end of Poupart's ligament, is placed the *saphenous opening*, an aperture in the fascia lata through which the internal saphenous vein passes to join the femoral vein, and which receives special attention from its being the place of exit of femoral hernia. The outer part of this opening lies in front of the femoral artery, and is bounded externally by a crescentic margin, the *falciform border*, which crosses the surface of the infundibuliform sheath of the femoral vessels. This margin in the middle of its extent is continued into looser tissue, the above-mentioned cribriform fascia, but superiorly and inferiorly it ends in more distinct incurved extremities, the *superior* and *inferior cornua*. The inferior cornu, the most completely defined part of the margin, lies in the angle between the internal saphenous and the femoral veins, below their junction; while the superior cornu forms a larger curve, the inner extremity of which, often called *femoral ligament*, passing completely to the inner side of the femoral sheath, is attached to the front of Gimbernat's ligament.

It is customary to call the parts of the fascia lata on the outer and inner sides respectively of the saphenous opening the *iliac* and *pubic portions*. The iliac portion is intimately connected above with Poupart's ligament, as well as with the deep layer of the superficial fascia of the abdomen (fascia of Scarpa), and internally forms the falciform margin of the saphenous opening; the pubic portion (or *pectineal fascia*), attached superiorly to the ilio-pectineal line, passes on its outer side deeply behind the sheath of the vessels, with which it is connected, and is continued into the iliac fascia, to be subsequently described.

The fascia lata is perforated in many places by foramina, which allow the passage of the cutaneous nerves and blood-vessels.

The fascia lata has various deep processes. One of these, leaving the main fascia at the insertion of the tensor vaginæ femoris muscle, passes upwards on the inner side of that muscle as a strong flat band on the surface of the vastus externus, and

is attached superiorly to the ilium above the origin of the posterior head of the rectus femoris, with which also it is closely connected. Two processes, the *external* and *internal intermuscular septa*, bind the fascia to the femur in the lower part of the thigh: the external septum, situated between the vastus externus and crureus in front and the short head of the biceps behind, is inserted into the linea aspera from the lower border of the tendon of the gluteus maximus to the outer condyle of the bone: the internal septum, which is much thinner and less distinct, is inserted into the femur between the vastus internus and the adductor magnus, becoming blended with the tendinous attachments of those muscles.

**Sheath of the femoral vessels.**—The femoral vessels are surrounded by an investment of fascia, which in its upper part is particularly distinct and receives the name of the *crural sheath*. This sheath, commencing at the deep crural arch, is continuous with the transversalis fascia and iliac fascia of the cavity of the abdomen. Its outer border descends in contact with the artery, while its inner border is inclined outwards from the margin of Gimbernat's ligament, and comes in contact with the vein at a distance of less than an inch lower down: the sheath is therefore funnel-shaped. It is divided into three compartments, separated by thin septa: the outermost contains the artery, the middle one the vein, and the innermost forms a space occupied at its upper end by the crural ring, and in which there is generally a lymphatic gland and some fat. Through this passage a femoral hernia descends, and on this account it has been named the *femoral* or *crural canal*. (See the special account of Hernia in Vol. III.)

#### THE MUSCLES OF THE HIP.

The muscles of this region are the ilio-psoas anteriorly, the three glutei and the tensor vaginæ femoris covering the pelvis and the hip-joint externally and posteriorly, and beneath the gluteus maximus the group of external rotators, viz., the pyramidalis, the obturator internus with the gemelli, the obturator externus, and the quadratus femoris.

The **ilio-psoas** muscle, the great flexor of the hip-joint, is divisible into two parts, a broad outer part, the iliacus, and an elongated inner part, the psoas magnus, which are sometimes described separately as two muscles. The greater part of the muscle is situated in the abdomen, only the lower conjoined portion appearing below Poupart's ligament over the front of the hip-joint.

The *iliacus* arises from the upper half of the iliac fossa of the hip-bone, anteriorly reaching down to the inferior spine, and posteriorly receiving a few fibres also from the ala of the sacrum and the ligament connecting the two bones. Its fibres converge as they pass downwards and inwards, and are inserted for the most part into the tendon of the psoas; the outermost, however, pass directly to a special triangular surface on the upper part of the femur, in front of and below the small trochanter.

The *psoas magnus* arises by five fleshy slips from the anterior surfaces and lower margins of the transverse processes of the lumbar vertebræ; also from the bodies of the vertebræ by a series of thick processes, each of which takes origin from an intervertebral disc, and from the contiguous margins of two bodies, the highest being attached to the last dorsal and first lumbar vertebræ, and the lowest to the fourth and fifth lumbar vertebræ with the intervertebral substance between them. These attachments are connected by thin tendinous arches extending over the middle of each vertebra, covering the lumbar vessels and communicating branches of the sympathetic nerve, and giving origin to other muscular fibres. The various bundles of fibres speedily unite to form a thick elongated muscle, which runs along the brim of the pelvis, and emerging from the abdomen beneath Poupart's ligament, is

inserted into the small trochanter of the femur by means of a tendon, which is placed at first within the substance of the muscle, and afterwards at its outer side, receiving as it descends the fibres of the iliacus as well as those of the psoas.

**Relations.**—Both iliacus and psoas are covered in the abdomen by the iliac fascia, which is also prolonged downwards over the conjoined muscle into the upper part of the thigh, where it becomes continuous with the pubic portion of the fascia lata. Superficial to the fascia are the subperitoneal fat and peritoneum, with the termination of the ileum, the cæcum, and the beginning of the ascending colon on the right side, and the lower part of the descending colon on the left side. The psoas at its upper extremity is placed behind the diaphragm, being

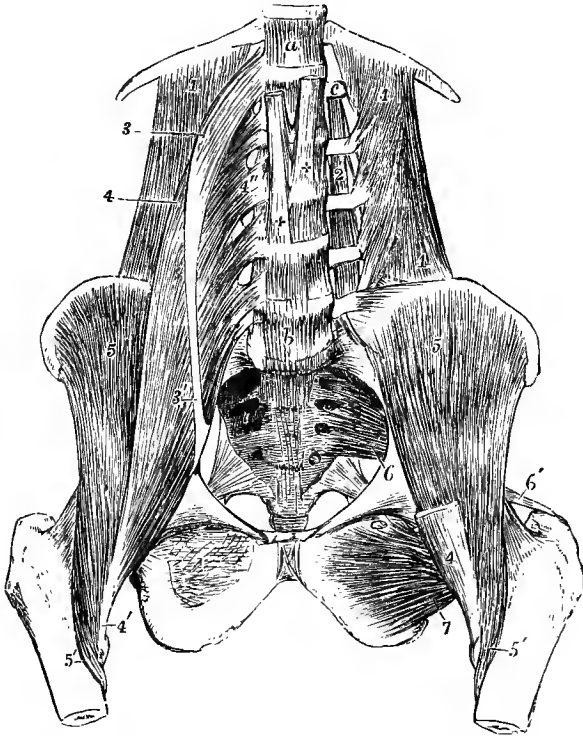


Fig. 248.—DEEP MUSCLES OF THE ABDOMEN AND PELVIS. (Allen Thomson.)  $\frac{1}{2}$

*a*, twelfth dorsal vertebra; *b*, fifth lumbar vertebra; *c*, transverse process of the first lumbar vertebra; 1, quadratus lumborum muscle; on the left side its fibres of origin from the transverse processes of the lumbar vertebrae are shown by the removal of the psoas; 2, placed upon one of the inter-transversales muscles of the left side; 3, upper part of the psoas parvus, drawn somewhat to the outer side; 3', insertion of its tendon into the brim of the pelvis; 4, psoas magnus; 4'', one of the origins of the muscle; 4'', insertion of the muscle into the small trochanter of the femur; 5, iliacus; 5'', insertion of the outer fibres of the iliacus below the small trochanter; 6, pyriformis muscle of the left side arising within the pelvis from the sacrum; 6'', insertion of its tendon into the summit of the great trochanter; 7, obturator externus of the left side; +, crura of the diaphragm.

crossed by the internal arched ligament; and below this the kidney with the ureter and renal vessels lie on the muscle, as well as the spermatic vessels and the genito-crural nerve. The external iliac artery rests against its inner border along the brim of the pelvis, but lies over the muscle as it enters the thigh. The lumbar plexus of nerves is imbedded deeply in the substance of the psoas, and its branches issue from the muscle at various points. The anterior crural nerve passes into the thigh lying in the groove between the psoas and iliacus, and the ilio-inguinal and external cutaneous nerves cross the surface of the iliacus. The iliacus lies over the ilium, the anterior head of the rectus femoris, and the hip-joint, to the capsule of which a few of its fibres are sometimes attached. The psoas rests against the vertebrae.

the quadratus lumborum, and the brim of the pelvis, overlapping also the inner border of the iliacus. The common tendon passes downwards in a deep groove between the anterior inferior spine and the ilio-pectineal eminence, and lower down, between the tendon and the capsule of the hip, is a large synovial bursa which sometimes communicates with the cavity of the joint.

**Varieties.**—The *iliacus minor* or *ilio-capsularis* is a small detached portion of the iliacus which is frequently present. It arises from the anterior inferior spine of the ilium, and is

Fig. 249.—SUPERFICIAL MUSCLES OF THE HIP AND THIGH, SEEN FROM BEHIND. (Allen Thomson.)  $\frac{1}{2}$

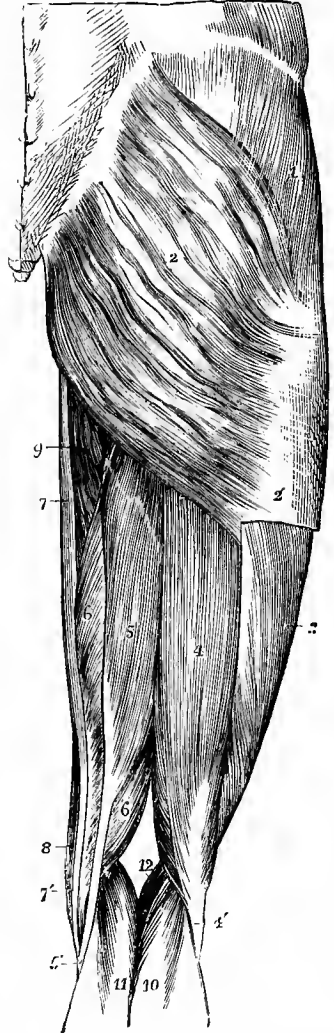
1, gluteus medius, covered by the gluteal portion of the fascia lata; 2, gluteus maximus; 2', lower part of the fascial insertion of the gluteus maximus; 3, vastus externus; 4, biceps flexor cruris; 4', tendon of the biceps; 5, 5', semitendinosus; 6, 6', semimembranosus; 7, 7', gracilis; 8, sartorius; 9, adductor magnus; 10, outer, and 11, inner head of the gastrocnemius; 12, placed in the popliteal space, points to the origin of the plantaris.

inserted into the lower part of the anterior intertrochanteric line of the femur, or into the ilio-femoral ligament.

The *psaos parvus*, a small muscle placed on the surface of the *psaos magnus*, arises from the bodies of the last dorsal and first lumbar vertebræ, and from the disc between them, and soon ends in a flat tendon, which passes along the front and the inner side of the *psaos magnus*, being incorporated with the iliac fascia, and is inserted into the ilio-pectineal line and eminence. This muscle, although it is well developed and constant in animals generally, is very inconstant in the human subject. Out of 450 bodies examined by Gruber it was absent on both sides in 183, on one side only in 69. When present, it is liable to many changes in the place of origin; thus it may be connected only with the first lumbar vertebra, or with the second and the intervertebral substance above it, and it has been observed to commence by two parts or heads separated by an interval.

The **gluteus maximus** is a very large and coarsely fasciculated muscle, quadrilateral in shape, which arises from the posterior fourth of the iliac crest and from the rough surface of the ilium between the crest and the posterior gluteal line, from the back of the last two pieces of the sacrum and the first three pieces of the coccyx, from the great sacro-sciatic ligament, and between the sacrum and the ilium from the aponeurosis of the erector spinæ muscle. Thence it passes downwards and outwards with parallel fibres. The whole of the upper half of the muscle, and the superficial fibres of the lower half are inserted into the strong fascia on the outer side of the thigh; the deeper and larger portion of the lower half forms a flattened tendon which is attached to the gluteal ridge on the upper third of the shaft of the femur.

**Relations.**—The gluteus maximus is superficial throughout. Its inner and lower part is rendered especially prominent by the subjacent ischial tuberosity, and thus forms, with a considerable quantity of overlying fat, the eminence of the buttock. Its lower border is crossed, a little external to the middle, by the fold of the nates. The deep surface of the muscle rests



on the gluteus medius and pyriformis muscles, the tendon of the obturator internus with the two gemelli, the quadratus femoris, a small portion of the adductor magnus, the great trochanter, the ischial tuberosity, and the origins of the hamstring muscles; it covers also the sciatic vessels and nerves as they emerge from the pelvis below the pyriformis, the superficial branch of the gluteal artery passing out above that muscle, and the pudic vessels and nerve lying behind the spine of the ischium.

Between the fascial insertion of the muscle and the great trochanter is a large multilocular bursa, or there may be two or three smaller ones, and another intervenes between it and the upper part of the vastus externus. In some cases there is also a bursa over the ischial tuberosity.

The great size of the gluteus maximus, and the consequent prominence of the buttock, is a characteristic of man as compared with those animals which most nearly approach him in general structure.

**Varieties.**—These are not frequent. The muscle has been seen receiving an additional fasciculus of origin from the lumbar aponeurosis, or from the ischial tuberosity. A distinct slip at the lower border arising from the coccyx occasionally represents the *agitator caudæ* of the

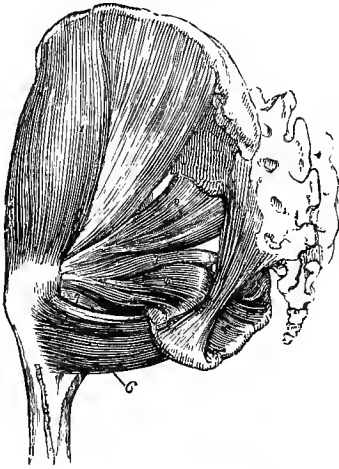


Fig. 250.—DEEP MUSCLES OF THE HIP ON THE LEFT SIDE, FROM BEHIND.  $\frac{1}{4}$

The gluteus maximus, and the muscles of the thigh have been removed. 1, 1, gluteus medius; 2, pyriformis; 3, gemellus superior; 4, gemellus inferior; 5, obturator internus, seen partially within the pelvis, and, after issuing by the sciatic notch, between the gemelli muscles; 6, quadratus femoris; 7, tendon of the obturator externus between the gemellus inferior and quadratus.

lower animals. The fibres arising from the sacro-sciatic ligament and the margin of the sacrum are normally separated by a layer of areolar tissue from the superficial portion, and a powerful development of the deep part has given rise to the bilaminar condition described by Tiedemann and others (Henle).

The **gluteus medius** muscle, covered partly by the gluteus maximus, partly by the fascia lata, arises from the surface of the ilium between the crest, the posterior and the middle gluteal lines, and in front of the gluteus maximus from the strong fascia covering its outer surface. The muscular fibres converge as they descend, the anterior fibres passing obliquely backwards, the posterior fibres obliquely forwards, and terminate in a flattened tendon, which is inserted into an oblique impression directed downwards and forwards on the outer surface of the great trochanter. The tendon is separated by a small bursa from the upper part of the trochanter.

**Relations.**—Between this muscle and the gluteus minimus are the superior gluteal nerve and the deep branches of the gluteal vessels. At its anterior border its fibres are parallel to and generally united with those of the gluteus minimus. This border also is overlapped by the tensor vaginae femoris. The posterior border is in contact with the pyriformis, the superficial part of the gluteal vessels passing between the two.

**Varieties.**—Some of the deeper fibres of the muscle occasionally end in a separate tendon which is inserted into the upper border of the great trochanter. The posterior border of the muscle is sometimes closely united to the pyriformis, or some of the fibres end on the tendon of that muscle. A bursa is occasionally present between the tendon of this muscle and the pyriformis (1 in 15, Macalister).

The **gluteus minimus**, covered by the preceding muscle, arises from the whole space on the ilium between the middle and inferior gluteal lines. The fibres, converging as they descend, terminate in an aponeurotic tendon on the outer surface of the muscle, which becoming narrowed is inserted into an impression on the front of the great trochanter. The tendon is bound down to the prominence of the trochan-

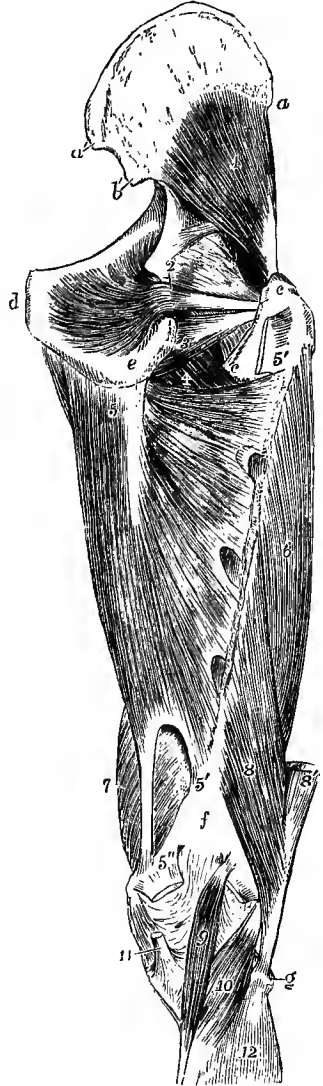


ter by a strong fibrous band which joins it from the upper margin of the capsule of the hip-joint. A synovial bursa is interposed between the tendon and the tubercle of the femur.

**Relations.**—The anterior border of the muscle is in contact with that of the gluteus medius; its deep surface with the capsule of the hip-joint, and the posterior head of the rectus

Fig. 251.—DEEP MUSCLES OF THE RIGHT HIP AND THIGH, FROM BEHIND. (Allen Thomson.)  $\frac{1}{2}$

*a*, anterior, *a'*, posterior superior spine of the ilium; *b'*, posterior inferior spine; *c*, *c*, great and small trochanters; *d*, symphysis pubis; *e*, ischial tuberosity; *f*, popliteal surface of femur; *g*, head of fibula; 1, gluteus minimus; 2, obturator internus; the gemelli have been removed; 3, obturator externus; 4, small part of the back of the pectineus and adductor brevis; 5, origin of the adductor magnus from the lower part of the ischial tuberosity; 5', 5'', line of insertion of this muscle on the shaft of the femur, in which are seen three arched tendinous intervals for the passage of the perforating vessels: the upper division of the muscle, or adductor minimus, extends down to the second arch; 5'', tendon of insertion into the adductor tubercle; between the lower 5' and 5'', the interval through which the femoral vessels pass into the popliteal space; the upper 5' is placed upon the cut end of the quadratus femoris; 6, vastus externus; 7, vastus internus; 8, femoral head of the biceps; 8', its ischial head, cut short; 9, plantaris muscle; at its upper end the outer head of the gastrocnemius; the figure 5'', is upon the cut inner head; 10, popliteus; 11, tendon of the semimembranosus; 12, upper part of the soleus.



femoris; its outer surface is covered by the gluteus medius, gluteal vessels and superior gluteal nerve; and its posterior border is covered by the pyriformis muscle.

**Varieties.**—This muscle may be divided into an anterior and a posterior part, or it may send detached slips to the hip-joint, to the pyriformis, to the gemelli superior, or to the outer part of the origin of the vastus externus. The anterior fibres are occasionally separate, representing the *scansorius* muscle of apes.

The **tensor vaginæ femoris** or ilio-aponeurotic muscle (fig. 252, 5) arises by tendinous fibres from the external margin of the iliac crest at its fore part, and from part of the notch between the two anterior iliac spines external to the attachment of the sartorius, and by some fleshy fibres from the fascia covering the gluteus medius: passing downwards and a little outwards and backwards, it is inserted between two laminæ of the fascia lata from three to four inches below the great trochanter of the femur. The outer of these laminæ is continued upwards on the muscle in its whole extent, being part of the general investment of the limb, the deeper is connected above with the origin of the rectus femoris, and with the band attaching the gluteus minimus to the hip-joint. The fibres in the fascia prolonged from the insertion of the muscle form part of the ilio-tibial band, and can be followed in this down to the outer tuberosity of the tibia.

**Relations.**—This muscle lies upon the anterior border of the gluteus medius, the upper parts of the rectus femoris and vastus externus muscles, and the ascending branch of the external circumflex artery. At its origin it lies between the sartorius and gluteus medius muscles.

The **pyriformis** muscle arises within the pelvis by three fleshy digitations from the second, third and fourth pieces of the sacrum between and outside the anterior sacral foramina, slightly from the hinder border of the ilium immediately below the posterior inferior spine, and from the great sacro-sciatic ligament. The muscle passes out of the pelvis by the great sacro-sciatic foramen, and is inserted into a mark on the upper border of the great trochanter by a rounded tendon which is closely united for some distance before its insertion to the subjacent tendon of the obturator internus and gemelli muscles.

**Relations.**—The anterior surface of the pyriformis is in contact, inside the pelvis, with the nerves of the sacral plexus, a thin portion of the pelvic fascia, the anterior branches of the internal iliac vessels, and the rectum; while in the gluteal region it lies over the ischium and the hinder part of the gluteus minimus, by which it is usually separated from the hip-joint. Its posterior surface is covered by the sacrum and the gluteus maximus; and the tendon at its insertion is beneath the gluteus medius, there being occasionally a bursa between the two. Between the upper border of the muscle as it escapes from the pelvis and the bone the gluteal vessels and superior gluteal nerve issue; and at its lower border, between it and the superior gemellus, the sciatic and pudic vessels and nerves make their appearance.

**Varieties.**—This muscle is frequently pierced by the external popliteal nerve, and is thus divided more or less completely into two parts. It may be united with the gluteus medius, or give fibres to the gluteus minimus, or receive the insertion of the superior gemellus. It may have only one or two sacral attachments; or again its tendon may be inserted into the capsule of the hip-joint. Its entire absence has also been noted.

The **obturator internus** muscle (fig. 251, 2; 254, 3), in great part lodged within the pelvis, arises from the deep surface of the obturator membrane except at its lower part, from the fibrous arch which completes the canal for the obturator vessels and nerve, and from the pelvic surface of the hip-bone, externally between the thyroid foramen and the ilio-sciatic notch, reaching up to the ilio-pectineal line, and internally between the foramen and the margin of the subpubic arch; a few fibres also arise from the obturator fascia, which is in contact with the deep surface of the muscle. Its fibres converging as they proceed backwards from this origin, the muscle emerges from the pelvis by the small sacro-sciatic foramen, turning round the trochlear surface of the ischium, and is directed outwards, to be inserted, in connection with the gemelli, into an impression on the fore part of the inner surface of the great trochanter. The tendon occupies the surface of the muscle which is towards the bone, and consists as it passes through the foramen of four or five narrow portions which, commencing independently in the substance of the pelvic portion of the muscle, receive the pinnately disposed fleshy fibres. A layer of cartilage lines the trochlear groove of the bone, and forms a series of ridges with intervening grooves corresponding to the divisions of the tendon, while the movement of the latter is facilitated by a large synovial bursa. Another bursa, of much smaller size, elongated and narrow, is sometimes placed between the tendon and the capsule of the hip-joint. These bursæ are occasionally continuous with one another.

**Relations.**—The deep surface of the pelvic portion is in contact with the obturator portion of the pelvic fascia, and near its lower border with the pudic vessels and nerve. The outer surface is in contact with the bone and obturator membrane. At its upper border the obturator vessels and nerve pass through the thyroid foramen. The extrapelvic portion lies between the gemelli and in contact with the ischium and capsule of the hip-joint. It is covered by the great sacro-sciatic ligament, the sciatic vessels and nerves, and the gluteus maximus.

The **gemelli** (gemini) are two small narrow muscles, consisting chiefly of fleshy fibres extended horizontally on each side of the tendon of the obturator internus; and they are named from their position above and below the tendon. The *gemellus superior*, which is usually the smaller muscle, arises from the outer and lower part of the ischial spine; the *gemellus inferior* takes origin from the upper part of the tuberosity

of the ischium, along the lower border of the groove for the obturator internus. Passing outwards, they join the tendon of the internal obturator muscle, and are inserted with that into the great trochanter. The two muscles usually meet at their origin beneath the tendon of the obturator, while at their insertion they overlap and more or less conceal it.

**Relations.**—The superior gemellus is placed immediately below the pyriformis; the inferior gemellus is above the quadratus femoris, and at its insertion is close to the tendon of the obturator externus muscle. These muscles may be regarded as portions of the obturator internus arising outside the pelvis.

**Varieties.**—The gemellus superior is often very small, and not unfrequently is altogether absent. Absence of the gemellus inferior has also been observed, but more rarely than that of the upper muscle.

The **quadratus femoris** muscle, of an oblong shape, arises from an impression along the outer border of the ischial tuberosity, and proceeding horizontally outwards, is inserted into the tubercle of the quadratus and the back of the femur immediately below this, reaching to the level of the small trochanter.

**Relations.**—The upper border of this muscle is in contact with the inferior gemellus; the lower with the adductor magnus, the transverse branch of the internal circumflex artery passing between the two. It conceals the outer part of the obturator externus, and also the lesser trochanter, which is separated from it by a small bursa.

**Varieties.**—The quadratus femoris may be entirely absent and replaced by an enlarged gemellus inferior.

The **obturator externus** muscle (fig. 248, 7; 251, 3) arises from the outer surface of the obturator membrane for the inner half of its extent, from the femoral surface of the body of the pubis, and from the conjoined rami of the pubis and ischium. The fibres converge as they are directed outwards in the groove between the acetabulum and the tuberosity of the ischium to the lower part of the hip-joint; then winding backwards and upwards, closely applied to the lower and hinder surfaces of the neck of the femur, they end in a tendon which is inserted into the bottom of the angular fossa of the great trochanter.

**Relations.**—The obturator externus is concealed in front by the pectineus, ilio-psoas, adductor brevis and adductor magnus muscles; near its insertion it is covered behind by the quadratus femoris: its deep surface is closely connected to the capsule of the hip as it passes backwards. The obturator vessels are placed between the muscle and the obturator membrane, and the superficial part of the obturator nerve passes above it, while the deep part perforates it near its upper border.

**Nerves.**—The ilio-psoas is supplied by the second and third lumbar nerves, the branches for the psoas arising from the nerves as they lie in the substance of the muscle, while those for the iliacus are given off from the anterior crural nerve. The gluteus maximus receives the inferior gluteal nerve (51, 1, 2s); the gluteus medius and minimus and the tensor vaginae femoris are supplied by the superior gluteal (4, 51, 1s). The nerves to the pyriformis (2s), to the obturator internus and superior gemellus (1, 2s), and to the quadratus femoris and inferior gemellus (51, 1s) spring from the sacral plexus; and the obturator externus is supplied by the deep part of the obturator nerve (2, 3, 41).

**Actions.**—The *ilio-psoas* muscle bends the thigh on the body, or the body on the thigh, according as either of these is the more fixed. The psoas also assists in bending the lumbar portion of the spine, either forwards or laterally.

The *gluteus maximus* muscle is the chief extensor of the hip-joint. By its agency the bent thigh is brought into a line with the body. The lower part of the muscle also acts as an adductor and external rotator of the limb, while the upper part will assist in producing abduction. Its most powerful action, and that in connection with which it is so largely developed in the human subject, is to extend the trunk upon the thigh when bent forwards. It also comes into operation in ascending an incline or a stair, in leaping, and in rising from the sitting posture. But although the full contraction of the glutei maximi is required to bring the body into the erect posture, it is not necessary for its maintenance when complete, the trunk being then supported on the thigh-bones by the tension of ligaments, while the body is so poised that its centre of gravity is placed behind the vertical plane passing through the middle of the hip-joints (see p. 183). By means of its insertion into the ilio-tibial band of

the fascia lata, which is attached below to the fore part of the outer tuberosity of the tibia, the gluteus maximus is farther enabled to exercise an influence upon the knee, steadying and supporting that joint in the extended position during standing, when the proper extensor muscles are relaxed.

The *gluteus medius* and *minimus* are powerful abductors of the thigh when the hip-joint is extended, and along with the tensor vaginae femoris, come principally into action in supporting the body on one limb, and in the rotation of the pelvis on the two limbs alternately which takes place in walking. Their anterior fibres draw forwards the great trochanter, and rotate the limb inwards, while the posterior part of the minimus produces outward rotation. In proportion as the hip is flexed, they lose their power as abductors, and become inward rotators.

The *tensor vaginae femoris* aids the gluteus medius and minimus in rotating inwards and abducting the limb, in the latter case being combined in its action with the upper part of the gluteus maximus. Owing to its mode of insertion, moreover, it will assist the gluteus maximus in supporting the knee in the extended position, counteracting the tendency of that muscle to draw the ilio-tibial band backwards, and thus ensuring that the traction is exercised upon the tibia in the direct line of the thigh.

The *pyriformis*, *obturator internus*, and *gemelli* muscles support the hip-joint posteriorly, and rotate the limb outwards when it is extended, but become abductors when the hip is flexed. The *quadratus femoris* rotates the thigh outwards and assists in adducting. The *obturator externus* is also principally an external rotator, but it is farther a flexor and adductor of the thigh, bringing the uppermost of the two limbs into position when the thighs are crossed in sitting. It supports the hip-joint posteriorly and inferiorly.

#### THE POSTERIOR FEMORAL OR HAMSTRING MUSCLES.

At the back of the thigh are three long flexor muscles of the knee-joint, viz., the biceps, semitendinosus, and semimembranosus.

The **biceps flexor cruris** muscle (fig. 249, 4) consists of two parts, arising one from the hip-bone, the other from the femur, which unite inferiorly to terminate on the fibula. The *long head* arises by a tendon common to it and the semitendinosus from the inner impression on the upper part of the ischial tuberosity, receiving also some fibres from the great sacro-sciatic ligament; the *short head* (fig. 251, 8) arises from the outer lip of the linea aspera in its whole extent, from the upper two-thirds of the external supracondylar line, and from the adjacent external intermuscular septum. The muscular fibres from both heads end in a common tendon, which is inserted into the upper and outer part of the head of the fibula by two portions, which embrace the external lateral ligament of the knee-joint. Some of the fibres of the tendon, passing forwards and inwards, are inserted into the outer tuberosity of the tibia, and from the posterior border others are given off to the fascia of the leg.

**Relations.**—The upper end of the biceps is covered by the gluteus maximus; in the rest of its extent the muscle is subcutaneous. It lies upon the semimembranosus, the great sciatic nerve, the adductor magnus, and the outer head of the gastrocnemius; its inner border is in contact with the semitendinosus and semimembranosus, and at its lower end it forms the upper and outer boundary of the popliteal space. A bursa is generally present between the tendon and the external lateral ligament, and there is sometimes another between the long head and the origin of the semimembranosus.

**Varieties.**—The short head may be absent; or there may be an additional head arising from the ischial tuberosity, or from the linea aspera, or from the inner supracondylar ridge of the femur, or from various other parts. A slip has been found passing from the long head to the gastrocnemius or the tendo Achillis.

The **semitendinosus** muscle (fig. 249, 5; 254, 12), closely united at its origin with the long head of the biceps, arises from the tuberosity of the ischium, and from the tendon common to it with the biceps for about three inches; it descends on the back of the thigh, and terminates in the lower third in a long, rounded, and slender tendon, which passes along the inner side of the popliteal space, resting on the semimembranosus, and curves forwards to be inserted in an expanded form into the upper part of the inner surface of the tibia, a considerable process being sent

from its lower border to the fascia of the leg. There the tendon is on the same plane with, but below that of the gracilis, both being under cover of the sartorius, and a bursa separates the three tendons from the internal lateral ligament of the knee-joint. The belly of the muscle is traversed about its middle by a thin oblique tendinous intersection.

The **semimembranosus** muscle (fig. 249, 6 ; 254, 11) arises from the tuberosity of the ischium, above and to the outside of the origin of the biceps and semitendinosus, by a strong flattened tendon which is grooved on its posterior surface for the reception of the common tendon of those two muscles. The tendon of origin is prolonged downwards on the outer side of the muscle for three-fourths of the length of the thigh ; from it spring numerous short fleshy fasciculi which are directed obliquely downwards and inwards, forming a thick fusiform belly, and terminate upon the tendon of insertion on the opposite border of the muscle. The lower tendon makes its appearance about the middle of the thigh, becomes free from muscular fibres at the level of the knee, and, turning somewhat forwards, is inserted mainly into the lower part of the horizontal groove on the back of the inner tuberosity of the tibia. One considerable expansion is sent upwards and outwards to the posterior ligament of the knee-joint (see p. 184), another is continued downwards to the fascia covering the popliteus muscle, and a few fibres join the internal lateral ligament of the joint.

**Relations.**—At its upper part the semimembranosus crosses obliquely from without inwards beneath the conjoined biceps and semitendinosus, and the latter muscle lies upon it in its whole length. Its deep surface rests upon the adductor magnus, and the great sciatic nerve lies along its outer border. Between the lower tendon and the inner head of the gastrocnemius is a large bursa which often communicates with the cavity of the knee-joint, and a second smaller one separates the main portion of the tendon from the prominent upper margin of the groove on the tibia.

The hamstring muscles descend for the greatest part of their length in contact with one another, being bound down by the fascia lata ; but inferiorly they diverge, the biceps passing to the outer side, and the semimembranosus and semitendinosus to the inner side of the knee, forming the superior borders of a diamond-shaped hollow at the back of the knee—the *popliteal space*, the inferior margins of which are formed by the heads of the gastrocnemius muscle.

**Varieties.**—Great reduction of the semimembranosus muscle, and complete absence have been observed in several instances. It has also been found double, arising mainly from the great sacro-sciatic ligament, and giving a slip to the femur, or to join the adductor magnus.

The name of *tensor fasciæ suralis* or *ischio-aponeuroticus* has been given to a muscular slip passing from one or other of the hamstring muscles to the fascia of the back of the leg.

**Nerves.**—These muscles are all supplied by the great sciatic nerve, the branches being derived from its internal popliteal division, with the exception of that to the short head of the biceps, which is given off by the external popliteal division.

**Actions.**—The *hamstring muscles* flex the knee, and when that joint is bent they can rotate the tibia—the biceps outwards, the semitendinosus and, to a less extent, the semimembranosus inwards. They are farther powerful extensors of the hip, and by their position they set a limit to flexion of that joint so long as the knee is extended.

#### THE ANTERIOR MUSCLES OF THE THIGH.

The **sartorius** muscle is very long, narrow, and ribbon-shaped, and has the longest fascicles of all the muscles of the body. It arises by a short tendon from the anterior superior spine of the ilium, and from a small part of the anterior margin of that bone immediately below ; passing downwards and inwards across the front of the thigh, it is inserted by a thin flattened tendon into a slight roughness on the inner side of the tibia near the tubercle, sending off one aponeurotic expansion from its upper border to the capsule of the knee-joint, and another from its lower border to the fascia of the leg.

**Relations.**—In this long course the sartorius is directed obliquely inwards over the anterior part of the thigh in the upper half, and then nearly vertically on the inner aspect of the limb as far as the knee; below this it curves forwards to its place of attachment. The muscle is covered only by the fascia lata and the integument. It passes over the iliacus and rectus femoris muscles, the anterior crural nerve and femoral vessels, the pectineus, the adductor longus, adductor magnus, and vastus internus muscles. The tendon of insertion

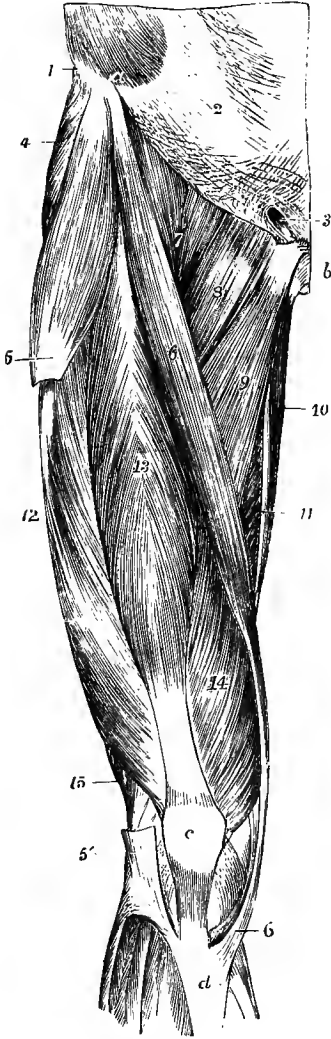


Fig. 252.—SUPERFICIAL MUSCLES OF THE FRONT OF THE THIGH. (Allen Thomson.)  $\frac{1}{2}$

*a*, anterior superior spine of the ilium; *b*, symphysis pubis; *c*, patella; *d*, tubercle of the tibia; 1, insertion of the external oblique muscle into the iliac crest; 2, its aponeurosis; 3, external abdominal ring; 4, gluteus medius; 5, tensor vaginae femoris at the place of its insertion into the ilio-tibial band, which has been removed between 5 and 5', where it is seen descending to be attached to the tibia; 6, sartorius; 6', its insertion; 7, iliopsoas; 8, pectineus; 9, adductor longus; 10, gracilis; 11, part of adductor magnus; 12, vastus externus; 13, rectus femoris; 14, vastus internus; 15, biceps flexor cruris.

covers those of the gracilis and semitendinosus, being separated from them, however, by a prolongation of the bursa which is interposed between these tendons and the internal lateral ligament of the knee-joint. The inner border of this muscle and the most projecting part of the adductor longus form the sides, and Poupart's ligament forms the base, of a triangular space in the upper third of the thigh, through the middle of which the femoral artery passes. This usually receives the name of *Scarpa's triangle*.

**Varieties.**—The sartorius not unfrequently receives fibres of origin from the outer end of Poupart's ligament. A separate head from the notch of the ilium, a supplementary slip of origin from the ilio-pectineal line, and one from the pubis close to the symphysis have also been observed. The muscle has in several instances been found divided into two parts similarly attached; or the accessory portion is inserted into the fascia lata, femur, or ligament of the patella, or into the tendon of the normal one or of the semitendinosus. The tendon of insertion has been found to end in the fascia lata, in the capsule of the knee-joint, and in the fascia of the leg. A tendinous intersection has been seen in rare cases. Absence of the muscle has also been noted.

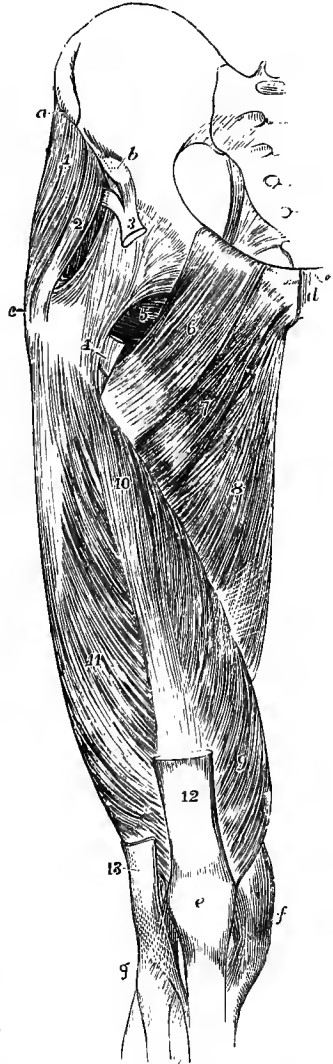
The **quadriceps extensor cruris**, the extensor muscle of the knee, is the largest muscle in the body. It consists of four parts, one of which, the rectus femoris, descends from the hip-bone and is distinct down to the lower tendon of the muscle, while the other three, viz., the vastus externus, vastus internus, and crureus, are more or less closely united together, and cover the whole of the anterior and lateral surfaces of the thigh-bone, from which they arise.

*a*. The *rectus femoris* is spindle-shaped, and extends in a straight line from the pelvis to the patella. It arises from the ilium by two tendinous heads, the anterior of which is attached to the anterior inferior spine, and the posterior to the impression on the outer surface of the bone immediately above the acetabulum. The two join at an angle of about 60° close below the margin of the acetabulum, and form a tendon which is prolonged on the anterior surface, and then in the centre of the muscular mass,

to beyond the middle of the thigh. From this the fleshy fibres spring pinnately, and, passing downwards and backwards as they diverge, they end on the inferior tendon, which extends over the lower two-thirds of the posterior surface of the belly. The lower tendon becomes free about three inches above the patella, and forms a flat band which is attached to the upper border of that bone, being joined with the tendons

Fig. 253.—DEEP MUSCLES OF THE FRONT OF THE THIGH. (Allen Thomson.)  $\frac{1}{2}$

*a*, anterior superior, and *b*, anterior inferior spine of the ilium; *c*, great trochanter; *d*, symphysis pubis; *e*, patella; *f*, inner side of the knee-joint; *g*, head of the fibula; 1, gluteus medius; 2, gluteus minimus; 3, upper tendon of the rectus, dividing into its two portions; 4, points to the cut tendon of insertion of the ilio-psoas muscle; 5, part of the obturator externus and quadratus femoris; 6, pectineus; 7, adductor brevis; 8, adductor magnus; 9, vastus internus; 10, creureus; 11, vastus externus; 12, lower tendon of the rectus; 13, lower part of the ilio-tibial band of the fascia lata.



of the deeper portions of the quadriceps, and forming with them the common tendon of insertion.

According to W. R. Williams the posterior or "reflected" head of the rectus is the main tendon, and the anterior or "straight" head is a secondary attachment formed by a thickening of the fascial investment and appearing only in the last months of fetal life. ("The Anatomy of the Quadriceps Extensor Cruris," Journ. Anat., xiii.)

*b*. The *vastus externus* has a narrow origin from the femur, along the upper half of the anterior intertrochanteric line, the fore and outer parts of the root of the great trochanter, the outer side of the gluteal ridge and the upper half of the linea aspera, and to a slight extent also from the external intermuscular septum. The origin takes place for the most part by a strong aponeurosis, which extends over the surface of the muscle for the upper two-thirds of its length. The fleshy fibres spring from this aponeurosis, and some deeper ones also from the bone immediately beneath it, and are directed downwards and forwards to end on the aponeurosis of insertion, which occupies the deep surface and anterior border of the mass in its lower half, and is continued down to the outer part of the upper border of the patella, joining the other portions in the common tendon, and sending also an expansion downwards to the capsule of the knee-joint. A few of the superficial fibres join the outer border of the rectus tendon, and its deep surface is connected to a greater or less extent with the subjacent creureus, especially in its lower part.

*c* and *d*. The remaining portions of the muscle, viz., the vastus internus and creureus, appear at first sight to be inseparably united and to form one mass. If, however, the rectus tendon be turned well downwards, there comes into view, above the patella, a narrow interval which can be followed up between the two tendons in the

direction of a line from the inner part of the patella to the lower end of the anterior intertrochanteric line of the femur, and the two portions can thus be separated, although their fleshy fibres are usually continuous above. The *vastus internus*, like the *vastus externus*, has a narrow origin from the femur, by a superficial aponeurosis and deeper fleshy fibres, along the spiral line and the inner lip of the *linea aspera*, while in the lower half numerous fibres arise from the tendons of the adductor longus and adductor magnus. The muscular fibres are directed downwards and forwards, and end mostly on a deep aponeurosis which forms below the innermost part of the common tendon; the lower fibres, however, which pass inwards more obliquely than the upper ones, end by being inserted, shortly tendinous, into the inner margin of the patella for its upper half. A few superficial fibres also join the adjacent margin of the rectus tendon, and from its lower border an expansion is given off to the capsule of the knee.

The *crureus* has a fleshy origin from the anterior surface of the femur for its upper two-thirds, from the outer surface of the bone in front of and below the attachment of the *vastus externus*, and from the lower half of the external intermuscular septum. The fibres are directed downwards, those of the outer and lower part also considerably forwards, and they end on a superficial aponeurotic lamina which forms the deepest portion of the common tendon. The *crureus* consists of four or five superposed fleshy layers, the origins of which form a series of transverse arches with intervening bare spaces on the front of the femur; and between this portion of the muscle and the *vastus internus* the greater part of the internal surface of the bone is also free from muscular attachment.

The *common* or *suprapatellar tendon*, in which the four portions of the quadriceps muscle terminate below, is broad and flat, and is inserted into the fore part of the upper border of the patella, a few fibres being prolonged over the anterior surface of the bone into the superficial portion of the infrapatellar tendon or ligamentum patellæ (p. 184).

*Subcrureus*.—This name is given to one or two thin bands of muscular fibres which might be regarded as the deepest layer of the *crureus*. It arises from the lower part of the anterior surface of the femur, and is inserted below by scattered fibres into the upper part of the synovial membrane of the knee-joint.

**Relations.**—The rectus is covered at its upper end by the tensor *vaginæ femoris*, *iliacus* and *sartorius* muscles, and the acetabular tendon lies beneath the *gluteus minimus*. In the rest of its extent it is covered only by fascia. It rests upon the capsular ligament of the hip-joint and the deep portions of the quadriceps: behind it pass also the external circumflex artery and branches of the anterior crural nerve. The *vastus externus* forms the large mass on the outer side of the thigh. It is covered by the *fascia lata* and the aponeurotic insertions of the *gluteus maximus* and *tensor vaginæ femoris*; and its anterior border is concealed by the rectus. It rests upon the *crureus*, and the branches of the external circumflex artery and anterior crural nerve entering it close to its anterior border pass between the two. The *vastus internus* is partly covered by the *sartorius* and *rectus*; between these muscles it is superficial, giving rise to the prominence at the lower part of the inner side of the thigh. In the middle two-fourths of the thigh it forms the outer wall of the space called *Hunter's canal*, which lodges the femoral vessels. The *crureus* is almost completely covered by the *rectus* and *vasti*, only a small portion being superficial on the outer side, behind the free posterior border of the *vastus externus*. Beneath the *suprapatellar tendon* is a *hursa* which communicates in most cases freely with the cavity of the knee-joint.

**Varieties.**—The parts of the quadriceps muscle are not liable to many anomalies. The rectus has been found with an additional origin from the anterior superior spine of the ilium, or wanting its acetabular origin. The *vasti* muscles are sometimes bilaminar, a condition which is normal in many birds.

**Nerves.**—The *sartorius* and quadriceps extensor *cruris* are supplied by the anterior crural nerve (2, 3, 4 l).

**Actions.**—The *sartorius* muscle produces flexion of the hip and knee-joints, accompanied by eversion of the thigh: it also assists in rotating inwards the leg. It has been supposed to



be the muscle principally concerned in producing the posture assumed by the tailor in sitting, and hence its name.

The *quadriceps extensor cruris* extends the knee-joint; but its action is not requisite for the maintenance of the erect attitude (see p. 189), the knee-joint remaining in complete extension without muscular aid while the foot is firmly planted on the ground. This may be tested by the fact that the patella of a person standing with the knee extended will be found to lie quite loosely, but will become at once fixed when an attempt is made to lift the foot. The *rectus femoris*, besides extending the knee, also flexes the hip: it acts mainly from its anterior head of origin when the thigh is fully extended, and the posterior head alone is tense when the thigh is bent. The lower fibres of the *vastus internus* draw the patella inwards during extension of the knee.

#### THE INTERNAL FEMORAL OR ADDUCTOR MUSCLES.

The **gracilis** or **adductor gracilis** muscle, long and slender, arises by an aponeurotic tendon from the inner margin of the pubic bone, along the lower half of the symphysis and the whole length of the inferior ramus. Thin and flat at first, the muscle becomes narrower and thicker as it descends; and in the lower third of the thigh it ends in a rounded tendon which curves forwards below the knee, and, becoming flattened and expanded, is inserted into the inner side of the tibia, on the same plane with but higher than the semitendinosus, and under cover of the tendon of the sartorius.

**Relations.**—This muscle is covered by the fascia lata, except where its tendon is overlapped by the sartorius; the deep surface rests against the adductor brevis and adductor magnus, and the tendon crosses the internal lateral ligament of the knee-joint. A bursa separates it from that ligament.

The **pectineus** muscle (fig. 252, 8; 253, 6), flat and oblong, arises from the iliopectineal line, and slightly from the surface of bone in front of it, between the iliopectineal eminence and the pubic spine; a few superficial fibres spring also from the upper part of the fascia covering the muscle. Inclining outwards and backwards as it descends, it is inserted by a flat tendon into the femur behind the small trochanter, and into the upper part of the line which connects the linea aspera with that prominence.

**Relations.**—The pectineus is in relation, by its anterior surface, with the pubic portion of the fascia lata and the femoral vessels; by the posterior surface, with the obturator nerve, the external obturator and adductor brevis muscles, and the capsular ligament of the hip-joint. Its outer border is in contact with the psoas magnus, and the internal circumflex vessels pass between the two; its inner border touches the adductor longus.

The **adductor longus** (fig. 252, 9), a flat triangular muscle, internal to the pectineus and lying in the same plane, arises by a short tendon from the body of the pubis below the crest and near the angle, and is inserted into the inner margin of the linea aspera, by an aponeurotic tendon which is closely united to the vastus internus in front and the adductor magnus behind.

**Relations.**—This muscle is covered by the fascia lata, the sartorius, and the femoral vessels; the posterior surface rests on the adductor brevis and adductor magnus, the deep femoral artery and the superficial portion of the obturator nerve. The outer border touches the pectineus above, but is separated from it by a small interval below; the inner border is in apposition with the gracilis and forms the inner boundary of Scarpa's triangle.

The **adductor brevis** (fig. 253, 7), thick above and broad below, has a fleshy and tendinous origin, from the femoral surface of the body and inferior ramus of the pubis, below the adductor longus and between the gracilis and obturator externus; directed obliquely backwards and outwards, it is inserted by a flat tendon into the whole of the line leading from the small trochanter of the femur to the linea aspera, immediately behind the insertion of the pectineus.

**Relations.**—The adductor brevis is concealed at its origin by the adductor longus and at its insertion in part by the pectineus; it is crossed by the superficial division of the obturator nerve, and by the deep femoral artery; it rests on the adductor magnus and deep division of the obturator nerve, and by its deep surface is in contact above with the obturator externus, the internal circumflex artery passing between the two.

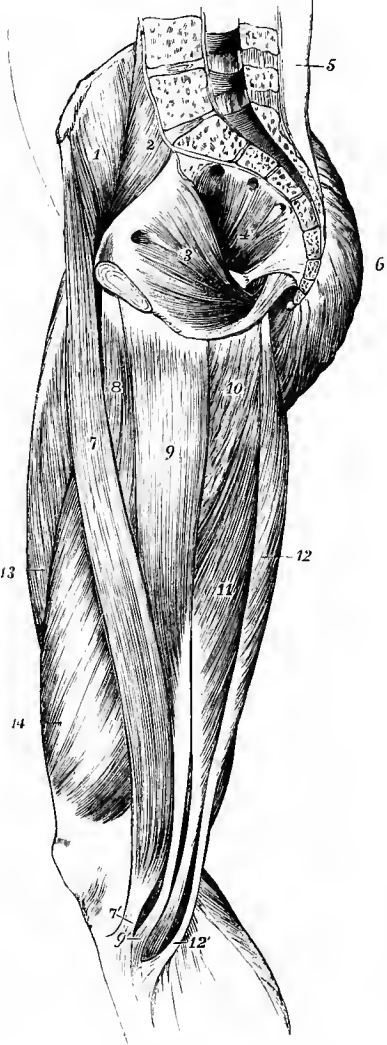


Fig. 254.—MUSCLES OF THE INNER SIDE OF THE THIGH AND INTERIOR OF THE PELVIS. (Allen Thomson.)  $\frac{1}{2}$

1, iliacus; 2, psoas magnus; 3, obturator internus, with its fibres converging towards the small sacro-sciatic foramen; 4, pyriformis, with three heads of origin, and its fibres converging towards the great sacro-sciatic foramen; 5, lumbar aponeurosis covering the erector spinæ muscle; 6, gluteus maximus; 7, sartorius; 7', its tendon inserted below the tuberosity of the tibia; 8, adductor longus; 9, gracilis, 9', its tendon passing under that of the sartorius; 10, part of the adductor magnus; 11, semimembranosus; 12, semitendinosus, 12', its insertion, and between 9' and 12', the tendon of the semimembranosus passing to its insertion on the inner tuberosity of the tibia.

The **adductor magnus** muscle (fig. 251, 5; 253, 8) arises slightly from the lower part of the body of the pubis external to the origin of the adductor brevis, from the inner margin of the conjoined ischio-pubic rami, and from the lower portion of the tuberosity of the ischium. The muscular fibres diverge from their origin, those from the body of the pubis passing horizontally outwards, the succeeding ones becoming longer and directed with increasing degrees of obliquity downwards, and those from the ischial tuberosity descending almost vertically. The insertion takes place, 1, by short tendinous fibres into the back of the femur along the inner side of the gluteal ridge, the internal lip of the linea aspera, and the internal supracondylar line for about an inch, and, 2, by a distinct rounded tendon, continued from the thick inner border of the muscle, into the adductor tubercle on the internal condyle of the femur: an aponeurotic layer unites the outer side of this tendon to the lower part of the internal supracondylar line.

Along the femoral attachment the insertion is interrupted by three or four tendinous arches through which pass the perforating arteries; and below the level of the inferior bifurcation of the linea aspera, between the two portions of the insertion of the muscle, an interval is left for the passage of the femoral vessels backwards into the popliteal space. Extending upwards from the opening for the femoral vessels is an aponeurotic membrane which consists of transverse fibres passing from the surface of the vastus internus to the adductor magnus and adductor longus muscles. It becomes thinner as it ascends, and encloses a three-sided passage called *Hunter's canal*, which contains the femoral artery and vein, together with the internal saphenous nerve.

The adductor magnus consists of two parts, which are as a rule quite distinct. The anterior and superior portion, which is often described as a separate muscle under the name of *adductor minimus*, arises from the body of the pubis and the ischio-pubic rami : its fibres form a thin layer which is inserted into the femur from the lower border of the quadratus femoris to the upper end of the linea aspera, and sometimes for a short distance along that line. The posterior and inferior portion, much the larger, arises from the ischial ramus internal to the foregoing, and from the ischial tuberosity by a strong tendon which descends on the posterior aspect of the muscle for the upper third of the length of the thigh. The fibres springing from the fore part of this origin and the outer side of the tendon pass obliquely to the linea aspera below the insertion of the superior portion, and to the upper part of the internal supracondylar line ; while those proceeding from the hinder part of the mass and the inner border of the tendon descend on the inner side of the opening for the femoral vessels to the condylar insertion.

**Relations.**—This muscle is in contact in front with the long and short adductors, the vastus internus, the obturator nerve, and the profunda artery, behind with the hamstring muscles, gluteus maximus, and great sciatic nerve, internally with the gracilis and sartorius muscles, superiorly with the obturator externus and quadratus femoris muscles ; and along the line of attachment to the femur it is pierced by the femoral and perforating arteries.

**Varieties.**—The adductor muscles are so closely related that their varieties may be conveniently considered together. The *pectineus* is sometimes divided more or less completely into two parts, which receive their nerves from different sources, viz., the inner from the obturator, and the outer from the anterior crural. This division occurs naturally in many animals. The muscle has also been seen attached to the capsule of the hip-joint, or even inserted into it. The *adductor longus* may be double, or it may extend as far as the knee with its tendon of insertion inseparable from that of the adductor magnus. Its outer border may be continuous with, or receive a slip from, the adjacent edge of the pectineus. The *adductor brevis* is frequently found divided into two or three parts, or it may be incorporated with the adductor magnus. The *adductor magnus* varies in the degree of its segmentation. Its condylar part has been found distinct from the rest of the muscle, a condition which is usual in apes. On the other hand, the muscle has been found with its upper part completely united to the quadratus femoris.

**Nerves.**—The adductor muscles as a whole are supplied by the obturator nerve (2, 3, 4 1), but the adductor magnus likewise receives a branch from the great sciatic, and the pectineus has regularly a branch from the anterior crural, while an offset to it from the obturator nerve is only occasionally present.

**Actions.**—All these muscles adduct the thigh. In addition to this action, the *pectineus*, *adductor longus* and *adductor brevis* are accessory flexors of the hip, while the strong part of the *adductor magnus* springing from the ischial tuberosity aids in extending that joint. The *gracilis* also flexes the knee and rotates the leg inwards. The adductors, acting with their opponents the gluteal muscles, balance the body upon the femur in walking, and the adductor magnus supports the pelvis and steadies the hip-joint in standing.

#### THE MUSCLES AND FASCLE OF THE LEG.

**FASCLE.**—The **aponeurosis of the leg** invests the muscles closely, but is not continued over the subcutaneous surfaces of the bones. It is thus intimately united with the periosteum over the head and the anterior and inner borders of the tibia, the head of the fibula, and the inner and outer malleoli. It is thicker on the front of the leg than behind, especially at the upper part, where it is very dense and gives origin to the subjacent muscles. Posteriorly it is continuous with the fascia lata on the back of the thigh, and near the knee it receives accessions from the tendons of the biceps externally, and the sartorius, gracilis and semitendinosus internally. Over the popliteal space it consists of strong transverse fibres, which bind together the muscles of the outer and inner sides, and it is perforated at the lower part of the space by the external saphenous vein ; lower down it becomes much thinner over the gastrocnemius muscle. From the deep surface of the fascia intermuscular septa are sent inwards, and give origin to the adjacent muscles : on the outer side two of these pass inwards to be attached to the anterior and external borders of the fibula, and thus separate the peroneal muscles from those of the front and back of the leg respectively ; and in front there is one septum, confined to the upper third of the leg, between the tibialis anticus and extensor longus digitorum muscles.

Beneath the gastrocnemius and soleus muscles on the back of the leg, a deep

layer of fascia is stretched from side to side, binding down the deeper muscles to the tibia and fibula. Where it is covered by the soleus and gastrocnemius, this fascia is weak, but it becomes stronger as it escapes from under cover of those muscles and approaches the malleoli.

Below the ankle the deep fascia of the leg becomes continuous with that of the foot. In front and on the sides of that joint, it is strengthened by broad bands of fibres, which are called annular ligaments, and serve to confine the tendons in their positions.

The **anterior annular ligament** includes two structures, one placed at the lower part of the leg, the other opposite the bend of the ankle. The *upper band*, of considerable breadth, stretches transversely from the anterior border of the fibula to the corresponding part of the tibia, and binds down the vertical portion of the extensor tendons as they descend to the foot: the tendon of the tibialis anticus alone has a synovial sheath under this part of the ligament. The *lower band* presents superficially the appearance of the letter  $\sphericalangle$  placed thus upon its side, being single in its outer half, and divided into two branches internally. The outer portion springs from the hollow of the os calcis, between the outer end of the interosseous astragalocalcaneal ligament and the posterior articular surface for the astragalus, and forms a strong loop (the *fundiform ligament* of Retzius) which completely surrounds the peroneus tertius and extensor longus digitorum muscles. From the extremity of the loop some of the fibres are continued into the two branches, which are, however, less regular in their arrangement: the strongest and most constant band passes to the internal malleolus, crossing over the extensor hallucis, and on the deep surface of the tibialis anticus tendon, only a few fibres passing superficially to the latter; while the lower band, after crossing both those tendons is inserted on the inner side of the foot into the fascia of the sole. The tendons are surrounded by three synovial sheaths under this part of the ligament: one is common to the peroneus tertius and extensor longus digitorum; the second invests the extensor proprius hallucis; and the third, on the tibialis anticus, is continuous with that under the upper band of the ligament. There is also in many cases a bursa between the fundiform ligament and the outer side of the neck of the astragalus.

The **internal annular ligament** crosses the space between the inner ankle and the heel, through which the tendons of the flexor muscles run. Its upper border, continuous with the fascia of the leg (more especially the intermuscular layer), is very imperfectly defined; and its lower border, giving origin to many fibres of the abductor hallucis, is but little more distinct. Its anterior extremity is attached to the inner malleolus, and its posterior to the inner side of the calcaneum; but between these two points it arches over several osseous grooves so as to form canals for the passage of tendons. The first canal (next to the malleolus) contains the tendon of the tibialis posticus, and the second that of the flexor longus digitorum, each being provided with a synovial lining. Then follows a wider space for the passage of the posterior tibial vessels and nerve. Lastly a fourth canal upon the astragalus, lined like the first two by a synovial bursa, transmits the tendon of the flexor longus hallucis.

The **external annular ligament** extends from the point of the outer malleolus to the outer side of the calcaneum, and keeps in place the tendons of the long and short peroneal muscles. The tendons are close together, and are surrounded by one synovial sac.

Subcutaneous bursæ are sometimes developed over the malleoli, especially the external, rarely over the lower end of the tendo Achillis.<sup>1</sup>

**MUSCLES.**—The muscles of this part are divided naturally into three groups, which occupy respectively the front, the outer side, and the back of the leg.

<sup>1</sup> Synnestvedt, "Beskrivelse af de paa Over- og Underextremiteterne forekommende Bursæ mucosæ." Christiania, 1869.

## ANTERIOR REGION.

Between the tibia and fibula, and on the front of the leg, are placed four muscles—the tibialis anticus, extensor proprius hallucis, extensor longus digitorum, and peroneus tertius.

The **tibialis anticus** arises from the lower part of the external tuberosity of the tibia, and from the upper half of the outer surface of that bone, from the adjoining portion of the interosseous membrane, from the strong fascia of the leg, and from the intermuscular septum between it and the extensor longus digitorum. The tendon glides in a synovial sheath beneath the anterior annular ligament, and is inserted into an oval mark on the inner and lower part of the internal cuneiform and into the contiguous extremity of the first metatarsal bone, dividing slightly into two slips as it descends.

**Relations.**—This muscle lies immediately under the aponeurosis of the leg. It rests upon the tibia and the interosseous membrane. Its outer surface is in contact with the extensor longus digitorum, the extensor proprius hallucis, and the anterior tibial vessels and nerve. Its tendon passes over the lower end of the tibia, the ankle-joint, and the inner surface of the tarsus. A small bursa is frequently placed under it close to its insertion.

**Varieties.**—In a few cases a deep portion of this muscle has been found inserted into the astragalus. The tendon has also been seen sending a slip to the head of the first metatarsal bone or the base of the first phalanx of the great toe. The *tibio-fascialis anticus* is a small muscle arising from the lower part of the tibia, and inserted into the annular ligament and deep fascia. It may also exist as a tendinous slip from the tibialis anticus.

The **extensor longus s. proprius hallucis** muscle (ext. prop. pollicis pedis), placed between the tibialis anticus and the extensor longus digitorum, arises from the middle two-fourths of the narrow anterior surface of the fibula, and from the contiguous portion of the interosseous membrane. Its tendon passes through a distinct compartment in the lower portion of the annular ligament and along the dorsum of the foot, to be inserted into the base of the terminal phalanx of the great toe. An expansion given off from the tendon on each side spreads over the metatarso-phalangeal articulation; and in a majority of cases there is a distinct slip from the inner edge of the tendon inserted into the base of the first phalanx.

**Relations.**—This muscle is partly concealed by those between which it is placed. It lies external to the anterior tibial artery at its origin, but crosses in front of that vessel in the lower third of the leg, and is internal to it on the foot.

**Varieties.**—The extensor proprius hallucis is occasionally united at its origin with the extensor longus digitorum. A partial insertion into the second toe has been observed in a negress (Chudzinski, Rev. d'Anthrop., 1882, 620).

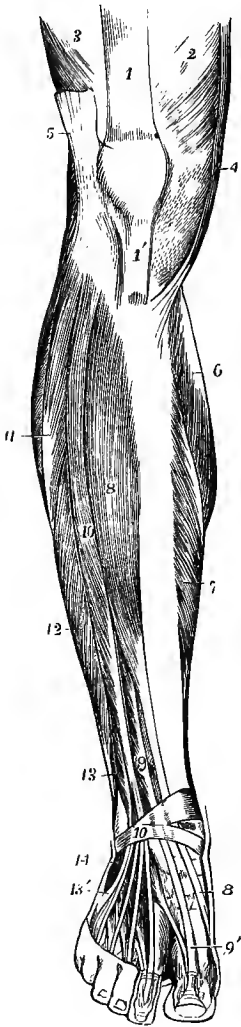
The *extensor ossis metatarsi hallucis* is a small muscle, sometimes found as a slip from the extensor proprius, or from the tibialis anticus, or from the extensor longus digitorum; or it may be a distinct muscle arising close to the extensor proprius, and traversing the same compartment of the annular ligament with that muscle.

The *extensor longus primi internodii hallucis* is rare as a separate muscle, but is commonly represented by the offshoot from the tendon of the extensor proprius hallucis, occasionally by a slip from the tibialis anticus, or by a fibrous band springing from the annular ligament and fascia.

The **extensor longus digitorum pedis** arises from the external tuberosity of the tibia, from the head and the anterior surface of the fibula for about two-thirds of its length in front of the extensor hallucis, and from a small part of the interosseous membrane at its upper part; also from the aponeurotic septa intervening between it and the muscles on each side, and from the fascia of the leg. The tendon begins on the anterior border of the muscle and becomes divided below into four slips, which descend through the lower part of the annular ligament, in the same sheath as the peroneus tertius, and on the dorsum of the foot pass respectively to the four outer toes.

The three inner tendons are each joined at the outer side, on the first phalanx, by a tendon from the extensor brevis digitorum. All the four tendons are continued into expansions, which are joined on the first phalanx by tendinous processes from the lumbricales and interosseous muscles; they divide into three parts, their middle fibres being inserted into the second phalanx, while their lateral parts unite together and

Fig. 255.—MUSCLES OF THE LEG AND FOOT FROM BEFORE.  
(Allen Thomson.)  $\frac{1}{2}$



1, tendon of rectus femoris; 1', infrapatellar tendon; 2, vastus internus; 3, vastus externus; 4, sartorius; 5, ilio-tibial band of fascia lata; 6, inner head of gastrocnemius; 7, inner part of soleus; 8, tibialis anticus; 8', its tendon near its insertion; 9, extensor proprius hallucis; 9', its tendon; 10, extensor longus digitorum; 10', lower band of the anterior annular ligament; 11, peroneus longus; 12, peroneus brevis; 13, peroneus tertius; 13', its tendon at its insertion; 14, origin of extensor brevis digitorum, the first head of which is seen passing to the great toe near the line from 9'.

are inserted on the third, in a manner exactly similar to the arrangement of the extensor tendons of the fingers (p. 231).

**Relations.**—It is in contact internally with the tibialis anticus and extensor proprius hallucis, and externally with the peronei muscles. It rests upon the external tuberosity of the tibia, the anterior surface of the fibula, the lower end of the tibia, the front of the ankle-joint, and the extensor brevis digitorum. The anterior tibial nerve passes obliquely inwards beneath its upper part.

**Varieties.**—This muscle varies considerably in the mode of origin and the arrangement of its various tendons. The tendons to the second and fifth toes may be found doubled, or extra slips are given off from one or more tendons to their corresponding metatarsal bones, or to the short extensor, or to one of the interosseous muscles. A slip to the great toe from the innermost tendon has also been met with.

The **peroneus tertius** muscle arises below the extensor longus digitorum, from the lower third or more of the anterior surface of the fibula, from the lower part of the interosseous membrane, and from the intermuscular septum which separates it on the outer side from the peroneus brevis. Its tendon is inserted into the upper surface of the base of the fifth metatarsal bone.

**Relations.**—It is placed to the outer side of the long extensor of the toes, with which it is united at its origin, and it passes through the same compartment of the annular ligament with that muscle.

**Varieties.**—The peroneus tertius is sometimes as large as the extensor longus digitorum; it frequently terminates partly or wholly on the fourth metatarsal bone; and it is sometimes wanting. A slip to join the extensor tendon of the little toe is seldom present (1.3 per cent., Gruber). The peroneus tertius is a muscle peculiar to man.

**Nerves.**—All the muscles of the front of the leg are supplied by the anterior tibial nerve.

#### EXTERNAL REGION.

The **peroneus longus** muscle arises by a few fibres from the outer tuberosity of the tibia, from the head and upper two-thirds of the external surface of the

fibula, from the fascia of the leg, and from the intermuscular septum on each side. The muscular fibres end in the lower half of the leg on a tendon which passes downwards with that of the peroneus brevis in the hollow behind the external malleolus; it next inclines forwards on the outer side of the os calcis, and then winds round the outer end of the tuberosity of the cuboid to enter the groove on the lower surface of that bone; finally, crossing the sole obliquely inwards and forwards, it is inserted into an impression on the outer side of the tuberosity of the first metatarsal bone, and slightly into the adjoining part of the internal cuneiform bone: an offset is frequently sent from it to the base of the second metatarsal bone.

**Relations.**—At its origin the peroneus longus lies between the extensor longus digitorum in front and the soleus and flexor longus hallucis behind; in the lower part of the leg it lies behind the peroneus brevis. Its attachment to the bone is interrupted for about an inch below the head of the fibula, where the external popliteal nerve passes beneath it. Behind the external malleolus the tendons of both peronei are contained in the same sheath under the annular ligament, but on the outer side of the os calcis each tendon has its own sheath, the two being separated by a fibrous septum and by the peroneal spine of the calcaneum when that process exists. A single synovial sac invests both tendons and sends two processes downwards into the special sheaths. In the sole of the foot the tendon of the peroneus longus lies in a canal formed by the cuboid bone and the long plantar ligament, and is surrounded by a second synovial membrane. A sesamoid fibro-cartilage, or sometimes a bone, is found in that part of the tendon which plays over the tuberosity of the cuboid.

The **peroneus brevis** arises from the lower two-thirds of the external surface of the fibula, extending upwards in front of the peroneus longus, and from the intermuscular septum on each side. Its tendon passes down behind the external malleolus, and then inclines forwards to be inserted into the tuberosity at the base of the fifth metatarsal bone, sending in a majority of cases a small slip to join the extensor tendon of the little toe, or to the fore part of the metatarsal bone.

**Relations.**—In front it is in contact with the extensor longus digitorum and the peroneus tertius, and behind with the peroneus longus and flexor longus hallucis. The common synovial membrane surrounds the tendon under the annular ligament, and sends a prolongation into its special sheath, above that for the peroneus longus.

**Varieties.**—Fusion of the two peronei is rare. A slip from the peroneus longus to the base of the third, fourth or fifth metatarsal bone, or to the adductor obliquus hallucis is occasionally seen.

The *peroneus accessorius* arises from the fibula between the peroneus longus and brevis, and joins the tendon of the former in the sole of the foot.

The *peroneus quinti digiti* arises from the lower fourth of the fibula under the peroneus brevis, and is inserted into the extensor aponeurosis of the little toe; this is rarely present as a distinct muscle, but it is commonly (58 per cent.<sup>1</sup>) represented by the above-mentioned slip of the tendon of the peroneus brevis. It occurs normally in many animals, either as a separate muscle, or united to a greater or less degree with the peroneus brevis.

The *peroneus quartus* arises from the back of the fibula, between the peroneus brevis and the flexor hallucis, and is inserted into the peroneal spine of the os calcis (*peroneo-calcaneus externus*) or less frequently into the tuberosity of the cuboid (*peroneo-cuboides*). It was found by Gruber in about 13 per cent.

**Nerves.**—The peroneus longus and brevis are supplied by the musculo-cutaneous branch of the external popliteal nerve.

#### POSTERIOR REGION.

The muscles at the back of the leg consist of a superficial group inserted into the extremity of the calcaneum, and a deeper group covered in by a deep fascia and for the most part descending to the sole.

The **SUPERFICIAL GROUP** consists of three muscles; two of them, the gastrocnemius and solens, are of large size, form the bulk of the calf of the leg, and

<sup>1</sup> Gruber, "Beobachtungen," Heft vii, 1886; Cunningham and Brooks, Proc. Roy. Irish Acad., 1887.

descend, the one lying on the surface of the other, to be inserted by a common tendon—the tendo Achillis; the third, a small muscle, the plantaris, passes downwards between the other two.

The **gastrocnemius** muscle consists of two large heads which spring from the lower end of the femur, and terminate about the middle of the leg in a common

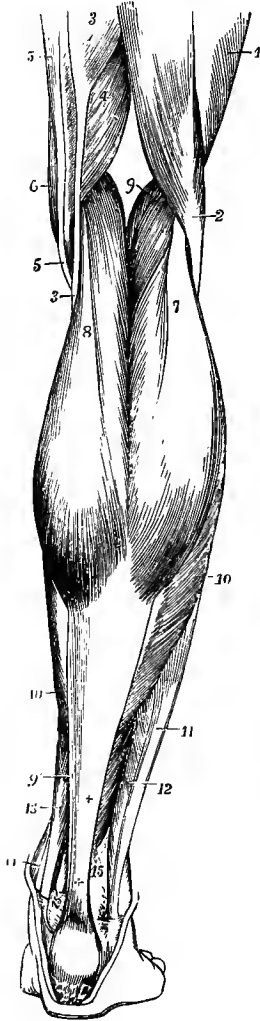


Fig. 256.—SUPERFICIAL MUSCLES OF THE LEG, SEEN FROM BEHIND. (After Bourguery.)  $\frac{1}{2}$

1, vastus externus; 2, biceps flexor cruris; 3, semitendinosus; 4, semimembranosus; 5, gracilis; 6, sartorius; 7, outer, and 8, inner head of the gastrocnemius; 9, placed in the popliteal space, points to the plantaris; 9', its thin tendon on the inner side of the tendo Achillis; 10, 10, fibres of the soleus descending to the flat tendon which, joining with that of the gastrocnemius, forms, + +, the tendo Achillis; 11, peroneus longus; 12, peroneus brevis; 13, flexor longus digitorum; 14, tibialis posticus; 15, points to the lower fibres of the flexor longus hallucis, the tendon of which is seen descending over the tibia at 15'.

tendon. The outer head arises from a depression on the outer side of the external condyle above the tuberosity, and from the hinder surface of the femur immediately above the condyle. The inner head arises from an impression on the upper part of the internal condyle, close behind the adductor tubercle, from the lower end of the internal supracondylar ridge, and from an adjoining roughened part of the popliteal surface of the femur. The lateral part of each origin takes place by means of a strong tendon which is attached to the impression on the condyle, and spreads out as it descends on the surface of the head; while the central part arises by short tendinous fibres, which are succeeded by a prominent fleshy mass extending along the part of the head next to the middle line of the limb. The two heads enlarge downwards as fresh fibres are added from the superficial tendons, and their adjacent borders converge and soon meet, but do not join, being separated superficially by a longitudinal groove, and deeply by a thin tendinous band which is seen when the fleshy fibres are drawn aside. The short muscular bundles incline forwards, and end obliquely on the posterior surface of the inferior tendon, which is broad and aponeurotic as it occupies the deep surface of the muscle, but becomes narrower and thicker as it proceeds downwards to be united

with the subjacent tendon of the soleus in the tendo Achillis.

The lower edge of each muscular part presents a convexity downwards; and the inner head, besides being broader and thicker, also descends lower than the outer. A synovial bursa, frequently communicating with the knee-joint, lies beneath the inner head of origin, and separates it from the tendon of the semimembranosus muscle; and above this, between the tendon and the femur, there is usually a second smaller sac, which may also open into the joint.<sup>1</sup> In the outer head a sesamoid fibro-cartilage or bone is sometimes met with over the condyle of the femur.

<sup>1</sup> Gruher, "Die Knieschleimbeutel," Prag, 1857.



**Relations.**—The heads of the gastrocnemius muscle form the inferior boundaries of the popliteal space, and are placed between the hamstring muscles: the peroneal nerve is lodged between the external head and the biceps. The gastrocnemius lies over the popliteus, plantaris and soleus muscles, with the popliteal vessels and internal popliteal nerve. The short saphenous vein is placed over, and the tibial communicating nerve descends in, the interval between its two heads.

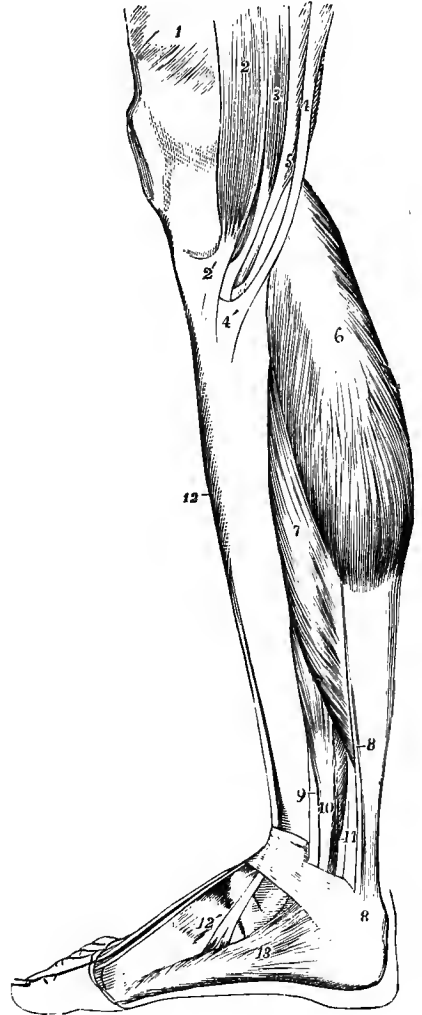
**Varieties.**—The gastrocnemius is not unfrequently joined by a bundle of muscular fibres

Fig. 257.—SUPERFICIAL MUSCLES OF THE LEG, SEEN FROM THE INNER SIDE. (After Bourguery.)  $\frac{1}{2}$

1, vastus internus; 2, sartorius; 2', its tendon, spreading on the inner upper part of the tibia; 3, gracilis; 4, semitendinosus; 4', its insertion; and between 2' and 4', that of the gracilis; 5, semi-membranosus; 6, inner head of the gastrocnemius; 7, soleus; 8, 8', placed upon the tendo Achillis, point to the tendon of the plantaris descending on the inner side; 9, small part of the tendon of the tibialis posticus; 10, flexor longus digitorum; 11, flexor longus hallucis; 12, tibialis anticus; 12', its tendon of insertion; 13, abductor hallucis.

which arises separately from some part of the popliteal surface of the femur. This bundle has been seen passing between the popliteal artery and vein. Absence of the outer head, or even of the whole muscle, has also been observed.

The **soleus** muscle arises externally from the posterior surface of the head and upper third of the shaft of the fibula; internally from the oblique line and the internal border of the tibia, as far down as the middle of the bone; and between the tibia and fibula, from a tendinous band which arches over the popliteal vessels and nerve. The muscular fibres spring in part from the bones, but to a much greater extent from two tendinous laminae which descend, the outer from the fibula, and the inner from the arch over the vessels and the oblique line of the tibia, in the substance of the muscle, on the front surface of which each appears by one edge, the opposite edge being directed obliquely towards the middle line of the leg. The fibres from the anterior surfaces of these laminae converge to a median tendinous septum which also appears on the front of the muscle by one border, while those arising from their posterior surfaces are directed downwards and backwards, and end in an aponeurosis which covers the greater part of the posterior surface of the mass, and over which the tendinous surface of the gastrocnemius glides. The tendon of insertion is prolonged downwards from this aponeurosis, being joined anteriorly by the median septum, and forms the deeper and larger part of the tendo Achillis. The fasciculi of the muscle are numerous and short, having a length of at most from two to three inches, and they are continued downwards on the deep surface of the tendo Achillis to within a short distance of the heel.



**Relations.**—The soleus rests upon the flexor longus hallucis, flexor longus digitorum, and tibialis posticus muscles, together with the posterior tibial vessels and nerve, from which, however, it is separated by the deep aponeurosis.

**Varieties.**—To the soleus an accessory portion is occasionally added at its lower and inner part; this usually ends on the inner side of the tendo Achillis, but it is sometimes attached separately to the os calcis, or to the internal annular ligament.

The tibial head of the soleus is almost peculiar to man; among the lower animals it occurs, of small size, only in the gorilla and sometimes in the chimpanzee.

The **tendo Achillis**, the thickest and strongest tendon in the body, is formed by the union of the flat tendons of the gastrocnemius and soleus. Broad at its commencement near the middle of the leg, it contracts as it proceeds downwards and becomes thicker to within about an inch and a half of the heel; it then expands slightly to be inserted into the middle part of the posterior surface of the tuberosity of the os calcis. A synovial bursa is interposed between the upper part of the tuberosity and the tendon.

The two heads of the gastrocnemius and the soleus, with their common tendon of insertion, constitute the *triceps extensor suræ*.

The **plantaris** muscle arises from the femur immediately above the external condyle, and from the posterior ligament of the knee-joint; its muscular part is from three to four inches in length, and terminates in a long slender tendon, which inclines inwards between the gastrocnemius and soleus, and, running along the inner border of the tendo Achillis, is inserted by the side of that into the posterior part of the calcaneum.

**Varieties.**—The plantaris varies in its mode of termination; it frequently joins the tendo Achillis, or ends in the deep fascia of the leg, or in the internal annular ligament. Its tendon is sometimes enclosed in the lower part of the tendo Achillis. It is often absent (7·5 per cent., Gruber).

Like the palmaris longus, this muscle, which is little developed in man, is the remains of a superficial flexor of the digits. In many animals it is of large size, and is continued over the calcaneum into the plantar fascia. It is, however, generally wanting in the anthropoids.

The **DEEP GROUP** of posterior muscles of the leg is in close contact with the bones; it consists of the popliteus, flexor longus digitorum, flexor longus hallucis, and tibialis posticus.

The **popliteus**, a short muscle placed below the knee, arises by a rounded tendon, about an inch in length, from the lower part of the groove on the outer surface of the external condyle of the femur, within the external lateral ligament and capsule of the knee-joint: it is in contact with the external semilunar fibro-cartilage, and receives additional fibres from the posterior ligament of the joint. The muscular fibres diverge as they pass downwards and inwards, and are inserted into the triangular surface of the tibia above the oblique line, and into the aponeurosis covering the muscle. Its tendon occupies the groove on the femur only when the knee-joint is fully flexed.

**Relations.**—The popliteus is bound down by an aponeurosis, principally derived from the tendon of the semimembranosus muscle. The plantaris and gastrocnemius muscles, the popliteal vessels and internal popliteal nerve lie upon its posterior surface. The synovial membrane of the knee-joint sends a prolongation downwards between its tendon and the back of the outer tuberosity of the tibia.

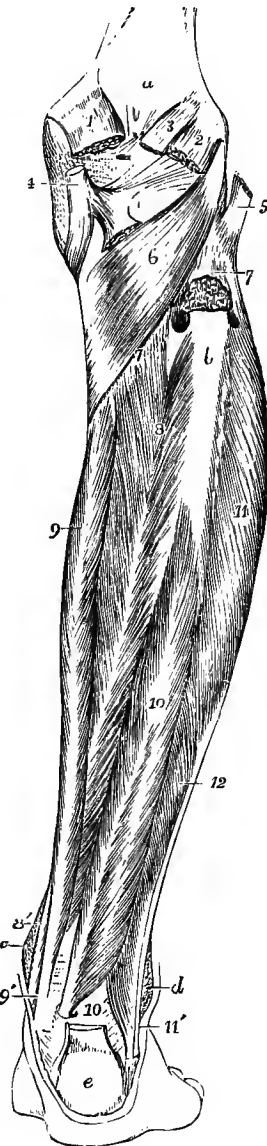
**Varieties.**—This muscle has been seen with an additional head of origin from the sesamoid bone in the outer head of the gastrocnemius. The *popliteus minor* is a muscular slip of rare occurrence, arising from the femur on the inner side of the plantaris, and inserted into the posterior ligament of the knee-joint. The *peroneo-tibialis* is a small muscle found by W. Gruber in the proportion of 1 in 7 in a large number of subjects. It arises from the inner side of the head of the fibula, and is inserted into the upper end of the oblique line of the tibia, being situated beneath the popliteus. It is constant in apes. (*Arch. f. Anat.*, 1877, p. 401, and 1878, p. 484.)

The three remaining muscles of this group are bound down together by a deep fascia, which extends between the tibia and fibula, and separates them from the soleus.

The **flexor longus digitorum pedis** muscle, or **flexor perforans**, arises from the inner portion of the posterior surface of the tibia (see p. 126), its attachment

Fig. 258.—DEEP POSTERIOR MUSCLES OF THE LEG. (Allen Thomson.)  $\frac{1}{2}$

*a*, popliteal surface of the femur; *b*, surface of the upper third of the fibula, from which the soleus muscle has been removed; *c*, internal malleolus; *d*, external malleolus; *e*, tuberosity of the os calcis, with a part of the tendo Achillis inserted into it, and the plantaris on its inner side; 1, inner head of the gastrocnemius, cut short; 2, outer head; 3, plantaris; 4, tendon of the semi-membranosus muscle near its insertion, seen spreading in three portions, viz., to the tibia, to the popliteal fascia, and to the posterior ligament; 5, tendon of the biceps inserted into the head of the fibula; 6, popliteus muscle; 7, upper part of the origin of the soleus from the fibula, cut short; 7', line of its tibial origin; between these figures is seen the perforation in the upper part of the interosseous membrane; 8, tibialis posticus; 8', its tendon, passing between the flexor longus digitorum and the tibia; 9, flexor longus digitorum; 9' its tendon, with that of the tibialis posticus, passing behind the internal malleolus; 10, flexor longus hallucis; 10', placed beside its tendon, where it passes over the tibia and astragalus; 11, peroneus longus; 11', its tendon behind that of the peroneus brevis, passing down behind the external malleolus; 12, peroneus brevis.



extending over the middle two-fourths of the length of the bone; it likewise receives fibres from a thin aponeurosis which covers the tibialis posticus, and is attached to the inner border of the fibula, and from which the flexor longus hallucis also takes origin. Its tendon descends behind the internal malleolus, lying outside that of the tibialis posticus, and invested by a distinct fibrous and synovial sheath; it is then directed obliquely forwards and outwards into the sole of the foot, crossing superficially the tendon of the flexor longus hallucis, to which it is connected by a tendinous slip; it there divides into four parts, which pass forwards to be inserted into the terminal phalanges of the four smaller toes. Each digital tendon enters a fibrous sheath on the toe to which it belongs, perforates the corresponding tendon of the flexor brevis digitorum, and is invested with synovial membrane and connected by vincula accessoria to the phalanges; the whole arrangement being essentially the same as that which has been already described in the fingers (see p. 228).

**Relations.**—The belly of the muscle rests upon the tibia and upon the tibialis posticus, crossing the latter obliquely in the lower third of the leg. It is covered at the upper part by the soleus and inferiorly by the aponeurosis of the leg. Upon it also lie the posterior tibial vessels and nerve.

**Varieties.**—A supplementary head, *flexor accessorius longus digitorum*, is not unfrequently found arising from the fibula, or the tibia, or the deep fascia, and ending in a tendon which, after passing beneath the internal annular ligament, joins the tendon of the long flexor, or

the *accessorius*. It has also been seen replacing the latter muscle. It rarely sends a slip to the flexor hallucis tendon. Gies describes an accessory slip from the tibialis anticus, which joined the flexor digitorum at the ankle.

Intimately connected with the tendon of the flexor longus digitorum are the flexor accessorius and the lumbricales muscles, which, although they are situated in the foot, may be most conveniently described in this place.

The **flexor accessorius** arises by two heads, the internal and larger of which is fleshy, and is attached to the inner surface of the calcaneum, while the external, flat, narrow, and tendinous, is attached to the outer surface of the calcaneum a little in

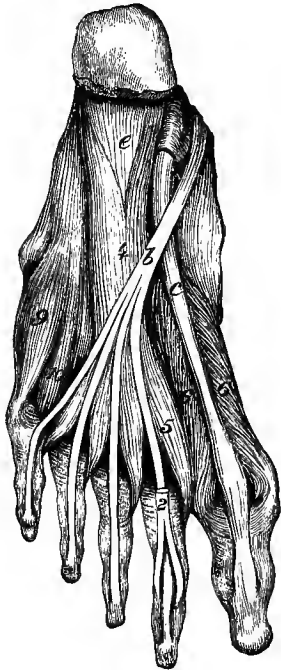


Fig. 259.—SECOND LAYER OF MUSCLES OF THE SOLE.  $\frac{1}{3}$

*b*, tendon of flexor longus digitorum ; *c*, tendon of flexor longus hallucis ; *e*, long plantar ligament ; 2, tendon of flexor brevis digitorum to second toe, cut short ; 4, flexor accessorius ; 5, first lumbricalis ; 6, 6, flexor brevis hallucis ; 9, flexor brevis minimi digiti ; 10, third plantar interosseous muscle.

front of the external tubercle, and to the long plantar ligament. These origins united form a muscular mass which is inserted into the external border and upper surface of the tendon of the flexor longus digitorum.

**Varieties.**—The outer head of the muscle is often wanting : absence of the whole muscle is recorded. The number of digital tendons to which the fibres of the accessorius can be followed is subject to considerable variation. Most frequently offsets are sent to the second, third and fourth toes ; in many cases however to the fifth as well ; occasionally to two toes only. More rarely a slip joins the tendon of the flexor hallucis, and the muscle has been seen to end entirely on that tendon.

The **lumbricales** muscles, four in number, arise from the tendons of the flexor longus digitorum at their point of division, each being, with the exception of the most internal, attached to two tendons. They pass forwards to the inner sides of the four outer toes, each muscle ending in a tendon, which is inserted

into the expansion of the extensor tendon on the dorsum of the first phalanx of the toe.

**Varieties.**—Absence of one or more of the lumbricales has been observed ; also doubling of the third and fourth. The insertion of these muscles frequently takes place, partly or wholly, into the first phalanges. There are sometimes small bursæ between the tendons and the bases of the first phalanges.

**Relations.**—In the sole of the foot the tendons of the flexor longus digitorum, together with the flexor accessorius and the lumbricales, are covered by the abductor hallucis and flexor brevis digitorum, the hinder part of the external plantar vessels and nerve being placed between. They lie over the tendon of the flexor longus hallucis, the adductor obliquus and adductor transversus hallucis, the interosseous muscles, and the plantar arterial arch.

The **flexor longus hallucis** muscle (*fl. long. pollicis pedis*) arises from the lower two-thirds of the posterior surface of the fibula, from the intermuscular septum between it and the peronei, and from the aponeurosis common to it and the flexor longus digitorum, which covers the tibialis posticus. The muscular fibres, passing obliquely backwards and downwards, end in a tendon on the posterior surface of the muscle. This tendon traverses a groove on the lower end of the tibia, on the back

of the astragalus and the under surface of the sustentaculum tali, being bound down to those bones by a fibrous sheath lined by synovial membrane. Thence passing forwards and inwards in the sole of the foot, it gives off a slip to the tendon of the flexor longus digitorum, by which it is crossed, and proceeds in a fibrous sheath over the first phalanx of the great toe to be inserted into the base of the terminal phalanx.

**Relations.**—This muscle is concealed for the most part by the soleus, a small part only on the outer side of the tendo Achillis being covered by the fascia of the leg. Externally it is in contact with the peronei, and internally with the posterior tibial vessels and nerve. It rests upon the fibula and tibialis posticus, and conceals the peroneal vessels. Behind the ankle the tendon of this muscle is separated from that of the flexor longus digitorum by an interval of more than half an inch, in which are placed the posterior tibial vessels and nerve. In the sole it is covered by the abductor hallucis and the plantar fascia; it is also crossed by the plantar vessels and nerves as well as by the tendon of the long flexor of the toes. It rests upon the flexor brevis hallucis.

**Varieties.**—This muscle is liable to very few variations, except in the mode of union of its tendon with that of the flexor longus digitorum which is exceedingly variable. In almost every case a slip is given from the flexor hallucis to the flexor digitorum; and frequently (1 in 5) an additional slip proceeds from the flexor digitorum to the flexor hallucis. Complete separation of the tendons is very rare. This slip from the flexor hallucis most frequently passes to the second and third toes (52 per cent.), but it may pass to the second only (28 per cent.), or to the second, third and fourth (19 per cent.), or rarely to all the four outer toes.

The *peroneo-calcaneus internus* is a rare muscle, which arises below or outside the flexor longus hallucis from the back of the fibula, and passes over the sustentaculum tali in the groove with the flexor hallucis to be inserted into the os calcis.

The **tibialis posticus** muscle, placed beneath the two long flexor muscles, arises from the posterior surface of the interosseous membrane, from the outer portion of the posterior surface of the tibia, extending from the superior tibio-fibular articulation to the middle of the bone, from the whole inner surface of the fibula, and slightly from the aponeurosis covering it. The fleshy fibres pass to a tendon which, commencing above in the centre of the muscle, descends along its inner border, becomes free at the level of the lower tibio-fibular articulation, and gains the groove at the back of the internal malleolus, where it is contained in a fibrous sheath and surrounded by synovial membrane. It then inclines forwards and ends by being inserted into the tuberosity of the navicular bone, sending offsets forwards to the three cuneiform bones, to the cuboid, and to the bases of the second, third and fourth metatarsal bones, as well as a thin process backwards to the sustentaculum tali. Near its insertion the tendon contains a sesamoid fibro-cartilage, occasionally a bone, as it lies over the head of the astragalus.

**Relations.**—The posterior surface of the tibialis posticus is in contact with the long flexors of the toes and the posterior tibial and peroneal vessels, while at the upper end the anterior tibial vessels are directed forwards between its attachments to the two bones. In the lower part of the leg the muscle crosses obliquely inwards beneath the flexor longus digitorum, and its tendon becomes superficial for a short distance, lying close to the hinder border of the internal malleolus. In the foot it is covered by the abductor hallucis, and it rests against the internal calcaneo-navicular ligament which separates it from the head of the astragalus.

**Varieties.**—These are rare. An additional muscle has been seen occasionally arising from the back of the tibia below the flexor digitorum, and inserted into the capsule of the ankle-joint or into the annular ligament. This is the *tensor of the capsule of the ankle-joint* of Henle and Linhart, or the *tibialis secundus* of Bahnsen.

**Nerves.**—The gastrocnemius, plantaris and popliteus are supplied by the internal popliteal nerve. The soleus receives one branch from the internal popliteal nerve and another from the posterior tibial. The flexor longus digitorum, flexor longus hallucis and tibialis posticus derive their nerves from the posterior tibial.

## THE MUSCLES AND FASCIÆ OF THE FOOT.

**FASCIÆ.**—The **fascia of the dorsum of the foot** is reduced to a thin membrane prolonged from the anterior annular ligament over the extensor tendons. Beneath it, deeper layers of fascia are placed over the short extensor of the toes and the interosseous muscles.

The **superficial fascia of the sole** resembles that of the palm of the hand. It forms a thick cushion, especially over the bony prominences, and consists mainly of small lobules of fatty tissue bound down by numerous fibrous bands which pass vertically from the skin to the deep fascia. Small bursæ are often formed over the heel and the heads of the first and fifth metatarsal bones.

The **deep fascia of the sole**, or **plantar fascia**, consists of a central and two lateral portions, which are marked off from each other by superficial grooves,

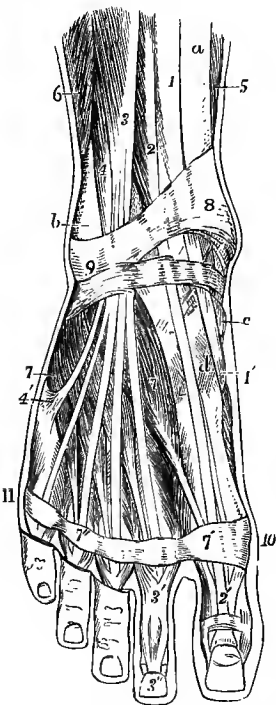


Fig. 260.—SUPERFICIAL MUSCLES AND TENDONS ON THE DORSUM OF THE FOOT AND LOWER PART OF THE FRONT OF THE LEG. (After Bourguery.)  $\frac{1}{3}$

*a*, tibia; *b*, fibula; *c*, navicular bone; *d*, internal cuneiform bone; 1, 1', tibialis anticus; 2, extensor proprius hallucis; 2', its expansion on the dorsum of the great toe; 3, extensor communis digitorum dividing into its four tendons for the toes; 3', its expansion, and 3'', final insertion (upon the second toe); 4, peroneus tertius; 4', its insertion on the base of the fifth metatarsal bone; 5, soleus; 6, peroneus brevis; 7, extensor brevis digitorum; 7', 7'', placed on the transverse band of aponeurosis, marks the first and fourth tendons of the extensor brevis muscle; 8, 9, part of the anterior annular ligament; 10, 11, a transverse band of the dorsal fascia of the foot.

indicating the position of intermuscular septa. The *inner* portion, thinner and looser than the others, invests the abductor hallucis, and is continuous round the inner border of the foot with the dorsal fascia and with the lower fibres of the internal annular ligament. The *outer* part covers the abductor minimi digiti, is much stronger, and forms a particularly thick band between the outer tubercle of the os calcis and the tuberosity of the fifth metatarsal bone. It is continuous round the outer border of the foot with the dorsal fascia, and sends a thin prolongation forwards over the insertion of the abductor and the short flexor muscles of the little toe. The *central* portion is exceedingly strong, and is composed of dense white glistening fibres, the greater number of which run longitudinally from the os calcis to the roots of the toes. It is narrow and thick behind, where it is attached to the inner tubercle of the os calcis, immediately below the origin of the flexor brevis digitorum, with which muscle it is closely connected. It becomes broader and thinner as it extends forwards, and near the heads of the metatarsal bones it divides into five processes, one passing to each of the toes. In the intervals between the processes a thin membrane composed of transverse fibres covers the lumbricales muscles and the digital nerves. The arrangement of the processes is identical with that of the corresponding part of the palmar fascia, fibres being sent to the digital sheaths, superficial transverse ligament and skin, as well as deep processes on each side of the flexor tendons to the transverse metatarsal ligament.

The two *intermuscular septa* which are given off between the middle and lateral

portions of the plantar fascia pass deeply into the sole of the foot ; they separate the flexor brevis digitorum from the abductor hallucis on the inner side, and from the abductor minimi digiti on the outer side, and give partial origin to each of these muscles.

The *superficial transverse ligament of the toes* is a thin band of fibres contained in the folds of skin limiting the interdigital clefts, and connected to the subjacent sheaths of the tendons. Like the transverse metatarsal ligament, it differs from the corresponding structure in the hand in being attached to all five digits.

**MUSCLES.**—On the dorsum of the foot, besides the tendons continued from the muscles of the front of the leg, one short muscle is present, viz., the extensor brevis digitorum. In the sole the muscles are more numerous, and are described in four layers as they are met with in the course of a dissection.

The **extensor brevis digitorum pedis** arises from the fore part of the upper and outer surfaces of the os calcis, in front of the groove for the peroneus brevis muscle, and from the lower band of the anterior annular ligament. It divides into four tapering slips, each of which terminates in a tendon ; the first or most internal of these is inserted separately into the dorsal surface of the first phalanx of the great toe at its tarsal extremity ; and the other three become severally united to the outer borders of the tendons of the long extensor proceeding to the three next toes.

The innermost portion of the muscle is commonly separate much farther back than the other slips, and is described by many anatomists as a distinct muscle under the name of *extensor brevis hallucis*.

**Relations.**—It crosses the dorsum of the foot somewhat obliquely, resting on the tarsus and metatarsus, and lying beneath the tendons of the peroneus tertius and long extensor of the toes. Its inner slip also crosses the dorsal artery of the foot and the anterior tibial nerve.

**Varieties.**—An accessory fasciculus of origin from the astragalus and navicular bone, or from the external cuneiform and third metatarsal bones, has been observed passing to the second slip of the muscle, and one from the cuboid to the third slip. The tendons vary considerably both as to number and position ; they may be reduced to two, or one of them may be doubled, or an additional slip may pass to the little toe. A supernumerary slip ending on one of the metatarso-phalangeal articulations, or joining a dorsal interosseous muscle, is not unfrequent, especially in the interval between the great and second toe bellies. Deep slips forming a transition between this muscle and the dorsal interossei also occur.<sup>1</sup> There is occasionally a single or double bursa between the short extensor muscle and the bases of the second and third metatarsal bones (Synnestvedt).

The **FIRST LAYER OF MUSCLES OF THE SOLE** includes the short common flexor of the toes, and the abductors of the great and little toes.

The **flexor brevis digitorum**, or **flexor perforatus**, arises by a small pointed attachment from the fore part of the inner tubercle of the calcaneum, from the deep surface of the plantar fascia for about two inches forwards, and from the intermuscular septum on each side. The muscle terminates in four slender tendons which are inserted into the sides of the second phalanges of the four outer toes. Each tendon prior to its insertion divides and gives passage to the tendon of the long flexor, in a manner precisely similar to the arrangement of the tendons of the flexor sublimis and flexor profundus muscles of the hand.

**Relations.**—This muscle lies between the abductor hallucis and abductor minimi digiti, and is covered by the plantar fascia ; it conceals the flexor accessorius, with the tendons of the flexor longus digitorum, and the external plantar vessels and nerve.

**Varieties.**—The slip of this muscle to the little toe, which is regularly much smaller than the others, is frequently wanting (23 per cent.) ; or it may be replaced (5 per cent.) by a small fusiform muscle arising from the long flexor tendon, or occasionally from the flexor accessorius. In rare cases the origin of the slip to the fourth toe is also transferred to the long flexor tendon. (In apes the perforated flexors of the outer toes arise regularly from the

<sup>1</sup> See Ruge, "Entwicklungsvorgänge an der Muskulatur des menschlichen Fusses," Morph. Jahrb., iv, 1878.

tendon of the flexor perforans.) On the other hand, the muscle has been seen with five tendons, one passing to the great toe, or two to the second toe. (Gruber, "Monographie des *Musc. flex. dig. brevis pedis*," &c., Wiener Denkschriften, 1889.)

The **abductor hallucis** muscle (*abd. pollicis pedis*) arises from the inner part of the larger tubercle of the calcaneum, from the internal annular ligament, from

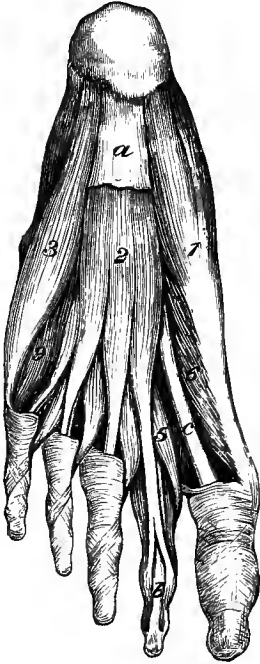


Fig. 261.—FIRST LAYER OF MUSCLES OF THE SOLE.  $\frac{1}{2}$

*a*, plantar fascia; *b*, tendon of flexor longus digitorum to second toe; *c*, tendon of flexor longus hallucis; 1, abductor hallucis; 2, flexor brevis digitorum; 3, abductor minimi digiti; 5, first lumbricalis; 6, inner head of flexor brevis hallucis; 9, flexor brevis minimi digiti.

the septum between it and the flexor brevis digitorum, and from the plantar fascia covering it. The fleshy fibres end in a tendon which, after being joined by fibres of the internal head of the flexor brevis hallucis, is inserted into the inner border of the base of the first phalanx of the great toe.

**Relations.**—It is covered by the thin internal division of the plantar fascia. Its deep surface is in contact with the tendons of the tibialis posticus and long flexor muscles, with the flexor brevis hallucis, and with the plantar vessels and nerves.

**Varieties.**—The abductor hallucis occasionally sends a slip to the base of the first phalanx of the second toe. Its tendon of insertion is sometimes joined by a muscular slip springing from the skin on the inner border of the foot, somewhat in front of the inner ankle; but this is not so frequent as the cutaneous slip of the corresponding muscle of the hand.

The **abductor minimi digiti** muscle has a wide origin behind, from the front of both tubercles on the under surface of the os calcis, from the external intermuscular septum, and from the deep surface of the band of the plantar fascia which extends from the external tubercle to the base of the fifth metatarsal bone. The fleshy fibres end in a tendon

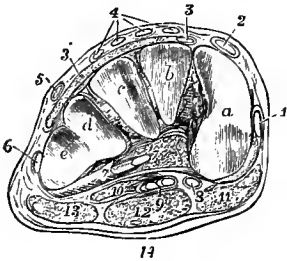


Fig. 262.—TRANSVERSE SECTION OF THE RIGHT FOOT BETWEEN THE TARSUS AND METATARSUS. (Allen Thomson.)  $\frac{1}{2}$

*a*, *b*, *c*, articular surfaces of the internal, middle, and external cuneiform bones; *d* and *e*, surfaces of the cuboid bone for the fourth and fifth metatarsal bones; 1, slip of the tendon of tibialis anticus, inserted into the first metatarsal bone; 2, tendon of extensor proprius hallucis; 3, slip of extensor brevis digitorum to the great toe; 3', remainder of extensor brevis digitorum; 4, tendons of extensor longus digitorum; 5, peroneus tertius; 6, peroneus brevis; 7, peroneus longus cut obliquely where it is emerging from its sheath below the cuboid bone; 8, tendon of flexor longus hallucis; 9, tendon of flexor longus digitorum; 10, flexor accessorius; 11, abductor hallucis; 12, flexor brevis digitorum; 13, abductor minimi digiti.

which, after gliding along a smooth depression on the inferior surface of the base of the fifth metatarsal bone, is inserted into the outer side of the base of the first phalanx of the little toe.

**Relations.**—The muscle is covered by the plantar fascia. Its deep surface is in contact with the outer head of the flexor accessorius, the long plantar ligament, the peroneus longus tendon, and the flexor brevis minimi digiti.

**Varieties.**—An additional slip of origin from the tuberosity at the base of the fifth



metatarsal bone is sometimes present (6 per cent.). The *abductor ossis metatarsi quinti* is an occasional muscle which arises from the external tubercle of the os calcis, and is inserted into the tuberosity of the fifth metatarsal bone in common with, or beneath the outer margin of the plantar fascia. It may be adherent to the abductor minimi digiti, and it has been seen inserted into the middle or even the anterior part of the metatarsal bone. It occurs in about 18 per cent. (Gruber, Virchow's Archiv, 1886, cvi, 489.)

The SECOND LAYER OF MUSCLES OF THE SOLE is constituted by the tendons of the flexor longus digitorum and flexor longus hallucis, together with the flexor accessorius and lumbricales, all of which have been described in the last section (pp. 265—266).

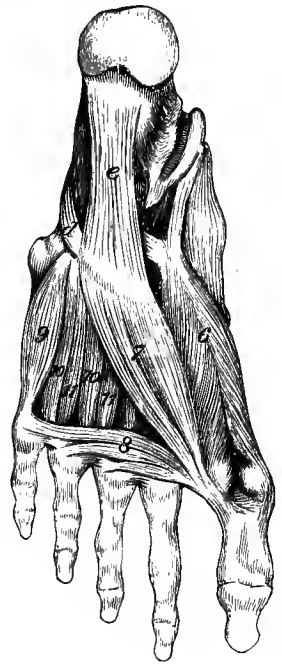The THIRD LAYER OF MUSCLES comprises the short flexor and the adductors of the great toe, and the short flexor of the little toe.

The **flexor brevis hallucis** (fl. brev. pollicis pedis) arises by a flat tendinous process from the inner border of the cuboid bone, and by a second band from the

Fig. 263.—THIRD LAYER OF MUSCLES OF THE SOLE.  $\frac{1}{2}$

*d*, tendon of peroneus longus; *e*, long plantar ligament; 6, flexor brevis hallucis; 7, adductor obliquus hallucis; 8, adductor transversus hallucis; 9, flexor brevis minimi digiti; 10, 10, second and third plantar interosseous muscles; 11, 11, third and fourth dorsal interosseous muscles.

offset of the tibialis posticus tendon which passes to the middle and outer cuneiform bones. The muscular part is single and narrow behind, but in front it divides so as to form two bellies or heads which are inserted by tendinous fibres, one into the inner border of the base of the first phalanx in union with the abductor hallucis, the other into the outer border in union with the adductors. A sesamoid bone is developed in each of the heads.



**Relations.**—This muscle is in great part covered by the abductor hallucis and the short flexor of the toes, while the tendon of the flexor longus hallucis runs in the groove between its heads.

**Varieties.**—The origin of the flexor brevis hallucis is subject to considerable variation: it often receives fibres from the os calcis or long plantar ligament, and the attachment to the cuboid is sometimes wanting. The muscle has been seen sending a slip to the first phalanx of the second toe.

The **adductor obliquus hallucis** (add. pollicis pedis), a thick fleshy mass occupying the hollow on the outer side of the first metatarsal bone, arises from the tarsal extremities of the third and fourth metatarsal bones, and from the sheath of the peroneus longus muscle; narrowing as it passes forwards, it is inserted, conjointly with the external head of the flexor brevis hallucis, into the base of the first phalanx of the great toe.

**Relations.**—At its inner side it is connected with the flexor brevis hallucis; its deep surface rests upon the second, third and fourth metatarsal bones and the intervening interosseous muscles. The deep parts of the external plantar artery and nerve pass inwards beneath its outer border.

**Varieties.**—A slip has been observed from this muscle also to the base of the first phalanx of the second toe. The *opponens hallucis* is a muscle occasionally found, coming off as a slip from the adductor, and inserted into the metatarsal bone of the great toe. It occurs in some apes.

The **adductor transversus hallucis** (transversus pedis) consists of narrow fasciculi of fleshy fibres, placed transversely under cover of the flexor tendons, and arising from the inferior metatarso-phalangeal ligaments of the three outer toes, and from the transverse metatarsal ligament. The fibres of the muscle pass transversely inwards, and are inserted in union with the adductor obliquus into the first phalanx of the great toe.

**Relations.**—Superficially it is crossed by the flexor tendons and by the digital nerves; its deep surface rests upon the heads of the metatarsal bones, the interosseous muscles and the digital vessels.

**Varieties.**—The slip from the little toe is frequently absent: absence of other slips or of the entire muscle has also been recorded.

The adductor transversus in early foetal life arises close to the adductor obliquus in the neighbourhood of the bases of the metatarsal bones, and subsequently travels forwards along

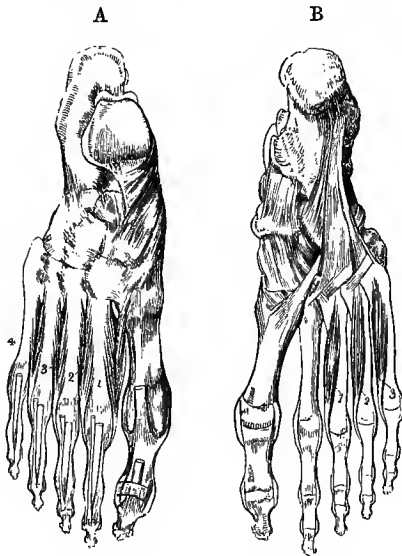

Fig. 264, A.—THE DORSAL INTEROSSEOUS MUSCLES FROM ABOVE.  $\frac{1}{4}$

1, 2, 3, 4, the several dorsal interosseous muscles in order from within outwards.

B.—THE PLANTAR INTEROSSEOUS MUSCLES FROM BELOW.

1, 2, 3, first, second, and third plantar interosseous muscles; this figure also shows the long and short plantar ligaments, and the insertion of the tendon of the peroneus longus into the first metatarsal bone.

the fascia covering the interosseous muscles, so as to acquire its transverse direction across the distal ends of the metatarsal bones. Occasionally its separation from the adductor obliquus is not complete, and fibres are found arising from the deep fascia in the interval between the two muscles. (Ruge, *Morph. Jahrb.*, iv, 1878.)

The **flexor brevis minimi digiti** arises by tendinous fibres from the base of the fifth metatarsal bone, and from the sheath of the peroneus longus, and terminates in a tendon which is inserted into the base and external border of the first phalanx of the little toe. In most cases some of the deeper fibres end on the distal half of the shaft of the fifth metatarsal bone.

**Relations.**—It is covered partly by the abductor minimi digiti, partly by the plantar fascia. It rests upon the fifth metatarsal bone, and its tendon blends at its insertion with the inferior metatarso-phalangeal ligament.

**Varieties.**—The portion of the muscle inserted into the fifth metatarsal bone represents an *opponens minimi digiti*, which is occasionally (3·5 per cent.) found entirely separate from the proper flexor brevis passing to the first phalanx. The insertion into the metatarsal bone is wanting in about 10 per cent. (Gruber, "Beobachtungen," Heft viii, 1887.)

THE FOURTH LAYER OF THE SOLE includes the dorsal and plantar interosseous muscles, with which the tendons of the tibialis posticus and peroneus longus are sometimes also enumerated.

The **interosseous muscles** of the foot, like those of the hand, are seven in number, three plantar and four dorsal; the plantar are visible only from the under side, while the dorsal muscles are visible both from above and below. Two muscles are found in the second, third and fourth spaces, but only one in the first.

The *dorsal interosseous* muscles lie one in each interspace. Each muscle arises by two heads from the adjacent sides of two metatarsal bones; their muscular fibres are attached pinnately on the two sides of a central tendon, which is inserted partly into the base of the first phalanx and partly into the extensor aponeurosis of the toe to which the muscle belongs. The first two are inserted one on each side of the second toe; the third and fourth are severally inserted on the outer sides of the third and fourth toes. At the proximal end of each muscle there is an interval between the two origins giving passage to perforating arteries as in the hand.

The inner head of the first dorsal interosseous muscle is smaller than the others, and arises from the base of the first metatarsal bone and the dorsal edge of the internal cuneiform. The third and fourth muscles also receive fibres posteriorly from the sheath of the peroneus longus.

The *plantar interosseous* muscles arise from the inner and under surfaces of the third, fourth and fifth metatarsal bones, and from the sheath of the peroneus longus; they are severally inserted, in a manner similar to the dorsal interossei, partly into the inner sides of the first phalanges of the third, fourth and fifth toes, and partly into the extensor tendons of these toes.

Bursæ are generally present between the heads of the metatarsal bones, often between the tendons of the plantar interosseous muscles and the metatarso-phalangeal articulations, and occasionally beneath the tendons of the second and third dorsal interosseous muscles (Gruber).

In the fœtus the dorsal interosseous muscles are originally situated on the plantar aspect of the closely appressed metatarsal bones and have only a single origin, which corresponds to the outer head of the fully formed muscle. The metatarsal bones then gradually become separated, and the muscles make their way in the intervals to the dorsum of the foot, acquiring at the same time their attachment to the inner bone, thus becoming two-headed. The definitive condition is attained by the twelfth week. In many animals these muscles are situated permanently in the sole. Similar changes take place in the muscles of the hand. (Ruge, *Morph. Jahrb.*, iv, 1878.)

**Nerves.**—The extensor brevis digitorum is supplied by the anterior tibial nerve. Of the muscles of the sole, the flexor brevis digitorum, the abductor and flexor brevis hallucis, and the innermost lumbricalis are supplied by the internal plantar nerve; all the others, including the flexor accessorius and the outer three lumbricales, are supplied by the external plantar nerve.

**Actions of the muscles of the leg and foot.**—There is only one muscle of the leg, viz., the *popliteus*, which acts on the knee-joint alone. Its principal action is that of a rotator inwards of the leg, but it also assists in bending the knee. It comes into play especially in the commencement of flexion, producing the inward rotation of the tibia (or outward rotation of the femur) which is essential to that stage of the movement.

It may here be observed that owing to the difference in the direction of the bend at the ankle, as compared with that at the wrist-joint, some confusion is apt to arise in the description of the action of the muscles of the leg upon the foot. As it is obvious from morphological considerations that the anterior surface of the leg and the dorsal surface of the foot belong to the general *extensor* surface of the limb, corresponding with the back of the forearm and the dorsum of the hand; and that the back of the leg and the sole of the foot belong in the same way to the general *flexor* surface corresponding with the front of the forearm and the palm of the hand, the foot being in a position of over-extension, it follows that the muscles on the anterior aspect of the leg are really extensors, and that their action in moving the foot so as to approximate the toes to the front of the leg merely increases the over-extension; while, on the other hand, the muscles on the posterior aspect of the leg are really flexors, and their action in straightening the ankle-joint is merely to reduce this over-extension by an opposite movement of flexion. Nevertheless, it has been customary to apply the name of flexion to the action of raising the foot on the front of the leg, and that of extension to its depression. In the following description the usual terms are employed.

The *gastrocnemius* acts both as a flexor of the knee and an extensor of the ankle-joint. When the anterior muscles of the leg fix the ankle-joint, it is fitted to act as a flexor of the knee; when the knee is fixed either by being placed in complete extension or by the sustained action of the extensor muscles, the gastrocnemius acts entirely on the foot, and combines with the *soleus* in lifting the heel from the ground, and in raising the body on the toes.

The *tibialis anticus* and *peroneus tertius* are flexors of the ankle; the *tibialis posticus* and

*peroneus longus* and *brevis* are extensors. The *tibialis posticus* produces the movement of inversion of the foot, in which action it is aided by the flexors of the toes. The three peronei and the extensors of the toes draw the foot upwards and outwards, and thus produce the movement of eversion. The *peroneus longus*, in crossing the foot inferiorly, strengthens the transverse arch formed by the metatarsal bones and anterior range of tarsal bones, especially when that arch is pressed upon by the weight of the body falling on the balls of the toes, as in stooping with bent knees; it also comes into play in walking, lifting the outer border of the foot, and throwing the weight onto the first metatarsal bone as the hinder foot is leaving the ground (p. 198).

The *flexor* and *extensor muscles* of the toes, including the *lumbricales* and *interosseous muscles*, act like the corresponding muscles in the hand. The direction of the *flexor longus digitorum* is, however, modified by the *flexor accessorius*, so as to bring its line of action into the direction of the middle of the foot and of the short flexor. The *tibialis posticus* and the flexors of the toes give important assistance to the ligaments and the plantar fascia in supporting the longitudinal arch of the foot.

#### MORPHOLOGY OF THE LIMB-MUSCLES.

It has already been mentioned (p. 201) that the muscles of the limbs and limb-girdles are primarily derived mainly from the ventro-lateral division of the epaxial set of muscles. In the case of the upper limb there are no muscles of hypaxial origin, but in the lower limb the *psaos* may be regarded as a prolongation outwards from the hypaxial set. As each limb begins bud-like to project from the side of the embryo, it may be supposed to receive an enveloping sheath of muscle from the side of the body. This sheath appears to be derived solely from the external of the three layers into which the trunk-portion of the ventro-lateral muscle divides (see later the morphology of the trunk-muscles). Forming at first a simple infundibulum, it gradually extends in length with the growth of the limb, and becomes segmented *pari passu* with the segmentation of the hard parts. The deeper fibres of the sheath are restricted to passing from one segment to the next, while the superficial fibres are frequently found to pass over one segment altogether to more distal parts. In the upper limb, from the greater freedom of movement of the girdle, and from its more superficial position, the proximal portion of the muscular sheath is longer, and its constituent parts are more easily recognized than in the case of the corresponding parts of the lower limb, which are not differentiated to the same extent from the trunk-muscles. The muscles passing from the trunk to the shoulder-girdle and the humerus fall into two primary divisions. Anteriorly are the pectorals and the subclavians, supplied by the ventral branches of the limb-nerves. Posteriorly are the more numerous muscles supplied by the dorsal divisions of the limb-nerves, and separated again into two masses, a superior and an inferior. The superior mass includes a superficial sheet consisting of the cleido-mastoid and trapezius (in part at least), the latter of which is continued to the humerus by the deltoid, and a deeper sheet constituted by the rhomboidei and the serratus magnus with its cervical prolongation the levator anguli scapulæ. The inferior mass is composed of the latissimus dorsi and a deeper part, the teres major, which has become segmented off and acquired an attachment to the scapula: the occasional origin of the latissimus dorsi from the lower angle of the scapula is an indication of the primitive connection of these muscles. As the muscles of this series have been formed by a process of differentiation occurring in a continuous sheath, so they are often found to some extent united together, either as varieties in man, or as regular structures in some of the lower animals. Thus in *Lepidosiren* the pectoralis major and latissimus dorsi are blended together at their margins, so as to form one continuous muscle; and in man the frequently recurring axillary arches or muscular slips which pass from one muscle to the other across the axillary space may point to an imperfectly segmented condition. Again, the pectoralis major is always united in man with the superficial fibres of the external oblique, but in *Cryptobranchus* the two are continuous in their entire thickness. The cleido-mastoid and the clavicular part of the trapezius are sometimes connected, and in those animals in which the clavicle is deficient they are continued into the representatives of the clavicular portions of the pectoralis major and deltoid to form a cephalo-humeral muscle.

In the case of the lower limb, the superficial layer of the anterior muscles, owing to the absence of the ventral extensions of the trunk-skeleton and the greater development of the limb-girdle, arises entirely from the latter, and thus the pectoralis major is probably represented by the superficial adductors, longus and brevis, while the deep layer is suppressed in association with the loss of mobility in the hip-girdle. The gracilis also belongs to this group, corresponding to the occasional chondro-epitrochlearis prolonged from the lower fibres of the pectoralis major. The superior mass of the posterior division is not differentiated from the primitive sheet, so that the trapezius, rhomboidei and serratus magnus are represented only by a part of the external oblique; and the inferior mass forms the gluteus maximus,

which corresponds to the latissimus dorsi and teres major, with probably the hinder part of the deltoid.

All the other muscles of the limb are *intrinsic*, and in their relation to the several segments are arranged in groups which may in the main be compared homologically with each other. These groups also show a primary division into dorsal or extensor masses, supplied by the posterior branches of the limb-nerves, and ventral or flexor masses, receiving their nerves generally from the anterior branches of the trunks entering the limbs.<sup>1</sup> The manner in which these masses are cleft to form separate muscles, however, is found to vary in the two limbs, especially in their proximal portions, in accordance with difference of function, and thus a precise correspondence between individual muscles is not always to be looked for. In the distal segments of both limbs the muscles, although more numerous, become shorter and more uniform in their disposition, and hence the homology becomes more apparent between the muscles of the hand and foot than in those situated nearer the roots of the limbs.

The intrinsic muscles passing from the girdle to the first segment of the limb have been partly referred to above, in so far as they are closely connected with extrinsic muscles passing from the trunk, and where extrinsic muscles of the upper limb are represented by intrinsic muscles of the lower limb (*e.g.* pectoralis major and the superficial adductors). The dorsal muscles are respectively scapulo-humeral and ilio-femoral; the ventral fall into claviculo-humeral (part of the pectoralis major) and pubo-femoral (adductors longus and brevis), and coraco-humeral and ischio-femoral. In accordance with the homologies that have been traced between the different parts of the scapula and ilium (p. 141), the subscapularis is represented by the gluteus medius and minimus, and the infraspinatus by the iliacus, while there appears to be no separate muscle at the hip corresponding to the supraspinatus of the shoulder. The teres minor is probably a derivative of the hinder part of the deltoid, the connection between the two being indicated occasionally by slips joining the latter muscle from the lower part of the scapula; the pyriformis is a segmentation of the same mass as the two smaller glutei; and the pectineus appears from its innervation to be a displaced part of the iliacus: these muscles have no separate representatives in the other limb. The coraco-humeral muscles in man and mammals generally are much reduced in comparison with their condition in the lower vertebrate forms, where the coracoid element of the shoulder-girdle is of large size, their function as adductors being discharged by muscles passing from the trunk: they form the several parts of the coraco-brachialis muscle (p. 219). The ischio-femoral muscles, on the other hand, are largely developed, and give rise to the quadratus femoris and adductor magnus, together with the obturators and gemelli: the obturator internus has extended its origin from the ischium to the inner surface of the pelvis, and the gemelli are portions of the muscle retaining the original connection. The adductor magnus probably contains also, in the part supplied by the great sciatic nerve, an element derived from the long flexor mass of the thigh, and the attachment to the tibia represented by the internal lateral ligament of the knee (p. 184) may be the insertion of this element.

In the first segment of the limb the flexor and extensor masses both show a division into a superficial long part arising from the limb-girdle, and a deep short part springing from the bone of the segment; but considerable differences exist in the mode of cleavage of these parts and in the insertion of the muscles thus formed. The sartorius is a derivative of the long extensor of the thigh, and may be compared to the dorso-epitrochlearis of the arm.

In the middle segment also a similar division into superficial long muscles arising from the bone of the upper segment, and short deep muscles arising from the bones of the proper segment, is to be recognized. These muscles are for the most part inserted into the distal segment of the limb, passing either to the metacarpal (or metatarsal) bones or to the digital phalanges, but in the forearm the pronators and supinators become separated off from the flexors and extensors respectively, and are inserted into the radius. In the leg in man there is only one such muscle developed, *viz.*, the popliteus, corresponding to the pronator teres of the forearm. In comparing the musculature of the leg with that of the forearm marked differences are observed, which may for the most part be referred to the following heads:—1, a reduction in number in accordance with the diminution of mobility, and due partly to less complete differentiation and partly to suppression or absence of certain elements; 2, the disappearance of the high origin of some of the superficial muscles, especially those of the extensor group; and 3, the development of insertions into the tarsal bones, most conspicuous in the case of the superficial flexors which, owing to the outgrowth of the heel, become completely separated from their continuations in the foot. In the arrangement of the deep extensor muscles, which in the upper limb arise from the forearm bones, whereas in the lower

<sup>1</sup> The only exceptions to this statement as to the nervous supply of the muscular groups are the short head of the biceps in the lower limb, which is supplied from the external popliteal division of the great sciatic nerve—the posterior or extensor nerve of the distal portion of the limb, and the brachialis anticus, which commonly receives a small branch from the musculo-spiral—the extensor nerve-trunk of the upper limb.

limb they are confined to the foot, there is reason for believing that the latter condition is the primary one (H. St. John Brooks. "The Morphology of the Extensor Muscles." Proc. Anat. Soc., 1888, and "Studies from the Museum of Zoology," University College, Dundee, 1889).

The short muscles of the digits may be derived from a typical arrangement consisting of—1, a superficial layer of four muscles, primarily adductors; 2, an intermediate layer of bicapital short flexors, one for each digit; and 3, a deep, or dorsal, layer of abductors, six in number. The deep branch of the ulnar (or external plantar) nerve crosses between the first and second layers. In the hand, the outermost muscle of the first layer is largely developed, forming the adductors of the thumb, the innermost muscle gives rise to the flexor brevis and the larger part of the opponens minimi digiti, and the two central muscles are suppressed. The

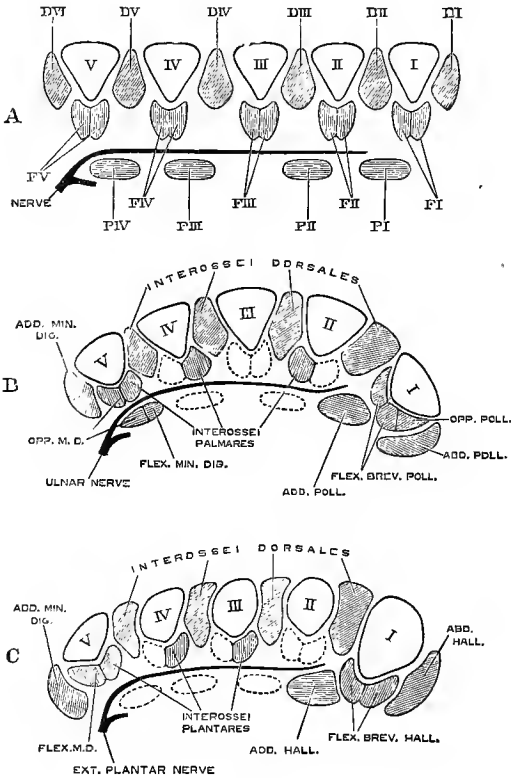


Fig. 265. — DIAGRAMS SHOWING THE ARRANGEMENT OF THE SHORT DIGITAL MUSCLES IN TRANSVERSE SECTIONS OF THE METACARPAL OR METATARSAL REGIONS. A, TYPICAL ARRANGEMENT; B, MUSCLES OF HAND; C, MUSCLES OF FOOT. (Based on Cunningham.) (G. D. T.)

I—V, first to fifth metacarpal or metatarsal bones; D I—D VI, the dorsal layer of abductors; F I—F V, the intermediate layer of short flexors; P I—P IV, the plantar layer of adductors. In B and C, the absent elements are indicated by dotted outlines.

two heads of the short flexor of the thumb are retained, the opponens pollicis being a segmentation of the outer head; the ulnar head of the index flexor becomes the first palmar interosseous, the radial heads of the short flexors of the ring and little fingers form the second and third palmar interosseous muscles, and the ulnar head of the little finger muscle is represented only by the small part of the opponens minimi digiti deeper than the nerve; the radial head of the flexor indicis, both heads of the flexor medii, and the ulnar head of the flexor annularis are absent.

The deep layer is represented in the abductors of the thumb and little finger, with the four dorsal interosseous muscles, two of which become inserted into the middle finger. In the foot, while the general disposition of the muscles is similar, there are the following differences in detail:—The adductor muscle of the little toe is also suppressed, and the flexor brevis and opponens are formed from the fibular head of the short flexor; both heads of the short flexor of the second toe are absent, and the first plantar interosseous is the inner head of the short flexor of the third toe, while the second dorsal interosseous muscle becomes inserted into the fibular side of the second toe. (D. J. Cunningham, Journ. Anat., xii and xiii, and "Challenger" Reports, Zoology, v; H. St. John Brooks, Journ. Anat., xx.)

The chief points of importance in seeking to determine muscular homologies are position, attachments and nervous supply. With reference to these it may be remarked:—1. The position of a muscle may be changed, and it may thus acquire an action differing from that of the mass from which it is derived. Thus, the supinator longus undoubtedly belongs to the dorsal or extensor mass of the upper limb, but being placed in front of the elbow it becomes a flexor of that joint; similarly, the peronei, longus and brevis, belonging to the proper dorsal group of the leg, but passing behind the external malleolus, produce movement of the

foot to the ventral aspect. 2. The attachments of homologous muscular masses may vary in accordance with functional necessity and skeletal modifications, as seen in the insertion of the extensor of the elbow into the postaxial ulna, of that of the knee into the preaxial tibia, or in the origin of the long extensor of the fingers from the humerus, while that of the toes arises from the leg-bones. 3. Nervous supply is undoubtedly the most valuable guide to muscular homology, but is however not infallible, since variations in the nerve-supply of certain muscles occur sometimes in man, and muscles which undoubtedly correspond are occasionally supplied by different nerves in allied animals. (See D. J. Cunningham, "The Value of Nerve-Supply in the Determination of Muscular Homologies and Anomalies," Journ. Anat., xxv, 1890.)

In the subjoined table the most probable views as to the homological relations of the muscles of the two limbs are presented; but it is proper to state that, while in some cases the resemblance is so obvious that there can be little doubt as to the correspondence indicated, yet in others there is much uncertainty as to the morphological nature of the muscles compared, and that anatomists are by no means agreed as to the manner in which the muscles of one limb are represented in the other.

TABLE OF MUSCULAR HOMOLOGIES IN THE UPPER AND LOWER LIMBS.

I. MUSCLES PASSING FROM TRUNK TO LIMBS, AND FROM GIRDLE TO HUMERUS OR FEMUR.

<i>Upper Limb.</i>	<i>Lower Limb.</i>
Trapezius . . . . .	} External oblique and lumbar aponeurosis.
Cleido-mastoid . . . . .	
Rhomboidei . . . . .	
Levator anguli scapulae . . . . .	
Serratus magnus . . . . .	} Tensor vaginae femoris. Gluteal fascia. Gluteus maximus, upper part.
Deltoid . . . . .	
Teres minor . . . . .	
Latissimus dorsi . . . . .	} Gluteus maximus, larger part.
Teres major . . . . .	
Pectoralis major . . . . .	} Adductor longus. Adductor brevis.
Pectoralis minor . . . . .	
Subclavius . . . . .	Psoas.
Supraspinatus . . . . .	} Iliacus. Pectineus. Gluteus medius. Gluteus minimus. Pyriformis.
Infraspinatus . . . . .	
Subscapularis . . . . .	
Coraco-brachialis . . . . .	} Obturator internus, with Gemelli. Obturator externus. Quadratus femoris. Adductor magnus.
<i>Chondro-epitrochlearis</i> <sup>1</sup> . . . . .	
	Gracilis.

II. MUSCLES OF THE ARM AND THIGH, PASSING OVER THE ELBOW- AND KNEE-JOINTS.

Biceps flexor cubiti . . . . .	} Ischial head of Biceps cruris. Semitendinosus. Semimembranosus.
<i>Humeral head of Biceps</i> . . . . .	
Brachialis anticus . . . . .	
<i>Dorso-epitrochlearis</i> . . . . .	} Femoral head of Biceps cruris. Sartorius.
Triceps extensor cubiti . . . . .	
<i>a.</i> Scapular head . . . . .	} Quadriceps extensor cruris. <i>a.</i> Rectus femoris. <i>b.</i> Vasti and crureus.
<i>b.</i> Humeral heads . . . . .	
Anconeus . . . . .	

<sup>1</sup> The names of muscles printed in italics are those of varieties more or less frequently found in human anatomy.

## III. MUSCLES OF THE FOREARM AND LEG.

Pronator radii teres . . . . .	Popliteus.
Flexor carpi radialis . . . . .	} Gastrocnemius.
Flexor carpi ulnaris . . . . .	
Palmaris longus . . . . .	Plantaris.
Flexor sublimis digitorum . . . . .	Soleus and Flexor brevis digitorum.
Flexor longus pollicis . . . . .	} Flexor longus hallucis.
Flexor profundus digitorum . . . . .	
Lumbricales . . . . .	Lumbricales.
Pronator quadratus . . . . .	
<i>Ulna-carpeus</i> . . . . .	<i>Peroneo-calcaneus internus.</i>
<i>Radio-carpeus</i> . . . . .	Tibialis posticus.
Supinator longus . . . . .	
Extensor carpi radialis longior . . . . .	
Extensor carpi radialis brevior . . . . .	
Extensor communis digitorum . . . . .	Extensor longus digitorum.
Extensor minimi digiti . . . . .	Peroneus tertius (?).
Extensor carpi ulnaris . . . . .	} Peroneus longus. Peroneus brevis.
Supinator brevis . . . . .	
Extensor ossis metacarpi pollicis . . . . .	Tibialis anticus.
Extensor longus pollicis . . . . .	Extensor longus hallucis.
Extensor brevis pollicis . . . . .	First slip of Extensor brevis digitorum.
Extensor indicis . . . . .	Second slip of Extensor brevis digitorum.
<i>Extensor medii digiti</i> . . . . .	} Extensor brevis digitorum.
<i>Extensor brevis digitorum</i> . . . . .	

## IV. MUSCLES OF THE HAND AND FOOT.

Palmaris brevis . . . . .	
Abductor pollicis . . . . .	Abductor hallucis.
Flexor brevis pollicis . . . . .	Flexor brevis hallucis.
Opponens pollicis . . . . .	<i>Opponens hallucis.</i>
Adductor obliquus pollicis . . . . .	Adductor obliquus hallucis.
Adductor transversus pollicis . . . . .	Adductor transversus hallucis.
Abductor minimi digiti . . . . .	Abductor minimi digiti.
Flexor brevis minimi digiti . . . . .	
Opponens minimi digiti . . . . .	} Flexor brevis minimi digiti. <i>Opponens minimi digiti.</i>
<i>a.</i> superficial part . . . . .	
<i>b.</i> deep part . . . . .	
First palmar interosseous . . . . .	First plantar interosseous.
Second palmar interosseous . . . . .	Second plantar interosseous.
Third palmar interosseous . . . . .	Third plantar interosseous.
First dorsal interosseous . . . . .	First dorsal interosseous.
Second dorsal interosseous . . . . .	Second dorsal interosseous.
Third dorsal interosseous . . . . .	Third dorsal interosseous.
Fourth dorsal interosseous . . . . .	Fourth dorsal interosseous.

## III.—THE MUSCLES AND FASCIÆ OF THE HEAD AND NECK.

## EPICRANIAL REGION.

FASCIA.—The **superficial fascia** is little developed on the head and neck generally, and is in great measure blended with structures described under other names. A layer of considerable firmness, however, intervenes between the aponeurosis of the occipito-frontalis muscle and the skin, uniting them closely together: from the surface of the occipital part of the muscle it becomes continuous with the superficial covering of the posterior muscles of the neck, and on each side of the



epicranial aponeurosis it descends as a thin areolar layer between the external muscles of the ear and the skin of the temporal region.

**MUSCLES.**—Under the title of **occipito-frontalis** are comprised the occipital and frontal muscles, united together by a thin aponeurosis which extends over and covers the upper part of the cranium.

The **occipitalis** muscle, thin and subcutaneous, is attached inferiorly by short tendinous fibres to the external two-thirds, sometimes less, of the superior curved

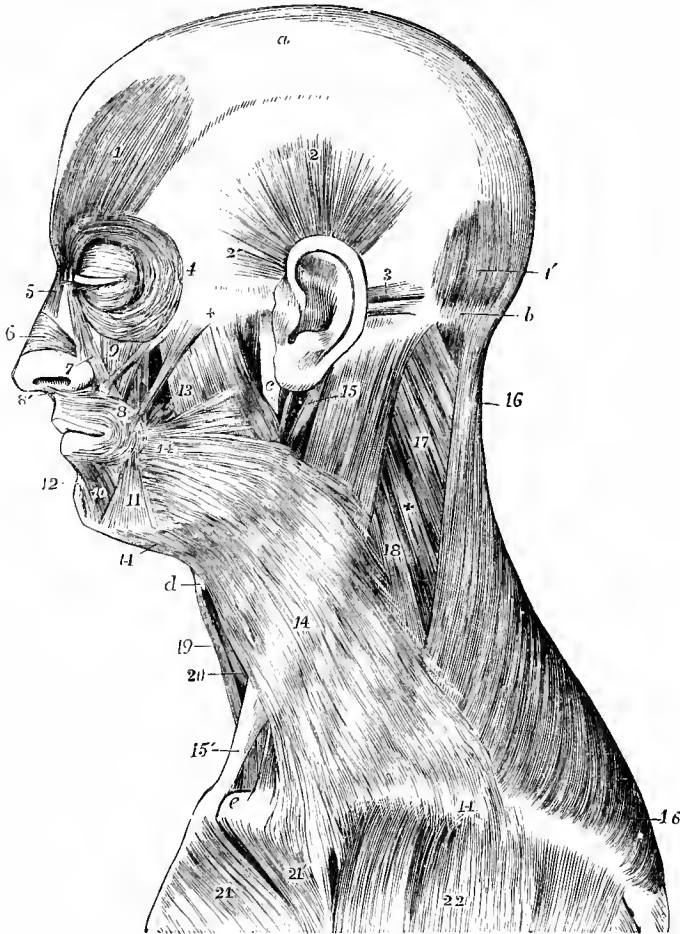


Fig. 266.—SUPERFICIAL MUSCLES ON THE LEFT SIDE OF THE HEAD AND NECK. (Allen Thomson, after Bourguery.)  $\frac{1}{3}$ .

*a*, epicranial aponeurosis ; *b*, superior curved line of the occipital bone ; *c*, ramus of lower jaw ; *d*, hyoid bone ; *e*, sternal end of clavicle ; 1, frontalis muscle ; 1', occipitalis ; 2, superior auricular muscle ; 2', anterior auricular ; 3, posterior auricular ; 4, margin of orbicularis palpebrarum ; 5, pyramidalis nasi ; 6, compressor naris ; 7, levator labii superioris aequae nasi ; 8, orbicularis oris ; 8', its attachment to the septum narium ; 9, levator labii superioris, and close by it, zygomaticus minor ; between *x* and 8, zygomaticus major ; and between the zygomatici, in shadow, is seen a portion of the levator anguli oris ; 10, depressor labii inferioris ; 11, depressor anguli oris ; 12, levator menti ; 13, on the masseter, is immediately above the risorius, and a line from it points to the buccinator ; 14, platysma myoides ; 15, on the upper part of the sterno-mastoid, points by a line to the posterior belly of the digastric muscle ; 15', the sternal head of the sterno-mastoid, a part of its clavicular head is seen near *c* ; 16, trapezius ; 17, splenius capitis ; 18, levator scapulae ; 19, sterno-hyoid ; 20, omo-hyoid ; 21, pectoralis major, its sterno-costal part ; 21', its clavicular part ; 22, deltoid.

line of the occipital bone, and to the mastoid portion of the temporal bone above the attachment of the sterno-mastoid muscle. Its fleshy fibres, from one to two inches in length, are directed upwards, and terminate in distinct tendinous fibres, continuous with the epicranial aponeurosis. The interval between the muscles of opposite sides is occupied by the aponeurosis.

The **frontalis** muscle, larger and of a paler colour than the occipitalis, arises superiorly in a convex line from the epicranial aponeurosis between the coronal suture and the frontal eminence. Inferiorly the fibres terminate in the subcutaneous tissue at the root of the nose and along the whole length of the eyebrow, the inner fibres appearing to be continued into the pyramidalis nasi muscle, while the larger number interlace with those of the corrugator supercillii and orbicularis palpebrarum. The fibres are nearly vertical, running slightly inwards as they descend: the margins of the right and left muscles are united for some distance above the root of the nose, but are separated by an angular interval superiorly.

The **epicranial** or **occipito-frontal aponeurosis** extends over the upper surface of the cranium uniformly from side to side, without division. Posteriorly it is attached to the occipitales muscles, and to the protuberance and highest curved lines of the occipital bone, and anteriorly it terminates in the frontales muscles, while laterally it presents no distinct margin, but below the temporal lines becomes thinner and less aponeurotic, and gives attachment to the superior and anterior auricular muscles. Its fibres are chiefly longitudinal, and are most distinctly tendinous where they give attachment to the occipitales muscles. Its outer surface is firmly bound to the skin by an abundant network of connective tissue, constituting the so-called superficial fascia, by the meshes of which the subcutaneous fat is divided into granules; while its deep surface glides upon the subjacent pericranium, to which it is loosely attached by a delicate areolar tissue devoid of fat. Beneath the lateral prolongation of the epicranial aponeurosis a thin fascial layer springs from the superior temporal line of the parietal bone, and is continued downwards on the deep surface of the auricular muscles to the pinna of the ear.

**Varieties.**—Both parts of the occipito-frontalis are subject to variation in their development, and in their places of attachment. The occipitalis occasionally approaches the middle line, and is frequently broken up into separate parts: its outermost fibres are sometimes inserted into the back of the pinna, becoming continuous with the posterior auricular muscle. The frontalis may send slips from its inner part to the frontal, nasal, or superior maxillary bones, or into the levator labii superioris alæque nasi, or from its outer part to the external angular process of the frontal bone, all of which have been described as normal by different anatomists.

**Actions.**—By the contraction of the frontales muscles the eyebrows are elevated, the scalp drawn forwards, and the skin of the forehead thrown into transverse wrinkles; by the contraction of the occipitales muscles the scalp is drawn backwards; and by the alternate action of the frontales and occipitales muscles the scalp is moved forwards and backwards. In the majority of persons, however, there is only a partial control over the action of these muscles, limited to the elevation of the eyebrows and horizontal wrinkling of the forehead.

#### AURICULAR MUSCLES.

Besides minute bundles of muscular fibres which pass from one part of the pinna to another, and which will be most conveniently described with that structure, there are attached to the external ear three larger, but still very slightly developed, muscles, which serve to move it as a whole.

The **auricularis superior** or **attollens auriculam**, the largest of the three, arises in the temporal region of the head from the epicranial aponeurosis. Its fibres are extremely delicate, and converge from a wide surface to be inserted by a compressed tendon into the anterior part of the helix and into the eminence on the inner surface of the pinna corresponding to the fossa of the antihelix.

The **auricularis anterior** or **atrahens auriculam**, scarcely separate from the preceding muscle, is pale and indistinct, and is attached to the thin lateral prolongation of the epicranial aponeurosis, from which it passes backwards to be inserted into the fore part of the helix.

The **auricularis posterior** or **retrahens auriculam** muscle consists of two or three fasciculi, which arise from the mastoid portion of the temporal bone by short tendinous fibres, and are inserted into a vertical ridge of the cartilage of the pinna at the back part of the concha. The fibres are deeper in colour and more distinctly marked than in either of the other auricular muscles.

**Varieties.**—Of the auricular muscles the posterior and the anterior are subject to greater varieties than the superior, but all vary somewhat in the extent of their development, the posterior more frequently by an increase in the number of its slips, the anterior by a diminution of the volume and distinctness of its fibres. The origin of part of the retrahens is sometimes carried backwards to a variable extent along the superior curved line of the occipital bone. Cruveilhier describes as normal a deep anterior auricular muscle, passing from the zygomatic process to the outer surface of the tragus. (See also Schwalbe, Arch. f. Anat., Suppl. Bd., 1889, 264.)

**Actions.**—The three auricular muscles respectively draw the pinna of the ear upwards, backwards, and forwards. In the majority of persons their action is not directly under voluntary control.

#### THE MUSCLES OF THE EYELIDS AND EYEBROW.

These are four in number, namely, the orbicularis palpebrarum and tensor tarsi, the levator palpebræ superioris, and the corrugator supercillii.

The **orbicularis palpebrarum** is a thin elliptical muscle surrounding the fissure between the eyelids and covering their surface, and spreading for some distance outwards on the temple, upwards on the forehead, and downwards on the cheek. It consists of two parts which differ in their arrangement and action. The central or *palpebral* portion is that part of the muscle which is contained in the eyelids. It is composed of thin pale fibres which arise from the upper and lower margins of the internal tarsal ligament, and pass outwards, describing a slight curve, to be inserted into the much less developed external tarsal ligament. A somewhat thicker fasciculus, which lies along the free margin of each lid, is distinguished as the *ciliary* bundle. The peripheral or *orbital* portion is larger, stronger, and of a deeper colour. Internally its fibres are attached to the inner part of the tarsal ligament, to the whole length of the nasal process of the superior maxilla, and to the inner part of the orbital arch of the frontal bone, while externally the fibres pass uninterruptedly from the eyebrow to the cheek, thus forming a series of concentric loops or, in the case of the more central fibres, nearly complete rings.

**Relations.**—The palpebral portion of the muscle is separated anteriorly from the skin by a layer of loose areolar tissue devoid of fat; posteriorly it rests upon the fibrous groundwork of the lids (tarsi) with the palpebral fascia. The orbital portion is more closely united to the skin; it lies in its upper part over the frontal bone and the corrugator supercillii, and is intimately connected with the insertion of the frontalis muscle: in its lower part it rests upon the superior maxillary and malar bones, and the origins of the elevator muscles of the upper lip and ala of the nose, and from both its inner and outer ends fibres are sent downwards to those muscles and to the skin of the cheek. These slips are described separately by Henle under the name of *malaris* muscle.

The *internal tarsal* or *palpebral ligament* (tendon of the orbicularis, tendo palpebrarum) is a small white band which is often obscured by the fibres of the orbicularis muscle, but is rendered prominent by drawing the lids outwards. This ligament is about two lines in length and half a line in breadth, and is attached to the nasal process of the superior maxilla, in front of the lachrymal groove; thence

it runs horizontally outwards to the inner commissure of the eyelids, where it divides into two thin fibrous lamellæ, which diverge and terminate on the tarsi.

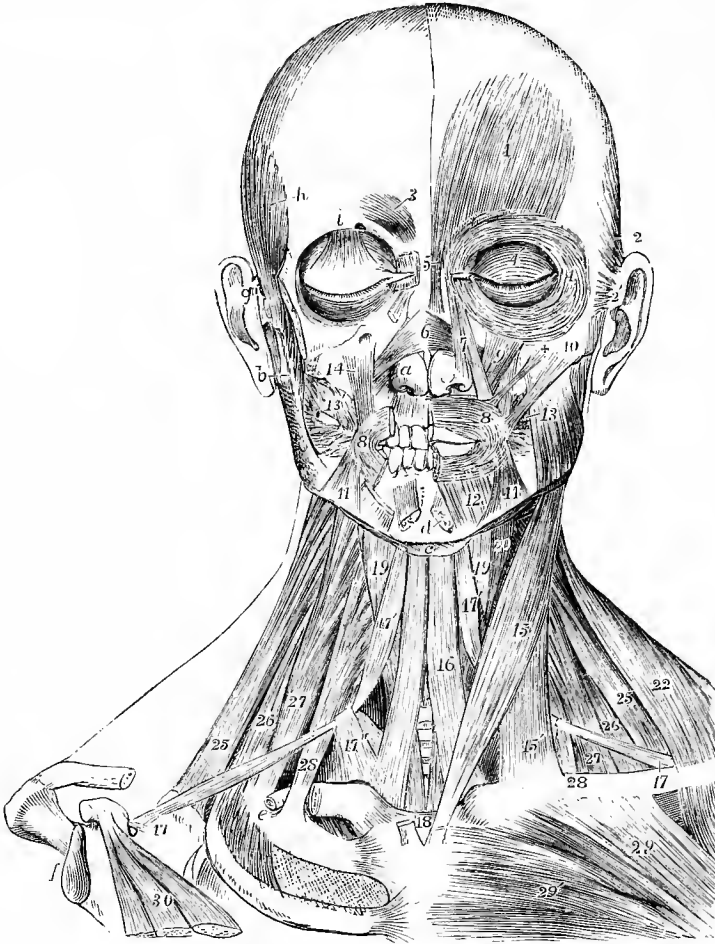


Fig. 267.—SUPERFICIAL AND DEEP MUSCLES OF THE HEAD AND NECK, FROM BEFORE.  
(Allen Thomson, after Bourguery.)

On the left side, the platysma alone has been removed; on the right side, portions of the zygomatic arch and clavicle, the superficial muscles of the cranium and face, the masseter, trapezius, sternomastoid and pectoralis major muscles have been removed. *a*, lower lateral cartilage of the nose; *b*, upon the lobule of the right ear, points to the coronoid process of the lower jaw; *c*, hyoid bone; *d*, symphysis of lower jaw; *e*, upon the groove of the first rib, lying in which is the cut end of the subclavian artery; *f*, glenoid cavity of the scapula; *g*, base of right zygoma; *h*, temporal crest of frontal bone; *i*, orbital arch; 1, frontalis muscle; 2, superior auricular; 2', anterior auricular; 3, corrugator supercili; 4, orbital portion of the orbicularis palpebrarum; 4', palpebral portion; below *z*, the expanded insertion of the levator palpebræ superioris in the eyelid; 5, pyramidalis nasi; 6, insertion of compressores naris on dorsum of nose; 7, levator labii superioris alæque nasi; 8, left half of orbicularis oris; 8', outer part of the same on the right side, the inner part being removed; 9, levator labii superioris; +, zygomaticus minor; 10, zygomaticus major; 11, depressor anguli oris; 12, depressor labii inferioris; *d*, cut ends of levatores menti; 13, placed on the left masseter, points to the buccinator; 13', buccinator of the right side, a portion of the parotid duct passing through the muscle; 14, levator anguli oris, seen also on the left side behind the zygomaticus minor; 15, sterno-mastoid, its sternal head, and 15', its clavicular head; 16, sterno-hyoid; 17, posterior, 17', anterior belly of omohyoid, and 17'', portion of deep fascia binding down its central tendon; 18, sterno-thyroid; 19, thyro-hyoid; 20, part of constrictors of pharynx; 22, trapezius; 25, levator scapulæ; 26, scalenus posticus; 27, scalenus medius; 28, scalenus anticus; 29, 29', pectoralis major; 30, pectoralis minor.

One surface of the ligament is subcutaneous ; the other crosses the lachrymal sac, to which it is closely adherent, a little above the centre, and from it a process is given off, which passes on the posterior side of the sac to be attached to the crest on the lachrymal bone. The *external tarsal ligament* is a much weaker structure connecting the eyelids to the malar bone.

The **tensor tarsi** (*musc. sacci lachrymalis*, Horner) is regarded by many anatomists as only a deep origin of the palpebral part of the orbicularis muscle. It consists of a thin layer of fibres, which springs from the lachrymal crest behind the sac and, passing outwards and forwards, divides into two slips which are continued behind the lachrymal canals into the ciliary bundles of the orbicularis.

The **corrugator supercilii** is a small, deeply-coloured muscle, placed at the inner side of the eyebrow, under cover of the orbicularis and frontalis muscles. It arises from the inner extremity of the superciliary ridge of the frontal bone ; thence its fibres proceed outwards and upwards, diverging somewhat, and end about the middle of the orbital arch, by passing between the bundles of the orbicularis and frontalis, and becoming inserted into the deep surface of the skin of the eyebrow.

**Relations.**—This muscle rests upon the frontal bone, and it crosses the supratrochlear branch of the ophthalmic nerve and the accompanying vessels, as they emerge from the orbit.

The **levator palpebræ superioris** lies in the upper part of the orbit. Its tendon only is seen in the dissection of the upper eyelid, where it forms a broad expansion which curves downwards, and ends under cover of the orbicularis muscle and palpebral ligament by becoming blended with the fibrous tarsus. It will be fully described along with the muscles of the orbit (p. 289).

**Actions.**—The palpebral part of the *orbicularis* closes the eyelids, the upper lid ordinarily moving much more freely than the lower. The upper half of the orbital part depresses the eyebrow, and stretches the skin of the forehead, opposing the frontalis muscle ; the lower half of this part raises the skin of the cheek, and gives rise to wrinkles below and outside the eye. The whole muscle comes into play in forcible closure of the eye, the orbital part then drawing up the surrounding skin and pressing the lids firmly together, while they at the same time are carried somewhat inwards towards the fixed part of the muscle. In closing the lids, as in winking, the contraction of the palpebral part of the orbicularis carries forwards the internal tarsal ligament and anterior wall of the lachrymal sac, which is thus dilated and sucks in the tears. The *tensor tarsi* muscle, according to one view, contracts simultaneously with the orbicularis, and draws backwards the puncta lachrymalia, disposing them more favourably for the admission of the tears ; but it appears more probable that the tensor alternates in its action with the orbicularis, and that, by drawing backwards the tarsal ligament, it compresses the sac, and so propels the tears along the nasal duct into the nose. The *corrugator* muscle draws the skin of the outer part of the forehead downwards and inwards, producing longitudinal furrows at the inner end of the eyebrow, as in frowning. The upper eyelid is supported by the *levator palpebræ*, and droops when that muscle is paralysed. On the other hand, paralysis of the orbicularis is attended by an inability to close the eyelids.

#### THE MUSCLES OF THE NOSE.

Under this head may be conveniently grouped not only the compressor naris and smaller muscles which act upon the nose alone, but also the pyramidalis nasi which acts on the forehead and the common elevator of the lip and wing of the nose.

The **pyramidalis nasi**, placed over the nasal bone, appears to be a prolongation of the inner part of the frontalis ; its fibres, however, decussate with those of the latter muscle, and are attached to the skin at the lower and mesial part of the forehead. It widens slightly as it descends, and terminates in a tendinous expansion common to it and the compressor naris.

The **compressor naris**, a thin triangular muscle, arises narrow and fleshy from the facial surface of the superior maxillary bone by the side of the anterior nasal aperture; proceeding forwards and inwards, it gradually expands into a thin aponeurosis, which is blended with that of the corresponding muscle of the opposite side, and with the pyramidalis nasi above, being closely attached to the skin of the nose, but only connected by loose areolar tissue to the subjacent cartilages. It is concealed at its origin by the muscle next described.

The **levator labii superioris alæque nasi**, the common elevator of the lip and nose, lies along the side of the nose, extending from the inner margin of the orbit to the upper lip. It arises by a pointed process from the nasal process of the superior maxillary bone, and, as it descends, separates into two fasciculi; one of these, much the smaller, is inserted into the wing of the nose, while the other is prolonged to the upper lip, where it is attached to the skin and becomes blended with the orbicularis and the special elevator muscle. It is subcutaneous, except at its origin, where the orbicularis palpebrarum overlaps it a little.

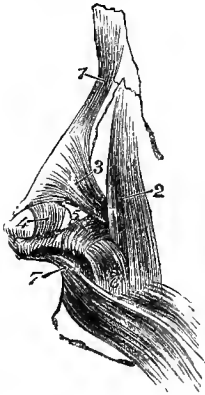


Fig. 268.—MUSCLES OF THE SIDE OF THE NOSE AND UPPER LIP.  
(Allen Thomson, after Arnold.)  $\frac{3}{4}$

1, pyramidalis nasi; 2, levator labii superioris alæque nasi; 3, compressor naris; 4, levator proprius alæ nasi anterior; 5, levator proprius alæ nasi posterior; 6, depressor alæ nasi; 7, septal origin of orbicularis oris.

The **depressor alæ nasi** is a small flat muscle which arises from the incisor fossa of the superior maxilla, and is inserted into the septum and posterior part of the ala of the nose. Some fibres are continued from the outer part of this muscle into the compressor naris.

Besides the muscles above described there are other irregular and often indistinct fibres which enlarge the orifice of the nose. Of these the following may be distinguished.

The **levator proprius alæ nasi posterior**, or **dilatator naris posterior**, is attached to the lateral margin of the nasal aperture and the smaller (quadrate) cartilages of the nose on the one hand, and to the skin on the other. Another set of fibres, the **levator proprius alæ nasi anterior**, or **dilatator naris anterior**, runs from the cartilage of the aperture of the nose to the skin at the margin of the nostril. The fibres of both of these muscles are very pale and often indistinct.

**Varieties.**—Absence of the pyramidalis has been observed. The compressor naris is sometimes very slightly developed, or even reduced to an aponeurotic condition. The dilators and depressor of the nostril are also subject to considerable variations in strength and in the mode of their attachment. The *musculus anomalus* of Albinus is a longitudinal muscular slip frequently present, lying beneath the common elevator of the lip and nose. It springs with the latter muscle from the nasal process of the superior maxilla, and ends below on the same bone in connection with the origin of the compressor naris.

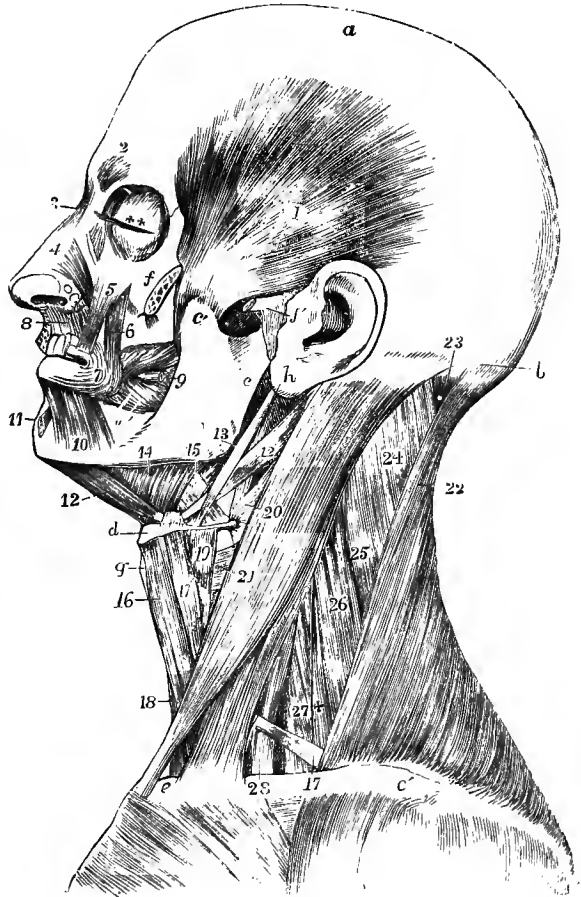
**Actions.**—The *pyramidalis nasi* muscle takes its fixed point from below and draws down the integument of the forehead, producing wrinkles across the root of the nose. The *compressor naris*, acting along with its fellow of the other side, depresses the cartilaginous part of the nose, and to some extent also compresses the alæ together. The actions of the other muscles are sufficiently indicated by their names; the dilatation of the alæ is seldom perceptible in natural inspiration, but is well-marked in dyspnoea.

## THE MUSCLES OF THE LIPS AND MOUTH.

Around the orifice of the mouth is situated the orbicularis muscle with concentric fibres, and this is joined by numerous other muscles which converge towards the aperture, viz., superiorly, the common elevator of the lip and nose already described, the proper elevator of the upper lip, the elevator of the angle of the mouth and the zygomatic muscles, laterally, the risorius and buccinator muscles,

Fig. 269.—DEEP MUSCLES OF THE LEFT SIDE OF THE HEAD AND NECK. (Allen Thomson, after Bourguery.)  $\frac{1}{3}$

*a*, vertex of head; *b*, superior curved line of occipital bone; *c*, ramus of lower jaw; *c'*, its coronoid process; *d*, hyoid bone; *e*, sternal end of clavicle; *e'*, acromial end; *f*, malar bone divided to show the insertion of the temporal muscle; *f'* divided zygoma, and external ligament of the jaw; *g*, thyroid cartilage; *h*, placed on the lobule of the auricle, points to the styloid process; 1, temporal muscle; 2, corrugator supercilii; 3, pyramidalis nasi; 4, compressor naris; 5, levator labii superioris; 6, levator anguli oris; 7, outer part of the orbicularis oris, the part below the nose has been removed; 8, depressor alæ nasi; 9, points to the buccinator muscle, through which the parotid duct is seen passing; 10, depressor labii inferioris; 11, levator menti; 12, 12, anterior and posterior bellies of the digastric; 13, stylo-hyoid muscle; 14, mylo-hyoid; 15, hyo-glossus, between which and 13, is seen a part of the stylo-glossus; 16, sterno-hyoid; 17, on the clavicle, indicates the posterior, and 17', the anterior belly of the omohyoid; 18, sterno-thyroid; 19, thyro-hyoid; 20, 21, on the sterno-mastoid muscle, point, the first to the middle, the second to the lower constrictor of the pharynx; 22, trapezius; 23, upper part of the complexus; 24, 25, splenius; 26, levator scapulæ; 27, middle scalenus; +, posterior scalenus; 28, anterior scalenus.



and inferiorly, the depressor of the angle of the mouth and that of the lower lip: and lastly, acting indirectly on the lower lip is the levator menti. The converging muscles will be first described, as the orbicularis is for the most part composed of fibres prolonged from them.

The **levator labii superioris proprius** muscle arises from the superior maxillary bone immediately above the infraorbital foramen, and from the adjoining surface of the malar bone; it passes downwards and a little inwards to be inserted into the skin of the upper lip.

**Relations.**—At its origin this muscle is overlapped by the orbicularis palpebrarum, but its greater part is subcutaneous; it partly conceals the levator anguli oris, and beneath it the

infraorbital vessels and nerve emerge from the canal of the same name. Its inner border is more or less united with the common elevator of the lip and nose.

The **levator anguli oris**, or **musculus caninus**, arises in the canine fossa immediately below the infraorbital foramen, and inclines downwards and slightly outwards to the angle of the mouth, where some of the fibres are inserted into the skin; but the greater number decussate with the depressor anguli oris, and are continued into the orbicularis muscle in the lower lip.

**Relations.**—At its origin this muscle is concealed by the proper elevator of the upper lip; its anterior surface supports the infraorbital nerve and artery, which separate it from the preceding muscle; the posterior surface lies on the superior maxilla and the buccinator muscle.

The **ZYGOMATICI** are two narrow and subcutaneous fasciculi of muscular fibres, extending obliquely from the most prominent part of the cheek towards the angle of the mouth, one being thicker and longer than the other.

The **zygomaticus minor**, a very small muscle, arises from the anterior and inferior part of the malar bone, and inclines downwards and forwards to terminate by joining the outer margin of the levator labii superioris.

The **zygomaticus major** arises from the malar bone near the zygomatic suture, and descends to the angle of the mouth, where it is mainly inserted into the skin, in small part also into the mucous membrane.

**Varieties.**—The zygomaticus minor is frequently absent; or it may fall short of the mouth, and be inserted into the fascia of the cheek. It may arise wholly or in part from the orbicularis palpebrarum; it has also been observed fused with the zygomaticus major, or the levator labii superioris, or even united to the outer fibres of the frontalis (Eustachius). It has frequently been found double.

The zygomaticus major has also been found double, or it may be double merely at its insertion. Sometimes it arises from the masseteric fascia below the zygoma. Absence of the muscle has also been observed.

The **risorius** (Santorini) consists of some very thin fasciculi, which commence in the fascia over the masseter, or on the parotid gland, and extending transversely inwards in the fat of the cheek, are inserted into the skin at the angle of the mouth.

**Varieties.**—The risorius is often absent. It has been seen to arise from the integument over the upper end of the sterno-mastoid, from the zygoma, from the external ear, and from the fascia over the mastoid process. It has also been found double and even triple.

The lower and lateral part of the face receives a superficial muscular covering from the facial part of the **platysma myoides**, which is incorporated with the muscles of the angle of the mouth and lower lip, and passes along with the superficial fascia over the base of the jaw into the cervical portion of the muscle; the anterior portion of the cervical platysma, on the other hand, though continuous externally with the facial, takes firm attachment to the base of the jaw for a length of two inches or more external to the symphysis.

The **buccinator** muscle consists of a flat and thin but strong set of fibres in contact with the mucous membrane, and forming a considerable part of the wall of the mouth. It is attached by its upper and lower margins to the outer surface of the alveolar parts of the maxillary bones, opposite the molar teeth, and by its posterior margin to the *pterygo-maxillary ligament*, a narrow band of tendinous fibres, which extends from the hamular process of the internal pterygoid plate to the mylohyoid ridge of the lower jaw close to the last molar tooth, and is placed between the buccinator muscle and the superior constrictor of the pharynx (fig. 280, p. 305). From these parts the fibres of the muscle are directed forwards, approaching each



other, so that the muscle is narrowed and proportionally thickened near the angle of the mouth, where it becomes incorporated with the orbicularis. The fibres near the middle of the muscle cross each other, those from above passing into the lower lip, and those from below into the upper one; but the higher and lower fibres are directed into the corresponding lip without decussation.

**Relations.**—The buccinator is covered and supported by a thin fascia, which is closely adherent to the muscular fibres, and is overlapped by the depressor anguli oris, by the upper fibres of the platysma myoides, and by the masseter and zygomaticus major, from which it is separated by a quantity of fat (see p. 293). Embedded in the last are the facial vessels and the buccal branches of the inferior maxillary and facial nerves. Opposite the second molar tooth of the upper jaw, its fibres give passage to the duct of the parotid gland.

The **depressor anguli oris**, or **triangularis menti** muscle, is broad at its origin from the external oblique line of the lower jaw; passing upwards it is collected into a narrower bundle, which ends in a similar way to the levator anguli oris, being partly inserted into the skin, and partly continued into the orbicularis in the upper lip.

**Relations.**—This muscle is covered only by the skin and fat; it conceals part of the buccinator and of the depressor of the lower lip.

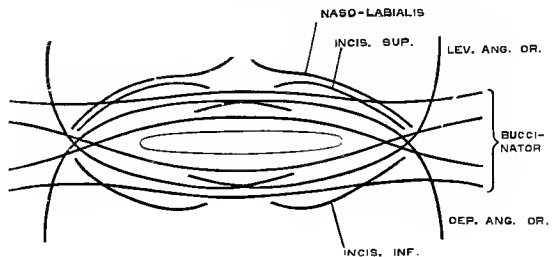
**Variety.**—The *transversus menti* is a small band of muscular fibres sometimes found arising from the inner border of the depressor, and curving downwards and inwards below the chin across the median line to the corresponding part of the opposite side.

At the corner of the mouth the decussating fibres of the elevator and depressor muscles, as well as of the buccinator, give rise to a dense mass of muscle which may be felt during life as a hard knot between the skin and mucous membrane a little external to the commissure of the lips.

The **depressor labii inferioris**, or **quadratus menti** muscle, arises from the lower jaw by a line of attachment extending from near the symphysis to a little beyond the mental foramen; thence it ascends with an inward inclination, unites with its fellow, and blending with the orbicularis oris is inserted into the lower lip. Its fibres are intermixed with much adipose matter.

The **levator labii inferioris**, or **levator menti** muscle, arises by a narrow head from the incisor fossa of the lower jaw, and expands as it is directed down-

Fig. 270.—SCHEME OF THE FORMATION OF THE ORBICULARIS ORIS MUSCLE. (G. D. T.)



wards and slightly forwards, between the depressors of the lower lip, to be inserted into the integument of the chin.

The **orbicularis oris** is an elliptical muscular sheet of considerable thickness, making the foundation of the lips, and composed for the most part of fibres prolonged from the buccinator and elevator and depressor muscles of the angle of the mouth. Its peripheral margin reaches above to the base of the nose, and below to the groove which separates the lip from the chin. The deeper fibres, together with a somewhat distinct marginal fasciculus beneath the red border of the lip, are continued from the buccinator, and cross from side to side without interruption. The fibres of the levator and depressor anguli oris, which have crossed at the corner of the mouth, enter the more superficial portion of the orbicularis, and are inserted into the skin of the

median portion of the lip, a few on the same side, but the greater number after crossing the middle line and decussating with their fellows: they do not reach the free border of the lip, but leave the marginal bundle of buccinator fibres uncovered. Besides these fibres, there are others which are attached to the cartilage and bone, viz., in the upper lip two slips, and in the lower lip one slip for each half. In the upper lip, the outer slip (*m. incisivus sup.*), thin and weak, springs from the incisor fossa of the superior maxilla; while the other (*m. naso-labialis*), thick and pointed, is fixed to the hinder part of the septum narium. In the lower lip the reinforcing fasciculus (*m. incisivus inf.*) arises from the incisor fossa of the inferior maxilla outside the levator menti. In both lips the

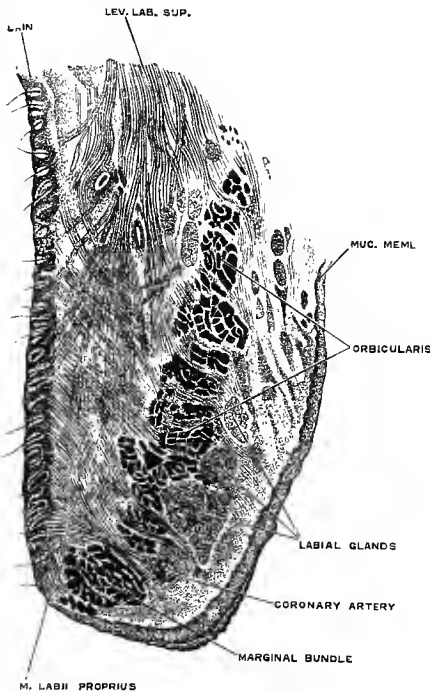


Fig. 271.—SAGITTAL SECTION OF UPPER LIP OF INFANT, A LITTLE TO ONE SIDE OF THE MEDIAN PLANE. (Aeby.)

slips are directed outwards towards the corner of the mouth, and there blend with the rest of the muscle. True orbicular fibres, passing from lip to lip, probably do not exist.

In front of, and to some extent interlacing with, the transverse fibres above described are the vertical fibres of the elevator and depressor muscles of the respective lips, passing to their insertion into the skin. There is also in the marginal portion of each lip a special set of fibres (*m. labii proprius*—Krause), more developed in the infant, passing obliquely from the skin to the mucous membrane between the transverse and vertical fibres. (W. Henke, *Zeitsch. f. Anat. u. Entw.*, i, 107; C. Aeby, *Arch. f. mikrosk. Anat.*, xvi, 651.)

**Relations.**—The skin of the lips is closely connected to the inner part of the orbicularis oris muscle, while over the outer part fatty tissue is interposed between them. The deep surface is in contact with the mucous membrane and the labial glands, as well as with the coronary arterial arch in each lip.

**Nerves.**—All the superficial muscles of the scalp and face previously described receive their motor fibres from the facial or seventh cranial nerve. It is probable, however, that the fibres which supply the frontalis and orbicularis palpebrarum muscles have their central origin from the oculo-motor nucleus, and not from that of the facial nerve (Mendel, *Neurolog. Centralblatt*, 1887, p. 537).

**Actions of the muscles of the lips.**—The *orbicularis oris* draws the lips together in both the vertical and transverse directions. Its deeper part, acting with the buccinators, closes the lips and presses them against the teeth. Its outer and superficial portion, continued from the muscles of the angle of the mouth, shortens the aperture, brings the lips together, and causes them to project forwards. The convergent muscles each draw their oral points of insertion in a direction corresponding to that of their muscular fibres. The *common elevator of the lip and nose* and the *depressor alæ nasi* act on the upper lip and the wing of the nose together—the one raising, the other depressing them. When the cheeks are distended with air, and the aperture of the lips narrowed, it is by the action of the *buccinator* that the forced expulsion of the air is regulated. The buccinator also flattens the cheek and keeps the food between the teeth during mastication. The *levator menti* draws upwards the integument of the chin and protrudes the lower lip. The muscles attached to the angles of the mouth are, along with others of the face, intimately connected with the expression of the passions: those which pass downwards not only raise the upper lip but also push upwards the cheek, and thus elevate the margin of the

lower eyelid, as in mirth; and those which ascend to the angle of the mouth depress that part, as in grief. (On the action of the facial muscles may be consulted C. Bell, "Anatomy and Philosophy of Expression;" Duchenne, "Mécanisme de la Physiologie humaine," Paris, 1862; and C. Darwin, "Expression of the Emotions in Man and Animals.")

#### THE MUSCLES OF THE ORBIT.

In this group will be described seven muscles, namely, the elevator of the upper eyelid before referred to, and six muscles of the eyeball, viz., the four straight and the two oblique muscles. Of these muscles, the inferior oblique alone is confined to the fore part of the orbit; all the others take their origin at its back part, and pass forwards to their insertion.

The **levator palpebræ superioris** is a slender muscle which arises, pointed and tendinous, above and in front of the optic foramen, from which it is separated by the origin of the superior rectus. Becoming broader as it passes forwards over the eyeball, it ends a little behind the supraorbital margin in a membranous expansion which is inserted chiefly into the fibrous tarsus of the upper eyelid.

From the membranous expansion of the levator a thin superficial layer is continued in front of the tarsus to be inserted into the skin of the lid, its fibrous bundles piercing the palpebral fascia and passing between the fasciculi of the palpebral portion of the orbicularis.<sup>1</sup> The layer inserted into the tarsus consists mainly of unstripped muscular fibres, and is attached along the upper edge of the fibrous plate. Some deeper tendinous fibres, joining an expansion from the sheath of the superior rectus, are attached to the conjunctiva. Lastly, the marginal part of the aponeurosis is prolonged on each side beyond the limit of the lid, and is attached to the wall of the orbit in conjunction with offsets from the sheaths of the recti; and internally a slip is fixed to the hinder part of the trochlea.

**Relations.**—Between this muscle and the roof of the orbit are situated the fourth and frontal nerves and the supraorbital vessels; beneath it are the inner half of the superior rectus and the globe of the eye. On entering the lid, it is placed behind the palpebral fascia, and its deep surface rests on the conjunctiva.

The four **STRAIGHT MUSCLES OF THE EYE** have a continuous tendinous origin at the bottom of the orbit, in the form of an oval ring which, commencing above, passes down on the inner side to the lower margin of the optic foramen, then stretches transversely across the inner part of the sphenoidal fissure to be attached to its lower border, where a prominent bony point is generally developed, and finally is completed by again crossing the sphenoidal fissure, this time about the middle and vertically to gain the upper edge of the optic foramen. In the upper and lower parts of this ring two stronger bands, or *common tendons*, are developed, which extend forwards on the ocular surface of the muscles, and from which most of the fleshy fibres spring. The upper is fixed to the inferior root of the small wing of the sphenoid, between the optic foramen and the sphenoidal fissure, and is prolonged anteriorly into the internal, superior, and external recti (Lockwood). The lower tendon, larger and more distinct than the upper, arises from the body of the sphenoid at the inner end of the sphenoidal fissure, and divides into three slips for the internal, inferior, and external recti (Zinn). The **superior rectus** arises above or in front of the optic foramen, and beneath the levator palpebræ; the **internal rectus** has a wide origin on the inner side of and below the optic foramen; the **inferior rectus** springs mainly from the middle slip of the lower common tendon; and the **external rectus** differs from the others in having two heads of origin, the inferior and larger of which springs from the outer slip of the lower common tendon and the spine on the lower border of the sphenoidal fissure, while the superior is formed by the outer part of the upper common tendon; be-

<sup>1</sup> F. Merkel, "Handbuch der topographischen Anatomie," i, 199.

tween these two origins muscular fibres also spring from a tendinous arch joining the heads over the fissure. The four recti, thus attached posteriorly, pass forwards, one above, one below, and one on each side of the eyeball, becoming flattened as they lie in contact with it, and are inserted by short membranous and slightly expanded tendons into the fore part of the sclerotic coat, at a distance of from three to four lines from the margin of the cornea.

The external and inferior recti exceed the other two in length. On the other hand, the internal rectus is the broadest and strongest, and the superior the smallest and narrowest of all. At their insertions the internal is nearest to, and the superior is farthest from the edge of the cornea<sup>1</sup>: the internal has the longest, and the external the shortest tendon. Between the heads of the external rectus is a narrow interval which gives passage to the third and sixth nerves and the nasal branch of the fifth nerve, with the ophthalmic veins.

The **superior oblique** or **trochlearis** is a narrow elongated muscle, placed at the upper and inner part of the orbit, internally to the levator palpebræ. It arises

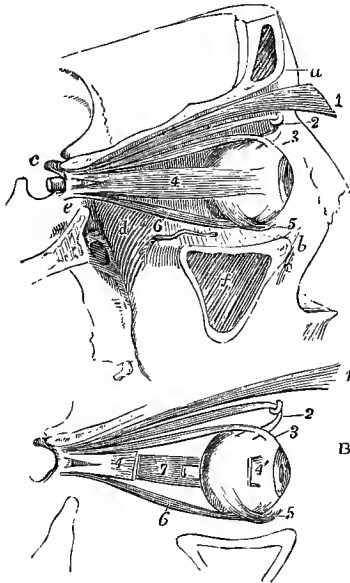


Fig. 272.—A, VIEW OF THE MUSCLES OF THE RIGHT ORBIT, FROM THE OUTSIDE, THE OUTER WALL HAVING BEEN REMOVED. (Allen Thomson.)  $\frac{1}{2}$

B, EXPLANATORY SKETCH OF THE SAME MUSCLES.

*a*, orbital arch; *b*, lower margin of the orbit; *c*, anterior clinoid process; *d*, posterior part of the floor of the orbit above the spheno-maxillary fossa; *e*, side of the body of the sphenoid bone below the optic foramen and sphenoidal fissure; *f*, maxillary sinus; 1, levator palpebræ superioris; 2, pulley and tendon of the superior oblique muscle; 3, tendon of the superior rectus muscle at its insertion upon the eyeball; 4, external rectus; 4', in B, tendon of insertion of the same muscle, a large part of which has been removed; 5, inferior oblique muscle crossing the eyeball below the inferior rectus; 6, inferior rectus; 7, in B, the internal rectus, and near it, the end of the optic nerve cut short close to the place of its entrance into the eyeball.

about a line in front of the inner part of the optic foramen; thence it proceeds towards the front of the orbit, and terminates in a round tendon which passes through a fibro-cartilaginous ring or pulley (trochlea) attached to the trochlear fossa of the frontal bone; it is there reflected outwards, backwards and downwards, and passes between the eye and the superior rectus to be inserted into the sclerotic coat beneath the outer edge of that muscle, and midway between the cornea and the entrance of the optic nerve.

**Relations.**—This muscle is in contact with the roof of the orbit, the fourth nerve entering its upper surface; and beneath it lie the nasal nerve, the ophthalmic artery, and the internal rectus muscle. The pulley is lined by a synovial sheath, and from its outer border an investment of firm connective tissue is prolonged on the tendon as far as the eyeball.

The **inferior oblique** arises from a minute depression in the orbital plate of the superior maxillary bone, just within the anterior margin of the orbit, and close outside the orifice of the nasal duct. The muscle inclines outwards, backwards and upwards, passing between the inferior rectus and the floor of the orbit, and ends in a tendinous expansion which is inserted, under cover of the external rectus, into the eyeball at its posterior and outer part, and nearer to the optic nerve than the superior oblique.

<sup>1</sup> On the precise mode of insertion of the eye-muscles see E. Fuchs, "Beiträge zur normalen Anatomie des Augapfels," Arch. f. Ophthalmologie, xxx, 1884.

**Varieties.**—The levator palpebræ sometimes gives off a distinct muscular slip from its inner border to the trochlea, forming the *tensor trochleæ* of Budge. Absence of the levator palpebræ has been observed.

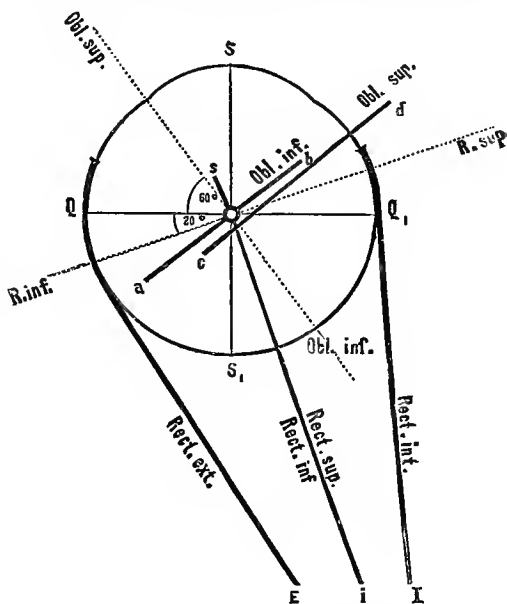
The muscles of the eye seldom vary. The external rectus has been seen :—with its two heads separate to their insertion, thus forming a double muscle; and giving slips to the outer wall of the orbit and the lower eyelid. Rex has described under the name of *obliquus inferior accessorius* a muscular slip passing from the inferior rectus to the inferior oblique.

The *transversus orbitæ* (Bochdalek) is an arched slip of muscular fibres passing from the orbital plate of the ethmoid across the upper surface of the eyeball to the outer wall of the orbit.

**Nerves.**—Five of the muscles of the orbit, viz., levator palpebræ superioris, the superior, internal and inferior recti, and the inferior oblique, are under the influence of the third or

Fig. 273.—DIAGRAM SHOWING THE ACTIONS OF THE OCULAR MUSCLES. (Landois.)

S, S 1, sagittal axis of the eyeball (visual axis); Q, Q 1, transverse axis of the eyeball; the directions of traction of the several muscles are indicated by the thick lines; the dotted lines R. inf., R. sup., and Obl. sup., Obl. inf., represent the axes about which the superior and inferior recti and obliqui muscles respectively move the eyeball; the axis of rotation of the internal and external recti is perpendicular to the plane of the paper, and identical with the vertical axis of the eyeball, O.



common oculomotor nerve; the external rectus is supplied by the sixth or abducent ocular, and the superior oblique by the fourth or trochlear nerve.

**Actions.**—The *levator palpebræ superioris* is simply an elevator of the upper eyelid, acting as the antagonist of the upper palpebral part of the orbicularis muscle.

The eyeball is so situated in the structures which surround it in the orbit that it is capable of free motion on a central fixed point; but it does not appear to shift its place as a whole within the orbit, at least to any extent, nor to undergo perceptible change of form from the action of the muscles. The position of the point round which the movements of the eyeball take place is nearly in the centre of curvature of the posterior wall, and from half a line to a line behind the middle of the antero-posterior axis of the eyeball.

The movements of the eyeball may be conveniently reduced to four kinds, viz., 1, simple lateral movements in a horizontal plane; 2, simple movements of elevation or depression; 3, oblique movements of elevation or depression; and 4, movements of rotation about a sagittal axis. In the first two kinds the vertical meridian of the eye is not subject to any change of inclination; in the third kind the movements of direction are accompanied by a small amount of inclination of the vertical meridian to one or other side; and in the fourth kind, when simple, the whole movement is one of inclination of the vertical meridian. These movements, however, unless perhaps the first, are seldom simple, but more frequently different kinds are combined together. The first three kinds constitute the various movements of direction by which the visual axis is turned within certain limits to various points in space, the extent of motion from the primary position (with the visual axis horizontal and parallel to the median plane) being about  $42^\circ$  outwards,  $45^\circ$  inwards,  $34^\circ$  upwards, and  $57^\circ$  downwards. Simple movements of rotation do not appear to occur to any considerable extent, and it has been ascertained by experiment that they are not sufficient, as has been supposed, to maintain the eyeballs in a fixed position during inclined movements of the head.

In these different movements the six muscles of the eyeball may be considered as acting in three pairs. 1st. In the horizontal movements the *internal* and *external recti* muscles are the sole agents, the one acting as an adductor and the other as an abductor; and this movement

they effect without any rotation, their line of action being almost exactly in the horizontal plane of the eyeball. 2nd. It is different with the *superior* and *inferior recti*; for while these muscles undoubtedly are respectively the most direct elevators and depressors of the cornea, they have both a tendency, from the line of their action being to the inner side of the centre of motion of the eyeball, to produce inward direction with a small amount of rotation. This tendency is corrected by the association of the *oblique* muscles in upward and downward movements; the inferior oblique being associated with the superior, and the superior oblique with the inferior rectus muscle. The simple action of the superior oblique muscle, when the eye is in the primary position, is to produce a movement of the cornea downwards and outwards, that of the inferior oblique to direct the cornea upwards and outwards, and in both with a certain amount of rotation, though in different directions in the two cases. But these movements caused by the oblique muscles are precisely those which are required to neutralise the inward direction and rotatory movements produced by the superior and inferior recti, and accordingly, by the combined action of the superior rectus and the inferior oblique muscles a straight upward movement is effected, while a similar effect in the downward direction results from the combined action of the inferior rectus and superior oblique muscles.

It has been farther shown that in all the oblique movements of direction a combination takes place of the action of the oblique with that of the straight muscles. Here, however, two recti muscles are in action and are associated with one oblique muscle, as, for example, in the upward and inward direction, the superior and internal recti with the inferior oblique, and in the downward and inward direction the inferior and internal recti with the superior oblique. And the same is true of the upward and outward and downward and outward movements of direction, for in all these movements the action of the oblique muscles is necessary to control or supplement the rotatory tendency of the recti muscles.

It is also obvious that the effect of the contraction of each muscle will vary according to the position of the eyeball. Thus, if the eye be abducted, so that the transverse axis of the ball coincides with the axis of movement of the superior and inferior recti, these muscles will simply elevate or depress the cornea without rotation; whereas if the eye be adducted the rotatory tendency of the same muscles is increased, and requires a stronger effort on the part of the associated obliqui for its correction; and in extreme adduction the eyeball is elevated and depressed mainly by the inferior and superior oblique muscles, which have in great measure lost their rotatory action.

The ocular movements are always bilateral; but while in the upward and downward movements both eyes are always turned in the same direction, in the lateral movements the two eyes may either be directed to the same side, the one being abducted and the other adducted, or they may both be adducted so as to bring about the convergence of the visual axes necessary for near vision.

(For fuller information as to the movements of the eyes the reader is referred to treatises on Physiology, as well as to the following special works:—Donders, "On the Anomalies of Accommodation," &c., Syd. Soc., 1864; Helmholtz, Proc. Roy. Soc., xiii, 186) and "Physiological Optics," and Hering in Hermann's "Handbuch der Physiologie," Bd. iii.)

**Fasciæ of the orbit.**—The space within the orbit which is not occupied by the eyeball and its muscles, or other parts belonging to it, is completely filled with soft fat and delicate yielding connective tissue. In various places this last is condensed into layers of slender fascia of various degrees of strength, the principal of which is that known as the *fascia* or *capsule of Tenon*, a thin membrane surrounding the greater part of the eyeball, and forming the wall of a socket in which the globe plays. The fascia is perforated behind by the optic nerve and the ciliary vessels and nerves, there becoming continuous with the connective tissue investing those structures, and in front it extends nearly as far as the cornea, where it ends by being attached to the ocular conjunctiva. Its inner surface is connected to the sclerotic coat of the eye only by delicate bundles of yielding connective tissue, the two being separated for the most part by an extensive lymph-space, so that it seems to serve all the purposes of a synovial membrane in the movements of the globe. The fascia is also pierced by the muscles of the eyeball near their insertions, and it sends a tubular prolongation on each of these, which speedily degenerates, however, into a simple areolar investment, except in the case of the sheath on the tendon of the superior oblique, which is stronger than the others and is continued as far as the pulley. The sheaths of the recti adhere closely to the muscular substance, and from their outer part expansions are given off to the margin of the orbit, which serve to limit the degree of contraction of the muscles. The processes from the sheaths of the inner and outer recti are stronger than the other two, especially the external, which is attached to the malar bone and external tarsal ligament. The inner expansion is similarly fixed to the crest of the lachrymal bone and the reflected portion of the internal tarsal ligament. The offset from the sheath of the superior rectus is connected with the tendon of the levator palpebræ (p. 289), and from that of the inferior rectus fibres are continued forwards into the lower tarsal plate; these muscles are thus enabled to exercise an influence upon the eyelids. Lockwood describes under the name of the *suspensory ligament of the eye* a boat-shaped thickening of the lower part of the capsule, which is attached at each

end to the orbital margin in common with the lateral expansions, and serves to support the eyeball in its socket. (Sappey, "Traité d'Anatom. descrip.," t. ii; v. Gerlach, "Beiträge zur norm. Anat. des menschl. Auges," Leipzig, 1880; C. B. Lockwood, Journ. Anat., xx, 1885; Merkel, "Handb. d. topog. Anat.," Bd. i, 300.)

Certain collections of involuntary muscular fibres that are contained in the eyelids and wall of the orbit will be noticed in connection with the anatomy of the eye in Vol. III.

#### THE MUSCLES OF MASTICATION.

The masseter, temporal, and two pterygoid muscles form a group of muscles of mastication, which may be properly considered together.

The **masseteric fascia** is a continuation upwards of the deep fascia of the neck over the masseter muscle. It is firmly bound down to the outer surface of the muscle, and is attached above to the zygoma. Farther back the fascia invests closely the parotid gland (*parotid fascia*), on the posterior and deep surfaces of which a process is also sent upwards; a strong band of this process, the *stylo-maxillary ligament*, extending from the angle of the jaw to the styloid process, separates the parotid and submaxillary glands.

The **masseter** (fig. 267, 13) is a thick quadrate muscle, the fibres of which form two portions differing in size and direction. The *superficial* part, obliquely four-sided in form, arises from the lower border of the zygomatic arch for the anterior two-thirds, chiefly by thick tendinous bundles projecting down between the muscular fasciculi, to which they afford an extensive surface of origin: its fibres proceed downwards and backwards to be inserted into the lower half of the ramus of the jaw, extending as far as the angle. The *deep* part of the muscle, of a triangular form, consists of fibres which are shorter than those of the superficial part, and are directed nearly vertically downwards. They arise from the posterior third of the lower border and from all the deep surface of the zygomatic arch, and, becoming united with the superficial part, are inserted into the upper half of the ramus of the jaw, including the coronoid process: only the upper and back part of this portion of the muscle is left uncovered by the superficial portion.

**Relations.**—The external surface of the masseter muscle is covered for the most part only by the skin and fascia, together with, in the lower half, the platysma myoides; it is, however, overlapped behind by the parotid gland, and crossed by its duct; some branches of the facial nerve and the transverse facial artery also rest upon it. The fore part of its inner surface overhangs the buccinator; the greater part is in close contact with the ramus of the jaw, and covers a nerve and vessels which enter it through the sigmoid notch of that bone.

**Buccal fat-pad.**—Occupying the interval between the fore part of the masseter and the buccinator is a definitely circumscribed mass of fat, which extends outwards around the anterior border of the masseter, and behind is prolonged into the zygomatic fossa between the lower part of the temporal and the pterygoid muscles. It is especially well developed in the infant, and has thence received the inappropriate name of the sucking-pad.<sup>1</sup> In front of this the buccinator is covered by the looser subcutaneous fat, in which the parotid duct and the vessels and nerves of the cheek are embedded.

The **temporal fascia** is a dense white shining aponeurosis, which covers the temporal muscle above the zygoma, and gives attachment to some of its fibres of origin. It is attached above to the temporal crest of the frontal bone and to the lower of the two lines on the parietal bone; while below, it is divided into two layers which are separated by a small quantity of fat, and are attached respectively to the inner and outer surfaces of the zygomatic arch close to its upper border. This dense fascia is separated from the integuments by the layer of thin membrane descending from the epicranial aponeurosis, and by the superior and

<sup>1</sup> Ranke, "Ein Saugpolster in der menschlichen Backe," Virchow's Archiv, xcvi, 1884.

anterior auricular muscles ; and from the temporal muscle, at the lower part, by a layer of fat.

The **temporal** muscle (fig. 269, 1) is fan-shaped, and arises from the whole surface of the temporal fossa, with the exception of the anterior or malar wall, and from the deep surface of the temporal fascia, except close to the zygomatic arch : some of its posterior fibres arising from this fascia blend with the deep fibres of the masseter muscle. The direction of the anterior fibres is nearly vertical, that of the middle fibres oblique, and that of the posterior fibres at first almost horizontal. The fibres converge as they descend, and terminate mostly in a tendon, which is implanted into the upper and anterior borders of the coronoid process of the lower jaw, while the deeper fibres have a fleshy insertion into the inner side of the process, reaching down to the union of the ramus and body of the jaw.

**Relations.**—The upper part of the muscle is closely covered by the temporal fascia ; the lower and anterior part is embedded in fat continuous with that which lies between the

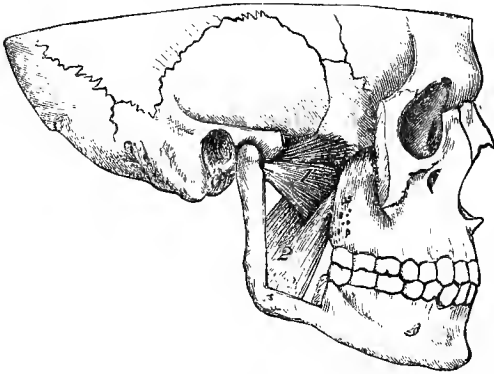


Fig. 274.—THE PTERYGOID MUSCLES FROM OUTSIDE. (G. D. T.)  $\frac{1}{2}$

The masseter muscle, the greater portion of the zygomatic arch, the temporal muscle with the coronoid process, and a large part of the ramus of the jaw have been removed. 1, external pterygoid ; the figure is placed on the lower head ; 2, internal pterygoid.

masseter and buccinator muscles. Between the muscle and the bone of the temporal fossa are the deep temporal arteries and nerves, which penetrate its substance. In contact with the deep surface of the muscle near its insertion the buccal nerve

descends, and at the posterior border of the insertion the masseteric nerve and artery emerge.

The **internal pterygoid** muscle arises from the pterygoid fossa, its fibres, tendinous and fleshy, being attached mostly to the inner surface of the external pterygoid plate and to that portion of the tuberosity of the palate bone which is situated between the pterygoid plates, and by a second smaller slip, tying outside the external pterygoid muscle, from the outer surface of the tuberosities of the palate and superior maxillary bones. Thence it is directed downwards, with an inclination backwards and outwards, and is inserted into the rough mark on the inner side of the ramus of the lower jaw between the angle and the dental foramen.

**Relations.**—The internal pterygoid muscle is placed on the inner side of the ramus of the jaw, somewhat in the same manner as the masseter lies on the outer side. Between the external surface of the muscle and the ramus of the mandible are the internal lateral ligament, the internal maxillary vessels with their inferior dental branches, and the inferior dental and lingual nerves ; and at its upper part the larger head is crossed by the external pterygoid muscle. Its inner surface is in contact with the tensor palati muscle, with the superior constrictor of the pharynx, and with the ascending palatine artery.

The **external pterygoid** muscle, occupying the zygomatic fossa, arises by two fleshy heads placed close together, the superior of which is attached to the zygomatic surface of the great wing of the sphenoid, and to the infratemporal crest which separates that surface from the temporal fossa ; while the inferior, which is larger, is attached to the outer surface of the external pterygoid plate. The fibres from



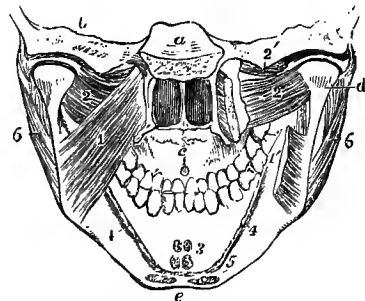
both heads pass backwards and outwards, and converge to be inserted into the depression on the front of the neck of the lower jaw, and into the interarticular fibro-cartilage of the temporo-maxillary articulation.

**Relations.**—The internal maxillary artery is usually placed on the outer surface of this muscle, passing thence between the heads of origin; while the buccal nerve issues from between those heads. The deep surface rests against the upper part of the internal pterygoid muscle, the direction of which it crosses, also the internal lateral ligament of the lower jaw, the inferior maxillary nerve, and the middle meningeal vessels. The upper border is crossed by the deep temporal and masseteric nerves.

**Varieties.**—The *pterygoideus proprius* is a nearly vertical band of muscular and tendinous fibres, sometimes entirely tendinous, passing from the infratemporal crest of the great wing of the sphenoid, over the surface of the external pterygoid muscle, to the lower part of the outer pterygoid plate, or to the tuberosity of the palate or superior maxillary bone. It has been seen sending a slip to the pterygo-maxillary ligament, or even to the lower jaw.

*Pterygo-spinosus.*—This is a muscular slip occasionally seen, springing from the spine of the sphenoid, or the adjoining part of the vaginal process, and inserted into the hinder margin of the outer pterygoid plate, between the external and internal pterygoid muscles. A fibrous band connecting these parts (*pterygo-spinosus ligament*) is frequently

Fig. 275.—VIEW OF THE LOWER PART OF THE SKULL AND FACE, FROM BEHIND, TO SHOW THE ATTACHMENTS OF THE PTERYGOID AND SOME OTHER MUSCLES. (Allen Thomson, after Bourguery.)  $\frac{1}{2}$



*a*, body of the sphenoid, below which are seen the posterior nares; *b*, section through the temporal bone; *c*, hard palate; *d*, back of the head and neck of the lower jaw, above which are seen the synovial cavities of the joint separated by the interarticular fibro-cartilage; *e*, placed below the symphysis menti; 1, on the left internal pterygoid muscle; 1', on the right side, the lower part of the same muscle, the middle portion of which has been removed to show the external pterygoid; 2, the lower head of the external pterygoid; 2', on the right side, points to the upper head of the muscle, attached in part to the interarticular disc; 3, origins of the genio-hyoid and genio-glossus muscles from the mental spines; 4, origin of the mylo-hyoid; 5, attachment of the anterior belly of the digastric; 6, 6, masseter muscles.

present, and is sometimes converted into bone (*cf.* p. 47). (J. Poland, "Variations of the External Pterygoid Muscle," *Journ. Anat.*, xxiv.)

**Nerves.**—The four muscles above described receive their nerves from the muscular branches of the inferior maxillary, which may be traced to the small or motor root of the fifth nerve.

**Actions.**—The masseter, temporal and internal pterygoid muscles are elevators of the lower jaw, and generally act in concert, bringing the lower teeth forcibly into contact with the upper. The opposite movement of depressing the jaw, not being opposed by any resisting obstacle, requires less force, and is effected by muscles of much smaller size, the principal of which is the digastric muscle hereafter described. The external pterygoid muscle draws forwards the condyle of the jaw, and, when the muscles of both sides act together, the lower jaw is protruded so as to make the lower incisor teeth project beyond the upper; but their more usual mode of action is alternately on the two sides, as in the grinding movement of the molar teeth, in which the horizontal movements of the external pterygoids are associated with the elevating actions of the other muscles. The external pterygoids also act in opening the mouth, when the condyles are carried forwards onto the articular eminences. The hinder portion of the temporal muscle retracts the jaw, and is thus the antagonist of the external pterygoid: in this action the depressor muscles also assist.

#### SUBCUTANEOUS MUSCLE OF THE NECK.

The *platysma myoides* (fig. 266, 14) is a pale-coloured thin sheet of muscular fibres, superficial to the deep cervical fascia, and extending over the front and side of the neck and lower portion of the side of the face. Its fibres arise by thin bands

from the skin and subcutaneous tissue over the upper part of the deltoid, pectoral, and trapezius muscles; thence they proceed upwards and inwards over the clavicle and the side of the neck, gradually converging and approaching the muscle of the opposite side. The greater number of the fibres are inserted into the outer surface of the lower jaw from the mental protuberance to the attachment of the masseter; some of the inner fibres mingle with those of the opposite platysma in front of the symphysis, and the innermost fibres of all cross from the one side to the other below the chin, those of the right side being generally superficial, and are attached to the lower border of the jaw opposite the mental protuberance; the posterior fibres are prolonged upon the side of the face as far as the angle of the mouth, blending with the depressor anguli oris and orbicularis muscles.

**Varieties, &c.**—The muscular fibres of the platysma sometimes extend upwards on the face and downwards on the neck, shoulder and breast farther than usual; and they occasionally take attachment to the clavicle. The upper part of the muscle is occasionally joined by a slip from the mastoid process, or from the occipital bone, and the frequently occurring muscular fasciculus known as the *occipitalis minor*, springing from the fascia over the upper end of the trapezius, and ending similarly over the insertion of the sterno-mastoid, is probably a less developed form of this accessory slip of the platysma. Suppression of the whole platysma on one or both sides is recorded by Macalister, and of the lower half by Gegenhaur. This muscle is the representative in man of a subcutaneous sheet of muscle, the *panniculus carnosus*, largely developed in most mammals, by which very varied movements of the skin and some superficial parts may be effected, as, for example, when the horse communicates a rapid motion to the skin to free itself from insects, or the dog shakes off the water after swimming, or the hedgehog elevates its spines.

**Nerves.**—The platysma receives its principal motor nerves from the inframaxillary branch of the facial, but as this unites with the superficial cervical nerve it may also be influenced through some of the spinal nerves.

**Action.**—The platysma raises the skin of the breast and shoulder and draws the angle of the mouth forcibly downwards and outwards; at the same time it carries the skin of the neck forwards, reducing the angle between the chin and neck. The muscle is put into action in swallowing, and is also called into play in expressing sudden terror.

#### THE MUSCLES AND FASCIÆ OF THE NECK ANTERIORLY.

**FASCIÆ.**—The **deep cervical fascia** passes forwards from the upper border of the trapezius muscle over the side and front of the neck beneath the platysma myoides. Posteriorly it is continuous with the layers of connective tissue by which the trapezius and deeper muscles are invested: it then extends over the posterior triangle of the neck, viz., the space bounded by the trapezius and sterno-mastoid muscles and the clavicle: at the posterior border of the sterno-mastoid it divides into two layers, which form an investment for that muscle; these unite again at the anterior border into a membrane which passes forwards to the middle line, where it becomes continuous with the fascia of the opposite side, and covers the area bounded by the middle line, the border of the jaw, and the sterno-mastoid muscle, and called the anterior triangle. In the posterior triangle the fascia is attached below to the clavicle, and near that bone is perforated by the external jugular vein, which in the previous part of its course lies on the surface of the membrane. In the anterior triangle it is bound above to the base of the jaw in front, and farther back is continued superficially over the parotid gland (*parotid fascia*) to the zygoma, sending upwards also a deep process between the sub-maxillary and parotid glands, in which the stylo-maxillary ligament (p. 163) is developed.

In front the fascia is attached to the hyoid bone, and becoming stronger as it descends, it splits, a little below the level of the thyroid body, into two distinct layers. Of these the more superficial and weaker, running along the sterno-mastoid muscles, is fixed to the anterior surface of the sternum; while the

stronger layer, lying under the former, and closely covering the sterno-hyoid and sterno-thyroid muscles, is attached to the interclavicular ligament and the deep surface of that bone. Between these layers, at the upper border of the sternum, is a small interval (*suprasternal space*), which extends also a short distance on each side above the clavicle and behind the sternal head of the sterno-mastoid (*supraclavicular recess*). This space contains some loose connective tissue and fat, the communicating branch between the two anterior jugular veins, and sometimes

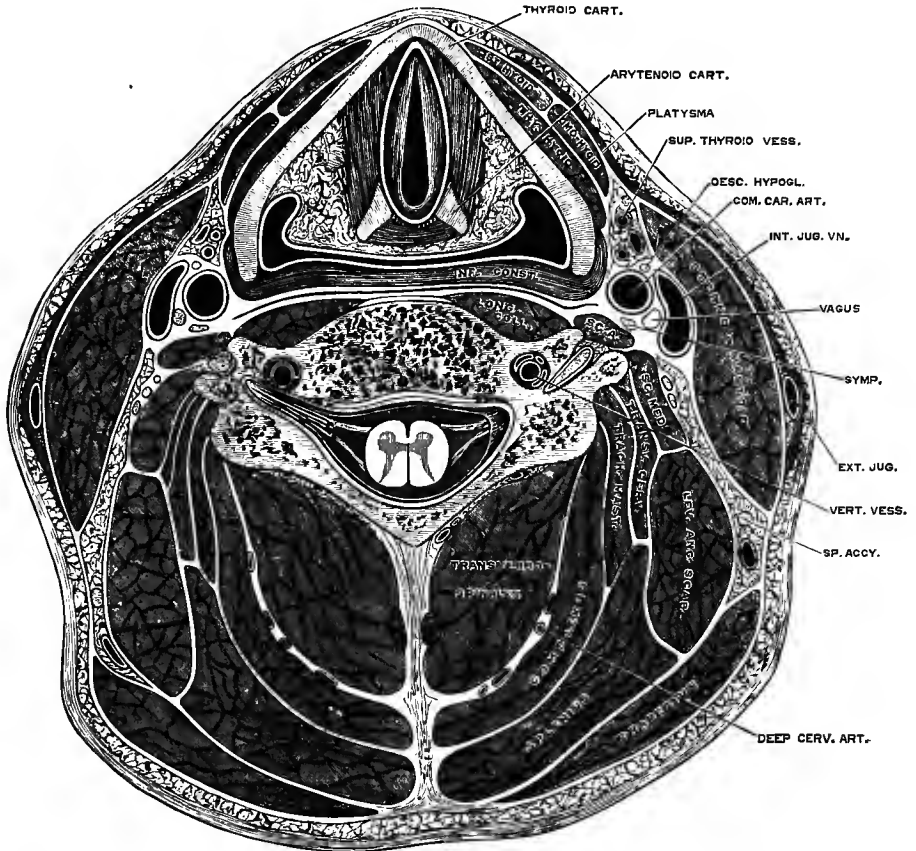


Fig. 276.—TRANSVERSE SECTION OF THE NECK THROUGH THE FIFTH CERVICAL VERTEBRA, REPRESENTING SEMIDIAGRAMMATICALLY THE ARRANGEMENT OF THE CERVICAL FASCIA. (After Braune and from nature.) (G. D. T.)

The section passes through the upper part of the larynx, a little above the rima glottidis. The fascial planes are indicated by white lines, but it is to be observed that these are in many places not definite membranes, but merely layers of more or less dense connective tissue.

a small lymphatic gland; and in the lateral recess the anterior jugular vein is directed outwards.

Prolonged from the deeper of these two layers, a fascia is found in the posterior triangle, investing the posterior belly of the omo-hyoid muscle, and binding it down to the clavicle and first rib, where this structure is connected with the costo-coracoid membrane. Still deeper in the anterior triangle a process of the fascia passes behind the depressor muscles of the hyoid bone, investing the thyroid body,

and extending thence on the trachea and large vessels at the root of the neck down to the fibrous layer of the pericardium.

Continuous with the deep processes of the cervical fascia is the *carotid sheath*, an envelope of fascia enclosing the carotid artery and jugular vein with the pneumogastric nerve. A thin fibrous septum intervenes between the artery and vein, thus completing a separate sheath for each.

Deepest of all is the *prevertebral fascia*, a layer descending on the prevertebral muscles, and forming the hinder wall of what may be termed the *visceral compartment* of the neck, which lodges the pharynx and œsophagus, the larynx and trachea, with the thyroid body. Covering the back of the pharynx there is a proper fascial layer (p. 306), adhering closely to the constrictor muscles, but connected behind to the prevertebral fascia only by very loose areolar tissue, the meshes of which are readily distended by fluid, thus giving rise to the so-called *retro-pharyngeal space*. This space is bounded laterally by the union of the pharyngeal and prevertebral fasciæ, both of which join the inner side of the carotid sheath, while inferiorly the loose tissue is continued without interruption along the œsophagus into the thorax, so that the artificial cavity may be extended downwards into the posterior mediastinum. Lastly, from the back of the carotid sheath a layer, which may be looked upon as the prolongation of the prevertebral fascia, extends outwards and downwards over the scaleni muscles, the brachial plexus of nerves, and the subclavian vessels, which it accompanies into the upper part of the axilla, thus giving rise to the *axillary sheath*. Between this layer and the more superficial layer roofing over the lower part of the posterior triangle is an interval in which are contained the posterior belly of the omo-hyoid with its fascia of attachment, the transverse cervical and suprascapular vessels, the inferior deep cervical lymphatic glands, and fat.

**MUSCLES.**—Immediately beneath the fascia is a large oblique muscle, extending the whole length of the neck, and named from its attachments the sterno-cleido-mastoid. At a deeper level than this are two sets of muscles situated respectively above and below the hyoid bone. The muscles of the upper set are known as the suprahyoid muscles or elevators of the hyoid bone; those of the lower set are the infrahyoid muscles or depressors of the hyoid bone.

The **sterno-cleido-mastoid** or **sterno-mastoid** muscle is attached inferiorly in two parts to the anterior surface of the manubrium and to the inner third of the clavicle on its upper aspect. The sternal head is thick and rounded, tendinous in front and fleshy behind. The clavicular portion, separated from the sternal by a variable interval, is flat, and is composed of fleshy and tendinous fibres. The two portions meet and form a thick prominent muscle, which, extending upwards, outwards and backwards, is inserted superiorly by short tendinous fibres into the anterior border and external surface of the mastoid process, as well as into a rough ridge continued backwards therefrom, and by a thin aponeurosis into the outer half or more of the superior curved line of the occipital bone. The sterno-mastoid muscle divides the quadrilateral space on the side of the neck into two great triangles.

**Relations.**—This muscle is covered for more than the middle three-fifths of its extent by the platysma. It is also crossed by the external jugular vein, and by the great auricular and superficial cervical nerves. It rests below on part of the sterno-hyoid and sterno-thyroid muscles, and crosses the omo-hyoid; in the middle part of the neck it covers the cervical plexus, the great cervical vessels, and parts of the levator anguli scapulæ and scaleni muscles, and in the upper part, the splenius and digastric muscles. It is pierced by the spinal accessory nerve.

**Varieties, &c.**—This muscle consists of two chief parts, *sterno-mastoid* and *cleido-mastoid*, which are sometimes described as separate muscles. The cleido-mastoid, the smaller of the two, runs upwards nearly vertically under the sterno-mastoid, and is inserted separately by a rounded tendon into the tip of the mastoid process; this part is pierced by the spinal accessory

nerve. In most cases a third factor is added, the *cleido-occipital*, which arises from the clavicle in front of or outside the cleido-mastoid and applies itself to the hinder border of the sterno-mastoid, being inserted in continuation thereof along the superior curved line. The clavicular origin of the muscle varies greatly in width, being sometimes as narrow as the sternal, while in other instances it extends for three inches along the bone; in such cases it may be divided into separate slips. In animals without a clavicle the cleido-mastoid is continued into the clavicular part of the great pectoral muscle or deltoid, thus forming a cephalo-humeral muscle.

The *transversus nuchæ* is a fasciculus of frequent occurrence springing from the external occipital protuberance in connection with the upper end of the trapezius, and inserted into the aponeurosis of the sterno-mastoid. When absent, tendinous fibres often run in its place.

The *supraclavicularis* (Luschka) is a small muscle not unfrequently met with, lying behind the origin of the sterno-mastoid. It arises by a slender tendon from the upper border of the manubrium, passes upwards and outwards above the sterno-clavicular articulation, and is inserted into the upper surface of the clavicle. When present on both sides the two muscles may be joined in the middle line.

The *supraclavicularis proprius* (Gruber) is attached to the clavicle at each end, forming an arch above the middle of the bone. It has also been seen ending in the fascia over the adjacent part of the trapezius.

**Nerves.**—The sterno-mastoid receives its principal nervous supply from the spinal accessory, the offsets of which to the muscle are joined by a branch of the second cervical nerve.

#### THE INFRAHYOID MUSCLES.

The **sterno-hyoid** muscle, a flat band of longitudinal fibres, arises variably, from the back of the sternum and the posterior sterno-clavicular ligament, from that ligament and the clavicle, or from the clavicle only, and sometimes, to a small extent, from the cartilage of the first rib. It is inserted by short tendinous fibres into the lower border of the body of the hyoid bone for the inner half.

**Relations.**—The muscle is concealed below by the sternum and the sterno-mastoid muscle, higher up by the skin and fascia only; it lies on the sterno-thyroid and thyro-hyoid muscles, which it partly covers. The inner border approaches that of the corresponding muscle towards the middle of its extent, but is separated from it by a slight interval superiorly, and by a larger interval near the sternum; the outer margin is in contact with the omo-hyoid near the hyoid bone.

**Varieties.**—Doubling of the sterno-hyoid is occasionally met with, or more rarely an accessory *cleido-hyoid* muscle, arising from the clavicle, and inserted into the hyoid bone in front of the sterno-hyoid. Absence of the sterno-hyoid on one or both sides has been seen. The muscular fibres are occasionally interrupted by a transverse tendinous intersection at the level of the intermediate tendon of the omo-hyoid, or in rare cases opposite the insertion of the sterno-thyroid.

The **sterno-thyroid**, broader and shorter than the preceding muscle, behind which it lies, arises from the thoracic surface of the first piece of the sternum, lower down and more internally than the sterno-hyoid, and variably from the first and second rib-cartilages; it ascends, diverging a little from its fellow, and is inserted into the oblique line on the ala of the thyroid cartilage.

**Relations.**—The greater part of its anterior surface is concealed by the sternum and the sterno-hyoid muscle, as well as by the sterno-mastoid. By its deep surface it rests on the innominate vein, the lower part of the common carotid artery, the trachea, and the thyroid body. The inner margin is contiguous to the muscle of the other side in the lower part of the neck.

**Varieties.**—The two sterno-thyroid muscles are frequently united across the middle line at their origins. Absence of the muscle has been observed, also doubling. It is occasionally partly crossed by transverse or oblique tendinous lines. At the upper extremity a few fibres are often continued into the thyro-hyoid muscle or into the inferior constrictor of the pharynx. From the outer border a slip is occasionally given off to the sheath of the carotid vessels, covering them as high as the thyroid cartilage (*costo-fascialis*).

The **thyro-hyoid** muscle forms a continuation upwards of the preceding; it

arises from the oblique line on the ala of the thyroid cartilage, and is inserted into the lower border of the hyoid bone, extending over the outer half of the body and the anterior half of the great cornu.

**Relations.**—This muscle is concealed in great part by the sterno-hyoid and omo-hyoid; it rests on the ala of the thyroid cartilage, and on the thyro-hyoid membrane. Between that membrane and the muscle, the superior laryngeal nerve and artery are placed before entering the larynx.

The **omo-hyoid** is a long ribbon-shaped muscle, consisting of two bellies united by an intervening tendon. It arises from the upper border of the scapula, near the suprascapular notch, and occasionally from the ligament which crosses the notch. Thence it extends forwards and only slightly upwards, across the root of

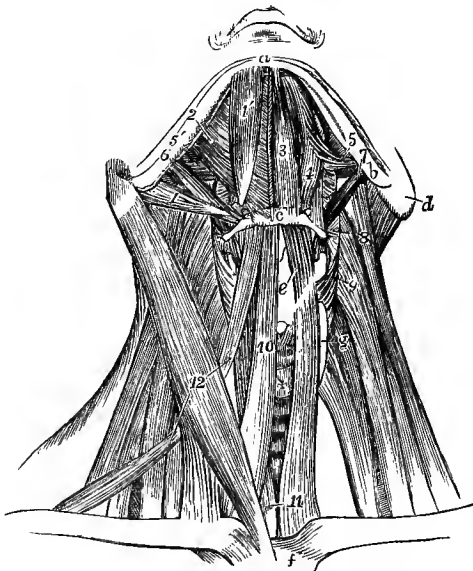


Fig. 277.—MUSCLES OF THE NECK, FROM BEFORE. (Allen Thomson.)  $\frac{1}{2}$

On the right side, the platysma alone has been removed; on the left side, both bellies of the digastric, the stylo-hyoid, mylo-hyoid, sterno-hyoid and omo-hyoid muscles have been removed. *a*, symphysis; *b*, angle of the lower jaw; *c*, hyoid bone; *d*, mastoid process; *e*, placed on the thyroid cartilage, points to the thyro-hyoid muscle; *f*, upper part of the sternum; *g*, lateral lobe, and +, isthmus of the thyroid body; above +, the cricoid cartilage and the crico-thyroid muscle; 1, posterior, and 1', anterior belly of right digastric muscle; 2, right mylo-hyoid; 3, left genio-hyoid; 4, hyo-glossus; 5, stylo-glossus; 5', a portion of the same on the right side; 6, stylo-hyoid of the right side; 7, stylo-pharyngeus of the left side; 8, placed on the levator scapulae, points to the left middle constrictor of the pharynx; 9, placed on the middle scalenus, points to the left inferior constrictor; 10, right sterno-hyoid; 11, placed on the left sterno-thyroid, points also to the lower part of the right muscle; 12, placed on the right sterno-mastoid, points to the anterior and posterior bellies of the right omo-hyoid.

the neck, till it passes beneath the sterno-mastoid muscle, and then, curving rapidly, it ascends nearly vertically, to be inserted into the lower border of the body of the hyoid bone immediately outside the sterno-hyoid. The tendon which divides the muscle is placed beneath the sterno-mastoid muscle, and varies much in length and form in different bodies. The tendon is enclosed within the deep cervical fascia, which, after forming a sort of sheath for it, is prolonged downwards, and becomes attached to the sternum and the cartilage of the first rib; and by this means, as also by fascia investing the posterior belly and descending to the clavicle, the muscle is maintained in its bent position.

**Relations.**—At its scapular origin the muscle is covered by the trapezius, in the middle of its course by the sterno-mastoid; the two bellies appear one in each of the triangles of the neck, the anterior crossing the common carotid artery, the posterior bounding the small triangle in which the subclavian artery is found; it also lies over the scaleni muscles, the lower cervical nerves, the sheath of the common carotid artery and jugular vein, and the sterno-thyroid and thyro-hyoid muscles.

**Varieties.**—These are very frequent. The commonest is an attachment to the clavicle, which may be the sole origin of the posterior belly, or it may be by a supernumerary belly. Complete doubling of the muscle has been observed in a few cases. On the other hand entire absence is recorded; also absence of the anterior belly, its place being taken by a band of fascia. The anterior belly is sometimes fused with the sterno-hyoid.

The omo-hyoid and sterno-hyoid are portions of the same muscular sheet, the original continuity of the two being indicated by the fascia which binds down the posterior belly of the omo-hyoid to the clavicle, and which has been seen in the infant to contain striped muscular fibres. The chief varieties of the omo-hyoid may be explained as resulting from an increased or diminished degree of cleavage in this sheet, or the reappearance (or persistence) of the part which is normally suppressed. (Gegenbaur, "Ueber den Musculus Omo-hyoideus und seine Schlüsselbeinverbindung," *Morph. Jahrb.*, i, 243.)

**Nerves.**—The infrahyoid muscles receive their nervous supply from the first three cervical nerves, by means of fibres which run in great part through the hypoglossal trunk. Thus, from the first two cervical nerves fibres pass to the hypoglossal, which they leave mainly as the descending branch, but some are continued on to form a special branch to the thyro-hyoid. The descending branch is joined by communicating branches from the second and third cervical nerves, and from the loop thus constituted offsets proceed to the sterno-hyoid, sterno-thyroid and both bellies of the omo-hyoid.

#### THE SUPRAHYOID MUSCLES.

The **digastric** muscle consists of two elongated fleshy bellies united by an intervening rounded tendon. The posterior belly arises from the digastric fossa of the temporal bone, and is directed downwards, forwards and inwards, tapering gradually, towards the hyoid bone: the anterior is attached to a rough depression on the lower border of the lower jaw, close to the symphysis; it is shorter and broader than the posterior belly, and is directed downwards, backwards, and slightly outwards. The intervening tendon is connected to the body and great cornu of the hyoid bone by a broad band of aponeurotic fibres and by the fleshy fibres of the stylo-hyoid muscle, through which the tendon passes.

**Relations.**—The posterior belly is for the most part concealed by the mastoid process, the sterno-mastoid and splenius muscles, and the parotid gland; it crosses the internal and external carotid arteries, with the internal jugular vein and accompanying nerves. The anterior belly is placed immediately beneath the deep cervical fascia, and rests on the mylo-hyoid muscle; its inner border is connected by a dense aponeurosis with its fellow of the opposite side.

**Varieties.**—The digastric muscle is subject to many variations. The posterior belly has been seen receiving an accessory slip from the styloid process, or arising entirely from that part, or connected by a slip with the middle or inferior constrictor of the pharynx. The anterior belly has been joined by a slip arising from the lower jaw in front of the angle. In rare cases the muscle is monogastric, the anterior attachment in that case taking place about the middle of the body of the lower jaw. The anterior belly is frequently divided into two or more parts, one or even two of which may cross the middle line and decussate with similar slips from the muscle of the opposite side; or a slip sometimes passes to the median raphe of the mylo-hyoid, or becomes incorporated with its fellow of the opposite side. Its deep surface is sometimes united by muscular fibres with the subjacent mylo-hyoid. The tendon of the digastric has been seen in front of, or more rarely behind the stylo-hyoid, instead of passing through it.

The *mento-hyoid* is an occasional median slip found passing from the body of the hyoid bone to the chin; it sometimes consists of two parallel bands.

The **stylo-hyoid** is a slender muscle placed along the upper border of the posterior belly of the digastric. It arises by a narrow tendon from the back of the styloid process of the temporal bone near the root, and inclines downwards and forwards, to be inserted into the hyoid bone at the union of the great cornu with the body. Its fibres are usually divided into two fasciculi near its insertion, for the transmission of the tendon of the digastric muscle.

**Relations.**—The upper part of the stylo-hyoid is covered by the parotid gland; the lower part is superficial. The muscle crosses the external carotid artery. The lower part of the stylo-hyoid, the anterior belly of the digastric, and the base of the lower jaw bound a triangular space which contains the submaxillary gland, and is known as the *submaxillary triangle*.

**Varieties.**—The stylo-hyoid is not unfrequently wanting; while, on the other hand, doubling of the muscle has also been recorded. It is occasionally placed on the inner side of

the external carotid artery. The insertion may take place partly or wholly into the tendon of the digastric; or fibres are continued into the omo-hyoid, thyro-hyoid, or mylo-hyoid muscles. An additional muscular slip is occasionally seen (*stylo-hyoidæus alter*), passing from the styloid process to the small cornu of the hyoid bone, and accompanying or replacing the stylo-hyoid ligament.

The **mylo-hyoid** muscle arises from the mylo-hyoid ridge on the inner surface of the lower jaw, extending from the last molar tooth almost to the symphysis. The nearly parallel fibres pass inwards, backwards and downwards; the hinder ones are inserted, shortly tendinous, into the body of the hyoid bone, while the larger number, becoming gradually shorter as they are placed farther forwards, meet at an angle with those of the opposite muscle and end in a median tendinous raphé, extending from near the symphysis of the jaw to the hyoid bone. Thus the two muscles together form a floor below the anterior part of the mouth (*diaphragma oris*, Meyer).

**Relations.**—The lower surface of the mylo-hyoid is in contact with the anterior belly of the digastric, the submaxillary gland, the facial artery and its submental branch, and the

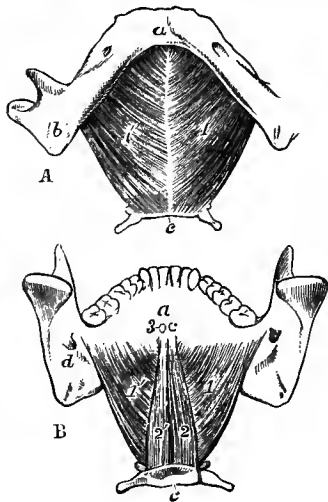


Fig. 278.—A, THE LOWER JAW AND HYOID BONE, FROM BELOW, WITH THE MYLO-HYOID MUSCLES ATTACHED.

B, THE SAME, FROM ABOVE AND BEHIND, WITH THE MYLO-HYOID AND GENIO-HYOID MUSCLES ATTACHED. (Allen Thomson.)  $\frac{1}{2}$

*a*, symphysis; *b*, angle of the lower jaw; *c*, hyoid bone; *d*, in B, the inferior dental foramen and upper end of the mylo-hyoid ridge; 1, 1', the mylo-hyoid muscles; 2, 2', the genio-hyoid muscles from above; 3, the cut ends of the attachments of the genio-glossi muscles to the superior mental spines.

mylo-hyoid vessels and nerve. The muscle covers the genio-hyoid, genio-glossus, and parts of the hyo-glossus and stylo-glossus muscles, the sublingual gland and the duct of the submaxillary gland, and the lingual branch of the fifth and the twelfth nerves. The posterior border alone is free, and around it the deep part of the submaxillary gland turns.

**Varieties.**—This muscle may be inseparably united with, and even upon one side in great part replaced by, the anterior belly of the digastric. It frequently receives an accessory slip from one of the other hyoid muscles, as the sterno-hyoid, omo-hyoid, or stylo-hyoid. A deficiency at the fore part of the muscle is of common occurrence, the origin not reaching

farther forwards than the canine tooth.

The **genio-hyoid** muscle has a narrow origin by short tendinous fibres from the inferior mental spine behind the symphysis of the jaw, and is inserted into the anterior surface of the body of the hyoid bone.

**Relations.**—It is in contact above with the lower border of the genio-glossus muscle, below with the mylo-hyoid, and internally meets its fellow in the median plane.

**Varieties.**—The genio-hyoid is sometimes blended with its fellow of the opposite side. It has also been found double, sending a slip to the great cornu of the hyoid bone, and united to the genio-glossus.

**Nerves.**—The elevator muscles of the hyoid bone receive their motor nerves from various sources, viz., the anterior belly of the digastric and the mylo-hyoid from the mylo-hyoid branch of the inferior maxillary division of the fifth nerve, the posterior belly of the digastric and the stylo-hyoid from the facial nerve near the place of its exit from the stylo-mastoid foramen, and the genio-hyoid from a branch given off by the hypoglossal, but consisting of fibres derived from the upper cervical nerves.

**Actions of the muscles of the front of the neck.**—The two *sterno-mastoid* muscles acting together bend forwards the head and neck towards the sternum. If one muscle act alone, the head, while it is slightly flexed, is inclined laterally towards the side on which the muscle



contracts and rotated to the opposite side. This is the attitude in wry neck, which is due to the spasmodic or organic contraction of one sterno-mastoid. Taking their fixed point at the head, they can elevate the upper part of the thorax in forced inspiration.

While the *sterno-hyoid* and *omo-hyoid* muscles act simply as depressors of the hyoid bone, the *sterno-thyroid* muscle, being a direct depressor of the thyroid cartilage, can also draw down the hyoid bone when it acts in conjunction with the *thyro-hyoid*, the latter muscle elevating the larynx when the hyoid bone is fixed. When, in the act of swallowing, the hyoid bone and thyroid cartilage have passed suddenly upwards, their original position is restored by the action of the infrahyoid muscles. In the utterance of low notes the larynx and hyoid bone descend below the natural level, in the direction of the sternal muscles; while in the utterance of high notes there is little elevation of the hyoid bone, but the larynx is raised by the action of the thyro-hyoid muscles. During deglutition the thyro-hyoid muscles, by drawing the thyroid cartilage up under the hyoid bone, are the principal agents in producing the descent of the epiglottis on the superior aperture of the larynx. The infrahyoid muscles also act with the sterno-mastoids in forced inspiration.

The *digastric*, *mylo-hyoid* and *genio-hyoid* muscles are either elevators of the hyoid bone, or depressors of the lower jaw, according as one or other of these bones is fixed by the antagonistic muscles. The *stylo-hyoid* acts only on the hyoid bone. The mylo-hyoid and genio-hyoid acting alone draw the hyoid bone forwards as well as upwards, while the stylo-hyoid (aided by the middle constrictor of the pharynx) moves it backwards and upwards. The attachment of the digastric to the hyoid bone, however, is not close enough to allow of the independent action of the anterior and posterior bellies, and this muscle therefore, when the jaw is fixed, elevates directly the hyoid bone, as do also the other muscles of this group acting in combination. The mylo-hyoid farther raises the floor of the mouth and presses the tongue against the palate, thus forcing backwards the food in the first stage of deglutition.

#### THE MUSCLES OF THE TONGUE.

The tongue is a muscular organ attached posteriorly to the hyoid bone, and inferiorly to the lower jaw. It is composed partly of fibres peculiar to itself—the *intrinsic* muscles, which will be noticed with the special anatomy of the tongue in Vol. III, and partly of muscles arising from neighbouring parts—the *extrinsic* muscles about to be described.

The **genio-glossus** or **genio-hyo-glossus** muscle is fan-shaped, and is placed vertically in contact with its fellow in the median plane. It arises by a short tendon from the superior mental spine behind the symphysis of the jaw: from this its fibres diverge, to be inserted, the inferior, for the most part, into the body of the hyoid bone, and a few into the side of the pharynx; the superior into the tip of the tongue; and the intermediate fibres into the whole length of the tongue spreading outwards in its substance. Some of the innermost fibres, as they enter the tongue, decussate across the middle line with those of its fellow muscle.

**Relations.**—Its external surface is in contact with the inferior lingualis, hyo-glossus and stylo-glossus muscles, the sublingual gland and the ranine vessels, and its lower border with the genio-hyoid muscle. The terminal portion of the hypoglossal nerve enters its posterior part.

**Varieties.**—Occasional slips of this muscle have been noticed passing to the epiglottis, or to the stylo-hyoid ligament, or more frequently to the small cornu of the hyoid bone. It has also been found united with the genio-hyoid muscle.

The **hyo-glossus** is a flat quadrate muscle, arising from the whole length of the great cornu and from the lateral part of the body of the hyoid bone; it passes upwards to the posterior half of the tongue close to its lateral border, whence the fibres spread forwards and inwards over the dorsum, joining those of the stylo-glossus muscle.

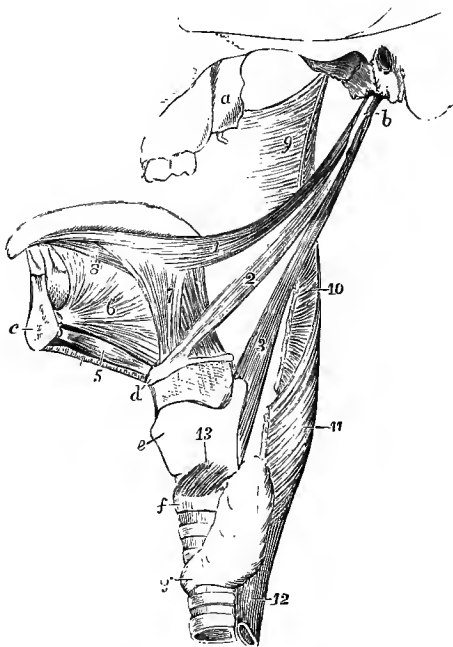
**Relations.**—The hyo-glossus is concealed by the digastric, stylo-hyoid and mylo-hyoid muscles, except at its posterior inferior angle: the deep part of the submaxillary gland rests on its surface, and it is crossed from below upwards by the hypoglossal nerve, the Whartonian duct, and the lingual nerve. It covers the hinder part of the genio-glossus, the lower end of the stylo-hyoid ligament, and the origin of the middle constrictor of the pharynx, together with the lingual artery and glosso-pharyngeal nerve.

**Varieties.**—The origin of the muscle is sometimes pierced by the lingual artery. The *triticeo-glossus* is a small muscle which arises from the cartilago triticea in the thyro-hyoid ligament, and passes upwards and forwards, lying on the inner side of the lingual artery, to enter the tongue with the posterior part of the hyo-glossus.

The **chondro-glossus** is a small flattened muscular slip, sometimes described as a part of the preceding muscle, from which it is separated, however, by the pharyngeal fibres of the genio-glossus. It arises from the inner side of the base of the small cornu and from part of the body of the hyoid bone, and its fibres are directed upwards and forwards, spreading somewhat, to end on the dorsum of the tongue by the side of the middle line. It is sometimes wanting.

The **stylo-glossus**, the shortest of the three muscles which spring from the styloid process, arises from the front of that process near its point, and from the

Fig. 279. — MUSCLES OF THE TONGUE, PHARYNX, &c., OF THE LEFT SIDE. (Allen Thomson.)  $\frac{1}{3}$



*a*, external pterygoid plate; *b*, styloid process; *c*, section of lower jaw; *d*, hyoid bone; *e*, thyroid cartilage; *f*, cricoid cartilage; between *d* and *e*, the thyro-hyoid membrane; *g*, isthmus of thyroid body; 1, stylo-glossus muscle; 2, stylo-hyoid; 3, stylo-pharyngeus; 4, cut edge of mylo-hyoid; 5, genio-hyoid; 6, genio-glossus; 7, hyo-glossus; 8, lingualis inferior; 9, part of superior constrictor of pharynx; 10, back part of middle constrictor; 11, inferior constrictor; 12, upper part of oesophagus; 13, crico-thyroid muscle.

stylo-maxillary ligament, to which in some cases the greater number of its fibres are attached: passing forwards and slightly downwards and inwards, it is inserted along the side and under part of the tongue as far as the tip, its fibres decussating, and becoming blended with those of the hyo-glossus and palato-glossus muscles.

**Relations.**—This muscle lies deeply beneath the parotid gland and angle of the jaw, and is crossed by the lingual nerve.

**Varieties.**—Absence and doubling of the stylo-glossus have both been noted. The *mylo-glossus* is a small accessory slip, which generally arises from the angle of the lower jaw, but has also been seen coming from the stylo-maxillary ligament. Occasionally the whole muscle arises from one of these points. The name *stylo-auricularis* has been given to a small muscular slip occasionally seen, springing from the cartilage of the external auditory meatus close to its attachment to the bone, and ending below on the styloid process, or passing in part or wholly into the stylo-glossus. A fibrous band is often found in this situation.

**Nerves.**—The muscles of this group are all supplied with branches from the hypoglossal or twelfth cranial nerve.

**Actions.**—The *genio-glossus* muscle has a complicated action, the hinder part protruding, and the fore part retracting the tongue, while the middle part, or nearly the whole muscle, acts as a depressor. The *stylo-glossus* draws the tongue backwards, and elevates its base. It thus comes into play in deglutition. The muscle of one side acting alone gives a lateral direction to the fore part of the tongue. The *hyo-glossus* and *chondro-glossus* retract and depress the tongue. The genio-glossus and stylo-glossus acting together tend to make the dorsum of the tongue concave, while the hyo-glossus produces a convexity.

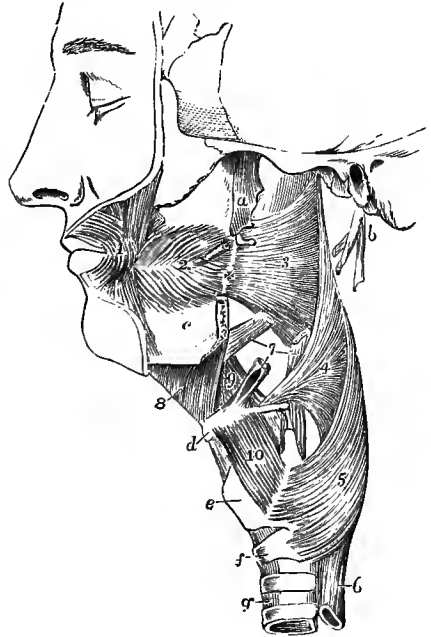
## THE MUSCLES OF THE PHARYNX.

The pharynx, the dilated upper part of the alimentary tube extending from the base of the skull to the œsophagus, presents at the sides and back a continuous wall, in great part formed and supported by distinct muscles resting posteriorly against the vertebral column, while in front it is open towards the nasal cavity, the mouth, and the larynx.

The muscles entering into the construction of the wall of the pharynx are disposed in two layers, viz., an outer layer in which the fibres have a generally transverse direction, and an inner one composed of longitudinal fibres. The outer layer includes three muscles named *constrictors*, all of which spring in front from bones or

Fig. 280. — DEEP MUSCLES OF THE CHEEK, PHARYNX, &c. (Modified from Cloquet.) (Allen Thomson.)  $\frac{1}{2}$

The pharynx has been distended by stuffing. *a*, external pterygoid plate; *b*, styloid process with short portions of the three styloid muscles attached; *c*, lower jaw, which has been divided at the place where the pterygo-maxillary ligament + is attached; *d*, hyoid bone; *e*, thyroid cartilage; *f*, cricoid cartilage; *g*, trachea; 1, outer part of the orbicularis oris muscle; 2, buccinator; 3, superior constrictor of the pharynx; 4, middle constrictor; 5, inferior constrictor; 6, œsophagus; 7, points by three lines to the lower parts of the stylo-glossus, stylo-hyoid, and stylo-pharyngeus muscles respectively; 8, mylo-hyoid; 9, hyo-glossus, of which a small part is removed posteriorly to show the attachment of the middle constrictor; 10, thyro-hyoid.



cartilages, and terminate behind, where they are much expanded and overlap one another from below upwards, by joining their fellows in the middle line, forming in the upper part a median tendinous raphé. The inner layer comprises the *elevator* muscles of the pharynx, two in number, viz., the stylo-pharyngeus and the palato-pharyngeus, the latter of which will be described together with the muscles of the soft palate.

The **inferior constrictor** muscle, the broadest and thickest of the three, arises by a series of slips from the side of the cricoid cartilage at its lower and posterior part, and from the inferior cornu, the oblique line and upper tubercle of the thyroid cartilage; some fibres are also usually continued into it from the sterno-thyroid and crico-thyroid muscles. It curves backwards and inwards, and unites with its fellow in the middle line at the back of the pharynx. The direction of the inferior fibres is horizontal; the rest ascend with increasing degrees of obliquity, and the highest fibres terminate on the raphé about an inch below the basilar process. From its lower border a few fibres turn downwards into the longitudinal fibres of the œsophagus.

**Relations.**—This muscle is in contact posteriorly with the cervical vertebræ and the prevertebral muscles; laterally with the thyroid body, the carotid arteries and the sterno-thyroid muscle. It covers the middle constrictor, the stylo-pharyngeus, the palato-pharyngeus and the mucous membrane of the pharynx. The superior laryngeal nerve and vessels pass inwards to the larynx above its upper border, and the inferior ascend beneath its lower border.

The **middle constrictor** muscle arises from the large and small cornua of the hyoid bone, and from the stylo-hyoid ligament: its fibres, diverging greatly, pass back to the middle line of nearly the whole length of the pharynx, the lowest fibres inclining downwards beneath the inferior constrictor, the highest ascending and overlapping the superior constrictor, and the intermediate fibres running transversely.

**Relations.**—This muscle is separated from the superior constrictor by the stylo-pharyngeus muscle, while between its origin and that of the inferior constrictor the superior laryngeal nerve and vessels pierce the thyro-hyoid membrane.

**Varieties.**—The middle constrictor has been seen to receive fibres from the body of the

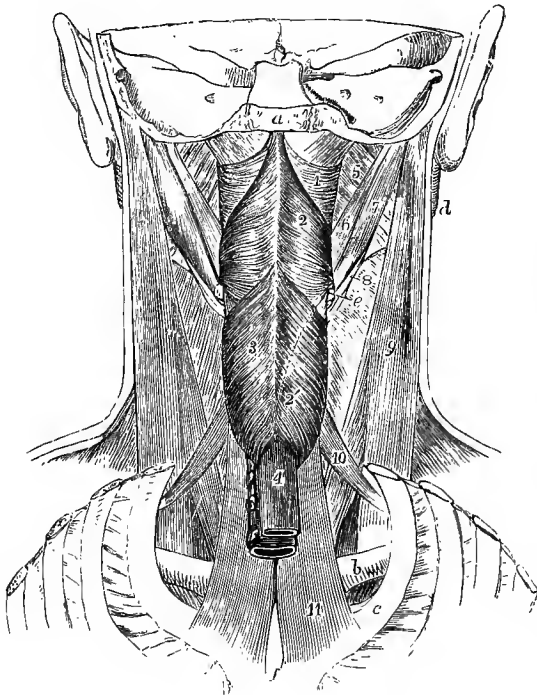


Fig. 281.—VIEW OF THE MUSCLES OF THE PHARYNX, &c., FROM BEHIND. (After Bourguery.)  $\frac{1}{3}$

The back part of the skull, the vertebral column and back parts of the ribs are removed. *a*, cut surface of basilar process; *b*, clavicle; *c*, first rib; *d*, ramus of lower jaw; *e*, posterior extremity of great cornu of hyoid bone; *f*, posterior surface of manubrium; 1, superior constrictor muscle of the pharynx; above it the fibrous membrane which closes the pharynx; 2, middle constrictor; 2', a dotted line, indicating the direction of the lower part of the muscle; 3, inferior constrictor; 4, œsophagus; 5, internal pterygoid; 6, stylo-glossus; 7, posterior belly of digastric; 8, a portion of the stylo-hyoid surrounding the tendon of the digastric; 9, sternomastoid; 10, anterior belly of the omo-hyoid; 11, sterno-thyroid muscle (represented somewhat too broad).

hyoid bone, from the tongue, and from the hinder part of the mylo-hyoid ridge of the lower jaw. A slip from the lateral thyro-hyoid ligament (*syndesmo-pharyngeus*) is of frequent occurrence.

The **superior constrictor** arises by fibres attached in series, from below upwards, to the side of the tongue, to the mucous membrane of the mouth, to the extremity of the mylo-hyoid ridge of the jaw, to the pterygo-maxillary ligament, and to the hamular process and lower third or less of the posterior border of the internal pterygoid plate. The fibres curve backwards, and are mostly blended with those of the corresponding muscle along the middle line, a few ending posteriorly in the aponeurosis which fixes the pharynx to the base of the skull. The upper margin curves round the levator palati and the Eustachian tube; and the space intervening between this concave margin of the constrictor and the base of the skull is closed by fibrous membrane.

**Relations.**—In contact with the outer surface of this muscle are the internal carotid artery, the vagus and sympathetic nerves, the middle constrictor, which overlaps a considerable portion, and the stylo-pharyngeus, which descends to the pharynx between the two constrictors. It conceals the palato-pharyngeus and the tonsil, and is lined by mucous membrane. It is united to the buccinator muscle anteriorly by the pterygo-maxillary ligament.

The constrictor muscles are invested on their outer surface by a layer of dense

connective tissue, which is but loosely attached to the adjacent prevertebral fascia (p. 298). This layer is stronger above than below, and is prolonged forwards over the lateral part of the superior constrictor to the pterygo-maxillary ligament, where it becomes continuous with the membrane covering the buccinator muscle, whence the whole structure is named the *bucco-pharyngeal fascia*.

The **stylo-pharyngeus** (fig. 279, 3), larger and longer than the other styloid muscles, arises from the inner surface of the styloid process near the root, and proceeding downwards and inwards to the side of the pharynx, passes under cover of the middle constrictor muscle, where it gradually expands, and being joined by the palato-pharyngeus, ends on the superior and posterior borders of the thyroid cartilage, and in the lateral wall of the pharynx.

**Relations.**—The external surface of this muscle is, in the upper part of its extent, in contact with the styloid process and the external carotid artery; in the lower, with the middle and inferior constrictors of the pharynx. Internally it rests on the internal carotid artery and superior constrictor, and lower down on the mucous membrane of the pharynx. The glosso-pharyngeal nerve crosses over the muscle in turning forwards to the tongue.

**Varieties.**—Splitting or doubling of the stylo-pharyngeus is often met with; a division into three parts has also been observed.

Supernumerary elevator muscles of the pharynx are not unfrequently present, arising from a neighbouring part of the base of the skull, and inserted variably into one or other of the constrictors, or passing between those muscles to the fibrous layer of the pharynx. Their most frequent origin is from the under surface of the petrous bone in front of the carotid canal or from the vaginal process of the temporal bone (*petro-pharyngeus*), but they also occur arising from the spine of the sphenoid (*spheno-pharyngeus*), from the hamular process (*pterygo-pharyngeus externus*), or farther back, from the basilar process (*occipito-pharyngeus*), or very rarely from the mastoid process (*pharyngo-mastoides*). Belonging to the same group is the *azygos pharyngis*, a small median slip sometimes present, arising from the pharyngeal tubercle of the occipital bone, and descending to the raphé or the posterior wall of the pharynx.

**Nerves.**—The constrictor muscles are supplied by the pharyngeal plexus, their motor fibres being derived from the bulbar portion of the spinal accessory nerve, and in the case of the middle constrictor perhaps also from the glosso-pharyngeal. The inferior constrictor receives branches in addition from the external and inferior laryngeal nerves. The stylo-pharyngeus is innervated by the glosso-pharyngeal.

#### THE MUSCLES OF THE SOFT PALATE.

The soft palate (*velum pendulum palati*) is a moveable curtain, continued backwards from the hard palate. It presents posteriorly a free pendulous margin, prolonged in the middle into a conical process, the *uvula*, and at each side into a prominent curved fold, the *posterior pillar of the fauces*, which runs downwards and backwards on the side wall of the pharynx, while from the base of the uvula and the under surface of the soft palate another fold, the *anterior pillar of the fauces*, descends to the tongue; between the two pillars on each side is lodged the tonsil. The constricted passage between the anterior pillars, leading from the mouth to the pharynx, is called the *isthmus of the fauces*. The soft palate is acted on by five pairs of elongated muscles, two superior, one intermediate, and two inferior.

The **palato-glossus** muscle, or **constrictor isthmi faucium**, occupies the anterior pillar of the fauces. Superiorly it is placed below all the other muscles of the palate, and its fibres are continuous with those of its fellow of the opposite side; inferiorly it enters the side of the tongue, where it becomes continuous with the transverse fibres of that organ.

Behind and continuous with the fibres of the palato-glossus are some thin bundles of muscular fibres which ascend from the side of the tongue and are lost over the outer surface of the tonsil. They were named *amygdalo-glossus* by Broca.

The **palato-pharyngeus** arises in the soft palate in two layers which embrace the levator palati and *azygos uvulæ* muscles. The superficial or upper layer con-

sists of scattered fibres which join those of the opposite muscle in the middle line; the deep or lower layer is much stronger, and partly meets its fellow, partly takes origin from the hinder margin of the hard palate and the aponeurosis of the velum. At the outer border of the soft palate the muscle also receives one or two slender bundles which descend from the lower and fore part of the cartilage of the Eustachian tube (*salpingo-pharyngeus*, Santorini). It then passes downwards and backwards in the posterior pillar of the fauces, becomes considerably expanded, and is inserted, its fibres mingling with those of the stylo-pharyngeus, into the upper and hinder borders of the thyroid cartilage, and into the fibrous layer of the lower part of the pharynx, reaching as far as, or even crossing, the middle line behind.

The **azygos uvulæ** muscle (Morgagni), so called from having been supposed to be a single muscle, consists of two slips, which arise, one on each side of the middle

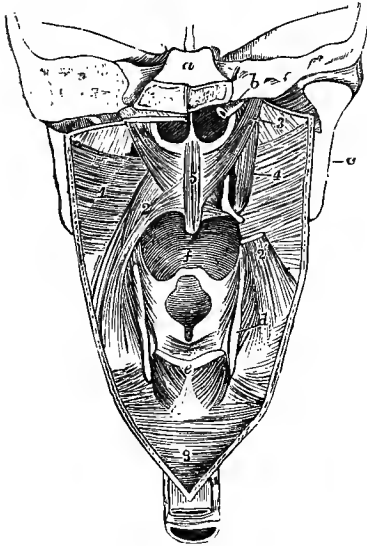


Fig. 282.—DIAGRAMMATIC VIEW OF THE MUSCLES OF THE SOFT PALATE, &c., FROM BEHIND. (Allen Thomson.)  $\frac{1}{2}$

The posterior wall of the pharynx has been divided by a vertical incision in the middle line, and the cut edges drawn to the side so as to expose the nasal, buccal, and laryngeal openings. *a*, is above the cut surface of the basilar process, and below that are the posterior nares; *b*, cartilage of the right Eustachian tube; *c*, back of the ramus of the lower jaw; *d*, posterior border of the thyroid cartilage; *e*, upper part of the cricoid cartilage; *f*, base of the tongue above the epiglottis; *g*, lower end of the pharynx leading into the gullet; 1, superior constrictor of the pharynx seen from within; 2, palato-pharyngeus; 2', the lower part of the same muscle, on the right side; 3, placed on the internal pterygoid muscle, points to the levator palati; 4, the right circumflexus palati muscle winding round the hamular process; 5, azygos uvulæ; above *e*, the arytenoid, and below it on each side the posterior crico-arytenoid muscle.

line, from the tendinous structure of the soft palate, sometimes also from the posterior nasal spine, and descend into the uvula.

The two slips are separated by a slight interval above, and unite as they descend.

The **levator palati** muscle arises by a narrow tendon from the under surface of the petrous portion of the temporal bone, in front of the orifice of the carotid canal, and from the lower margin of the cartilage of the Eustachian tube. The fibres form a rounded muscle which passes downwards and forwards into the pharynx, crossing the upper border of the superior constrictor. Becoming flattened as it approaches the middle line, its fore part is inserted into the aponeurosis of the palate, while the larger posterior portion meets the muscle of the other side under cover of the *azygos uvulæ*.

The **circumflexus** or **tensor palati** arises from the navicular fossa at the root of the internal pterygoid plate, from the spine of the sphenoid, and from the outer side of the Eustachian tube. Its flattened belly descends perpendicularly, on the mesial side of the internal pterygoid muscle, and ends in a tendon which, turning round the hamular process, where a synovial bursa smooths its passage, extends horizontally inwards, and is inserted into a transverse ridge on the under surface of the palate bone, and into the aponeurosis of the soft palate.

**Nerves.**—The muscles of this group receive their nerves from sources some of which are not yet sufficiently determined. The tensor palati receives a branch through the otic ganglion

from the third division of the fifth nerve; the levator palati, azygos uvulæ, palato-glossus and palato-pharyngeus are probably supplied by the bulbar portion of the spinal accessory nerve through the pharyngeal plexus. (For a summary of the evidence bearing upon the innervation of the palatal muscles see W. A. Turner in Journ. Anat. and Phys., xxiii, 523.)

**Actions of the muscles of the pharynx and soft palate.**—In considering the mode of action of the constrictor muscles it is to be observed that their so-called insertion takes place into a part which, owing to its connections, cannot be moved forwards, and that the constriction of the pharynx takes place therefore mainly by movement backwards of its anterior wall, the cavity being thus converted into a transverse slit. The hyoid bone and larynx are at the same time carried somewhat upwards as well as backwards, in consequence of the oblique direction of the larger number of the fibres of the middle and lower constrictors. The upper part of the superior constrictor differs from the rest in the circumstance that, being placed above the level of the palate, it cannot act directly on the food, and also that its fibres are attached at both ends to parts which are immovable. The effect of its contraction is consequently to flatten the side-walls of this part of the pharynx, and thus to assist in approximating the posterior pillars of the fauces. The *stylo-pharyngeus* is the principal elevator of the pharynx and larynx. The *palato-glossi*, besides depressing the soft palate and elevating the tongue, also bring together the anterior pillars of the fauces, and thus shut off the mouth-cavity from the pharynx. The *palato-pharyngei* similarly depress the soft palate and raise the pharynx, but their principal action is to bring together the posterior pillars of the fauces, thus separating the nasal and buccal portions of the pharynx. The *azygos uvulæ* raises and shortens the uvula. The action of the *levator palati* is expressed by its name, while the *tensor* not only tightens and supports the soft palate against pressure from below, and against the traction of the depressor muscles, but is also, in the opinion of most anatomists, the agent by which the Eustachian tube is opened during deglutition. It is proper, however, to remark that a different view is taken by Cleland, who holds—and in this he, to some extent, agrees with Luschka—that the tube is closed during deglutition by the thickening which accompanies the contraction of the levator palati, pressing up the membranous floor of the canal against the upper and outer wall, so as completely to obliterate the opening (Journ. Anat., iii, 97).

The muscles of the pharynx and soft palate are so arranged as to accomplish, in conjunction with those of the tongue and hyoid bone, the action of deglutition—that is to say, the propulsion of food into the œsophagus without any portion being permitted to pass into the nasal cavity or larynx. The first stage of this operation is effected by the mylo-hyoid, stylo-glossus and palato-glossus muscles, which press the tongue against the palate, and so force the food backwards through the isthmus of the fauces, the hyoid bone being at the same time raised by its proper elevators. The larynx is then carried upwards under the hyoid bone by the thyro-hyoid and stylo-pharyngeus muscles, and the root of the tongue being drawn backwards by the stylo-glossi, the epiglottis is pressed downwards over the superior aperture of the larynx, which is thus protected. Simultaneously the soft palate is raised and fixed by its superior muscles, and the palato-pharyngei bring together the posterior pillars of the fauces, which nearly touch one another (the uvula lying in the small interval between them) and prevent the passage of the food towards the upper part of the pharynx or the posterior nares, while they form an inclined surface for its guidance into the lower part of the pharynx. The food being thus thrown into the grasp of the constrictors of the pharynx, these muscles contract rapidly from above downwards and force it into the tube of the gullet below.

#### DEEP LATERAL AND PREVERTEBRAL MUSCLES OF THE NECK.

The **SCALENI** muscles form a group of strong muscular columns, which are usually three in number, but sometimes only two. All of them are subdivided above into musculo-tendinous slips, corresponding in number with their vertebral attachments.

The **scalenus anticus** muscle is attached superiorly to the anterior tubercles of the transverse processes of the third, fourth, fifth and sixth cervical vertebra, and inferiorly by a thick flattened tendon to the scalene tubercle on the upper surface of the first rib.

**Relations.**—This muscle is deeply placed under cover of the sterno-mastoid; on its anterior surface lie the subclavian vein, omo-hyoid muscle and phrenic nerve; behind are the scalenus medius. The nerves of the brachial plexus, the subclavian artery and the pleura. On its inner side the rectus anticus major arises from the same transverse processes, and the ascending cervical artery lies in the groove between the two muscles, while the internal jugular vein is in front. Below the sixth cervical transverse process the vertebral vessels pass backwards between the scalenus anticus and the longus colli.

The **scalenus medius** is attached superiorly to the posterior tubercles of the transverse processes of all the cervical vertebræ (sometimes not to the atlas), and inferiorly to a rough impression on the first rib, extending from the tuberosity to the groove for the subclavian artery.

**Relations.**—In front of this muscle, between it and the anterior scalenus, are the cervical nerves and the subclavian artery; behind it are the posterior scalenus and levator anguli scapulæ muscles.

The **scalenus posticus**, smaller than the other scaleni muscles, is attached above by two or three small tendons to the transverse processes of as many of the lower cervical vertebræ, and inferiorly by an aponeurotic tendon to the second rib external to the attachment of the serratus posticus superior.

**Varieties.**—The scaleni muscles are subject to a considerable amount of variation, both in the number of their points of attachment, and in the arrangement of their fibres. A slip from

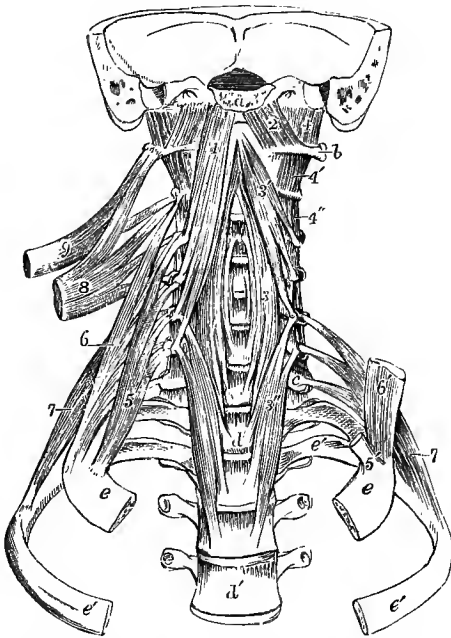


Fig. 283.—THE DEEP LATERAL AND PREVERTEBRAL MUSCLES OF THE NECK, FROM BEFORE. (Allen Thomson.)  $\frac{1}{2}$

*a*, cut surface of basilar process; *b*, transverse process of atlas; *c*, transverse process of seventh cervical vertebra; *d*, body of first, *d'*, of fourth dorsal vertebra; *e*, first, and *e'*, second rib; 1, rectus capitis anticus major muscle; 2, rectus capitis anticus minor; 3, middle part, 3', upper part, and 3'', lower part of longus colli; 4, rectus lateralis; 4', first pair, and 4'', second pair of intertransversales; 5, scalenus anticus of right side; 5', its attachment to the first rib on left side; 6, scalenus medius; 6', lower portion of corresponding muscle of left side; 7, scalenus posticus, its superior attachments shown upon the left side; 8, upper part of levator scapulæ drawn out from its vertebral attachments; 9, splenius colli, shown in the same manner.

the scalenus anticus sometimes passes behind the subclavian artery. The scalenus posticus is not unfrequently absent; on the other hand it has been seen extending to the third rib. The *scalenus pleuralis* (Sibson) consists of fibres which arise from the transverse process of the seventh cervical vertebra, and spread out in the fascia supporting the cervical dome of the pleura, by means of which they are inserted into the inner border of the first rib.

The PREVERTEBRAL muscles of the cervical region are three in number, two of which pass to the head from the upper vertebræ, viz., the rectus capitis anticus major and minor, and the third is confined to vertebral attachments, the longus colli. Along with these the rectus capitis lateralis muscle may also be described in this place.

The **rectus capitis anticus major** muscle arises by tendinous slips from the anterior tubercles of the transverse processes of the third, fourth, fifth and sixth cervical vertebræ: it is inserted into the basilar process of the occipital bone, a little in front of the foramen magnum. The muscles of opposite sides converge as they ascend, and their mesial fibres are longest.

**Relations.**—Its anterior surface supports the pharynx, the sympathetic and vagus nerves, and the great cervical vessels. The posterior surface rests upon the vertebræ, part of the longus colli and the rectus anticus minor.



The **rectus capitis anticus minor**, partly covered by the major, arises from the front of the root of the transverse process of the atlas, and is inserted into the basilar process, between the margin of the foramen magnum and the preceding muscle, half an inch from its fellow.

The **rectus capitis lateralis** is a short thick muscle arising from the upper and fore part of the enlarged extremity of the transverse process of the atlas, and inserted into the rough under surface of the jugular process of the occipital bone. This and the foregoing muscle complete the series of intertransversales muscles, which are described along with the deep muscles of the back.

The **longus colli** muscle rests on the front of the vertebral column from the atlas to the third dorsal vertebra; it consists of three sets of fibres, of which one is vertical and two are oblique. *a.* The *vertical* part arises by a series of flattened muscular and tendinous processes from the bodies of the lower two cervical and upper two or three dorsal vertebræ, and along its outer border it receives slips also from the transverse processes of the lower three or four cervical vertebræ; it is inserted into the bodies of the second, third and fourth cervical vertebræ. *b.* The *lower oblique* part, the smallest of the three, takes origin in common with the vertical part from the bodies of the upper dorsal vertebræ, and is inserted by narrow tendinous slips into the anterior tubercles of the transverse processes of the fifth and sixth cervical vertebræ. *c.* The *upper oblique* part arises by separate tendinous slips from the anterior tubercles of the transverse processes of the third, fourth and fifth cervical vertebræ, and is inserted into the lateral part of the tubercle on the anterior arch of the atlas, becoming connected also with the upper end of the vertical part.

**Relations.**—By its anterior surface the longus colli muscle is in contact with the pharynx and œsophagus, the great vessels of the neck contained in their sheath, the sympathetic and recurrent laryngeal nerves, and the inferior thyroid artery. Behind, it rests upon the vertebræ.

**Varieties.**—The number of attachments, and the degree of separation of the several parts are subject to variation. A slip of the lower oblique part is sometimes inserted into the head of the first rib, or a fasciculus may be continued into the rectus capitis anticus major.

The *transversalis cervicis anticus* is a muscle arising from the front of the transverse processes of some of the cervical vertebræ from the fourth to the seventh, and inserted into one or more of the first three.

**Nerves.**—The rectus anticus minor and rectus lateralis are supplied by branches from the first cervical nerve; the scaleni and long prevertebral muscles receive branches from the adjacent cervical nerves.

**Actions.**—The *scalene* muscles, acting from their vertebral attachments, are elevators of the upper ribs, and thus come into play in the movement of inspiration, contracting forcibly in laboured breathing, while in tranquil respiration a moderate degree of action suffices to fix the first rib and support the lung where it projects through the upper aperture of the thorax. Taking their fixed point at the ribs they act as lateral flexors of the neck, and the muscles of the two sides acting together (especially the anterior scaleni) can bend the neck forwards. The *recti antici* are flexors of the head on the spine, and the *rectus lateralis* can only bend the head to the side. The *longus colli* is chiefly a flexor of the neck, but its upper and lower oblique parts may produce a certain amount of rotation.

#### IV.—THE MUSCLES AND FASCIÆ OF THE TRUNK.

The muscles passing between the trunk and the upper limb having been already described, those which belong exclusively to the trunk itself will now be treated of under the three heads of, 1. Dorsal muscles; 2. Thoracic muscles, including the diaphragm; and 3. Abdominal and Perineal muscles.

##### DORSAL MUSCLES AND FASCIÆ.

The muscles to be described under the above head, taken as a whole, occupy the hollow between the line of vertebral spines and the prominences formed by the mastoid process, the cervical transverse processes, the most projecting parts of the

ribs, and the crest of the ilium; and they extend from the superior curved line of the occipital bone to the lower part of the sacrum. Some of them are small and are limited to certain parts of the extensive region now referred to; others extend, either continuously or by the serial repetition of similar short fasciculi, throughout the greater part of it. They may be arranged for purposes of description, according to the order in which they occur, in the following groups, viz., *a*, the posterior serrati muscles; *b*, the splenius; *c*, the erector spinæ; *d*, the complexus and transverso-spinales; *e*, the interspinales and intertransversales; *f*, the short cranio-vertebral muscles. Of these muscles the serrati act solely on the ribs and are closely related to the thoracic muscles, although from their position they are most conveniently described in this place. The remainder act on the spinal column and head, and considered with regard to the direction of their fibres fall into three main

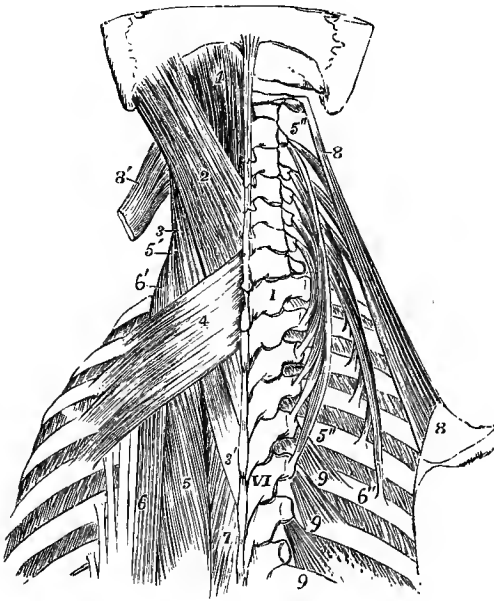


Fig. 284.—DORSAL MUSCLES OF THE UPPER PART OF THE TRUNK. (Allen Thomson.) 4

I, first, VI, sixth dorsal vertebra; 1, upper part of the complexus muscle; 2, splenius capitis; 3, 3', splenius colli; 4, serratus posticus superior; 5, upper part of longissimus dorsi; 5', the same continued up on the left side into the transversalis cervicis; 5'', 5''', on the right side, the transversalis cervicis spread out from its attachments; 6, upper insertions of ilio-costalis and accessorius; 6', the same continued up on the left side into the cervicalis ascendens; 6'', lower end of the latter muscle of the right side showing its attachments; 7, small part of spinalis dorsi; 8, 8, right levator scapulae; 8', on the left side, its upper part divided; 9, 9, 9, levatores costarum on the right side.

divisions. In the first division (splenius) the muscular fibres are directed obliquely upwards and outwards, or from spinous to transverse processes; in the second (transverso-spinales and complexus) the fibres pass obliquely upwards and inwards, or from transverse to spinous processes; in the third the fibres run longitudinally between corresponding parts of the vertebrae or ribs, being either of considerable length and passing over several segments (erector spinæ), or short and attached to adjacent vertebrae (interspinales and intertransversales). The short cranio-vertebral muscles may be regarded as presenting examples of each of these divisions.

**SERRATI MUSCLES.**—The **serratus posticus superior** is a thin flat muscle which is covered, excepting at its upper border, by the rhomboid and levator anguli scapulae muscles. It arises from the lower part of the ligamentum nuchæ, from the spines of the last cervical and two or three upper dorsal vertebrae, and from the supraspinous ligament, by a thin aponeurotic tendon forming nearly half of the length of the muscle. The fibres are directed obliquely downwards and outwards, and form four fleshy digitations which are inserted by tendinous extremities into the upper borders and outer surfaces of the second, third, fourth and fifth ribs, a little beyond their angles.

**Varieties.**—The slips are sometimes only three in number; or less frequently there are five or even six. In very rare cases absence of the muscle has been observed.

The **serratus posticus inferior** (fig. 227, p. 207), broader and stronger than the superior, arises from the spines of the lower two dorsal and upper two or three lumbar vertebræ, by a thin aponeurotic membrane which forms part of the posterior layer of the lumbar aponeurosis, and is closely united to the overlying tendon of the latissimus dorsi. Passing outwards, upwards and forwards, it is inserted by four fleshy digitations into the lower borders of the last four ribs. The fleshy digitations are shorter than the aponeurotic part of the muscle, and they overlap one another from above downwards. The last slip varies in size with the length of the twelfth rib, and is often entirely concealed by the one above it.

**Varieties.**—Absence of the first or last digitation is frequently seen; of the whole muscle very rarely.

**Nerves.**—The serrati muscles are supplied by the intercostal nerves, each slip receiving a small branch which perforates the external intercostal muscle upon which it lies.

**Actions.**—The serratus posticus superior elevates the upper ribs, and is therefore a muscle of inspiration. The serratus inferior draws the lower ribs downwards, and, to a greater extent, backwards (see p. 162), and is also a muscle of inspiration, enlarging the lower part of the chest, and at the same time resisting the tendency of the diaphragm to draw the lower ribs upwards and forwards.

**DORSAL AND LUMBAR FASCIÆ.**—The **vertebral aponeurosis** is situated on the same plane as the serratus posticus inferior, and consists of a thin lamella which separates the muscles belonging to the shoulder and arm from those which support the spine and head. Its fibres are for the most part transverse, a few only being longitudinal. Above, it passes beneath the superior serratus; below, it is blended with the tendons of the latissimus and inferior serratus muscles; and in being stretched from the spinous processes outwards to the angles of the ribs, it helps to enclose the angular space in which are lodged the long extensor muscles.

The transverse fibres of the vertebral aponeurosis represent the middle portion of the muscular sheet of the serrati, the whole forming a continuous muscle in some of the lower animals (Gegenbaur).

Under the name of **lumbar fascia** or **aponeurosis** it has been customary to describe three membranous layers ensheathing the erector spinæ and quadratus lumborum muscles. The deeper parts of this structure, to which by some the name of lumbar fascia is restricted, are described along with the abdominal muscles, with which they are chiefly connected (pp. 333 and 337). The *superficial* or *posterior layer* (fig. 293, 10) is that through which the latissimus dorsi and serratus posticus inferior muscles are attached to the spines of the vertebræ. This layer is of considerable strength, and extending outwards beyond the line along which the latissimus becomes free from it, inclines forwards to join the middle layer, thus binding down firmly the erector spinæ muscle: it is by some described as the lower part of the vertebral aponeurosis, with which it is continuous, by others it has been named the aponeurosis of the latissimus dorsi.

The **SPLENIUS** muscle is so named from its having the form of a strap, which binds down the parts lying under it. It is attached superiorly in part to the cervical vertebræ, in part to the skull, and is described accordingly under two names.

*a.* The **splenius colli** is attached inferiorly to the spinous processes of the third, fourth, fifth and sixth dorsal vertebræ, and superiorly along with the slips of the levator anguli scapulæ to the transverse processes of the first two or three cervical vertebræ.

*b.* The **splenius capitis**, broader and thicker than the preceding, arises from the spines of the seventh cervical and upper two dorsal vertebræ, and from the ligamentum nuchæ as high as the third cervical vertebra. It is inserted into the lower part of the mastoid process, and into the outer part of the superior curved line of the occipital bone.

**Relations.**—The splenius is covered below and internally by the trapezius, the rhomboids and the serratus posticus superior; and at its insertions by the sterno-mastoid and levator anguli scapulæ: between these the splenius capitis is exposed in the posterior triangular space. The muscle conceals, in part, the spinalis dorsi, the complexus and the trachelo-mastoid. The splenius represents the prolongation to the head and upper cervical vertebræ of the outer division of the erector spinæ.

**Varieties.**—The origin of the splenius is frequently moved upwards to the extent of one or two vertebræ. Absence of the splenius colli has been observed in a negro (Testut). The *rhombo-atloideus* or *splenius colli accessorius* is a muscular slip occasionally present, arising from one or two lower cervical or upper dorsal spines, superficial to the serratus posticus superior, and inserted into the transverse process of the atlas. The name *splenius capitis accessorius* may be given to a similar slip ending on the occipital bone or the mastoid process.

**ERECTOR SPINÆ.**—This is a large composite muscle, extending throughout the whole length of the back from the pelvis to the head, and divided for purposes of description into seven parts, to which distinct names are applied. Commencing below as a common mass, it is continued upwards in three columns, of which the innermost, *spinalis dorsi*, is comparatively slender and short, while the other two are much thicker, and are again subdivided each into three portions, viz., in the outer column, *ilio-costalis*, *accessorius*, and *cervicalis ascendens*, and in the middle column, *longissimus dorsi*, *transversalis cervicis*, and *trachelo-mastoid*.

The origin of the erector spinæ takes place mainly by means of a strong flattened tendon, which is attached to the lowest two or three dorsal and all the lumbar and sacral spines, to the posterior fifth of the iliac crest, and to the lower and back part of the sacrum, as well as to the ligaments uniting that bone to the coccyx. This tendon becomes blended below with the overlying layer of the lumbar fascia; its deep surface gives origin also to some fibres of the multifidus spinæ; and between the iliac and sacral attachments a part of the gluteus maximus arises from its border. The fasciculi of which it is composed pass nearly vertically upwards, the outer ones, above the iliac crest, being very short, while the inner ones ascend by the side of the spines to the middle of the dorsal region. The fleshy fibres of the muscle are derived mostly from the oblique upper border and the deep surface of the tendon, but others spring directly from the rough posterior part of the inner surface of the ilium, beneath and outside the attachment of the tendon. The lower part of the muscle forms a large mass which projects backwards beyond the spines, and laterally beyond the transverse processes of the lumbar vertebræ, and which becomes divided below the level of the last rib into the middle and outer columns. The inner column only separates itself from the middle column in the upper dorsal region.

*a.* The **ilio-costalis** or **sacro-lumbalis**, the first portion of the outer column, is continued from the outer and superficial portion of the common mass. It ends in a series of tendons which incline slightly outwards, and are inserted one into each of the lower six or seven ribs at their angles; a slender fasciculus is usually prolonged also into the accessorius, and contributes to the formation of the lower two or three tendons of insertion of that muscle.

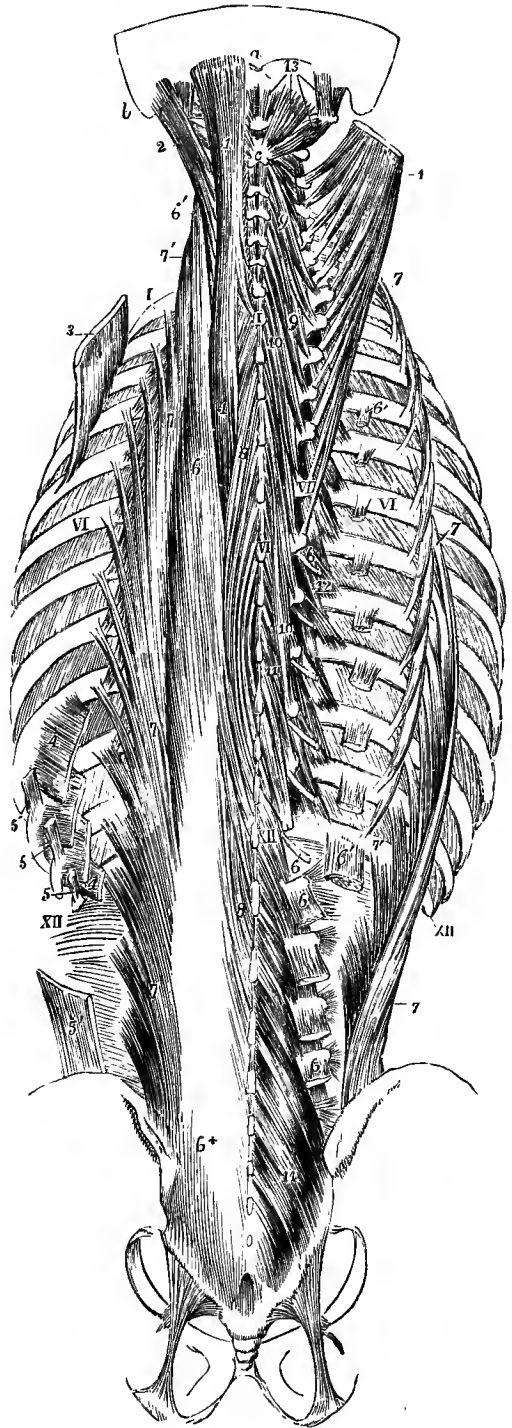
*b.* The **musculus accessorius ad ilio-costalem** (ad sacro-lumbalem) prolongs upwards the preceding muscle. It arises by flat tendons from the upper margins of the lower six ribs, internal to the tendons of the ilio-costalis, and ends above by continuing the series of those tendons to the angles of the upper ribs, and to the transverse process of the seventh cervical vertebra.

*c.* The **cervicalis ascendens** consists of slips in serial continuation with the foregoing, taking origin from four or five ribs above the accessorius, and inserted into the posterior tubercles of the transverse processes of the fourth, fifth, and sixth cervical vertebræ. Its insertions are intimately connected with those of the transversalis cervicis.

*d.* The **longissimus dorsi** is both larger and longer than the ilio-costalis, its

Fig. 285.—DEEP MUSCLES OF THE BACK.  
(Allen Thomson.)  $\frac{1}{2}$

On the left side the several parts of the erector spinæ are nearly in their natural position, with the exception of the spinalis dorsi, which is drawn out from the spines of the vertebræ; on the right side the spinalis dorsi has been entirely removed, the ilio-costalis drawn to the outer side so as to expose its accessory muscle, and the longissimus removed, excepting small portions at its insertions. Superiorly on the left side, the trachelo-mastoid and complexus are left nearly in their natural positions; while on the right side, the trachelo-mastoid has been entirely removed, and the complexus, separated from its occipital attachment, has been spread out so as to stretch its vertebral attachments. *a*, external occipital protuberance; *b*, mastoid process; *c*, spine of axis; I, I, spine of first dorsal vertebra and first rib; VI, VI, VI, sixth dorsal spine and transverse process and sixth ribs; XII, XII, twelfth dorsal spine and twelfth ribs. *On the left side*, 1, complexus; 2, trachelo-mastoid; 3, serratus posticus superior, detached from the spine and drawn upwards from the ribs; 4, 4, slips of attachment of serratus posticus inferior to lowest four ribs; 5, 5, 5, costal, and 5', iliac origins of the latissimus dorsi; 6 +, tendon of origin of erector spinæ; 6, upper part of longissimus dorsi; 6', transversalis cervicis continued up from longissimus; 7, ilio-costalis drawn slightly inwards to show the slips of insertion into the ribs; inside the costal insertions are seen the origins of the accessorius; 7', cervicalis ascendens continued upwards from accessorius; 8, spinalis dorsi. *On the right side*, 6, marks, in the lumbar region, the insertions of the longissimus dorsi into the upper four transverse processes (the insertion into the accessory processes not being shown); in the dorsal region the narrower tendons of insertion into the lower part of the dorsal transverse processes (the six lower only are represented); 6', 6', the costal insertions; 7, ilio-costalis, drawn outwards; 7', placed between lowest insertion of ilio-costalis and lowest origin of accessorius; 7'', cervicalis ascendens; 9, 9, semispinalis colli; 10, 10, semispinalis dorsi; 11, 11, lower dorsal and lumbar parts of the multifidus spinæ, which appears again above the semispinalis colli, above the upper 9; 12, levatores costarum, long and short; 13, in the upper part of the figure, points by four lines to the rectus capitis posticus minor and major, and the obliquus inferior and superior muscles.



original fibres passing as high as the first dorsal vertebra. Internally it is closely connected on the surface with the spinalis dorsi, the tendinous slips springing from the upper

two or three lumbar vertebræ being common to the two muscles. When those slips and the tendons of origin from the lower lumbar spines are cut through the inner surface of the muscle is brought into view, and it is then usually seen to receive from two to four slender accessory tendons from the lower dorsal transverse processes. The longissimus dorsi presents two series of insertions. The inner row of insertions is a series of rounded tendons attached to the transverse processes of all the dorsal, and the accessory processes of the lumbar vertebræ. The outer insertions form a series of thin fleshy processes which are attached in the dorsal region to the lowest nine or ten ribs, between their tuberosities and angles, and in the lumbar region to the whole length of the transverse processes, and beyond these to the lumbar fascia connected with them.

*e.* The **transversalis cervicis** muscle prolongs upwards the column of fibres of the longissimus dorsi. It arises from the transverse processes of the highest four or five dorsal vertebræ, and occasionally the last cervical, and is inserted into the posterior tubercles of the transverse processes of five cervical vertebræ, from the second to the sixth inclusive. It generally receives a slip of the original fibres of the longissimus dorsi.

*f.* The **trachelo-mastoid** muscle (*transversalis capitis*), which may be regarded as the continuation of the longissimus dorsi to the head, arises in close connection with the transversalis cervicis from the upper dorsal transverse processes, and also from the articular processes of the lower three or four cervical vertebræ, and, forming a thin flat muscle, passes to be inserted into the posterior margin of the mastoid process, under cover of the splenius and sterno-mastoid muscles. It is usually crossed by a tendinous intersection a little below its insertion.

*g.* The **spinalis dorsi** is a long narrow muscle placed at the inner side of and closely connected with the longissimus dorsi. It receives the slender tendinous fasciculi from the lowest two or three dorsal spines, and other fleshy fibres spring from the tendons which pass from the upper lumbar spines into the longissimus. Its insertion takes place into a variable number, from four to nine, of the upper dorsal spines, the slips being closely adherent to those of the subjacent semispinalis muscle.

**Varieties.**—The slips of the longissimus dorsi arising from the lower dorsal transverse processes may be more independent than usual, forming a small muscle with an insertion into the transverse processes of the highest two or three dorsal vertebræ—the *transversalis dorsi* of J. Müller and Luschka.

The *spinalis cervicis* is an inconstant muscle, arising variably from the ligamentum nuchæ and the seventh cervical spine, or from one or two spines above or below this, and inserted mainly into the spine of the axis, occasionally also into those of the third and fourth cervical vertebræ.

The *sacro-coccygeus posticus*, or *extensor coccygis*, is a thin muscular slip occasionally, although rarely, found extending from the lower end of the sacrum to the coccyx, and representing the extensor of the caudal vertebræ of the lower animals. (F. H. Jacobi, "Beitrag zur Anatomie der Steissbeinmuskulatur des Menschen," Arch. f. Anat., 1888.)

**COMPLEXUS AND TRANSVERSO-SPINALES.**—The muscles of this group, comprising the complexus, semispinalis, multifidus spinæ, and rotatores dorsi, present the feature in common of ascending with an inward inclination, and are thus distinguished from those last described. The most superficial, the complexus, has the longest and most vertical fibres, but is the shortest in its whole extent, being limited to the upper part of the dorsal and the cervical regions; the muscle beneath it, the semispinalis, occupies the greater part of both those regions; the multifidus spinæ, still more deeply placed, extends from the sacrum to the axis; and the rotatores dorsi, the deepest of all, are confined to the thoracic region.

The **complexus** muscle (*semispinalis capitis*) arises by tendinous slips from the transverse processes of the upper six or seven dorsal and the last cervical vertebræ,

and from the articular processes of the three and sometimes four succeeding cervical vertebræ, together with the capsular ligaments uniting them; it is also frequently joined by one or two slender fasciculi from the lowest cervical or highest dorsal spines. It is inserted into the large internal impression between the two curved lines of the occipital bone. It is narrower above than below, and its inner margin in the neck is in contact with the ligamentum nuchæ. An irregular, commonly imperfect, tendinous intersection crosses the muscle about the level of the spine of the axis; and lower down, another longer one interrupts the fibres of the inner portion of the muscle, which is more or less separate from the rest, and is hence sometimes described independently under the name of *biventer cervicis*.

**Relations.**—The complexus muscle is covered by the splenius, except at its lowest origins from the dorsal vertebræ and at the internal portion of its upper extremity; the trachelomastoid and transversalis cervicis rest upon its series of origins; and the semispinalis colli, the posterior recti, and the obliqui capitis, together with the deep cervical vessels, are concealed by it.

The **semispinalis** muscle consists of bundles of fibres extending from transverse processes to spines, and crossing over from four to six vertebræ. It is described in two parts.

*a.* The *semispinalis colli* is the part under cover of the complexus. It arises from the upper five or six dorsal transverse processes, and is inserted into the spines of the cervical vertebræ from the second to the fifth inclusive, being thickest at its insertion into the second vertebra.

*b.* The *semispinalis dorsi* consists of narrow muscular bundles interposed between tendons of considerable length, and forms an elongated thin stratum, especially towards its lower border. It arises from the transverse processes of the dorsal vertebræ from the sixth to the tenth inclusive, and is inserted into the last two cervical and from four to six upper dorsal spines.

The **multifidus spinæ** muscle occupies the vertebral groove by the side of the row of spinous processes, reaching from the sacrum to the axis, and passing up under cover of the semispinalis. It is more largely developed towards the lower than at the upper end of the column, and is thinnest in the dorsal region. In the sacral region the fibres arise from the deep surface of the tendinous origin of the erector spinæ, from the groove on the back of the sacrum as low as the fourth foramen, from the inner part of the posterior extremity of the ilium, and from the posterior sacro-iliac ligament; in the lumbar region they take origin from the mamillary processes; in the dorsal region from the transverse processes; and in the neck from the articular processes of the four lower cervical vertebræ. From these several points the muscular bundles ascend obliquely, to be inserted into the spines of the vertebræ, from their bases to their extremities. The fibres from each point of origin are fixed to several vertebræ, some being inserted into the side of the spinous process next but one above, and others ascending more and more vertically as high as the fourth from the place of origin, the longer fibres from one origin overlapping those from the origin next above.

The **rotatores dorsi** are eleven small muscles on each side, which may be regarded as the deepest fibres of the multifidus spinæ in the dorsal region, and are distinguished by being more nearly horizontal than the rest. Each arises from the upper and back part of the transverse process of one vertebra, and is inserted into the inferior margin of the lamina of the vertebra next above.

**Varieties.**—The highest one or two, or the lowest of the rotator muscles may be wanting. Similar small slips between adjacent vertebræ, but more longitudinal in direction, are occasionally present in the cervical and lumbar regions. The *rotatores longi* of Henle are inconstant slips passing from the transverse process of one dorsal vertebra to the root of the spine of the second, or even the third vertebra above.

**INTERSPINALES AND INTERTRANSVERSALES.**—The **interspinales** are short vertical fasciculi of fleshy fibres, placed in pairs between the spinous processes of contiguous vertebræ. In the neck, from the axis downwards, they are roundish bundles attached to the two parts into which the spinous processes are divided. In the dorsal region they are for the most part absent, a few fibres only being present in one or two of the highest and lowest spaces. In the loins they are flattened bands, one on each side of the interspinous ligament, and extending the whole length of the spinous processes.

**Variety.**—Longer interspinous bundles are sometimes found in the neck passing over one or two vertebræ, and forming a transition to the spinalis cervicis muscle already described.

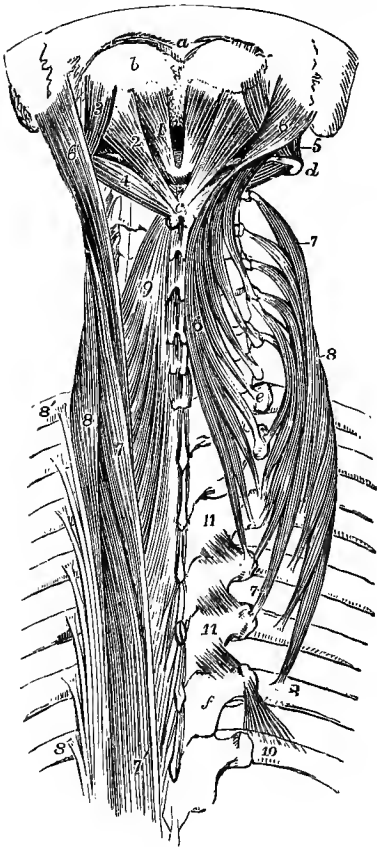


Fig. 286.—DEEP POSTERIOR MUSCLES OF THE UPPER PART OF THE VERTEBRAL COLUMN. (Allen Thomson.)  $\frac{1}{2}$

*a*, external occipital protuberance; *b*, surface between the superior and inferior curved lines into which the complexus is inserted; *c*, spine of axis; *d*, transverse process of atlas; *e*, transverse process of first dorsal vertebra; *f*, lamina of sixth dorsal vertebra; 1, rectus capitis posterior minor muscle; 2, rectus posterior major; 3, obliquus superior; 4, obliquus inferior; 5, rectus capitis lateralis; 6, 6, trachelo-mastoid, the muscle of the right side turned inwards and its slips of origin from the dorsal and cervical vertebræ separated from each other; 7, 7, transversalis cervicis, the figures are placed near the extreme ends of the muscle on the right side; 7', on the left side, longissimus dorsi; 8, 8, cervicalis ascendens, the muscle of the right side is spread out; 8', 8', on the left side, tendinous insertions of the iliocostalis and accessorius colli of the left side; 9, upper part of the semispinalis colli of the left side; 10, placed on the seventh rib of the right side close to the insertion of its levator costæ muscle; 11, 11, three rotatores dorsi.

The **intertransversales** are short muscles passing nearly vertically from vertebra to vertebra between the transverse processes. In the cervical region there are two rounded fleshy bundles below each transverse process, the one descending from the anterior, the other from the posterior part of the process. In the dorsal region there are small fleshy bundles in the lowest three or four spaces; in the middle spaces they are replaced by small tendinous bands which constitute the so-called intertransverse ligaments; and in the upper spaces they are usually altogether

wanting. In the lumbar region there are again two sets: one set, the *intertransversales laterales*, lie between the transverse processes; the other set, *intertransversales mediales* or *interaccessorii*, pass from the accessory process of one vertebra to the mamillary process of the next.

The posterior intertransversales of the neck and the mesial intertransversales of the loins are in series with the rudimentary thoracic muscles, and belong to the dorsal musculature. The anterior cervical muscles with the scaleni, and the lateral lumbar muscles with the quadratus lumborum correspond to the levatores costarum and intercostal muscles of the thoracic region.

**SHORT POSTERIOR CRANIO-VERTEBRAL OR SUBOCCIPITAL MUSCLES.**—The **rectus**



**capitis posticus major** muscle arises by a narrow tendon from the spinous process of the axis, and expanding as it passes upwards and outwards, is inserted into and below the outer part of the inferior curved line of the occipital bone. Its insertion is inside and beneath that of the superior oblique muscle.

The **rectus capitis posticus minor** muscle arises from the posterior arch of the atlas by the side of the tubercle, and expands as it passes upwards to be inserted into the inner third of the inferior curved line of the occipital bone, and the depression between that and the foramen magnum.

The **obliquus capitis inferior**, the strongest of the muscles now under consideration, arises from the spinous process of the axis, between the origin of the rectus posticus major and the insertion of the semispinalis colli, and is inserted into the lower and back part of the transverse process of the atlas.

The **obliquus capitis superior**, smaller than the preceding muscle, arises from the upper surface of the transverse process of the atlas, thence inclines obliquely upwards and backwards, increasing in breadth as it ascends, and is inserted into an impression between the outer parts of the curved lines of the occipital bone.

**Relations.**—The two oblique muscles with the rectus major form the sides of a small triangular space—the *suboccipital triangle*, in the area of which the posterior primary branch of the suboccipital nerve and the vertebral artery are found.

**Varieties of the suboccipital muscles.**—Longitudinal division or doubling of the rectus posticus major or minor is not unfrequent; doubling of the oblique muscles is less common. Accessory slips are sometimes found passing in continuation of the spinalis cervicis from the spines of one or two of the cervical vertebrae and the ligamentum nuchæ to the occipital bone. The *atlanto-mastoid* is a small muscle often present, arising from the transverse process of the atlas between the obliquus superior and rectus lateralis, and inserted into the hinder part of the mastoid process. A supernumerary muscle has also been seen passing from the spine of the axis to the mastoid process.

**Nerves.**—All the muscles of the back which act upon the head and spine, viz., the splenius, erector spinæ, complexus, and the muscles more deeply seated are supplied by the posterior primary branches of the spinal nerves.

**Actions of the dorsal spinal and cranial muscles.**—In extending the spinal column and head not only the *erector spinæ*, but all the muscles of this group come into play, necessarily acting simultaneously on both sides. Acting on one side alone they produce the lateral flexion of the column. While the action of the longitudinally directed muscles is limited to these movements, the oblique muscles are farther enabled to rotate the head and spinal column. Thus, when the *splenius* of one side acts it rotates the head and neck to the same side, while the *complicatus* and *transverso-spinales* rotate the head and spine to the opposite side. The power of the extensor muscles to straighten the back from the flexed condition, as measured by the muscular dynamometer, varies in adults of medium strength from 200lbs. to 400lbs. A certain amount of extension of the spine, as will be hereafter explained, accompanies inspiration; but if the spine be fixed, some of the erector muscles may, by their costal attachments, depress the ribs, and thus assist in forced expiration.

Of the short cranio-vertebral muscles, two—the *rectus minor* and *superior oblique*—act principally by drawing the head backwards, that being the chief movement allowed between the atlas and occipital bone; while the principal action of the *rectus posticus major* and the *inferior oblique*, when acting on one side, is to rotate the atlas and skull upon the axis, the former muscle also assisting in the extension of the head.

#### THE MUSCLES OF THE THORAX.

The muscles of the thoracic wall are the intercostals, levatores costarum, subcostals, and triangulæ sterni, and along with these the diaphragm intervening between the thorax and abdomen may conveniently be grouped.

The INTERCOSTAL MUSCLES consist of two thin layers of short oblique fibres occupying the intercostal spaces: these layers are named respectively the external and internal muscles.

The **external intercostal** muscles are stronger than the internal, and thicker behind than in front. Their fibres are intermixed with a considerable quantity of

tendinous substance, and are directed obliquely downwards and forwards from the prominent lower margin of one rib to the upper border of the next. The extent of these muscles is generally from the tuberosities of the ribs to the outer ends of the cartilages; but in the upper three or four spaces they do not quite reach the ends of the ribs, while in the last two intervals they are continued forwards along the lower cartilages. Beyond the points at which the muscles cease the spaces are occupied by the *anterior intercostal aponeuroses*, thin shining membranes, composed of fibres having the same direction as those of the external intercostal muscles with which they are continuous externally, and covering the fore parts of the internal intercostals.

**Variety.**—The *supracostalis* is a muscular slip occasionally seen, passing from the anterior end of the first rib downwards to the fourth, sometimes also to the second and third ribs. It has been found connected above with the deep fascia of the neck, or with the scaleni muscles.

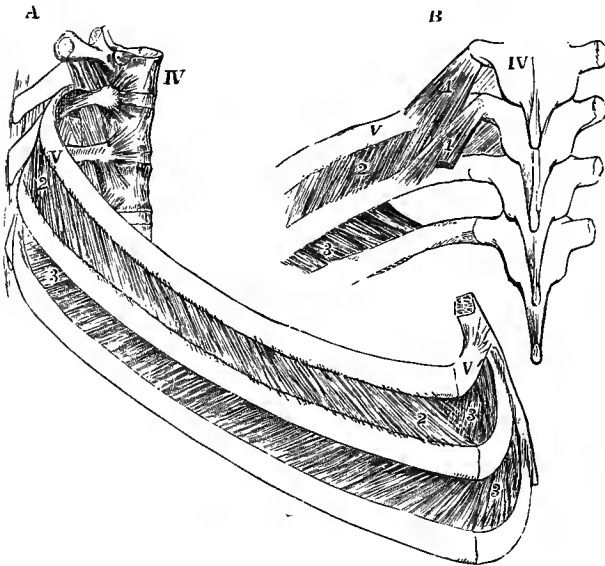


Fig. 287.—INTERCOSTAL MUSCLES OF THE FIFTH AND SIXTH SPACES. (Allen Thomson, after Cloquet.)

A, from the side; B, from behind.

IV, fourth dorsal vertebra; V, V, fifth rib and cartilage; 1, 1, levatores costarum muscles, short and long; 2, 2, external intercostal muscle; 3, 3, internal intercostal layer, shown in the lower space by the removal of the external layer, and seen in A in the upper space, in front of the external layer: the deficiency of the internal layer towards the vertebral column is shown in B.

The **internal intercostal** muscles, thicker in front than behind, consist of fibres which

incline downwards and backwards, but are somewhat shorter and less oblique than those of the external muscles. Their attachments take place on the inner surfaces of the ribs, the upper one being situated immediately above the subcostal groove, the lower one near the upper margin of the bone. Anteriorly they reach to the sternal ends of the costal cartilages, and in the last two spaces they become continuous with the internal oblique muscle of the abdomen: posteriorly they extend as far as, or sometimes, especially in the upper spaces, slightly beyond the angles of the ribs. Where the internal intercostals are deficient behind the inner surface of each external intercostal is lined by the *posterior intercostal aponeurosis*, a membranous layer which is continuous internally with the anterior superior costo-transverse ligament, and externally is prolonged into a thin fascia between the two intercostal muscles.

**Relations.**—The internal are separated from the external intercostal muscles at the back of the spaces by the intercostal vessels and nerves: they are lined internally by the pleura and subpleural tissue (*endothoracic fascia*).

The **levatores costarum**, twelve on each side, arise from the tips of the transverse processes of the seventh cervical and the upper eleven dorsal vertebrae.

Corresponding in direction with the external intercostal muscles, into which they are continued at their outer borders, they pass downwards and outwards, spreading as they descend, and each is inserted into the outer surface of the rib belonging to the vertebra below that from which it springs, between the tuberosity and angle. The levator muscles belonging to the lower ribs present some longer additional fibres which, passing over a rib, are inserted into the next one below; these fibres are sometimes distinguished as *levatores costarum longiores*.

The levatores costarum lie in-series superiorly with the middle and posterior scaleni, and inferiorly with parts of the lateral lumbar intertransverse muscles.

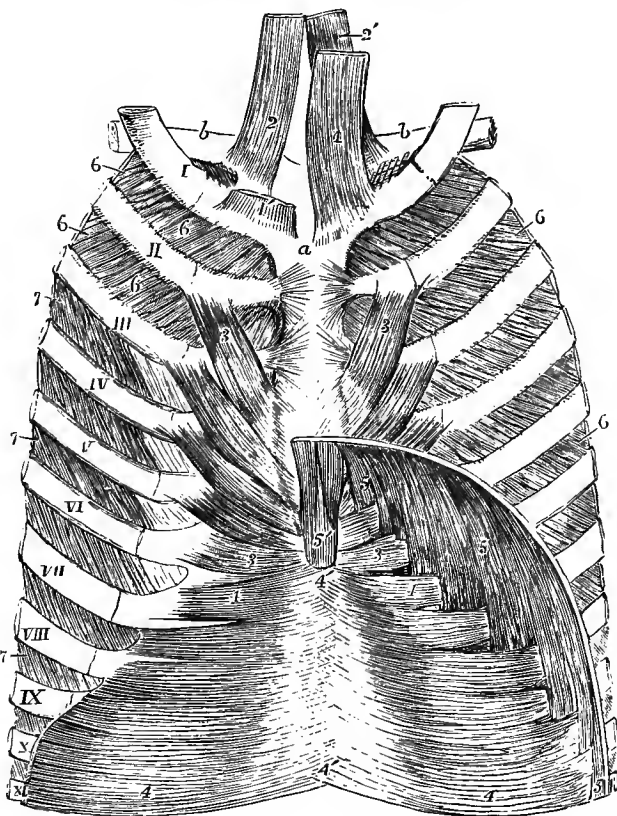


Fig. 288.—DEEP MUSCLES OF THE ANTERIOR WALL OF THE THORAX, SEEN FROM BEHIND.  
(Allen Thomson, after Luschka.)  $\frac{1}{2}$

*a*, back of manubrium; *b, b*, clavicles; I to XI, anterior parts of eleven ribs and costal cartilages; 1, 1', sterno-thyroid muscles, that of the left side being cut short to show more fully the next muscle; 2, 2', sterno-hyoids; 3, 3, triangularis sterni; 4, 4, upper part of transversalis abdominis, the right and left muscles meeting at 4', 4', the back of the linea alba; 5, attachments of diaphragm to the lower ribs (the twelfth not represented in the figure), interdigitating with those of the transversalis; 5', the two slips to the ensiform process; 6, 6, 6, internal intercostal muscles extending to the sternum, shown in all the spaces on the right side, but only in the highest two of the left side; 7, 7, 7, in the lower spaces of the left side, the external intercostal muscles are seen, the internal having been removed.

The **subcostal** muscles (transversus thoracis posterior; fig. 289, 10) are small, very variable slips lying on the inner aspect of the thoracic wall, in close connection with the internal intercostals, and chiefly in the neighbourhood of the angles of the ribs. They follow the same direction as the internal intercostal muscles, but their

fibres extend over one or two intercostal spaces. They are most constant on the lower ribs.

The **triangularis sterni** (transversus thoracis anterior), a thin stratum of muscular and tendinous fibres placed within the thorax, behind the costal cartilages, arises from the deep surface of the ensiform process and lower part of the body of the sternum, and from the cartilages of two or three of the lower true ribs. Its fibres pass outwards and upwards in a diverging manner, the lowest being horizontal, the middle oblique, and the upper becoming more and more nearly vertical; they are inserted by separate slips into the outer parts of the cartilages of the ribs, sometimes also into the bones, from the sixth to the second inclusive, on the lower border and inner surface of each. At the lower margin the fibres are in the same plane with those of the transversalis abdominis, of which the triangularis sterni muscle is a continuation upwards.

**Relations.**—The internal mammary vessels pass between its anterior surface and the costal cartilages: its deep surface is in contact with the pleura, and on the left side also with the pericardium.

**Varieties.**—The triangularis sterni is subject to much variation as to its extent and points of attachment in different bodies, and even on the opposite sides of the same body. Occasionally it is prolonged to the first rib. Absence on one or both sides has been recorded.

#### THE DIAPHRAGM.

The **diaphragm**, or **midriff**, forms a musculo-tendinous partition between the abdominal and thoracic cavities. It consists of fleshy fibres which arch upwards

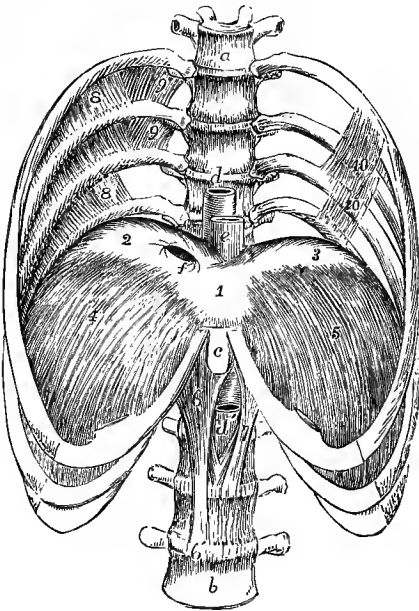


Fig. 289.—THE LOWER HALF OF THE THORAX, WITH FOUR LUMBAR VERTEBRÆ, SHOWING THE DIAPHRAGM FROM BEFORE. (Allen Thomson, after Luschka.) †

*a*, sixth dorsal vertebra; *b*, fourth lumbar vertebra; *c*, ensiform process; *d, d'*, aorta, passing through its opening in the diaphragm; *e*, oesophagus; *f*, opening in the tendon of the diaphragm for the inferior vena cava; 1, central, 2, right, and 3, left division of the trefoil tendon of the diaphragm; 4, right, and 5, left costal part, ascending from the ribs to the margins of the tendon; 6, right, and 7, left crus; 8, to 8, on the right side, the sixth, seventh, and eighth internal intercostal muscles, deficient towards the vertebral column, where in the two upper spaces the levatores costarum and the external intercostal muscles 9, 9, are seen; 10, 10, on the left side, subcostal muscles.

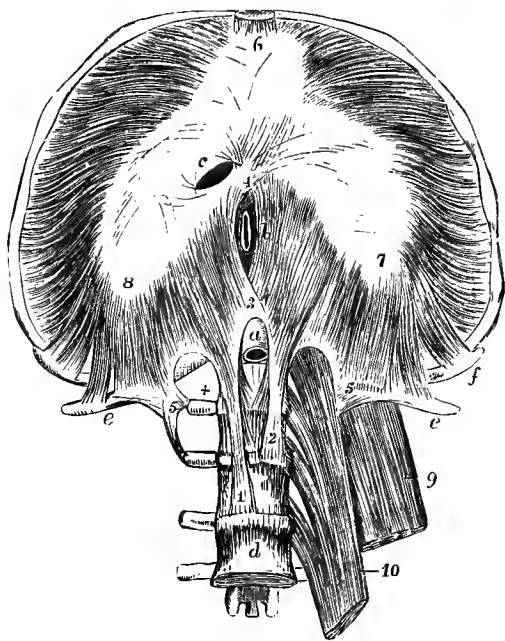
as they converge from the circumference of the visceral cavity to an aponeurotic tendon in the centre, and it is perforated by the various structures which pass from the thorax to the abdomen.

According to the mode of origin and arrangement of its fibres the diaphragm is divided into:—a *vertebral* portion, arising posteriorly from the lumbar vertebræ by two thick processes or *crura*, and from two fibrous bands on each side external to the bodies of the vertebræ, called *arched ligaments*; a *costal* portion on each side, arising from the cartilages of the lower six ribs; and a *sternal* portion, arising anteriorly from the back of the ensiform process.

The *crura* or *pillars* arise by tendinous fibres, intimately connected with the anterior common ligament, from the upper three or four lumbar vertebræ and the interposed discs on the right side, and from the first and second vertebræ and adjoining discs on the left side. The tendinous portions of the *crura* are continued higher internally than externally, and curving forwards and inwards join in the middle line so as to form an arch over the front of the aorta; while inferiorly their inner margins frequently meet behind that vessel, which is thus enclosed in an oval fibrous loop or ring. The muscular fibres of the *crura*, springing from the tendons in thick bundles, diverge as they pass upwards to the concave posterior margin of the central aponeurosis. The innermost fibres of the two pillars decussate in front of the aortic opening, and pass up on opposite sides of the œsophagus, for

Fig. 290.—THE DIAPHRAGM, FROM BELOW. (Allen Thomson.)  $\frac{1}{2}$

The lower ribs and sternum are drawn upwards so as to expose and stretch the lower surface of the diaphragm, and the four upper lumbar vertebræ have been exposed by the removal of all the muscles on the right side, and the dissection of the *psoas magnus* and *quadratus lumborum* on the left side. *a*, aorta, emerging from between the pillars on the first lumbar vertebra; *b*, œsophagus, in its aperture between the muscular fibres, represented too far to the right; *c*, aperture for the inferior vena cava, situated at the place of union of the middle and right divisions of the trefoil tendon; *d*, fourth lumbar vertebra; *e, e*, twelfth ribs; *f, f*, eleventh ribs; 1, tendinous part of the right crus; 2, the left; 3, tendinous arch formed by their union over the aorta, above which the decussation of the muscular fibres is seen; 4, second decussation of muscular fibres in front of the œsophageal opening; 5, on the right side, the attachment of the arched ligaments to the first and second lumbar transverse processes; from 5 to *e*, external arched ligament; +, is in the hollow of the internal arched ligament from which the *psoas* has been removed; 5, on the left side, external arched ligament; 6, middle division of the trefoil tendon, from which in front pass the slips of attachment of the diaphragm to the ensiform process; 7, left, and 8, right divisions of the trefoil tendon; from the outer and anterior margins of these the costal slips of the muscle are seen diverging, and from the posterior border of the tendon the slips of origin proceeding from the arched ligaments and the tendinous arch of the *crura*; 9, part of *quadratus lumborum*; 10, part of *psoas magnus*.



which they thus bound an elongated aperture, meeting and again decussating to some extent anteriorly as they join the tendon. In the first decussation the fasciculus derived from the right crus usually passes in front of that from the left, which is much smaller and not unfrequently is altogether wanting.

The *internal arched ligament* (ligamentum arcuatum internum) is a fibrous band which extends from the body to the transverse process of the first lumbar vertebra, and sometimes also to that of the second, and arches over the upper part of the *psoas* muscle. The *external arched ligament* (ligamentum arcuatum externum) extends outwards from the transverse process of the first lumbar vertebra to the last rib, arching over the front of the *quadratus lumborum*: it is the upper part of the fascia covering that muscle, somewhat increased in thickness. From both arched ligaments muscular fibres take origin, and are directed upwards to the lateral portion

of the posterior margin of the tendinous centre. It frequently happens that fleshy fibres spring only from the inner portion of the external arched ligament, and in that case a triangular interval is left between the vertebral and costal portions of the muscle, through which the areolar tissue of the thoracic cavity becomes continuous with that of the abdomen.

The *costal portion* of the muscle consists of a series of serrated slips arising from the cartilages of the six lower ribs, and interdigitating with the attachments of the transversalis abdominis muscle (fig. 288). They sometimes arise also in part from the osseous ribs. The *sternal portion* is a narrow slip, sometimes divided into two, separated on each side from the costal portion by an interval which gives passage to the epigastric division of the internal mammary vessels together with some lymphatics, and in which the lining membranes of the thorax and abdomen are separated only by a small quantity of loose connective tissue. The sternal fibres of the diaphragm are much the shortest; the fibres from the eighth and ninth rib-cartilages are the longest. The fibres of the sternal and costal slips, after being united, rise in an arched and converging manner to be inserted into the anterior and external margins of the central tendon.

The *central tendon*—*trefoil* or *cordiform tendon*—is a strong aponeurosis, forming the central and highest part of the diaphragm. It is elongated from side to side, convex in front and concave behind, and consists of three *lobes* or *alae*, partly separated by indentations. The right lobe is the largest; and the left, which is elongated and narrow, is the smallest of the three. The central tendon is surrounded on every side by the muscular portion of the diaphragm, the fibres of which are directly continuous with those of the tendon. The tendinous fibres cross one another, and are interwoven in various directions.

*Foramina.*—There are in the diaphragm three large perforations for the passage respectively of the aorta, the œsophagus, and the vena cava, besides some smaller holes or fissures which are less regular.—*a.* The foramen for the aorta (*hiatus aorticus*), placed in front of the first lumbar vertebra, is bounded by tendinous fibres of the crura as already described. Besides the aorta, this opening transmits the thoracic duct, and generally also the large azygos vein. *b.* The foramen for the œsophagus is opposite the tenth dorsal vertebra, and lies farther forward than, as well as a little to the left of the aortic opening, from which it is separated by the decussating fibres of the crura. It is oval in form, and is generally entirely surrounded by muscular fibres; in some rare cases, however, a small part in front is formed by the margin of the central tendon. Through it pass also the pneumogastric nerves and œsophageal branches of the coronary artery. Its margin is connected to the structures passing through only by loose areolar tissue. *c.* The opening for the vena cava (*foramen quadratum*) is placed in the highest part of the diaphragm about the level of the disc between the eighth and ninth dorsal vertebræ, in the tendinous centre at the junction of the right and middle lobes, posteriorly. Its form is somewhat quadrangular; and it is bounded by fasciculi of tendinous fibres running parallel with its sides, and firmly attached to the wall of the vessel. Besides the foregoing large foramina there are small perforations through the crura for the splanchnic nerves on both sides, and for the small azygos vein on the left side; while the large azygos vein often takes its course through the right crus. The cord of the sympathetic nerve either perforates the outer part of the crus or passes under the internal arched ligament; and the last dorsal nerve descends on the quadratus lumborum beneath the external arched ligament.

**Form and relations.**—The upper or thoracic surface of the diaphragm is highly arched. Its posterior and lateral fibres, ascending from their connection with the lower margin of the thorax, are for a considerable extent placed close to the ribs, the lungs, especially in their

collapsed condition, not descending so far as the attachments of the diaphragm. The central lobe of the tendon is slightly depressed where it underlies the heart, being about the level of the xiphi-sternal articulation. The vault of the diaphragm rises higher on the right than on the left side. In the dead body it rises on the right side to the level of the junction of the fifth rib-cartilage with the sternum, and on the left side only as high as the sixth: this difference is connected with the great size and firmness of the liver on the right side. It is covered superiorly by the pleuræ and the pericardium, the fibrous layer of the latter membrane blending with the tendinous centre, as well as with the fascia covering its muscular substance. The lower surface, of a deeply concave form, is lined by the peritoneum, and has in apposition with it the liver, the stomach, the pancreas and spleen, and the kidneys.

**Varieties.**—The sternal portion of the muscle is not unfrequently wanting. As a very rare occurrence a fleshy fasciculus has been seen passing from the upper surface of the diaphragm to the wall of the œsophagus.

**Nerves.**—The intercostals, levatores costarum, subcostals, and triangularis sterni are supplied by the intercostal nerves. The diaphragm is mainly supplied by the phrenic nerves from the fourth and fifth cervical; but it also receives small twigs from the lower intercostal nerves (Luschka), and sympathetic filaments from the plexuses round the phrenic arteries.

**Actions.—Movements of respiration.**—The mechanical act of respiration consists of two sets of movements, viz., those of inspiration and of expiration, in which air is successively drawn into the lungs and expelled from them by the alternate increase and diminution of the thoracic cavity. The changes in the capacity of the thorax are effected by the expansion and contraction of its lateral walls, called *costal respiration*, and by the depression and elevation of the floor of the cavity, through contraction and relaxation of the diaphragm, called *diaphragmatic* or *abdominal respiration*. These two movements are normally combined in the act of respiration, but in different circumstances one of them is resorted to more than the other. Thus, abdominal respiration predominates in the male, while costal respiration is employed to a greater extent in the female.

**Inspiration.**—The study of the movements of the thoracic walls in respiration presents considerable difficulty from the complexity of these movements, and from the impossibility of perfectly imitating in the dead body the mechanical conditions under which they occur during life. On a fresh ligamentous thorax, by raising and depressing the sternum, the ribs may be moved upwards and downwards nearly parallel to one another; the first rib moving as freely as the others. But during life several causes combine to make the first rib more fixed than those which follow; as for example, the weight of the upper extremity, and the strain of the intercostal muscles and ribs below. The movements of the thoracic walls in respiration are as follows: 1st. The antero-posterior diameter is increased by a forward movement of the sternum with the attached ribs and cartilages; the lower end of the sternum being raised and advanced, while the upper end, which in easy respiration is at rest, or nearly so, is only raised in full inspiration. 2nd. The transverse diameter of the thorax is increased by the elevation and the eversion of the ribs, the first of these movements bringing larger costal arches to a level occupied in expiration by smaller arches above them, and the second increasing the width of their arch outwards (v. p. 161). These movements are facilitated by the elasticity of the ribs and, to a greater extent, of the cartilages, allowing of the opening out of the angle between the two, while the capacity of the thorax is also increased in its inferior part by the simultaneous backward movement of the lower ribs, due to the arrangement of the costo-transverse articulations. 3rd. The vertical diameter of the thoracic cavity is increased by the descent of the platform of the diaphragm forming its floor; and as the lower ribs are drawn backwards and outwards rather than raised, while the last rib may even move somewhat downwards, the depth of the hinder part of the cavity is by this means also slightly augmented. Lastly, it may be remarked, that extension of the vertebral column is an important agent in respiration, for when the column is bent forwards, the ribs are pressed together in the concavity of the curve, and, conversely, when the column is extended, the ribs are separated.

**Action of the intercostal muscles.**—The manner in which these muscles act has been a subject of controversy from an early time, and is not yet thoroughly determined. It is now generally agreed that the external muscles are elevators of the ribs, and therefore muscles of inspiration, but as to the action of the internal muscles there is still considerable difference of opinion. According to one view, defended by Haller, the external and internal layers have a common action, the decussating fibres acting in the direction of the diagonal between them; while according to another view, that of Hamberger, the external intercostal muscles are admitted to be elevators, but the internal are held to be depressors of the ribs. More recently these views have been modified by Hutchinson to the extent of admitting that the external intercostal muscles, and the parts of the internal intercostals placed between the costal cartilages, elevate the ribs, and that the lateral portions of the internal intercostals act as depressors. This view is illustrated mechanically, and supposed by some to be demonstrated, by means of a mechanism of rods and elastic bands imitating the conditions of the ribs. But

the ribs differ from such rods in respect that they are not straight or rigid bars, and are not free at either end, but are deeply curved, and have the greatest extent of motion in the middle of their arch; and in the living subject the costal arches, in their elevation, both rotate upon certain axes and diminish their curvature, instead of describing a simple upward and downward movement like the bars, so that it is impossible to draw any certain conclusion from such imperfect imitations of the mechanism. The view advocated by Haller, that the two muscles act in combination as elevators of the ribs, appears to derive support from several circumstances, among which may be particularly mentioned the deficiency of the external intercostal muscles in front and of the internal behind, in situations where both would undoubtedly act as depressors, and the experiments of Duchenne,<sup>1</sup> who found that the direct galvanic stimulation of the external intercostal muscle throughout the fifth space caused the lower rib to rise towards the upper, and that the stimulation of the internal intercostal muscle in the intercartilaginous part of the space also caused the lower rib to rise, and farther that when the galvanic stimulus was so strong as to reach the intercostal nerve, and throw the whole of the internal as well as the external intercostal muscle into action, the lower rib was still elevated. On the other hand, the careful and extensive series of measurements carried out by v. Ebner<sup>2</sup> on the partially dissected thorax, both in the collapsed and inflated conditions, tend to confirm Hutchinson's view, indicating that, with the exception of the first two intervals, the intercostal spaces are generally widened and the fibres of the interosseous internal intercostals lengthened during inspiration.

Apart from the action of these muscles in producing movements of the ribs, they also fulfil an important function in supporting and maintaining an equable tension in the portions of the thoracic wall corresponding to the intercostal spaces, without opposing the resistance to the movements that would be presented by a firmer although elastic structure in the same situation.

The *levator costarum* are usually considered to have a similar action with the posterior fibres of the external intercostal muscles, and are therefore ranked among the agents of inspiration. The above-mentioned experiments of v. Ebner, however, show that these muscles have very little influence upon the elevation of the ribs, but that their fibres are most contracted during extension and lateral flexion of the dorsal part of the spinal column. The *scalene* muscles also contribute, even in normal and quiet inspiration, to the support and elevation of the first and second ribs; and it is obvious that the *serratus posticus superior* must have a similar effect on those upper ribs to which it is attached.

The *action of the diaphragm* is more easily understood than that of the intercostal muscles. By its contraction and descent its convexity is diminished, the abdominal viscera are pressed downwards, and the thorax is expanded vertically. The extent to which the central tendon descends in full inspiration is estimated by Hasse<sup>3</sup> at one inch for the right lobe, four-fifths of an inch for the left lobe, and two-fifths of an inch for the hinder part of the middle lobe. The fibres arising from the ribs, being directed nearly vertically upwards from their origins, must tend to raise those ribs, and Duchenne has shown<sup>4</sup> that the contraction of the diaphragm by itself elevates and expands the upper ribs to which it is attached, but only so long as the vault of the muscle is supported by the abdominal viscera, for when they are removed it no longer has that action. The *serratus posticus inferior* and *quadratus lumborum* muscles, by opposing the diaphragm, and thus giving it a fixed point on which to descend, become assistant muscles of inspiration. The anterior fibres of the diaphragm, being directed more horizontally towards the central tendon, oppose the forward motion of the sternum; hence the sternum becomes arched in patients long subject to asthma.

In more forcible inspiration, and more especially in severe attacks of dyspnoea, there are called into play other powerful muscles, to secure the inspiratory action of which a fixed attachment must be provided by the support and elevation of the shoulder and arm; among these may be enumerated the *pectoralis minor*, the lower part of the *pectoralis major*, and possibly also the lowest slips of the *serratus magnus*. Additional assistance in elevating the sternum and upper ribs is afforded by the *sterno-mastoid* and the *infrahyoid* muscles.

**Expiration.**—In normal and quiet expiration the diminution of the capacity of the chest is mainly, if not wholly, due to the return of the walls of the chest to the condition of rest, in consequence of their own elastic reaction, and of the elasticity and weight of the viscera and other parts displaced by inspiration; the lungs themselves, after distension by air, exert considerable elastic force, and no doubt the ribs and their cartilages react strongly by their elastic return from the elevated and expanded condition into which they had been thrown by the inspiratory forces. In more forcible acts of expiration, in muscular efforts of the limbs and trunk, and in efforts of expulsion from the thoracic and abdominal cavities, all the muscles which tend to depress the ribs, and those which compress the abdominal cavity, concur in powerful action to empty the lungs, to fix the trunk, and to expel the contents of the abdominal viscera. (See farther, "Action of the Abdominal Muscles.")

<sup>1</sup> "Physiol. des Mouvements," &c., 1867, p. 646.

<sup>2</sup> Archiv für Anatomie, 1880, p. 185.

<sup>3</sup> Archiv für Anatomie, 1886, p. 199.

<sup>4</sup> Op. cit. p. 620.



## THE MUSCLES AND FASCIAE OF THE ABDOMEN.

**FASCIAE.**—The **superficial fascia of the abdomen** is usually described as consisting of two layers. One of these, the *subcutaneous layer*, corresponds in its general features with the areolar subcutaneous tissue of other parts of the body, and contains embedded in it a very variable and often large quantity of fat. The other, or *deeper layer*, is of a denser and more membranous structure, and contains a considerable amount of yellow elastic tissue in its substance; it is only connected by loose areolar tissue to the subjacent aponeurosis of the external oblique muscle, except at the umbilicus and along the *linea alba*, where the attachment is more intimate, while inferiorly a fibrous and elastic expansion of considerable strength, derived from this layer, passes from the lower part of the *linea alba* and the symphysis pubis to the dorsum of the penis, constituting the *suspensory ligament* of that organ. These two layers are both continuous with the superficial fascia on other parts of the trunk: they can be dissected as distinct layers only on the fore part of the abdomen, and they are separated in a more marked manner in the immediate neighbourhood of the groin, where subcutaneous vessels, such as the superficial epigastric and circumflex iliac, as well as lymphatic glands, lie between them. This distinct portion of the deeper layer is known as the *fascia of Scarpa*, and passing down freely over Poupart's ligament it ends immediately below that band by becoming blended with the *fascia lata*; but internally, near the external abdominal ring, it remains free and is prolonged downwards over the spermatic cord to the scrotum. The subcutaneous layer, losing its fat, is combined with the deeper layer as they both pass to the scrotum; and here the united layer acquires a reddish brown colour, and undergoes a modification of structure by becoming mingled largely with involuntary muscular fibres, constituting the *dartos tunic* of the scrotum. Some involuntary muscular fibres also exist in the altered superficial fascia which covers the penis. This covering, on leaving the scrotum posteriorly, becomes continuous with the superficial fascia of the perineum.

The parts of the superficial fascia here described have received minute attention from anatomists, by reason of their close relation to the seat of hernial tumours and other pathological conditions; the adhesion of the fascia below Poupart's ligament, and its disposition over the inguinal aperture, spermatic cord, and scrotum, while they prevent the descent upon the thigh of fluid which has been effused beneath the fascia, cause it either to spread upwards upon the abdomen or to take its course downwards into the scrotum.

The deep layer of the abdominal fascia is also interesting as corresponding with the *tunica abdominalis* of animals, a strong membrane consisting almost entirely of yellow elastic tissue, which may be well seen in the horse or ox, and which contributes to the support of the viscera.

**MUSCLES.**—The muscular wall of the abdomen is mainly formed on each side by three layers of muscle, the fibres of which run in different directions, those of the superficial and middle layers being oblique, and those of the innermost layer being transverse. In front, these three layers of muscle are replaced by tendinous expansions, which meet in the middle line, giving rise to the *linea alba*: on each side of this line the fibres of the rectus muscle extend in a vertical direction between the tendinous layers, supported usually at the lower end by the pyramidalis muscle. Posteriorly, the wall is formed in part by aponeurosis, and in part by muscles of which the fibres are chiefly vertical, viz., the muscles of the back, and in front of them the quadratus lumborum.

The **obliquus externus abdominis** muscle, the strongest and most superficial of the three broad muscles of the abdomen, arises from the outer surface of the lower eight ribs, by slips arranged in a serrated series, four or five of them interdigitating with origins of the serratus magnus, and three or four with origins of the

latissimus dorsi. The lower and upper digitations of the external oblique are connected with the ribs near their cartilages, the intermediate ones are attached to the ribs at some distance from their extremities; the lowest digitation generally embraces the cartilage of the twelfth rib. The fleshy fibres from the last two ribs pass down in a nearly vertical direction to be inserted into the external margin of the crest of the ilium for about the anterior half of its length; all the rest incline downwards and forwards, and terminate in tendinous fibres, forming the broad aponeurosis by which the greater part of the muscle is inserted.

The *aponeurosis* of the external oblique muscle is wider below than above, and is larger than that of either of the subjacent broad muscles. Consisting for the most

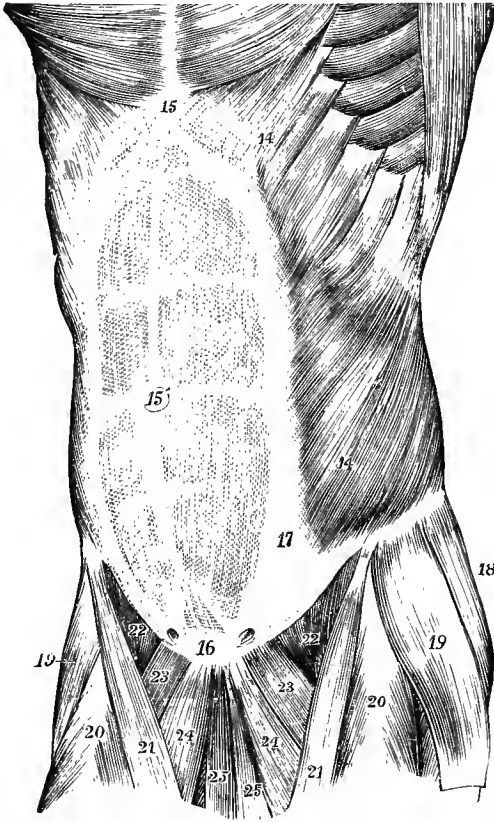


Fig. 291. — SUPERFICIAL VIEW OF THE MUSCLES OF THE ABDOMEN, FROM BEFORE AND SLIGHTLY FROM THE SIDE. (Allen Thomson.)  $\frac{1}{2}$

14, 14, external oblique muscle; 15, placed over the ensiform process at the upper end of the linea alba; 15', umbilicus; 16, symphysis pubis at the lower end of the linea alba; above 16, the pyramidales muscles are seen, showing through the abdominal aponeurosis; from the upper 14 to 17, the linea semilunaris; between this line and the linea alba are seen the lineæ transversæ; above 22, the curved margin of Poupart's ligament; on either side of 16, the external abdominal ring is indicated.

part of oblique fibres, which continue the direction of the muscular fasciculi, it extends inwards to the middle line in front, where it meets its fellow of the opposite side in the linea alba; at some distance from this line, but farther out above than below, it becomes inseparably united with the aponeurosis beneath, and forms a part of the sheath of the rectus muscle in the whole extent of the space from the ensiform process to the symphysis pubis. The upper part of the aponeurosis is connected with the pectoralis major, giving

origin to the lowest fibres of that muscle. The lowest fibres of the aponeurosis are closely aggregated together, and extend across from the anterior superior spine of the ilium to the spine of the pubis, in the form of a thickened band, which is called *Poupart's ligament*. This ligament is curved with its convexity downwards owing to the attachment of the iliac portion of the fascia lata to its lower border, but the degree of curvature and the tension of the band vary with the position of the limb, being increased with extension and eversion, and diminished with flexion and inversion of the thigh.

The aponeurosis is perforated by numerous small apertures for the passage of cutaneous vessels and nerves, and near the body of the pubis by one large opening which transmits the spermatic cord in the male or the round ligament in the female. This is known as the *superficial* or *external abdominal ring* (*external inguinal aper-*

ture), and is formed by the separation of the fibres composing the lower and inner angle of the aponeurosis from the innermost part of Poupart's ligament. The direction of the opening is obliquely upwards and outwards conformably to the direction of the principal fibres of the aponeurosis; its base is formed by the pubic crest, and its sides by the two sets of diverging fibres called the *pillars*. The upper or internal pillar is flat and straight, and is attached to the anterior surface of the symphysis pubis, decussating with the corresponding fibres on the opposite side: the lower or external pillar is in its upper part also flat and thin, but its lower part, which is formed by the inner end of Poupart's ligament, is thick and prismatic, and curves strongly inwards to its termination at the pubic spine.

While the mesial attachment of Poupart's ligament takes place mainly into the pubic spine, the deepest fibres of that band are sent backwards to be fixed to the innermost part of the ilio-pectineal line for a distance of about three-quarters of an inch, constituting a triangular layer which is termed *Gimbernat's ligament*, and which presents upper and lower surfaces, and a concave external margin, the latter being free and forming the inner boundary of the femoral ring. Some of the fibres of Gimbernat's ligament and of the outer pillar of the ring are usually attached only indirectly to the bone; and these are reflected upwards and inwards beneath the spermatic cord, becoming incorporated with the lowest part of the front of the sheath of the rectus, and reach the middle line where they interlace with the fibres of the opposite side. They form a variably developed layer, placed behind the lower part of the external abdominal ring and its inner pillar, and known as the *triangular fascia*.

On the surface of the aponeurosis, especially in its lower part, are seen slender bundles of fibres crossing transversely and binding together its principal oblique fibres. These are the *intercolumnar fibres*, and they are most developed in the neighbourhood of the outer third of Poupart's ligament, and the anterior superior iliac spine. They extend across the upper part of the external abdominal ring, closing to a greater or less extent the angular interval left between the diverging pillars, and from them a thin membrane is prolonged downwards upon the spermatic cord, known as the *intercolumnar or spermatic fascia*. The external abdominal ring thus acquires a somewhat oval form, and its size varies in proportion to the degree of development of these fibres. In the male the opening has an average length of an inch or a little more, with a breadth of half as much. In the female it is usually much smaller.

**Relations.**—The external oblique muscle is superficial with the exception of a small part at its posterior border which is overlapped by the latissimus dorsi. It lies upon the internal oblique and the lower ribs with their cartilages and the intervening intercostal muscles. The origins of the external oblique and latissimus sometimes meet at the iliac crest, but more frequently a small interval is left, and the free portion of bone forms the base of a triangular space between the two muscles—*triangle of Petit*, in which a hernia (lumbar hernia) has been seen to protrude.

**Varieties.**—The external oblique varies chiefly in the number of its attachments to the ribs. Absence of the highest or lowest digitation is not uncommon; on the other hand, one or more slips may be doubled, most frequently those from the eighth and ninth ribs; or an additional slip may arise from the lumbar aponeurosis below the last rib. Besides the connection with the pectoralis major, some fibres are occasionally continued into the serratus magnus. The muscle has also been found double, the deeper accessory portion passing from some of the lower ribs to the crest of the ilium or to Poupart's ligament.

— The **obliquus internus abdominis** muscle, placed under cover of the external oblique, arises by fleshy fibres from the external half or two-thirds of the deep surface of Poupart's ligament, by short tendinous fibres from the middle ridge of the iliac crest for two-thirds of its length; and by some fleshy fibres again from the posterior aponeurosis of the transversalis muscle (lumbar fascia) in the angle between the

crest of the ilium and the outer margin of the erector spinae muscle. From these attachments the fibres, spreading over the side of the abdomen, pass to be inserted as follows: the most posterior fibres pass upwards and forwards to the lower margins of the cartilages of the last three ribs, where they are inserted in the same plane with the internal intercostal muscles; those arising from the anterior part of the iliac crest pass forwards, the upper more obliquely and the succeeding ones more horizontally, to end in an aponeurosis on the front of the abdomen; those from the

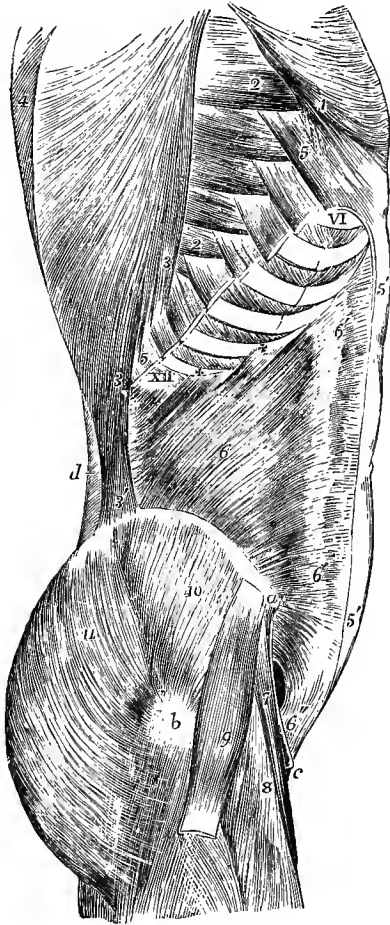


Fig. 292.—LATERAL VIEW OF THE MUSCLES OF THE ABDOMEN, THE INTERNAL OBLIQUE HAVING BEEN EXPOSED BY THE REMOVAL OF THE EXTERNAL OBLIQUE. (Allen Thomson, after Henle.)  $\frac{1}{2}$

*a*, anterior superior iliac spine; *b*, great trochanter; *c*, pubic spine; *d*, posterior layer of the lumbar fascia; VI and XII, sixth and twelfth ribs; 1, lower part of pectoralis major, where it is attached to the aponeurosis of the external oblique; 2, 2, lower digitations of serratus magnus; 3, 3, costal attachments of latissimus dorsi; 3', its iliac attachment; 4, trapezius; 5, 5, divided attachments of external oblique, left in connection with the ribs; 5', 5', aponeurosis of external oblique divided in front of the rectus, where it joins the sheath; 6, internal oblique at its middle; 6', 6', line where its aponeurosis divides to form the sheath of the rectus; + + XII, its attachment to the lowest ribs; 6'', conjoined tendon; 7, sartorius; 8, rectus femoris; 9, tensor vaginae femoris; 10, gluteus medius; 11, gluteus maximus.

anterior superior spine run horizontally to the same aponeurosis; while the fibres from Poupart's ligament, usually paler than the rest, incline downwards to the lower portion of the aponeurosis; and the lowest, arching downwards and inwards over the spermatic cord, or the round ligament of the uterus, end in tendinous fibres common to them and the lower part of the transversalis muscle, thus forming the structure known as the *conjoined tendon* of these muscles; through the medium of this tendon they are attached to the front of the pubis, and to the inner part of the ilio-pectineal line behind Gimbernat's ligament. The spermatic cord, or round ligament, passes under the arched lower

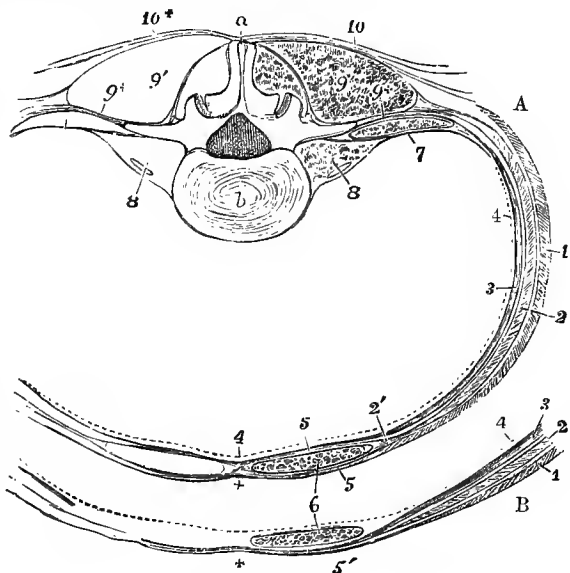
borders of the transversalis and internal oblique muscles on its way from the internal to the external abdominal ring.

The *aponeurosis* of the internal oblique may be regarded as the expanded tendon of the muscle continued forwards and inwards: it extends from the margin of the thorax to the pubis, and is wider at the upper than at the lower end. At the outer border of the rectus muscle the aponeurosis divides into two layers, one passing before, the other behind that muscle; and the two reunite at its inner border in the linea alba, so as to enclose it in a sheath. The anterior layer, as already mentioned, becomes inseparably united with the aponeurosis of the external oblique muscle, and the posterior layer is similarly incorporated with that of the transversalis. The

upper border of the posterior lamina is attached to the margins of the seventh and eighth rib-cartilages, as well as to the ensiform process. This division of the aponeurosis into two layers stops short a little above half-way between the umbilicus and the pubis and about on a level with the anterior superior spine of the ilium, the aponeurosis below that spot remaining undivided, and along with that of the transversalis muscle, to which it is united, passing wholly in front of the rectus. The deficiency thus resulting in the posterior wall of the sheath of the rectus is marked superiorly by a more or less well defined lunated edge, the concavity of which looks downwards towards the pubis—the *semilunar fold of Douglas* (fig. 294).

**Relations.**—The internal oblique muscle is almost entirely covered by the external oblique. The hindmost part of the muscle, arising from the lumbar fascia, is under cover of the latissimus dorsi, and a small part is frequently exposed between the latissimus and the external oblique, when those muscles fail to meet at their iliac origins (p. 329).

Fig. 293.—DIAGRAM OF A TRANSVERSE SECTION OF THE WALL OF THE ABDOMEN, TO SHOW THE CONNECTIONS OF THE LUMBAR FASCIA, AND THE SHEATH OF THE RECTUS MUSCLE. (Allen Thomson.)  $\frac{1}{2}$



A, at the level of the third lumbar vertebra; B, the fore part, at a few inches above the pubis.

a, spinous process, b, body of the third lumbar vertebra; 1, external oblique muscle; 2, internal oblique; 3, transversalis; 4, a

dotted line to mark the position of the transversalis fascia; 5, 5', in A, anterior and posterior parts of the sheath of the rectus, formed by the aponeurosis of the internal oblique splitting at the outer edge of the muscle 2'; 6, rectus abdominis; 7, anterior layer of the lumbar fascia, passing in front of the quadratus lumborum to the anterior surface of the transverse process; 8, psoas magnus and parvus muscles; 9, 9', erector spinae muscles; 9+, middle layer of the lumbar fascia (posterior aponeurosis of the transversalis) passing to the extremity of the transverse process; 10, 10+, posterior layer of the lumbar fascia, connected with the latissimus dorsi and serratus posticus inferior: in A, at the sheath of the rectus, the aponeurosis of the external oblique is seen to unite in front with the sheath, while that of the transversalis is seen uniting with it behind: in B, the section is taken below the semilunar fold of Douglas, and all the tendons pass in front of the rectus at 5'; the + near this, and in a similar place in A, marks the middle line, and the place of the union of the several aponeuroses in the linea alba.

**Varieties.**—A fibrous band or inscription is not uncommonly seen in the upper part of this muscle, prolonged forwards from the point of the tenth or eleventh rib, and a slender cartilaginous slip, separate from that of the rib, has been seen lying in this inscription. An additional slip of insertion, into the ninth costal cartilage, is occasionally present. The portion of the muscle arising from Poupart's ligament may be separated by an interval from the iliac origin (Solger).

The fold of Douglas is often indistinct, the hinder layer of the sheath of the rectus ending indefinitely in scattered tendinous bundles united to the transversalis fascia. The deficiency at the lower part of the aponeurotic sheath posteriorly is regarded by Gegenbaur as due to the position of the urinary bladder in early life, which is in a measure embedded in the anterior abdominal wall, and the upward extent of which is said to correspond to the semilunar folds. Solger, with more probability, explains the deficiency as the result of differences in the degree of tension to which the aponeurosis is subject in its upper and lower parts in the movements of respiration and during the contraction of the abdominal muscles, the portions of the obliquus internus and transversalis below the fold of Douglas being weaker, and having

a less firm origin from Poupart's ligament than the portions above, which have a bony origin (Morph. Jahrb., xi, 1885).

The **cremaster**, a muscle peculiar to the male, consists of fibres lying in series with those of the lower border of the internal oblique muscle. It has an external and an internal attachment. The external attachment is to the inner part of Poupart's ligament, and there its fibres are continuous with those of the internal oblique muscle: the internal attachment, smaller and less constant, is by means of

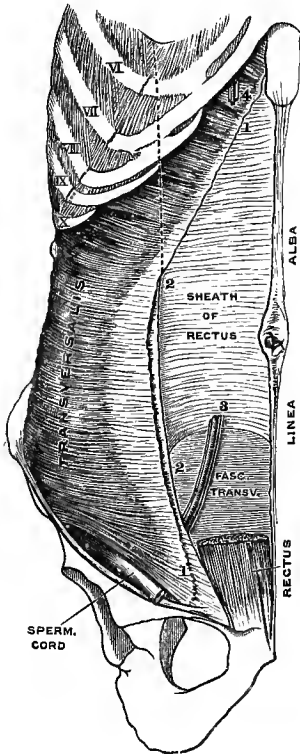


Fig. 294.—THE TRANSVERSALIS MUSCLE AND POSTERIOR LAYER OF THE SHEATH OF THE RECTUS. (Drawn by E. Wilson.)

$\frac{1}{8}$

VI—X, sixth to tenth ribs; 1—1, line of junction of internal oblique; 2—2, cut edge of anterior layer of sheath of rectus; 3, inferior epigastric vessels crossing in front of the semilunar fold of Douglas; 4, superior epigastric vessels; above this, in the angle between the seventh costal cartilage and the ensiform process, the lowest slip of the triangularis sterni is seen. The position of the outer edge of the rectus is indicated in its upper part by the dotted line.

a tendinous band to the spine and crest of the pubis, close to the insertion of the internal oblique muscle. The superior fibres of the muscle extend between these attachments in a series of successively longer loops, descending in front of the spermatic cord, a few of them reaching as low as the level of the testicle; the remaining fibres, the greater number of which descend from the outer attachment, and only a few from the inner, spread out below and are embedded in the substance of a fascia termed *cremasteric*, which adheres to the fascia propria of the testicle. Sometimes the only fibres developed are a bundle descending from the outer attachment.

In the female there may be almost constantly detected a few fibres descending on the round ligament of the uterus, which correspond with the last-mentioned fibres of the cremaster muscle of the male.

The **transversalis abdominis** muscle, subjacent to the internal oblique, arises from the inner surface of the cartilages of the six lower ribs by fleshy slips which interdigitate with the costal attachments of the diaphragm (fig. 288, p. 321), from the transverse processes of the lumbar vertebræ by a strong posterior aponeurosis, from the inner margin of the crest of the ilium in the anterior two-thirds of its extent, and from the outer third of Poupart's ligament. The greater part of the fibres have a horizontal direction, and extend forwards to a broad aponeurosis in front; the lowest fibres curve downwards like those of the internal oblique, with which they are usually closely united, and are inserted into the front of the pubis and into the ilio-pectineal line, through the medium of the conjoined tendon already described as common to this muscle and the internal oblique.

The *anterior aponeurosis* of the transversalis muscle commences in the greater part of its extent at the distance of about an inch from the outer border of the rectus muscle; but at its upper extremity it is much narrower, and there the muscular fibres of opposite sides approach nearly to the middle line behind the recti muscles. In its upper two-thirds it becomes united with the posterior layer of the aponeurosis of the internal oblique, forming the posterior wall of the rectus-sheath;

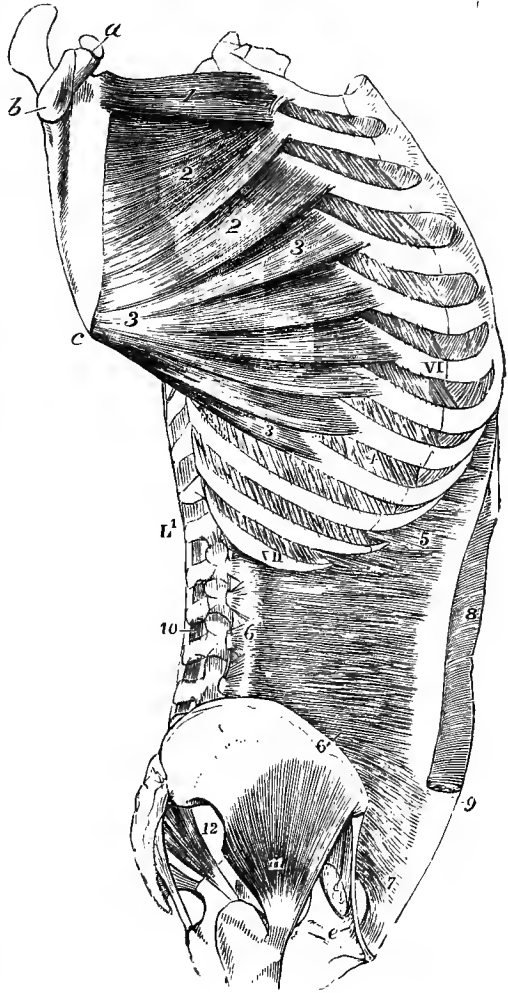
and inferiorly, where that aponeurosis passes entirely in front of the rectus, it takes a similar position in relation to that muscle.

The *posterior aponeurosis* of the transversalis springs by strong fibrous bundles from the tips of the transverse processes of the lumbar vertebræ, and extends outwards to the commencement of the fleshy fibres, being placed between the erector spinæ and quadratus lumborum muscles. Superiorly it is attached to the lower

Fig. 295.—LATERAL VIEW OF THE TRUNK, SHOWING THE SERRATUS MAGNUS AND TRANSVERSALIS ABDOMINIS MUSCLES. (Allen Thomson.)  $\frac{1}{2}$

For the explanation of the references in the upper part of the figure see the description of fig. 230, p. 212.

*e*, placed on the pubis, points to the insertion of Gimbernat's ligament; VI, XI, sixth and twelfth ribs; L<sup>1</sup>, first lumbar vertebra; 5, costal origins of the transversalis abdominis; 6, origin of the muscle from the transverse processes of the lumbar vertebræ by the lumbar aponeurosis; 6', part arising from the crest of the ilium; 7, lower portion arising from the outer part of Poupart's ligament; 8, sheath of the rectus muscle opened in its upper part by removing the aponeurosis of the oblique muscles; 9, the same in its lower part left entire at the place where the tendons pass wholly in front of the rectus muscle; 10, interspinales muscles; 11, glutæus minimus; 12, pyriformis.



border of the last rib, and inferiorly to the ilio-lumbar ligament and the adjoining part of the iliac crest. This membrane constitutes the *middle layer of the lumbar fascia*; it is joined behind, at the outer edge of the erector spinæ, by the posterior layer, and in front, more externally, at the outer edge of the quadratus, by the anterior layer of that structure.

**Relations.**—Between the outer surface of this muscle and the internal oblique are placed the lower intercostal nerves and a branch of the circumflex iliac artery: its inner surface is lined throughout by the transversalis fascia, which separates it from the subperitoneal tissue and the peritoneum. The highest part of the transversalis is continued into the triangularis sterni muscle of the thorax.

**Varieties.**—The transversalis has been found fused with the internal oblique, or entirely absent. The spermatic cord has been seen to pierce its lower border. Slender muscular slips have been observed arising from the ilio-pectineal line behind the conjoined tendon, and inserted into the transversalis fascia, the aponeurosis of the transversalis muscle (*pubo-transversalis*, Luschka), or the outer end of the semilunar fold of Douglas.

The **rectus abdominis** is a long flat muscle, consisting of vertical fibres, situated at the fore part of the abdomen, within a tendinous sheath formed in the manner already described in the account of the aponeurosis of the internal oblique

muscle ; it is separated from the muscle of the other side by a narrow interval, which is occupied by the linea alba. It arises from the pubis by a flat tendon consisting of two parts, of which the internal is much the smaller and is connected with the ligaments covering the front of the pubic symphysis, becoming blended with the one of the opposite side, while the external is fixed to the pubic crest.

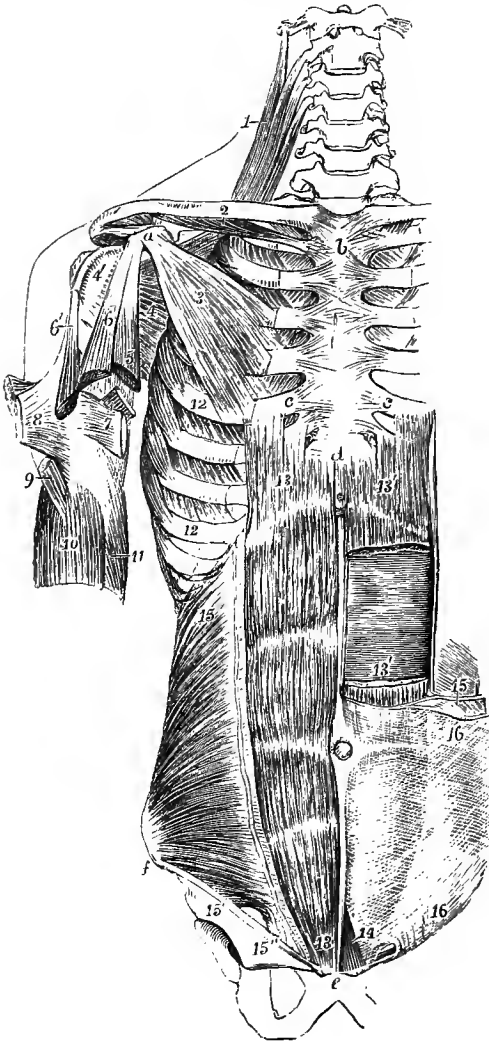


Fig. 296.—DEEP MUSCLES OF THE FORE PART OF THE TRUNK AND SHOULDER. (Allen Thomson.)  $\frac{1}{2}$

For the explanation of the references in the upper part of the figure see p. 211.

*c, c*, cartilages of the fifth ribs ; *d*, ensiform process ; *e*, symphysis pubis ; *f*, anterior superior iliac spine ; *12*, origin of the serratus magnus ; *13, 13*, on the right side, the rectus abdominis ; on the left side, *13', 13'*, the divided ends of the same muscle, a portion being removed ; *14*, pyramidalis muscle, exposed on the left side ; *15*, on the right side, the internal oblique muscle ; *15'*, origin of its lower fibres from the deep surface of Foupart's ligament ; *15''*, conjoined tendon of the internal oblique and transversalis ; *15*, on the left side, cut edge of the internal oblique, shown diagrammatically, to indicate the manner in which its aponeurosis splits to form the sheath of the rectus muscle ; *16*, aponeurosis of the external oblique muscle, uniting in front with the sheath of the rectus.

Expanding and becoming thinner as it ascends, the muscle is inserted into the cartilages of three ribs, the fifth, sixth, and seventh, as well as usually into the bone of the fifth, by three distinct slips of unequal size. Some fibres also are frequently found attached to the ensiform process.

The fibres of the rectus muscle are interrupted by three or more irregular tendinous intersections, known as the *inscriptiones tendineae*. The three which are most constant are placed, one opposite the umbilicus, another on a level with the lower end of the ensiform process, and the third intermedi-

ately between the first two ; and these generally run across the whole or the greater part of the muscle. When one or two additional transverse lines occur, they are usually incomplete ; one of them is very generally placed below the umbilicus, the position of the other is variable. The intersections do not usually penetrate the whole thickness of the muscle, but are confined chiefly to its anterior fibres, and are firmly united to the anterior wall of the sheath of the muscle, while the posterior surface of the muscle has no attachment to the sheath.

**Varieties.**—The rectus is sometimes joined by some fibres springing from the lower part of the linea alba. The insertion of the muscle has been seen prolonged upwards to the fourth,



and even to the third rib. On the other hand, the slip of insertion into the fifth cartilage may be wanting.

The tendinous intersections have been regarded as indications of the abdominal ribs of some of the lower animals; they are rather vestiges of the septa between the original vertebral myotomes. They sometimes extend outwards from the rectus, and penetrate partially into the internal oblique.

The **pyramidalis** is a small muscle resting on the lower part of the rectus, in the sheath of which it is contained. It arises by short tendinous fibres from the front of the pubis below the rectus, and, becoming narrower as it ascends over the lower third of the interval between the umbilicus and pubis, is inserted into the linea alba.

**Varieties.**—This muscle varies greatly in size, and it is often absent on one or both sides, in which case the size of the lower part of the rectus is increased: in some instances it has been found to be double.

The **linea alba** is a white fibrous structure extending perpendicularly in the middle line from the ensiform process to the pubis. This tendinous band is formed by the union of the aponeuroses of the two oblique and the transverse muscles, the tendinous fibres being continued in a decussating manner from one side to the other. It is broader superiorly than inferiorly, and a little below the middle it is widened out into a circular flat space, in the centre of which is situated the cicatrix of the *umbilicus*. At the lower end, where the linea alba becomes narrow and less marked, and passes in front of the conjoined inner heads of the recti muscles to the symphysis pubis, there is detached from it posteriorly a small band of longitudinal fibres, the *admiriculum lineæ albae*, which spreads out below into a triangular expansion fixed on each side to the upper border of the body of the pubis behind the outer head of the rectus. At the upper end there are also a few longitudinal fibres descending from the ensiform process. The linea alba is much increased in breadth when the abdomen is distended during pregnancy or from disease.

The **linea semilunaris** is a curved linear depression on each side of the front of the abdomen, situated along the outer border of the rectus muscle, and appearing as a white line on the surface of the aponeurosis of the external oblique. It corresponds to a narrow portion of the aponeurosis of the internal oblique, between its division to form the sheath of the rectus internally, and the termination of the fleshy fibres of the muscle externally. The **lineæ transversæ** are cross lines, corresponding to, and produced by, the tendinous intersections of the rectus.

The **quadratus lumborum** (fig. 248, p. 244) is a quadrilateral muscle, somewhat broader below than above, placed between the last rib and the pelvis, close to the vertebral column. It arises below by fleshy and tendinous fibres from the ilio-lumbar ligament and from the iliac crest for about two inches, behind and external to the attachment of that ligament, and on the inner side from the transverse processes of two, three or four lumbar vertebræ, by tendinous and fleshy slips, the fibres of which ascend on the anterior surface of the muscle. It is inserted into the lower border of the last rib for about half its length, and into the transverse processes of the upper four lumbar vertebræ, by tendinous slips placed generally behind the slips arising from those processes.

**Relations.**—The quadratus lumborum is contained in a sheath formed by the anterior and middle layers of the lumbar fascia. Its anterior surface is overlapped by the psoas, and upon it rests the kidney, while the ascending or descending colon lies in front of its outer border. The inner border is intimately connected with the lateral intertransverse muscles.

**Varieties.**—The number of the points of insertion of this muscle to the vertebræ, and the extent of its connection with the last rib, vary in different instances. It is sometimes attached to the body or transverse process of the last dorsal vertebra.

**Nerves.**—The abdominal muscles are supplied generally by the lower intercostal nerves. The internal oblique and transversalis receive also branches from the ilio-hypogastric and ilio-inguinal nerves, and the cremaster is supplied by the genital branch of the genito-crural nerve. The quadratus lumborum receives small branches from the last dorsal and the upper lumbar nerves.

**Actions.**—The abdominal muscles not only form a great part of the wall to enclose and support the abdominal viscera, but by their contraction are capable of acting successively on those viscera, on the thorax, and on the vertebral column. When the pelvis and thorax are fixed, the abdominal muscles constrict the cavity and compress the viscera, particularly if the diaphragm be fixed at the same time by the closure of the glottis, as occurs in vomiting and in the expulsion of the fœtus, the fœces, or the urine.

If the vertebral column be fixed, these muscles raise the diaphragm by pressing on the abdominal viscera, draw down the ribs, and contract the base of the thorax, and so contribute to expiration; but if the vertebral column be not fixed, the thorax will be bent directly forwards when the muscles of both sides act, or inclined laterally when they act on one side only, or rotated when the external oblique of one side and the opposite internal oblique act in combination.

The quadratus lumborum is a lateral flexor, and to a slight extent also an extensor of the spine when the muscles of the two sides act together. By drawing down the last rib it also aids in inspiration (p. 326).

If the thorax be fixed, the abdominal muscles may be made to act on the pelvis; thus, in the action of climbing, the trunk and arms being elevated and fixed, the pelvis is drawn upwards, either directly or to one side, as a preparatory step to the elevation of the lower limbs.

**LINING FASCIÆ OF THE ABDOMEN.**—On the inner surface of the wall of the abdomen is a membranous structure which lines the visceral aspect of the deepest stratum of muscles: it is divisible into two principal parts, the transversalis fascia and the iliac fascia.

The **transversalis fascia** is named from its position on the deep surface of the transversalis muscle. It is strongest in the lower part of the abdomen, where the muscular and tendinous support is somewhat weaker. Followed upwards from this situation, it becomes gradually slighter, and beyond the margin of the ribs it is continued into a thin areolar layer on the under surface of the diaphragm. Along the inner margin of the iliac crest, between the iliacus and transversalis muscles, the fascia is attached to the periosteum. For about two inches inwards from the anterior superior iliac spine, it is closely connected with the back of Poupart's ligament, and is there directly continuous with the iliac fascia. Internal to the middle of Poupart's ligament, the external iliac artery and vein, as they pass out into the thigh, intervene between the transversalis fascia and the iliac fascia, and from this point to the edge of Gimbernat's ligament the transversalis fascia is prolonged downwards under Poupart's ligament, and over the vessels, forming the fascia passes under Poupart's ligament it is strengthened by a dense band of fibres, constituting the *deep crural arch*, which curves over the vessels, and is inserted into the pubic spine and the ilio-pectineal line behind the conjoined tendon of the transversalis and internal oblique muscles. It includes beneath it, internal to the vessels, a space between Gimbernat's ligament and the vein, sufficiently large to admit the point of the little finger; this is called the *femoral ring*, and is the space through which a femoral hernia descends. About midway between the anterior superior iliac spine and the symphysis pubis, and about half an inch above Poupart's ligament, the spermatic cord in the male, or the round ligament in the female, pierces the transversalis fascia. The opening thus made is called the *internal or deep abdominal ring (internal inguinal aperture)*; the fascia above and internal to it is thin, but below and external to it is firm and thick, and the lower boundary of the opening is formed by a distinct crescentic edge, over which the cord or round ligament passes: from the margin of the opening a delicate funnel-shaped covering,

the *inufndibuliform fascia*, is prolonged downwards on the emerging structures, and thus forms in cases of oblique hernia one of the coverings of the tumour.

The **iliac fascia**, stronger than the transversalis fascia, lines the back part of the abdominal cavity, and covers the ilio-psoas muscle. The densest portion is stretched transversely from the iliac crest, over the iliacus and psoas, to the brim of the pelvis, where it is attached to the iliac portion of the ilio-pectineal line. A thinner part is continued upwards on the surface of the psoas, along the inner border of which it is attached to the sacrum, to the intervertebral discs and the neighbouring margins of the lumbar vertebræ, as well as to the tendinous arches over the lumbar vessels (p. 243). Externally, it joins the anterior layer of the lumbar fascia; and above, it becomes blended with the internal arched ligament of the diaphragm. Inferiorly the iliac fascia is prolonged downwards, covering the conjoined muscle, a short distance into the thigh, being placed behind the femoral artery and vein, and forming the hinder portion of the femoral sheath. On the outer side of the vessels, the fascia as it descends is closely united with the lower border of the transversalis fascia and Poupart's ligament, and it ends by blending with the fascia lata forming the upper part of the sheath of the sartorius. Internally this part of the fascia becomes directly continuous with the pubic portion of the fascia lata (see p. 242), while from the junction of the two a short but strong inter-muscular septum is sent backwards between the psoas and pectineus muscles to be attached to the ilio-pectineal eminence and the capsule of the hip-joint.

In cases where the psoas parvus is present the iliac fascia is thickened above the ilio-pectineal eminence by the incorporation of the tendon of this muscle as it expands to its insertion.

At the back part of the abdomen there is also a thin membrane covering the quadratus lumborum muscle and forming the **anterior layer of the lumbar fascia**. It is attached at the inner border of the quadratus to the front of the transverse processes of the lumbar vertebræ, while along the outer border of that muscle it becomes united with the middle layer of the fascia. Superiorly it forms the external arched ligament of the diaphragm already described, and inferiorly it is attached to the ilio-lumbar ligament and the crest of the ilium.

The **middle layer of the lumbar fascia**, much stronger than the anterior, and placed between the erector spinæ and quadratus lumborum, is formed by the posterior aponeurosis of the transversalis muscle, in connection with which it has already been described (p. 333).

#### MUSCLES AND FASCIAE OF THE PERINEUM AND PELVIS.

**FASCIAE OF THE PERINEUM—Superficial fascia.**—In the posterior half of the perineum the subcutaneous fat is continued deeply into the ischio-rectal fossa, the pyramidal space intervening between the obturator fascia and the levator ani muscle. In the anterior half of the perineum, beneath the subcutaneous fat, is placed a special layer of fascia, continuous with the dartos, the proper *superficial perineal fascia*, sometimes called *fascia of Colles*. This fascia is bound down on each side to the margin of the rami of the pubis and ischium as far back as the ischial tuberosity; posteriorly, along a line from the ischial tuberosity to the central point of the perineum, it turns round the hinder margin of the transversus perinei muscle to join the deep perineal fascia, to be presently described. From its deep surface, likewise, an incomplete median septum passes upwards towards the urethra and is continued forwards into the scrotum. It thus happens that air blown in beneath the proper perineal fascia on one side passes forwards and distends the scrotum to a certain extent on that side; it may then penetrate to the

other side also, and if injected with sufficient force may reach the front of the abdomen, and travel upwards beneath the superficial fascia; but it neither passes backwards to the posterior half of the perineum nor downwards upon the thighs. The same course is followed by urine or matter extravasated beneath the proper perineal fascia.

The **deep perineal** or **subpubic fascia, triangular ligament of the urethra**, is stretched across the subpubic arch on the deep surface of the crura of the penis and the bulb of the urethra. It consists of two distinct layers of thin but strong fibrous membrane, separated by intervening structures. The *inferior* or *superficial layer*, extending backwards in the middle line to the central point of the perineum, is attached on each side to the rami of the pubis and ischium, while posteriorly its base becomes connected with the superior layer, and with the recurved margin of the superficial perineal fascia. Anteriorly it is continued into the angle between the crura of the penis, and at a deeper level a short fibrous band

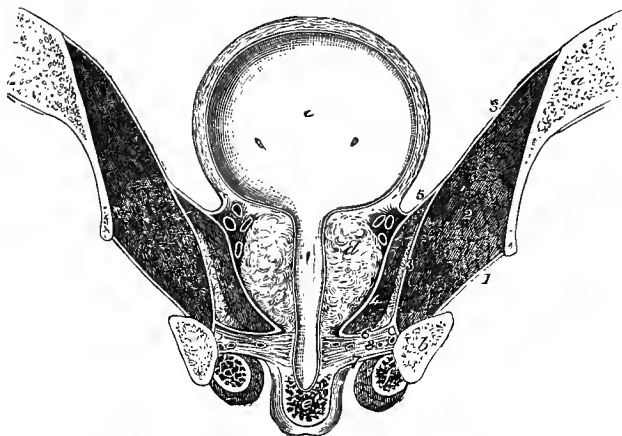


Fig. 297.—CORONAL SECTION OF THE PELVIS IN THE SITUATION INDICATED BY THE LINE A, A', IN FIG. 298, SHOWING THE DISPOSITION OF THE PELVIC FASCIA AND TRIANGULAR LIGAMENT OF THE URETHRA (SEMIDIAGRAMMATIC). (G. D. T.)  $\frac{1}{2}$

*a*, section of the hip-bone passing through the centre of the acetabulum; *b*, section of the ramus of the ischium; *c*, bladder, from which the urethra is continued downwards; *d*, prostate gland; *e*, corpus spongiosum urethrae, covered by the bulbo-cavernosi muscles; *f*, crus penis, covered by the ischio-cavernosus muscle; *g*, levator ani muscle; *h*, recto-vesical fascia, dividing into an ascending layer attached to the bladder, and a descending layer forming the sheath of the prostate: between the fascia and the prostate are the veins of the prostatic plexus; *i*, superior, and *j*, inferior layer of the triangular ligament of the urethra; *k*, constrictor urethrae muscle, embedded in which, close to the ischium, are the pudic vessels and the dorsal nerve of the penis.

In order to show more clearly the relations of the parts, the urethra is represented as being laid open through the whole of the prostatic and membranous, and the commencement of the spongy portions; whereas the lower half of the prostatic portion is naturally a little behind the plane of the section.

(*transverse ligament of the pelvis*, Henle) stretches across the subpubic angle near its apex, bounding with the subpubic ligament an oval aperture, through which the dorsal vein of the penis is transmitted. About an inch from the symphysis this layer is perforated by the urethra, immediately before its entrance into the bulb, and the latter structure is intimately adherent to, and receives a superficial expansion from, the under surface of the membrane. It is also pierced on each side of the urethral opening by the artery to the bulb, and a little farther forwards, close to the pubic ramus, by the artery of the corpus cavernosum. Between the two layers of the deep perineal fascia are placed the membranous portion of the urethra, the

constrictor muscle of the urethra, and Cowper's glands, together with the pudic vessels and their offsets to the bulb, and the dorsal nerves of the penis. The *superior* or *deep layer* consists of right and left lateral halves, which are separated in the middle line by the urethra close to the neck of the prostate, where they are continued into the sheath of that gland derived from the recto-vesical portion of the pelvic fascia, whilst laterally they join on each side the obturator portion of the pelvic fascia close to its attachment to the pubic and ischial rami. This layer of fascia is superficial to the anterior fibres of the levator ani muscle, which lie between it and the recto-vesical fascia, and it is connected with a thin web of areolar tissue which extends backwards on the surface of the levator ani muscle, and is distinguished as the *anal fascia*.

In the female the deep perineal fascia is divided in the middle by the vagina.

**FASCIÆ OF THE PELVIS.**—The **pelvic fascia** is a complicated structure lining the muscles within the cavity of the pelvis and supporting the pelvic viscera. It consists of two principal parts, which are known as the *obturator fascia* and the *recto-vesical fascia*.

The **obturator fascia**, a distinct piece on each side of the pelvis, may be regarded as the special fascia of the obturator internus muscle, the inner surface of which it covers, and around which it is fixed to the bone. It is attached above for a short distance to the iliac portion of the ilio-pectineal line; in front, to the body of the pubis along an oblique line extending from the upper and inner part of the thyroid foramen to a little below the symphysis; behind, to the anterior margin of the ilio-sciatic notch, as well as to the great sacro-sciatic ligament; and below, it joins the falciform process of that ligament, by means of which it is connected to the ischial and pubic rami. At the upper end of the thyroid foramen its attachment to the bone is interrupted, and the fascia joins the upper edge of the obturator membrane, forming an arch over the border of the muscle, and bounding below the short canal by which the obturator vessels and nerve issue. The inner surface of this fascia in its upper part looks into the pelvic cavity and is lined by peritoneum; in its lower part it looks into the perineal space, forming the outer boundary of the ischio-rectal fossa, and in this part of the fascia the internal pudic vessels with their accompanying nerves are embedded in a sheath as they course to the front of the perineum.

The *fascia of the pyriformis* is a thin and unimportant layer, which is continued backwards from the obturator fascia to the sacrum, passing in front of the pyriformis muscle and the nerves of the sacral plexus, and being perforated by the branches of the internal iliac vessels which leave the pelvis by the great sacro-sciatic foramen.

The **recto-vesical fascia** is attached anteriorly to the back of the pubis above the obturator fascia, from which it is here separated by the origin of the levator ani, the three being, however, generally closely adherent near the bone; laterally it springs from the obturator fascia along a curved line passing from the upper part of the obturator foramen to the ischial spine; and posteriorly it becomes continuous with the lower part of the fascia of the pyriformis. From these attachments the fascia is directed downwards and inwards, in contact with the upper surface of the levator ani muscle, to the prostate gland, to the bladder, and to the rectum, and being farther continuous from side to side across the middle line in front of the bladder and between the bladder and the rectum, it thus forms a fibrous partition which completely separates the pelvic cavity above from the perineal space below. Certain parts of this fascia, generally not very well defined, however, are referred to as ligaments of the viscera with which they are connected. The best marked of these are the *anterior true ligaments of the bladder* or *pubo-prostatic ligaments*, a narrow but strong band on each side, consisting in great part of involuntary muscular fibres, and passing from the lower part of the pubis to the anterior surface of the prostate

and the neck of the bladder. Between the two ligaments the fascia is thin and depressed, forming a small pouch which is occupied by some loose fat and areolar tissue. On the outer side of the anterior ligament, the part of the fascia which descends to the side of the bladder and prostate is known as the *lateral true ligament of the bladder*; and farther back, the part joining the side of the rectum has been called the *ligament of the rectum*. There is also seen on the upper surface of the recto-vesical fascia another thickened band, which springs from the pubis in common with the anterior true ligament of the bladder, and passes backwards and outwards to the ischial spine, thus strengthening the floor of the pelvic cavity, and assisting materially in the support of the bladder. This is the so-called *white line of the pelvic*

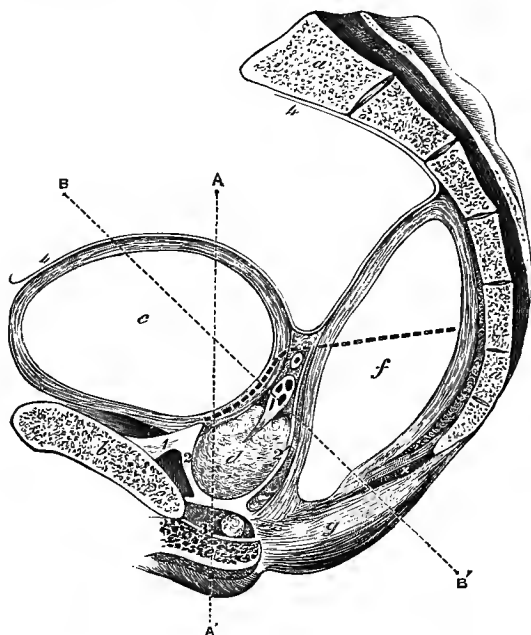


Fig. 298.—DIAGRAM OF A SAGITTAL SECTION OF THE PELVIS, A LITTLE TO THE LEFT OF THE MEDIAN PLANE, TO SHOW THE ARRANGEMENT OF THE PELVIC FASCIA, &C. (G. D. T.)  $\frac{1}{2}$

*a, a*, section of sacrum and coccyx; *b*, section of pubis; *c*, bladder; *d*, prostate gland, above which are the vesicula seminalis and vas deferens cut obliquely; *e*, corpus spongiosum urethrae, covered by the bulbocavernosus muscle; *f*, rectum; *g*, external sphincter; *x*, levator ani; 1, anterior true ligament of bladder; 2, 2', sheath of prostate, continuous below with the upper layer of the triangular ligament of the urethra; the hinder part of the sheath is continued upwards between the vesiculae seminales and the rectum; 3, inferior layer of the triangular ligament, between which and the superior layer are seen in section the constrictor urethrae muscle and Cowper's gland; 4, 4, peritoneum.

The thick dotted line indicates the level at which, to the left of the section, the ascending layer of the recto-vesical fascia is attached to the bladder and rectum. The thinner dotted lines

*A, A'*, and *B, B'*, represent the situation of the sections shown in figs. 297 and 299.

*fascia*, and in its posterior part it corresponds to the place of origin of the recto-vesical fascia from the obturator fascia.

At its connection with the viscera, the recto-vesical fascia has the following arrangement. The anterior part of the fascia meets the side of the bladder along the line of its junction with the prostate, and there divides into two layers. The upper of these is short and is reflected upwards, soon becoming closely united with the muscular coat of the bladder: the lower is stronger and more extensive, and is continued downwards, forming the sheath of the prostate, which at the apex of that gland is continued into the superior layer of the deep perineal fascia (triangular ligament of the urethra). In the angle between the two layers, and between the sheath and the substance of the prostate, are contained the large veins of the prostatic plexus, but these structures are so closely united by dense connective tissue that the prostatic sheath can only be dissected off the gland with difficulty. Behind and above the prostate, the prolongation of the upper layer is attached to the base of the bladder immediately outside the line of the vesiculae seminales, which are thus excluded, together with the intervening portion of the base of the bladder, from the

proper pelvic cavity; while the inferior layer, continuous with the posterior part of the prostatic sheath, extends across between the bladder and rectum, on the one hand binding the vesiculæ seminales and vasa deferentia to the base of the bladder, on the other, forming the front part of the sheath of the rectum. The hinder part of the fascia is similarly attached to the rectum, and sends a prolongation downwards on the lower part of the gut, which becomes gradually thinner and is lost a short distance from the anus.

In the female the vagina receives an investment from the recto-vesical fascia, corresponding to the prostatic sheath of the male. In other respects the arrangement of the pelvic fascia is substantially the same in the two sexes.

**MUSCLES.**—The muscles of the perineum differ somewhat in the two sexes, and must therefore be separately described in each. In both sexes they may be divided into two groups, according as they are more immediately connected with the lower

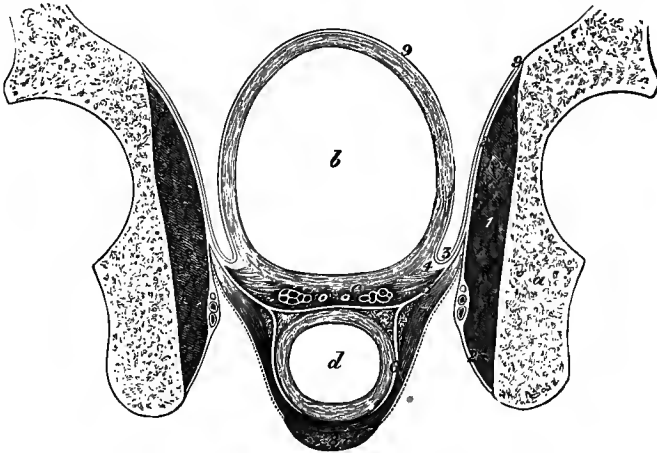


Fig. 299.—DIAGRAM OF AN OBLIQUE SECTION OF THE PELVIS IN THE SITUATION INDICATED BY THE LINE B, B', IN FIG. 298. (G.D.T.)  $\frac{1}{2}$

*a*, section of hip-bone, passing behind the centre of the acetabulum; *b*, bladder; *c*, vesicula seminalis and vas deferens of the right side; *d*, rectum; 1, obturator internus muscle; 2, 2, obturator fascia, in the lower part of which the pudic vessels and nerves are contained in a sheath; 3, recto-vesical fascia; 4, its upper layer attached to the bladder; 5, its lower layer passing across in front of the rectum, and continuous with 6, the lateral part of the investment of the rectum; 7, levator ani, the dotted line on its under surface indicates the position of the anal fascia; 8, external sphincter; 9, 9, peritoneum.

orifice of the alimentary canal or with the genito-urinary outlet. In both groups superficial and deep muscles are to be distinguished.

**A.—IN THE MALE.**—*a*. **ANAL MUSCLES.**—The **internal** or **circular sphincter** is a thick ring of unstriped muscle continuous with the circular fibres of the rectum, and will be referred to along with the anatomy of that organ.

The **superficial** or **external sphincter** muscle (sphincter ani externus) is a layer of fibres nearly an inch in depth on each side, placed immediately beneath the skin surrounding the margin of the anus. It is elliptical in form, and is attached posteriorly by a small tendon to the tip and back of the coccyx, usually receiving also some fibres from the overlying integument. Passing forwards it divides into two parts which enclose the anus and meet again anteriorly, where the superficial fibres end in the skin, some of the innermost ones decussating across the middle line, while the larger part becomes blended with the transverse and the bulbo-cavernosus

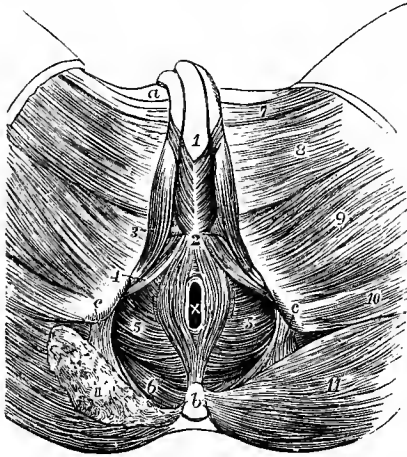


Fig. 300.—SUPERFICIAL MUSCLES OF THE PERINEUM IN THE MALE. (Allen Thomson, after Bourguery.) ‡

*a*, spine of the pubis; *b*, coccyx; *c*, placed on the tuberosity of the ischium, points by a line to the great sacro-sciatic ligament; *x*, anus; 1, placed on the corpus spongiosum urethræ in front of the bulbo-cavernosus muscles; 2, central point of the perineum; 3, ischio-cavernosus; 4, transversus perinei; 5, levator ani; from 2 to *b*, external sphincter of the anus; surrounding *x*, is the internal sphincter; 6, coccygens; 7, adductor longus; 8, gracilis; 9, adductor magnus; 10, semitendinosus and biceps; 11, on the left side, the gluteus maximus entire; 11', the same cut on the right side, so as to expose a part of the coccygens muscle.

muscles in the central point of the perineum. A few deeper fibres pass across without interruption from side to side in front of and behind the anal passage.

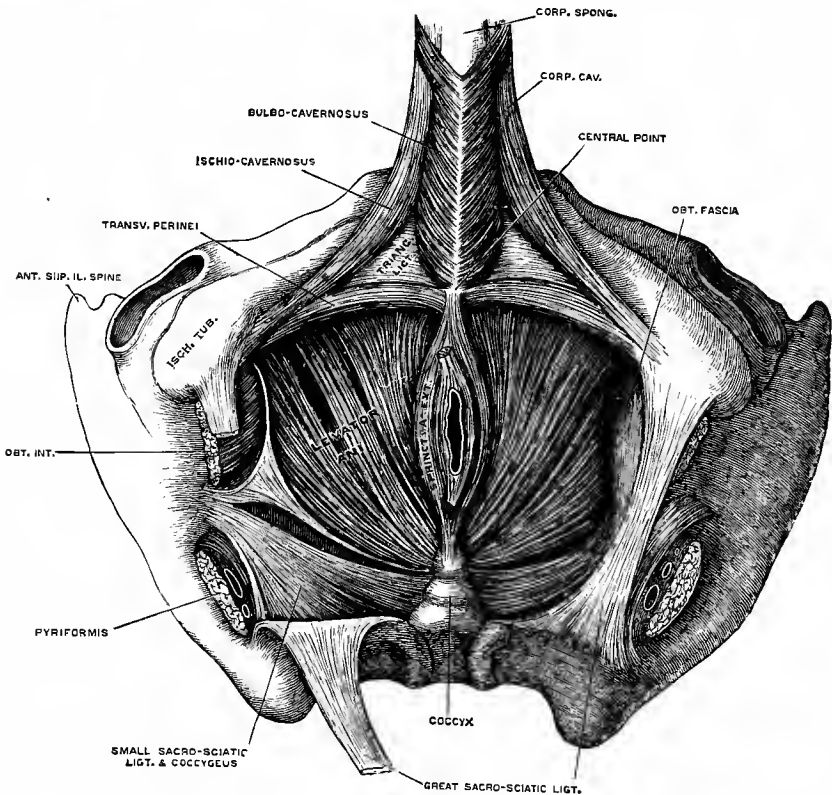


Fig. 301.—MUSCLES OF THE MALE PERINEUM. (After Henle.) ‡

The *central point of the perineum* is the median part of a small transverse tendonous septum in which several muscles of the perineum meet. It is placed about an inch in front of the anus, and immediately behind the bulb of the urethra in



the male, behind the vulval orifice in the female. The tendinous structure is, however, not unfrequently entirely absent, in which case the muscles are directly continuous with one another.

The **levator ani** is a broad fleshy layer which extends from the anterior and lateral parts of the pelvic wall downwards and inwards to the middle line, and forms, together with its fellow of the opposite side, a muscular floor to the greater part of the pelvic cavity. It takes origin from the pelvic surface of the body of the pubis by thin tendinous fibres, placed between and intimately adherent to the pubic attachments of the obturator and recto-vesical fasciæ, from the pelvic fascia along the line of origin of the recto-vesical fascia, and to a slight extent from the ischial spine. Some fasciculi are also frequently added to the fore part of the muscle from the upper layer of the deep perineal fascia. The hinder fibres pass downwards and inwards to the lateral margin of the coccyx; the foremost ones run almost directly backwards to the central point of the perineum; and the intervening ones descend with varying degrees of obliquity to the lower end of the rectum and to a narrow median aponeurosis common to the muscles of the two sides between the tip of the coccyx and the anus.

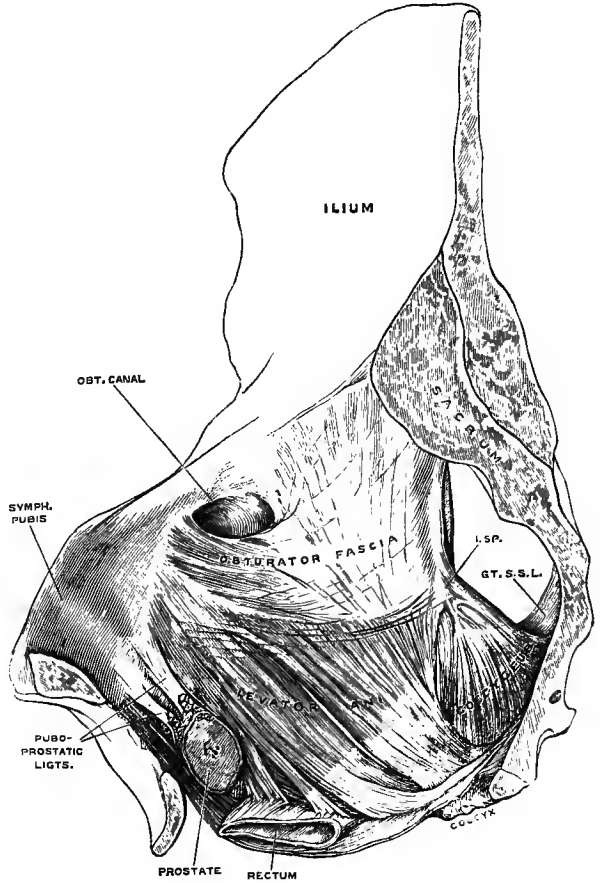


Fig. 302.—LEVATOR ANI AND COCCYGEUS MUSCLES OF THE RIGHT SIDE, FROM WITHIN. (Drawn by T. W. P. Lawrence.)  $\frac{1}{2}$

*l.sp.*, ischial spine; *gt.s.s.l.*, great sacro-sciatic ligament.

The levator ani is divided by a cleft beginning just below the obturator canal into two portions, only the anterior of which is directly connected with the rectum. This portion (the *pubo-coccygeus* of Savage) includes the fibres springing from the pubis and the adjoining part of the fascial origin, and is to some extent bilaminar: its outer or superficial fibres run backwards over the side of the prostate and rectum, being closely applied to the highest bundles of the external sphincter, of which they seem to form a continuation upwards, and becoming united with the corresponding part of the opposite side behind the bowel are inserted into the tip of the coccyx. The inner or deep fibres are partly inserted into the wall of the rectum, making their way between the external and internal sphincters to join the longitudinal fibres of the bowel; but a few anterior ones meet and decussate with those of the opposite muscle

in front of the anus, and the posterior fibres similarly join with those of the other side to be attached to the front of the coccyx. The hinder part of the muscle (the *ischio-coccygeus* of Henle, *obturato-coccygeus* of Savage) proceeds from the pelvic fascia and the ischial spine, and its fasciculi converge to be inserted into the lateral margin of the coccyx and the median aponeurosis. (C. Roux, "Beiträge zur Kenntniss der Aftermuskulatur des Menschen," Arch. f. mikrosk. Anat., 1881.)

**Relations.**—The upper or pelvic surface of the levator ani is in contact with the recto-vesical fascia, which intervenes between the muscle and the rectum and prostate. The lower or perineal surface, invested by the thin anal fascia, is covered by the fat which occupies the ischio-rectal fossa. The posterior border is adjacent to, and often continuous with, the coccygeus. Between the anterior borders of the right and left muscles the membranous part of the urethra passes downwards as it issues from the prostate.

The **coccygeus** or **levator coccygis** muscle is composed of fleshy and tendinous fibres, forming a thin, flat, and triangular sheet, which arises by its apex from the spine of the ischium, and from the inner surface of the obturator fascia above the spine, and is inserted by its base into the border of the coccyx and the lower part of the sacrum.

**Relations.**—The internal or pelvic surface of this muscle assists in supporting the rectum : its external surface is intimately united to the small sacro-sciatic ligament.

The levatores ani and coccygei muscles together have been appropriately named by Meyer the *pelvic diaphragm*.

**Varieties.**—The coccygeus is sometimes inserted wholly into the side of the sacrum. A few fleshy and tendinous fibres are occasionally seen passing from the lower part of the anterior surface of the sacrum to the coccyx, constituting the *sacro-coccygeus anticus* or *curvator coccygis* muscle.

**b. GENITO-URINARY MUSCLES.**—These are three muscles on each side, placed immediately beneath the superficial perineal fascia, viz., the transversus perinei, the ischio-cavernosus, and the bulbo-cavernosus, and one single muscle more deeply placed, between the layers of the triangular ligament, viz., the constrictor urethræ.

The **transversus perinei** muscle arises from the inner side of the ischial tuberosity, immediately above (deeper than) the origin of the ischio-cavernosus, and is directed obliquely forwards and inwards to unite with the muscle of the opposite side, as well as with the external sphincter and bulbo-cavernosus, at the central point of the perineum. Behind this muscle the superficial perineal fascia turns upwards to join the base of the triangular ligament.

**Varieties.**—The transverse muscle is exceedingly variable in its arrangement. It is sometimes absent, and at other times one or more small muscular slips are found lying superficial to or on the same plane with it, in front or behind. It may also be inserted wholly or in great part into the bulbo-cavernosus or external sphincter. A muscular slip is occasionally found springing from the fascia at the lower border of the gluteus maximus, and running into the transversus perinei or being inserted into the triangular ligament—*M. gluteo-perinealis*, Krause.

The **ischio-cavernosus** or **erector penis** muscle, embracing the crus penis, arises from the inner part of the tuberosity and ramus of the ischium behind and on each side of the attachment of the crus. From this origin the fleshy fibres are directed forwards to a tendinous expansion which is spread over the surface of the crus, and is inserted into the outer and under sides of that body towards its fore part.

**Variety.**—Houston has described ("Dublin Hosp. Reports," v. 458), under the name of *compressor venæ dorsalis penis*, a muscular slip separated from the outer part of the erector penis by an interval, though apparently belonging to that muscle. It arises from the pubic ramus, in front of the origin of the erector muscle and the crus of the penis, and, passing upwards and forwards, is inserted by joining its fellow in a median aponeurosis above the dorsal vein. This muscle, which is well developed in the dog and several other animals, is by no means constant in the human subject.

The **bulbo-cavernosus** or **ejaculator urinæ** muscle is united with its fellow of the opposite side in a median tendinous raphé continued forwards from the central point of the perineum, and the two muscles cover the bulb and the adjacent part of the corpus spongiosum urethræ.

The fleshy fibres arise from the central point of the perineum and from the median raphé, and are directed outwards and forwards on the surface of the corpus spongiosum. The greater number ascend between the crus penis and the corpus spongiosum, and end on the dorsum of the latter body by joining those of the opposite side in a strong aponeurosis. At the fore part a small portion of the muscle passes to the outer side of the corpus cavernosum, where it is attached in front of the ischio-cavernosus, sending also a tendinous expansion over the dorsal vessels of the penis; and the posterior fibres, shorter than the anterior, are inserted by the side of the bulb into the under surface of the triangular ligament.

The fibres which invest the most prominent part of the bulb are more or less distinct from those contiguous to them, and have been described by Kohelt as forming a separate muscle, to which he has given the name *compressor hemisphæricum bulbi*. The fibres of this muscular slip are connected by a small tendon, above the urethra, with the corresponding part of the opposite side.

The **constrictor** or **compressor urethræ** muscle consists of fibres attached on each side to the ischio-pubic rami, as well as to the adjacent surfaces of the fascial layers between which it is enclosed, and extending for the most part transversely across the subpubic arch, some of them in front of, and others behind, the membranous part of the urethra, for which they form a kind of sphincter. In some bodies a median tendinous raphé divides the muscle more or less completely into lateral halves. The hindmost fibres of this muscle are sometimes described separately under the name of *transversus perinei profundus*.

While the greater number of the muscular fibres contained between the layers of the triangular ligament pass transversely from side to side as above stated, there are usually to be recognized, especially in well-developed subjects, other collections which take different directions. Thus, one set of fibres passes obliquely from behind forwards and inwards; another set surrounds the urethra circularly; and on the inferior surface of the constrictor muscle a longitudinal slip of variable breadth extends from apex to base of the triangular ligament. All these bundles are, however, intimately connected together, and pass gradually into one another, so that they cannot properly be regarded as forming distinct muscles. The longitudinal fasciculi described by Wilson as passing from the pelvic surface of the pubis on each side, and meeting behind the membranous part of the urethra, have not been generally recognized by succeeding anatomists. (On the arrangement of the constrictor urethræ muscle, as well as of the other muscles and fasciæ of the perineum, see Lesshaft, "Ueb. einige d. Urethra umgebenden Muskeln und Fascien," Arch. f. Anat., 1873; Cadiat, "Etude sur les muscles du périnée en particulier sur les muscles dits de Wilson et de Guthrie," Journ. de l'anat., 1877; Holl, "Ueb. d. Verschluss des männl. Beckens," Arch. f. Anat., 1881; Tschaussow, "Resultate makro- und mikroskopischer Untersuchungen üb. d. tiefen Muskeln d. vord. Damms b. Manne u. üb. d. Verhalten d. Venen zu ihnen," Arch. f. Anat., 1883; Cros, "Rech. anat. sur les muscles de Wilson et de Guthrie," Montpellier, 1887.)

**Relations.**—The constrictor urethræ is separated from the levator ani by the upper layer, and from the superficial muscles of the fore part of the perineum by the lower layer of the triangular ligament. Embedded in the substance of the muscle on each side at its origin from the bone are the pudic vessels and the dorsal nerve of the penis, and more mesially are the vessels of the bulb and the gland of Cowper.

Within the constrictor muscle the membranous part of the urethra is surrounded by involuntary muscular fibres which form part of its proper wall, and will therefore be referred to in the description of the reproductive organs in Vol. III.

**Nerves.**—The external sphincter receives offsets from the fourth sacral nerve and the inferior hæmorrhoidal branch of the pudic nerve; the levator ani from the fourth sacral and the perineal branch of the pudic; and the coccygeus from the fourth sacral nerve.

As to *size*, the ulnar artery presents some varieties which are generally accompanied by deviations of an opposite and compensating character in the radial artery; but as these influence the extent of the distribution of the ulnar artery in the hand, they will be noticed in connection with the varieties of the vessels of that part.

*Branches.*—The *anterior* and *posterior ulnar recurrent* branches frequently arise by a common trunk. One or both have been seen to arise from the brachial artery.

The *anterior* and *posterior interosseous arteries* are occasionally given separately from the ulnar. The *anterior interosseous artery* has been seen of large size, reinforcing the radial or, more rarely, the ulnar artery by means of a transversely directed branch joining the main trunk at the wrist (enlargement of an anterior carpal artery); or its posterior branch has been seen joining the radial on the back of the hand. More frequently it gives off a large median artery.

*Median artery.*—The branch accompanying the median nerve is sometimes much enlarged, and in such cases may be regarded as a reinforcing vessel. It is generally a branch of the anterior interosseous, but sometimes of the ulnar; and more rarely a median branch has been met with descending from the brachial or axillary artery. Generally accompanying the median nerve beneath the annular ligament, occasionally however passing over the front of the ligament, it enters the palm of the hand and there ends, most frequently by joining the superficial palmar arch, sometimes by forming digital branches, and in other cases by joining digital branches given from other sources (figs. 360, 369).

#### SUPERFICIAL PALMAR ARCH (IV).

The superficial palmar arch is the continuation of the ulnar artery in the hand. As it passes over the anterior annular ligament the ulnar artery gives off its deep branch, and a little below that band it turns outwards across the palm of the hand towards the middle of the muscles of the thumb. In this course the vessel describes a curve, having its convexity directed towards the fingers, and extending downwards somewhat lower than a line on a level with the metacarpo-phalangeal articulation of the thumb. The arch is sometimes completed on the outer side by inosculating with the superficial volar branch of the radial artery, and in many cases it is connected also, by a small branch, with the *radialis indicis* or *princeps pollicis* artery at the lower border of the *adductor transversus pollicis* muscle.

The superficial palmar arch rests at its commencement on the annular ligament of the wrist, and slightly on the short muscles of the little finger; then on the tendons of the superficial flexor of the fingers, and the divisions of the median and ulnar nerves, the latter nerve accompanying the vessel for a short distance. It is covered towards the ulnar border of the hand by the *palmaris brevis*, and afterwards by the palmar fascia and the integument.

*BRANCHES.*—The superficial palmar arch gives off small twigs to the superficial muscles and integument of the palm, and the following larger branches to the fingers:—

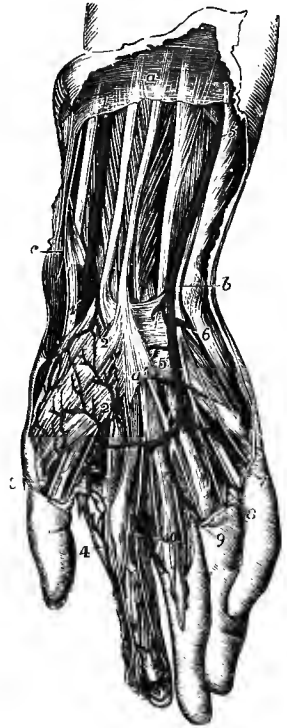
The **digital arteries** (v), usually four in number, proceed downwards from the convexity of the palmar arch to supply both sides of the inner three fingers, and the ulnar side of the fore finger. The *first digital* branch (often derived from the deep arch) inclines inwards to the ulnar border of the hand, and, after giving minute offsets to the muscles of the little finger, runs along the inner margin of its phalanges. The *second* runs along the fourth intermetacarpal space, and at the root of the fingers divides into two *collateral* branches, which proceed along the contiguous borders of the ring and little fingers. The *third* is similarly distributed to the ring and middle fingers; and the *fourth* to the middle and index fingers. The thumb and the radial side of the index finger are supplied from the radial artery.

The digital arteries descend in the intervals between the flexor tendons, resting upon the digital nerves and *lumbricales* muscles, as far as the clefts of the fingers,

where they are joined by the palmar interosseous arteries from the deep arch, and by inferior perforating arteries from the back of the hand. On the sides of the fingers, each collateral artery lies beneath the corresponding nerve, and gives branches which supply the sheaths of the tendons and the joints, some of them anastomosing across the front of the bones with similar branches from the opposite side. At about the middle of the last phalanx, the two arteries of each finger converge and form an arch, from which numerous branches proceed to supply the skin and subcutaneous tissue of the tip of the finger. Other offsets pass to the

Fig. 365.—SUPERFICIAL DISSECTION OF THE LOWER PART OF THE FOREARM AND THE HAND, SHOWING THE RADIAL AND ULNAR ARTERIES, THE SUPERFICIAL PALMAR ARCH, AND THE ACCOMPANYING NERVES. (R. Quain.)  $\frac{1}{2}$

*a*, on the deep fascia of the forearm, between the tendons of the palmaris longus and flexor carpi radialis muscles; *b*, points by a line crossing the pisiform bone to the ulnar nerve; *c*, points to the styloid process of the radius and twigs of the radial nerve; 1, radial artery lying on the flexor longus pollicis; 1', the same passing beneath the tendons of the ext. ossis metacarpi and ext. brevis pollicis; 2, superficial volar branch, piercing the short muscles of the thumb and emerging below to join the superficial palmar arch; 3, external branch of the princeps pollicis; 4, radialis indicis; a branch from the superficial arch is seen joining the internal branch of the princeps pollicis; 5, ulnar artery lying upon the flexor profundus digitorum; 5', the same descending on the anterior annular ligament to form the superficial palmar arch; 6, deep branch of the ulnar artery passing between the abductor and flexor minimi digiti to join the deep arch, accompanied by the deep branch of the ulnar nerve; 7, 8, 9, 10, digital arteries from the superficial arch; 7, and 8, are accompanied by the digital branches of the ulnar nerve, and 3, 4, 9, and 10, by branches of the median nerve.



structures on the back of the second and third phalanges, and form a close plexus beneath the matrix of the nail.

The varieties observed in the branches of the superficial palmar arch will be noticed after the description of the deep arteries of the hand.

THE DEEP BRANCH OF THE ULNAR ARTERY arises at the commencement of the superficial palmar arch, immediately below the pisiform bone; passing deeply into the palm between the abductor and short flexor muscles of the little finger, it inosculates with the termination of the radial artery, and so completes the deep palmar arch.

#### RADIAL ARTERY (IV).

The radial artery appears by its direction to be the continuation of the brachial, although it does not equal the ulnar in size. It extends along the front of the forearm as far as the lower end of the radius, below which it turns round the outer border of the wrist, and descends to the upper end of the space between the metacarpal bones of the thumb and fore finger: there it passes forwards into the palm of the hand, supplies digital branches to the thumb and index finger, and terminates in the deep palmar arch. In consequence of the changes in its direction, the course, relations and branches of the radial artery may be separately described in the forearm, at the wrist and in the hand:

IN THE FOREARM.—The radial artery, commencing at the point of bifurcation

rectus by the separation of the fibres attached to the atlas and axis respectively, and in the obliquus by a connection being formed with the transverse process of the atlas, which acquires a much greater prominence in mammals, and thus carries outwards the differentiated obliquus superior and inferior, leaving the interval known as the suboccipital triangle. (Chappuis, "Die morphologische Stellung der kleinen hinteren Kopfmuskeln." Zeitschr. f. Anat. u. Entwicklsgesch., 1876.)

In the postaxial part of the trunk in tailed animals this dorsal series of muscles is continued backwards without interruption as the superior caudal muscles, and in man a muscular slip is occasionally found developed as a sacro-coccygeus posticus; but in general, owing to the slight development of the caudal vertebrae, and the large size of the pelvic girdle, the dorso-lateral muscles in man do not extend beyond the upper part of the sacrum.

In the head the dorsal musculature is in great measure suppressed, in accordance with the absence of mobility in the cranium, and the protovertebrae which have been observed in this region in the early embryo for the most part disappear without forming muscles; but in the first three segments the protovertebrae undergo development and give rise to the orbital muscles. From the first muscle-segment are formed the muscles supplied by the third nerve, viz., the superior, internal and inferior recti, the inferior oblique, and the levator palpebrae superioris, which is a derivative of the superior rectus. The second segment furnishes the superior oblique supplied by the fourth nerve, and the third segment the external rectus supplied by the sixth nerve.<sup>1</sup>

The *ventro-lateral* muscle, while equally simple in the lowest vertebrates with the dorso-lateral, shows in the higher animals a much greater degree of complexity, both of form and attachments. It springs from the ventral surfaces and tips of the transverse processes of the vertebrae, as well as from the lateral septa and general fascial investment; and by means of its connection with the last-mentioned structure the superficial portion of the muscle is prolonged dorsally, and gains an attachment to the spinous processes, so that it covers the dorso-lateral muscle almost completely. Ventrally, it extends round the visceral cavity to the median line, where it is separated from the corresponding mass of the opposite side by the haemal septum, and it thus forms the whole thickness of the muscular portion of the body-wall. It comes into connection with the orifices only of the alimentary canal, where portions of the right and left muscles become united and form the external sphincters.

According to the direction of its fibres the trunk portion of this muscular mass may be divided into two groups of muscles, a *mesial* with longitudinally directed fibres and a *lateral* with obliquely or transversely directed fibres.

The *mesial* group is represented in man by the rectus abdominis, the sterno-hyoid, sternothyro-hyoid, and omo-hyoid (the posterior belly of which has, however, acquired an oblique direction by extending its origin to the scapula), the genio-hyoid and genio-glossus. The other tongue-muscles supplied by the hypoglossal nerve, although differing widely in direction, are probably derived from the same source. In fishes the oblique fibres are almost entirely wanting, and in the lower vertebrates generally they are less developed than the longitudinal. On the other hand, in the higher forms, as in man, the oblique fibres are the more important, the longitudinal fibres being in certain places (thorax) absent altogether, or only present as a more or less developed thoracic prolongation of the rectus. In some animals, as Lepidosiren, the oblique fibres of the abdomen are directly continuous with the longitudinal, but in man greater differentiation exists, for the lateral muscles are merely prolonged forwards as strong aponeuroses which form a fibrous sheath for the rectus on each side of the middle line. In man these longitudinal fibres have little or no connection with the muscles of the limbs, but in urodeles they are continued outwards upon the ventral aspect of each limb as part of the pectoralis major and gracilis.

Longitudinal fibres are also found in the pyramidalis, a small vestigial muscle in man, but which in marsupials and monotremes is extremely large; and as rare varieties between the lateral oblique muscles forming a *lateral rectus*, which consists of a few fibres running between the lower ribs and the ilium, or over the thorax as a supracostal muscle. Posteriorly again the longitudinal direction is maintained by certain fibres of the quadratus lumborum. The longitudinal muscles probably lie in the same plane with the middle stratum of the lateral muscles.

The *lateral* group of trunk-muscles, distinguished by the oblique or transverse direction of their fibres, is divisible usually into three or it may be into four layers. In the lowest vertebrates this stratification does not occur, but in the higher animals it is coincident with the differentiation of separate muscles. Of these layers three are very constant in their relations and extent, but the fourth, which is the most superficial, though very constantly

<sup>1</sup> In the lower vertebrates some of the hinder protovertebrae of the head give rise to muscles connecting the shoulder-girdle with the cranium (see Vol. I, Embryology, p. 161), but this appears not to be the case in mammals, where the somites that have been recognised in the occipital region are said to disappear in the course of subsequent development.

found, is only a partial layer. In man these layers are represented, the first three by the abdominal muscles, the external and internal oblique and transversalis respectively, and the fourth by the *platysma myoides* with the facial, auricular and epicranial muscles.

The transverse or deepest of these layers is represented by the transversalis muscle, which is prolonged into the thorax by the *triangularis sterni*. The sternal and costal portions of the diaphragm and the subcostals, small in man, but very largely developed in birds, serpents, &c., as the *retrahentes costarum* and *levator costarum interni*, must also be referred to this layer, as well as a part at least of the levator ani or pelvic diaphragm.

The muscles of the deep layer, together with the hypaxial group, are sometimes regarded as forming a distinct set corresponding to the visceral musculature of the head, which they resemble in being innervated by fibres (the non-gangliated splanchnic efferent nerves of Gaskell) of rather smaller calibre than those supplying the skeletal muscles generally (somatic muscles of Gaskell); but evidence is wanting to show that they differ in origin and development from the rest of the ventro-lateral muscle (except in the case of the diaphragm), and that they agree in these respects with the visceral head-muscles.

The internal oblique is directly continuous with the lower internal intercostals, and the external intercostals and levatores costarum, as well as the serrati postici, are differentiated portions of the same layer. In series with these are the scaleni and anterior intertransverse muscles in the neck, and the quadratus lumborum and lateral intertransverse muscles in the loins. Inferiorly the middle layer furnishes the coccygeus, originally the ischio-caudal or abductor caudæ muscle, and possibly also part of the levator ani.

The external oblique layer is prolonged upwards upon the side of the chest, and outwards upon the upper limb as serratus magnus with levator anguli scapulæ and rhomboidei, pectorales, and latissimus dorsi, and between the limb and head as sterno-cleido-mastoid and trapezius. The superficial perineal muscles also belong to this layer. They may be derived from a sphincter cloacæ, which becomes divided into a posterior portion (sphincter ani externus) and an anterior portion (bulbo-cavernosus) with the separation of the urogenital passage from the intestinal canal: the ischio-cavernosus and transversus perinei are detached portions of the anterior division (Gegenbaur).

The ventral or visceral musculature of the head exhibits a special segmentation in accordance with that of the visceral portion of the head-skeleton, and the muscles are for the most part arranged in groups corresponding to the cephalic visceral arches of the embryo, in which they are developed. In connection with the mandibular arch there are two such groups of muscles, all of which are supplied by the fifth nerve. The one, placed more dorsally or laterally, includes the muscles of mastication, temporal, masseter and pterygoids, with the tensor palati lying on the anterior or preaxial side of the Eustachian tube (first visceral cleft) and the tensor tympani. The other, occupying a ventral or mesial position, is differentiated into mylo-hyoid and anterior belly of the digastric, which, acquiring an attachment to the hyoid bone, cover over the prolongation of the longitudinal trunk-muscles in the floor of the mouth. The muscles of the hyoid arch are the stylo-hyoid, posterior belly of the digastric, and stapedius, all supplied by the facial nerve. The levator palati, arising on the hinder or postaxial side of the Eustachian tube, and the palato-glossus correspond in position to the inner side of this arch, but by innervation they are associated with the pharyngeal muscles. In the third arch is developed the stylo-pharyngeus, supplied by the glosso-pharyngeal nerve; while the fourth does not appear to furnish any corresponding muscle. The constrictors of the pharynx result from the differentiation of the dorsal muscular wall of the cephalic portion of the alimentary tube, and the palato-pharyngeus has a similar origin, being developed in the hinder part of the palatine process by which the primitive mouth and pharynx are subdivided.

The fourth or most superficial layer of the ventro-lateral muscle, corresponding to the panniculus carnosus of animals, seems to be mainly developed from the cutaneous surface of the external layer. In man this layer exists only upon the surface of the head and neck, and very slightly over the shoulder. In the neck it forms the subcutaneous colli or *platysma myoides*, and those slight continuations downwards which are occasionally found upon the surface of the pectoral and deltoid muscles. On the head it furnishes the epicranial muscles with the intervening aponeurosis, the auricular and the facial muscles. Although thus widely distributed over the head and neck, this layer is originally derived from the hyoid arch, in which region it first makes its appearance in the embryo, and whence it extends downwards and upwards in the course of development. The various muscles resulting from its segmentation are therefore all innervated by branches of the facial trunk, which is the nerve of the hyoid arch, and the ramifications of which have spread over areas belonging to other nerves *pari passu* with the expansion of the muscular sheet. (Rabl, "Ueber das Gebiet des Nervus facialis," *Anatom. Anzeiger*, 1887.)

The evolution of the complex system of superficial head-muscles in man and apes from a simpler arrangement, such as is met with in lemurs, has been fully studied by G. Ruge. In the latter animals the cutaneous muscular layer is double; the more superficial is the *platysma-*

*sheet* proper, while the deeper, consisting of transverse fibres, is known as the *sphincter colli*. From the platysma-sheet a part extends upwards behind the ear (occipito-auricular muscle) and furnishes the occipitalis with the retrahens auriculam, as well as the transverse and oblique muscles on the back of the pinna; the occasional occipitalis minor (p. 296) is a vestige of the primitive connection. In front of the ear the prolongation of this sheet is more extensive, and undergoes greater development and differentiation:—1, a direct continuation of the platysma-fibres over the border of the lower jaw gives rise to the depressor labii inferioris and levator menti; 2, a second portion (inferior auriculo-labial) is for the most part suppressed in man, the muscles of the tragus and antitragus of the pinna being the sole remains; 3, a much larger portion (superior auriculo-labial) passes from the front of the ear, where it forms the muscles of the helix, to the upper lip as the zygomatic muscles, and extends upwards around the eye forming the orbicularis palpebrarum, from which again the corrugator supercillii, pyramidalis nasi and levator labii superioris alæque nasi are segmented off; while above this, 4, an auriculo-frontal tract furnishes the attollens and attrahens auriculam and the frontalis.

The deep layer, or sphincter colli, in man is suppressed in the neck, but is largely developed over the lower part of the face, forming most of the musculature of the lips and mouth. From it proceed the orbicularis and the muscles contributing thereto, viz., the buccinator, levator anguli oris and depressor anguli oris, as well as the levator labii superioris. Continued from the levator anguli oris is the compressor naris, of which the depressor alæ nasi is an extension downwards. The depressor anguli oris makes its way to the surface through a cleft in the platysma-sheet; its inner fibres curving beneath the chin to join those of the opposite side give rise to the occasional transversalis menti, and the risorius is similarly detached from its outer edge. (G. Ruge, "Untersuchungen über die Gesichtsmuskulatur der Primaten," Leipzig, 1887.)



# ANGEIOLOGY

By G. D. THANE.

IN this section will be included the descriptive anatomy of the heart and of the principal blood and absorbent vessels. The account of the minute structure of the blood-vessels and of the lymphatic vessels and glands is given in the part of Volume I that treats of General Anatomy; and the arrangement and distribution of the smaller vessels within the several tissues and organs of the body are described in connection with the microscopic anatomy of those parts.

## 1.—THE HEART.

The heart is situated in the thorax, between the two lungs, and, together with the adjacent parts of the great vessels which convey blood to and from it, is enclosed



Fig. 304.—TRANSVERSE SECTION OF THE CHEST OF A FŒTUS, PASSING IN FRONT THROUGH THE JUNCTION OF THE FIFTH COSTAL CARTILAGE WITH THE STERNUM. (Allen Thomson.)

The sketch represents the upper surface of the lower section; the division is carried nearly in a horizontal plane. *s*, sternum; *c*, body of the eighth dorsal vertebra; *h*, right, and *h'*, left ventricle; *æ*, œsophagus; *pn*, left pneumo-gastric nerve; the right pneumo-gastric is behind the œsophagus; *phr*, phrenic nerves; *a*, aorta; *v a*, vena azygos major; *d*, thoracic duct; 1, 1, cardiac pericardium; 2, in the anterior mediastinal space, the parietal pericardium; 2', 2', cavity of the pericardium; 3, 3, pulmonary pleura passing over the surface of the lungs, and reflected below their roots to form the ligamentum latum pulmonis, *l, l'*; 3', 3', the pleural cavities; 4, 4, parietal pleura, reflected in front at the mediastinum to the surface of the pericardium; *c, c*, walls of the chest including the ribs, pectoral muscles, &c.

by a membranous covering, the pericardium. These structures, covered on each side by the parietal pleura, constitute the chief part of the middle mediastinum, the largest division of the median thoracic septum which, extending from spine to sternum, separates the two pleural cavities. The heart lies nearer to the front than the back of the chest, but is for the most part separated from the anterior thoracic wall by the pleuræ and the thin anterior portions of the lungs.

#### THE PERICARDIUM.

This membranous sac, in which the heart is contained, is of a somewhat conical shape, its base resting on the diaphragm, while the upper narrower part surrounds the trunks of the great vessels. It consists of two layers, one external and fibrous, the other internal and serous.

The fibrous layer is a dense, unyielding membrane, consisting of fibres which interlace in every direction. This layer is attached below to the upper surface of

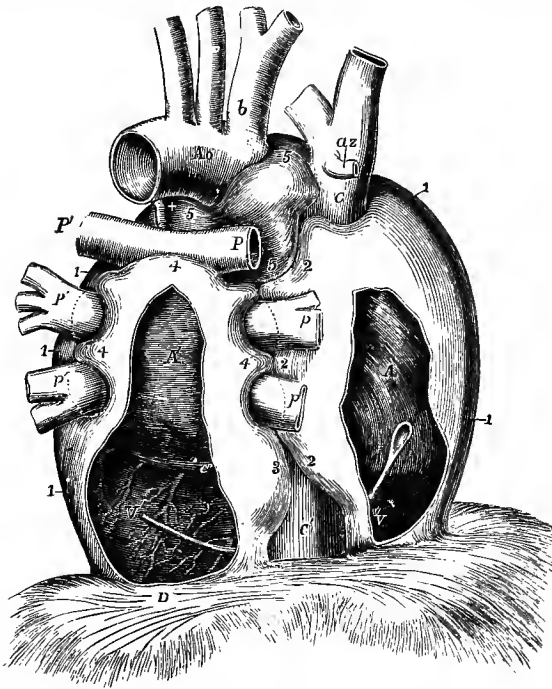


Fig. 305. — SEMIDIAGRAMMATIC VIEW OF THE PERICARDIUM FROM BEHIND, DESIGNED TO SHOW THE PRINCIPAL INFLECTIONS OF THE SEROUS SAC ROUND THE GREAT VESSELS. (Allen Thomson.)  $\frac{1}{2}$

The drawing is taken from preparations in which the heart and vessels had been partially filled by injection, the pericardium inflated and dried in the distended state, and the fibrous continuation on the vessels removed. By the removal of a portion of the pericardium from behind the right and left cavities of the heart, the position of that organ is made apparent. *A*, right auricle; *A'*, left auricle; *V*, right ventricle; *V'*, left ventricle; *Ao*, aortic arch; *b*, innominate artery; *C*, vena cava superior; *az*, azygos vein; *C'*, vena cava inferior; *c'*, great coronary vein; +, ligamentum arteriosum; *P*, right, *P'*, left pulmonary artery; *p*, right, *p'*, left pulmonary veins; *D*, central tendon of diaphragm; 1, sac of pericardium; 2, the portion on the right side which partially surrounds the superior vena cava, the right pulmonary veins, and the inferior vena cava; 3, portion

on the left side which partially surrounds the inferior vena cava; 4, portion which is extended upwards behind the left auricle, and partially folds over the pulmonary arteries and veins, meeting between these different vessels the extensions of the sac from the right and left; 5, upper part of the transverse sinus passing behind the aortic and pulmonary arterial trunks. A bent probe is passed within the pericardium from behind the right auricle, in front of the inferior vena cava, to the back of the left ventricle, which may indicate the place where the large undivided sac of the pericardium is folded round that vein.

the diaphragm (fig. 305, *D*), partly to the central tendon, partly to the adjoining muscular surface, especially on the left side. Near the median line the connection is very firm, the fibrous structures being continuous; elsewhere the attachment is more lax, and is effected mainly by areolar tissue. The pericardium is supported also in front by two variable fibrous bands, the superior and inferior sterno-pericardial ligaments of Luschka, which pass to it from the manubrium and ensiform process of

the sternum. The fibrous layer is continued above for some distance along the large blood-vessels in the form of tubular prolongations, which become gradually lost upon their external coats. The superior vena cava, the four pulmonary veins, the aorta, and the right and left divisions of the pulmonary artery, receive investments of this kind.

The serous layer of the pericardium not only lines the fibrous layer, but, like other serous membranes, is reflected on the surface of the viscus which it invests. It has, therefore, a visceral and a parietal portion. The parietal portion adheres firmly to the fibrous membrane. It is reflected and becomes continuous with the visceral portion along the great vessels, about 1 to 1½ inches from the base of the heart. For this distance the serous membrane encloses the aortic and pulmonary arterial trunks in a common tubular sheath, so that a passage, the *transverse sinus* of the pericardium, is formed between these vessels in front and the auricles of the heart behind (fig. 305, 5, 5). It is reflected also upon the superior vena cava (c), and on the four pulmonary veins (p, p'), and forms a deep recess behind, between the entrance of the right and left veins into the left auricle. The inferior vena cava (c') receives only a very scanty covering of this membrane (3, 2), inasmuch as that vessel enters the right auricle almost immediately after passing through the diaphragm, and is only partially surrounded by a reflection of the pericardium in the narrow interval between these parts. None of the vessels, indeed, joining the heart, with the exception of the aorta and pulmonary artery where they are united together, receive a complete covering from the pericardium, or can be said to be entirely enveloped in the sac.

When the left pulmonary artery and subjacent pulmonary vein are separated, a triangular fold of the pericardium, the *vestigial fold* of Marshall, is seen between them. It is from half to three-quarters of an inch in length, and from half to one inch deep, and is formed by a duplicature of the serous layer, including areolar and fatty tissue, together with vessels and nerves. It also encloses a vestige of the left superior vena cava (duct of Cuvier) existing in early embryonic life, in the form of a small fibrous band which may often be traced from the left superior intercostal vein above the pulmonary artery downwards to the side of the left auricle, where it is lost in a narrow streak coursing round the root of the lower left pulmonary vein.

Beneath the serous layer of the pericardium there are more or less developed accumulations of fat, especially in the grooves of the heart, surrounding the cardiac vessels and nerves, along the sharp margin of the right ventricle, around the arterial trunks, and sometimes on the surface of the diaphragm. One small mass often causes a transverse projection of the serous membrane on the right side and front of the ascending aorta about an inch above its origin, marking the upper limit of the right auricular appendix. Minute villiform processes are also common, occurring singly or in tufts chiefly along the edges of the auricles.

The pericardium is in relation in front and behind with the anterior and posterior mediastina and their contents. Anteriorly also it is covered by the pleuræ and to some extent by the lungs, except below, where it approaches the surface in the angular space to the left of the lower part of the sternum. At the sides it is in contact with the phrenic nerves, as well as with the pleuræ and their contained viscera. Its relations to the diaphragm and great vessels have been already noticed.

In structure the serous layer of the pericardium agrees with that of serous membranes generally, being formed of connective tissue containing a network of elastic fibres, blood-vessels and lymphatic vessels.

**Vessels and nerves.**—The parietal pericardium is supplied with blood by small offsets of the descending thoracic aorta, by the superior phrenic and pericardial branches of the

internal mammary arteries, and by twigs of the inferior phrenic arteries. The veins run to the azygos, internal mammary and phrenic trunks. Its lymphatics pass to the mediastinal glands. Nervous filaments are furnished to it by the phrenics, vagi and sympathetic. The visceral pericardium is supplied by the vessels and nerves of the heart.

### THE HEART.

The heart is a hollow muscular organ, divided by a longitudinal septum into a right and a left half, each of which is again subdivided by a transverse constriction into two compartments, communicating with each other, and named **auricle** and **ventricle**. Its general form is that of a blunt cone. Enclosed in the pericardium, it is placed behind the sternum and the costal cartilages (fig. 318, p. 366), the broader end or base being directed upwards, backwards, and to the right, and placed opposite the sixth, seventh and eighth

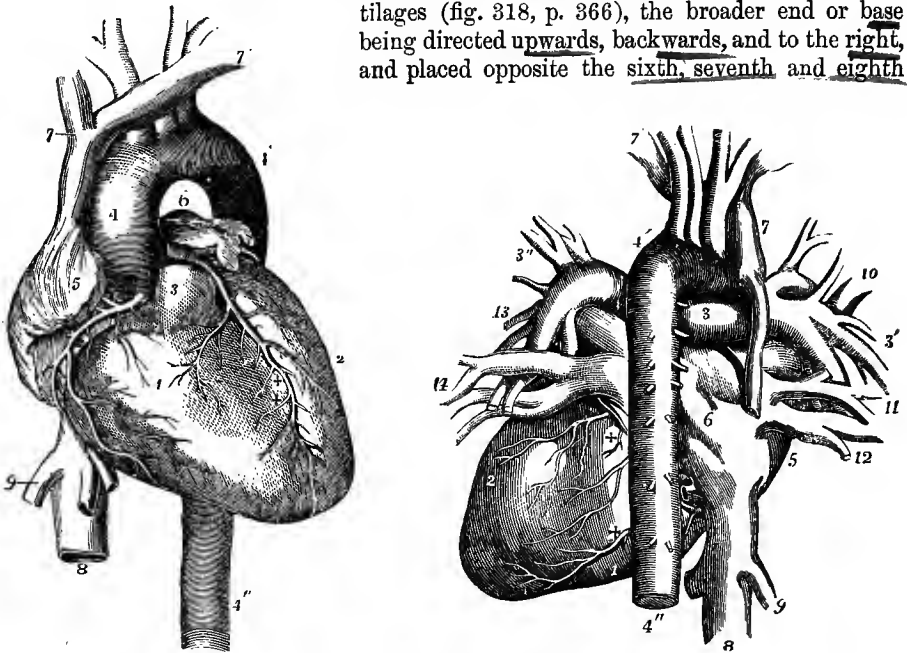


Fig. 306.—THE HEART AND GREAT VESSELS FROM BEFORE. (R. Quain.)  $\frac{1}{2}$

The pulmonary artery has been cut short close to its origin in order to show the first part of the aorta. 1, right ventricle; 2, left ventricle; 3, root of pulmonary artery; 4, 4', arch of aorta; 4'', descending aorta; 5, appendix and anterior part of right auricle; 6, those of left auricle; 7, 7', innominate veins joining to form the superior vena cava; 8, inferior vena cava below the diaphragm; 9, one of the hepatic veins; +, right, ++, left coronary artery.

Fig. 307.—THE HEART AND GREAT VESSELS FROM BEHIND. (R. Quain.)  $\frac{1}{2}$

1, right ventricle; 2, left ventricle; 3, right pulmonary artery; 3', its branches in the root of the right lung; 3'', the same of the left; 4', arch of aorta; 4'', descending aorta; 5, right auricle; 6, is placed on the division between the right and left auricles; 7, superior vena cava; 7', left innominate vein; 8, inferior vena cava; 9, right hepatic vein; 10, 11, 12, right pulmonary veins; 13, 14, left pulmonary veins; +, +, branches of the right and left coronary arteries.

dorsal vertebræ; while the apex points downwards, forwards, and to the left. In the living subject its stroke against the wall of the chest is felt in the space between the cartilages of the fifth and sixth ribs, a little below and to the inner side of the left nipple ( $3\frac{1}{2}$  inches from the middle line of the sternum and  $1\frac{1}{2}$  inch below the nipple): in the dead body the apex is a little higher than during life. The heart,

therefore, has a very oblique position in the chest, and projects farther into the left than into the right half of the cavity. Its position is affected to a certain extent by that of the body; thus it comes more into contact with the anterior wall of the chest when the body is in the prone posture or is lying on the left side. In inspiration, on the other hand, when the diaphragm sinks and the lungs expand, it recedes slightly from the chest-wall.

The heart is attached at its base to the great blood-vessels, and the serous layer of the pericardium is here continued onto it. Otherwise the heart is entirely free within the sac of the pericardium. The convex anterior surface looks somewhat

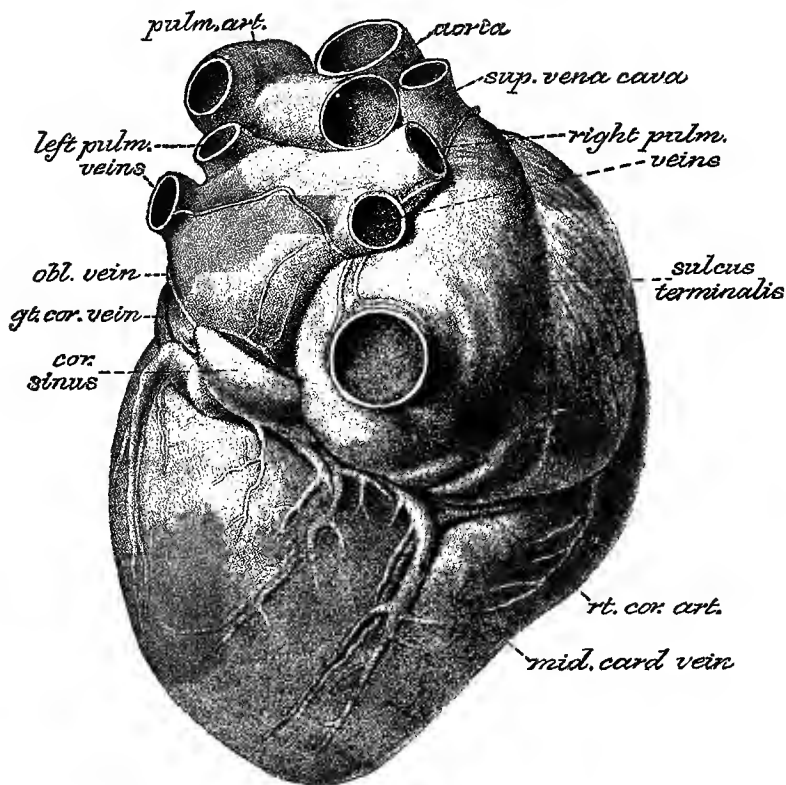


Fig. 308.—VIEW OF THE INJECTED HEART FROM BEHIND AND BELOW. (His.)  $\frac{3}{4}$

upwards as well as forwards towards the sternum and costal cartilages: from these it is for the most part separated by the pleuræ. The lungs also advance over it to some extent, and encroach still farther during inspiration, so as in that condition to leave only a triangular part, not more than two square inches in extent, uncovered.<sup>1</sup> The posterior or under surface is flattened, and rests on the diaphragm. Of the two borders or margins formed by the meeting of the anterior and posterior surfaces, the right or lower border, called margo acutus, is comparatively thin, and is longer than the upper or left border, which is more rounded and named margo obtusus.

A deep transverse groove, the auriculo-ventricular furrow, divides the heart into

<sup>1</sup> This uncovered part may be marked off on the surface of the chest by two lines drawn from the point of the apex-beat to the middle line of the sternum, one horizontal, the other extending obliquely upwards to between the fourth cartilages.

the auricular and the ventricular portions; and on the ventricular portion two longitudinal *interventricular furrows*, situated one on the anterior, the other on the posterior surface, mark its division into a right and left chamber. They extend from the base of the ventricular portion, and are continuous one with the other a little to the right of the apex, which is thus formed entirely by the wall of the left ventricle. The *anterior interventricular furrow* (fig. 306, + +) is nearer to the left, and the *posterior furrow* (fig. 308) nearer to the right side of the heart, the right ventricle forming more of the anterior, and the left more of the posterior surface of the organ. In the furrows run the *coronary arteries and veins* with the *lymphatic vessels and nerves*, embedded in fatty tissue and covered by the *visceral layer* of the pericardium.

#### CAVITIES OF THE HEART.

The heart, as before remarked, contains four chambers or compartments, a right and a left auricle and a right and a left ventricle.

The **right auricle** (fig. 306, 5) is best brought into view on turning the heart somewhat to the left side; it is then seen to occupy the right and anterior portion

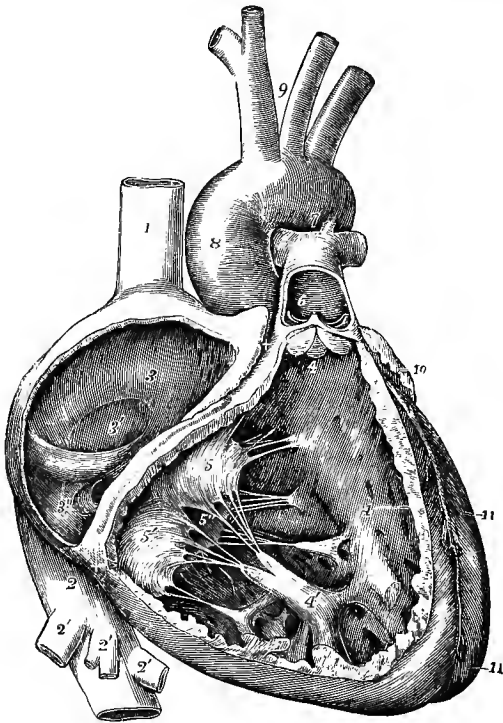


Fig. 309.—INTERIOR OF THE RIGHT AURICLE AND VENTRICLE, EXPOSED BY REMOVAL OF THE GREATER PART OF THEIR RIGHT AND ANTERIOR WALLS. (Allen Thomson.)  $\frac{1}{2}$

1, superior vena cava; 2, inferior vena cava; 2', hepatic veins; 3, septum of the auricles; 3', fossa ovalis, the Eustachian valve is just below; 3'', aperture of the coronary sinus with its valve; +, +, right auriculo-ventricular groove, a narrow portion of the adjacent walls of the auricle and ventricle having been preserved; 4, 4, on the septum, the cavity of the right ventricle; 4', large anterior papillary muscle; 5, infundibular, 5', right, and 5'', posterior or septal segment of the tricuspid valve; 6, pulmonary artery, a part of the anterior wall of that vessel having been removed, and a narrow portion of it preserved at its commencement where the pulmonary valve is attached; 7, the aortic arch close to the cord of the ductus arteriosus; 8, ascending aorta covered at its commencement by the auricular appendix and pulmonary artery; 9, placed between the innominate and left common carotid arteries; 10, appendix of the left auricle; 11, 11, left ventricle.

of the base of the organ. When thus viewed the auricle appears of a quadrangular form, the superior and inferior venæ cavæ occupying respectively the upper and lower posterior angles, while a tongue-shaped portion, the *auricular appendix* or *auricle proper*,<sup>1</sup> is seen to project from the anterior and upper angle and to turn to the left over the root of the aorta. The main part of the auricle, that into which the great veins directly pour their blood, is commonly named *sinus venosus* or *atrium*, to distinguish it from the auricular appendix. At the outer and posterior

<sup>1</sup> So termed from its resemblance to the external ear of some animals.

part of the atrium is a slight groove, the *sulcus terminalis* of His (fig. 308), which runs from the front of the termination of the superior to the right of the inferior vena cava, and marks off the portion of the atrium formed by the dilated end of the venous trunks (*saccus reuniens* of the embryo) from that belonging to the primitive auricle.

When opened, the interior of the right auricle presents a smooth and even surface over the inner and posterior wall of the atrium, but the appendix is ridged vertically with closely set reticulated muscular bands, and upon the right wall of the atrium

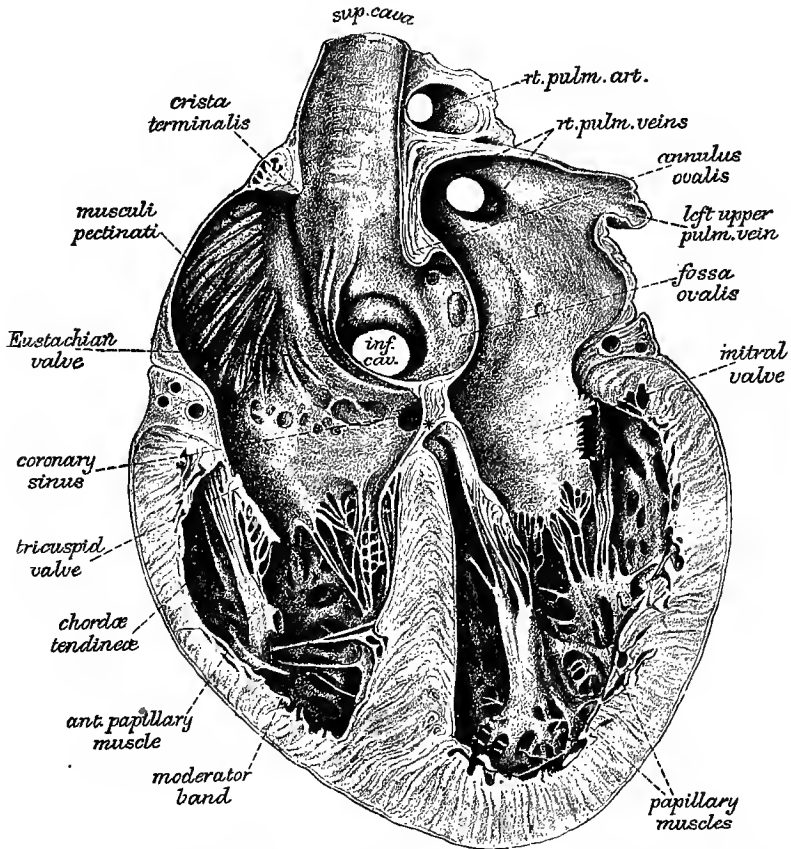


Fig. 310.—THE INTERIOR OF THE HINDER PORTION OF THE HEART, FROM BEFORE, SHOWING THE CONFORMATION OF THE INTERAURICULAR AND INTERVENTRICULAR SEPTA, THE CRISTA TERMINALIS AND MUSCULI PECTINATI OF THE RIGHT AURICLE, &C. (His.) §

\* portion of the septum between the right auricle and left ventricle, continued below into the septal flap of the tricuspid valve.

similar bundles are seen, here running more parallel with one another, like the teeth of a comb, whence they are named *musculi pectinati*. The musculi pectinati end posteriorly on a vertical ridge, the *crista terminalis* of His (fig. 310), corresponding to the *sulcus terminalis* externally.

The posterior wall corresponds with the partition between the two auricles (*septum auricularum*). At its lower part, and just above and to the left of the orifice of the inferior vena cava, is an oval depression, the *fovea* or *fossa ovalis* (fig.

309, 3'), the remains of the *foramen ovale* (*vestigium foraminis ovalis*), which is an open passage in the fetal heart from the right to the left auricle. The *fossa ovalis* is bounded above and at the sides by a prominent border, deficient below, the *annulus ovalis* or *isthmus Vieussenii*, while the floor of the fossa, formed by what was previously a valve, is thin and translucent; and not unfrequently a small oblique passage leading into the left auricle is left between it and the annular border. At the hinder part of the cavity are seen the orifices of the superior and inferior venæ cavæ, the former passing downwards and forwards, the latter, larger and placed a little farther back, being directed upwards and inwards. Just below the orifice of the superior cava is a slight projection, better marked in certain quadrupeds than in man, which has received the somewhat misleading name of *tubercle of Lower*.

In front of the orifice of the inferior vena cava, and partly covering it, is a crescentic fold of the lining membrane, the *Eustachian valve*, which is continuous by its convexity with the margin of the venous orifice, while its inner cornu is prolonged into the anterior limb of the annulus ovalis. This valve, which is very variable in character in the adult, being often cribriform or perforated with larger holes, is an important structure in the fetal heart, and serves the purpose of directing the stream of blood from the inferior vena cava through the foramen ovale into the left auricle. The other openings into the right auricle are—1, the *auriculo-ventricular aperture*, situated in front of the inferior vena cava at the lower and fore part of the cavity: it is *oval* in form and large, admitting *three fingers easily*; 2, the *orifice of the coronary sinus* of the heart (fig. 309, 3''), situated between the inferior cava and the auriculo-ventricular opening: this is guarded by a semicircular valve, sometimes fenestrated, which, although previously figured by Eustachius, is commonly named *valve of Thebesius*; 3, *openings* of three or four *anterior cardiac veins* from the surface of the right ventricle; and 4, the *foramina of Thebesius*, a number of small pits variously situated, some of which are merely recesses closed at the bottom, while others are the mouths of small veins (*venæ minimæ cordis*).

According to L. Langer the foramina Thebesii are not confined to the right auricle but occur in all the cavities of the heart; and into some of them, even in the ventricles, small veins which proceed from the muscular substance of the heart open.

The great coronary vein (fig. 308) is considerably dilated before it enters the auricle, and this dilated portion, which is imbedded in the posterior wall of the left auricle, is termed the *coronary sinus*. At the junction of the coronary vein with the dilated portion there is a valve consisting of one or two segments. Other small veins likewise enter the coronary sinus, each of them protected by a valve. One of these small veins, the *oblique vein* of Marshall, takes a straight course from the vestigial fold before mentioned, over the back of the left auricle, to open into the coronary sinus. This vein has no valve over its orifice: it, together with the coronary sinus, is to be looked upon as the remnant of the original left superior vena cava of the embryo (*vide antea*, p. 353).

The **right ventricle** (fig. 306, 1) occupies the chief part of the anterior surface of the heart, the right border, and a smaller portion of the posterior surface. It extends nearly, but not quite, to the apex. **Triangular** in shape, its upper and left angle is prolonged in a conical form to the commencement of the pulmonary artery: this part of the ventricle is named *conus arteriosus*, or *infundibulum*. The muscular wall of this ventricle is **thickest at the base**, and becomes thinner towards the apex. When the cavity is laid open (fig. 309) the septum of the heart is seen to bulge into it, so that in cross section this ventricle is **crescentic** in form (fig. 311, 6). At the base of the ventricle are two orifices, protected by valves; the *auriculo-ventricular*, of an oval form, and situated toward the right, and that of the *pulmonary artery*, smaller, more elevated, and towards the left. Between the two the wall of the cavity projects downwards, in the form of a thick rounded muscular

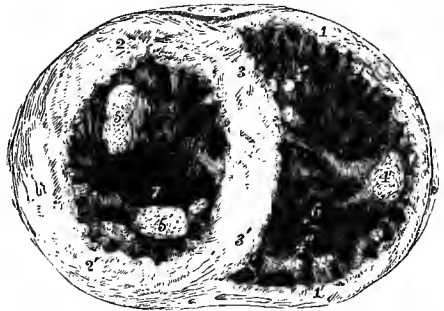


partition which corresponds to the beginning of the aorta from the left ventricle (fig. 317). The inner surface is marked by muscular bundles, *columnæ carneæ*, some of which are attached by each extremity to the wall of the ventricle and are free in the middle (*trabeculae*); others are only sculptured in relief, as it were, being continuous with the wall of the ventricle in their whole length; and a third set, forming two principal bundles, an anterior and a posterior, named *musculi papillares*, are attached at their base to the ventricular wall, and by the other end are prolonged into small tendinous cords (*chordæ tendineæ*), through which they are connected with the segments of the auriculo-ventricular valve. The inside of the *conus arteriosus* is smooth, and free from *columnæ carneæ*.

The valve guarding the right auriculo-ventricular opening is composed of three triangular segments or flaps, and is hence named *tricuspid*. The flaps are mainly formed of fibrous tissue covered by *endocardium*. At their bases they are continuous with one another, so as to form an *annular membrane* attached around the margin of the auricular opening: they are directed downwards, and are retained in position within the ventricle by the *chordæ tendineæ*, which are attached to their ventricular

Fig. 311.—CROSS SECTION OF THE VENTRICULAR PART OF THE HEART AT TWO-THIRDS FROM THE APEX, LOOKING DOWNWARDS INTO THE CAVITIES. (Allen Thomson.) §

1, 1', wall of right ventricle; 2, 2', wall of left; 3, 3', septum; 4, principal papillary muscle of right ventricle; 4', some *columnæ carneæ* on the septum near the front; 4'', posterior papillary muscles; 5, anterior or left, 5', posterior or right papillary muscles of left ventricle; 6, deepest part of cavity of right ventricle; 7, that of left ventricle at apex of heart.



surfaces and free margins. The middle part of each segment is thicker than the rest, while the marginal part is thin, transparent, and jagged at the edges (compare fig. 315, B, e, e'). Of the three segments, one (fig. 313, 5), which is usually the largest, is situated at the anterior and left part of the opening, and projects downwards between the latter and the infundibulum, whence it is called the *infundibular* or *left flap*; the second, or *right* (5') corresponds to the free margin of the ventricle; and the third, named *posterior* or *septal* (5''), is placed internally and posteriorly, against the ventricular septum.

The anterior papillary muscle (311, 4) is the larger and more constant: its *chordæ tendineæ* pass to the cleft between the *infundibular* and *right segments*, to be attached to both. The *posterior papillary muscle* (4'') is more irregular, and is often represented by two or three smaller ones: the *chordæ tendineæ* proceeding therefrom are attached in like manner to the *right and septal segments*; while others forming a *third set* spring directly from the surface of the septum, sometimes from small eminences upon it (4'), and pass upwards to be attached to the adjacent borders of the left and posterior segments. In the angles between each pair of the principal segments of the auriculo-ventricular valves there may be found, but not constantly, as many small intermediate lobes. On the other hand, the *division between the infundibular and right flaps* is often indistinct.

During the contraction of the ventricle, the segments of the valve are applied to the opening leading from the auricle, and prevent the blood from rushing back into that cavity. Being retained by the *chordæ tendineæ*, the expanded flaps of the valve resist the pressure of the blood, which would otherwise force them back

through the auricular orifice ; the papillary muscles, shortening as the cavity of the ventricle itself shortens, prevent the valve from yielding too much towards the auricle.

According to Kürschner,<sup>1</sup> there are three kinds of cords to each segment ; *a*, the first set, generally two to four in number and proceeding from two different sets of papillæ, or from one of these and the wall of the ventricle, run to the attached margin of the segment, and are there connected also with the tendinous ring round the auriculo-ventricular opening ; *b*, the second set, more numerous, and smaller than the first, proceed also from two adjacent papillary muscular groups, and are attached at intervals to the back or ventricular surface of each segment along two or more lines extending from the points of attachment of the tendons of the first order at the base of the valve to near its free extremity ; *c*, the third set, which are still more numerous and much finer, branch off from the preceding ones, and are attached to the back and edges of the thinner marginal portions of the valves. A few muscular fibres prolonged from the neighbouring walls of the auricles sometimes penetrate into the segments of the auriculo-ventricular valves ; blood-vessels accompany these, but in all other parts the valves are non-vascular.

Stretching obliquely across the cavity of the right ventricle there is usually a more isolated fleshy trabecula known as the *moderator band*, which extends from the base of the anterior papillary muscle upwards and inwards to the septum. It varies much in size, and is occasionally fibrous ; or it may be divided into two or more parts. This band is more largely developed in the heart of the ox and some other mammals.

The valve at the orifice of the pulmonary artery consists of three flaps, a right and left, and a posterior, named from their shape *semilunar* or *sigmoid* (fig. 309 ; fig. 314, I) : they are constructed similarly to those on the left side at the root of the aorta ; and as the characters of the last named are better marked, the more complete description will be reserved until these are treated of.

The **left auricle** occupies the left and posterior part of the base of the heart. The *atrium* presents from behind, where it is best seen, an oblong appearance, with its longer diameter directed transversely. In front it is in contact with the aorta and pulmonary artery ; behind, it receives two pulmonary veins on each side, those from the left lung entering very close together ; on the right, it is in contact with the other auricle. The *auricular appendage* (fig. 306, 6) is the only part of the left auricle seen from the front : it extends forwards from the left side of the atrium, and curves towards the right side, resting on the pulmonary artery. It is more curved as well as longer and narrower than that of the right auricle, and its margins are more deeply indented.

The interior of the appendix has muscoli pectinati somewhat similar to those on the right side of the heart, but the walls of the atrium are altogether smooth and even, and are also thicker than those of the right auricle. Posteriorly the openings of the pulmonary veins are seen, usually two on each side, and without valves (fig. 312, 1). The two veins of one or both sides sometimes unite into one before entering the auricle ; while in other cases there is found an additional opening, more frequently on the right side. In the lower and fore part of the auricle is situated the left *auriculo-ventricular orifice*. It is of an oval form, and is rather smaller than the corresponding opening between the right auricle and ventricle. On the septum between the auricles is seen a vestige of the foramen ovale in the form of a lunated depression (1'), comparable to the mark made by a finger-nail on a soft surface, and placed on a higher level than the fossa ovalis of the right auricle. The depression is limited below by a slight crescentic ridge, having the concavity turned upwards ; this is the border of the now adherent membranous valve, which during foetal life is applied to the left side of the then open foramen

<sup>1</sup> Wagner's Handwörterbuch, art. "Herzthätigkeit."

ovale. The line of adhesion may vary so as to leave more or less of a pocket-like recess.

The **left ventricle** occupies the left border of the heart, but only about a third

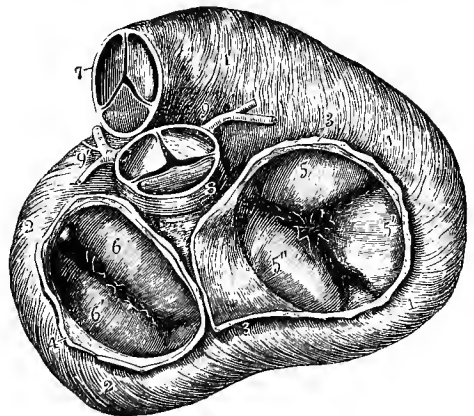
Fig. 312.—THE LEFT AURICLE AND VENTRICLE OPENED AND A PART OF THE WALL REMOVED SO AS TO SHOW THEIR INTERIOR. (Allen Thomson.)  $\frac{1}{2}$

The commencement of the pulmonary artery has been cut away, so as to show the aorta; the opening into the left ventricle has been carried a short distance into the aorta between two of the semilunar flaps; and part of the auricle with its appendix has been removed. 1, right pulmonary veins cut short; 1', placed within the cavity of the auricle on the left side of the septum, on the part formed by the valve of the foramen ovale, of which the crescentic border is seen; 2', a narrow portion of the wall of the auricle and ventricle preserved around the auriculo-ventricular orifice; 3, 3', cut surface of the wall of the ventricle, seen to become very much thinner towards 3'', at the apex; 4, a small part of the wall of the left ventricle which has been preserved with the left papillary muscle attached to it; 5, 5, right papillary muscles; 5', the left side of the septum ventriculorum; 6, the anterior or aortic segment, and 6', the posterior or parietal segment of the mitral valve; 7, placed in the interior of the aorta near its commencement and above its valve; 7', the exterior of the great aortic sinus; 8, the upper part of the conus arteriosus with the root of the pulmonary artery and its valve; 8', the separated portion of the pulmonary trunk remaining attached to the aorta by 9, the cord of the ductus arteriosus; 10, the arteries arising from the aortic arch.

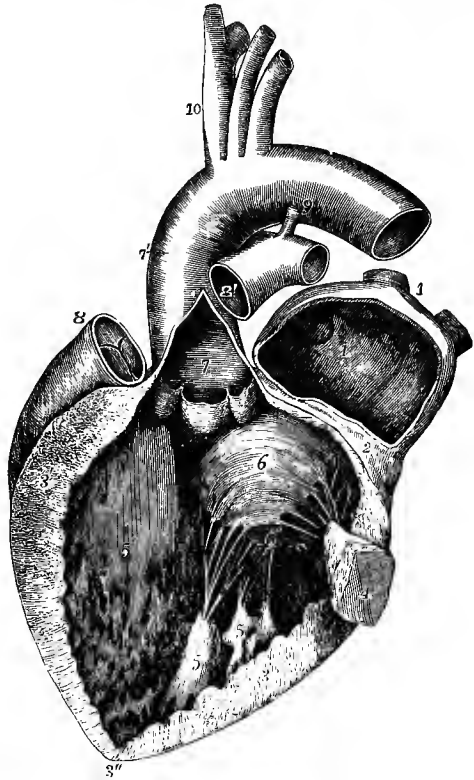

Fig. 313.—VIEW OF THE BASE OF THE VENTRICULAR PART OF THE HEART, SHOWING THE RELATIVE POSITION OF THE ARTERIAL AND AURICULO-VENTRICULAR ORIFICES. (Allen Thomson.)  $\frac{2}{3}$

The muscular fibres of the ventricles are exposed by the removal of the pericardium, fat, blood-vessels, &c.; the pulmonary artery and aorta and the auricles have been removed; the valves are in the closed condition. 1, 1, right ventricle; 1', conus arteriosus; 2, 2, left ventricle; 3, 3, the divided wall of the right auricle; 4, that of the left; 5, the infundibular; 5', the right, and 5'' the septal segment of the tricuspid valve; 6, the anterior or aortic, and 6', the posterior or parietal segment of the mitral valve (in the angles between these segments are seen smaller lobes); 7, the pulmonary artery; 8, placed upon the root of the aorta; 9, the right, 9', the left coronary artery.



of its extent appears on the anterior surface, the rest being seen behind. It is longer and narrower than the right ventricle, and the cross section of its cavity is oval, not crescentic, the septum on this side being concave (fig. 311). Its wall,

which, excepting near the apex, is nearly three times as thick as that of the right ventricle, is thickest at the part where the ventricle is widest, about one-fourth of its length from the base (fig. 312, 3); from this point it becomes thinner towards the auricular opening, and still thinner towards the apex (3"), which is, therefore, the weakest part. The lining membrane, which is continuous with that of the left auricle and the aorta, is usually less transparent than that of the right ventricle, especially in later life. In the interior of the cavity are noticed columnæ carneæ, musculi papillares with chordæ tendineæ, and two orifices guarded by valves. The ~~columnæ carneæ~~ are smaller than those of the right ventricle, but are more numerous and more closely reticulated. Their intersections are very numerous near the apex of the cavity, and also along its posterior wall, but the upper part of the anterior wall and septum is comparatively smooth. The musculi papillares (4, 5) are collected into two groups, which are larger than those of the right ventricle. The two orifices of this ventricle are situated very close together, with one of the segments (fig. 313, 6) of the auriculo-ventricular valve between: the auricular opening is placed at the lower and posterior part of the base of the ventricle; the aortic opening, in close proximity, in front and higher.

The bicuspid or mitral valve (fig. 312, 6, 6'), at the left auricular opening, resembles in structure the tricuspid valve of the right ventricle, but it is much

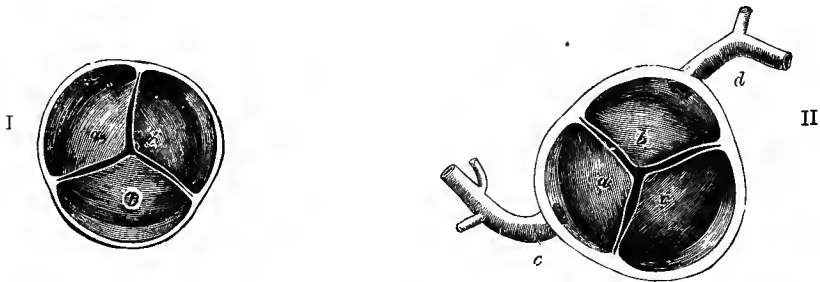


Fig. 314.—THE SEMILUNAR VALVES OF THE AORTA AND PULMONARY ARTERY, SEEN FROM THEIR DISTAL SIDE. (Allen Thomson.)

I, transverse section of the pulmonary artery immediately above the attachment of the semilunar valves: *a*, the left, and *c*, the right anterior segments; *b*, the posterior segment: opposite each the sinus of Valsalva is seen, and the attachment of the valve-segment to the inner wall of the artery.

II, a similar section of the aorta: *a*, the left posterior segment, and *b*, the anterior segment, with the corresponding sinuses of Valsalva, from which the coronary arteries are seen to take their origin; *c*, the right posterior segment; *d*, the right, and *c*, the left coronary arteries.

thicker and stronger in all its parts, and consists of only two pointed segments, continuous at their attached bases. The larger of the two segments is suspended obliquely to the right and in front of the other, between the auricular and aortic openings; the smaller to the left and behind, and close to the wall of the ventricle. There is usually a smaller lobe at each angle of junction of the two principal segments, more apparent than those between the segments of the tricuspid valve.

As on the right side, the two sets of chordæ tendineæ from the papillary muscles proceed each to an angle between the two segments, and are attached in like manner to their margins and ventricular surfaces (fig. 312, and fig. 315, B, *c*), so that the musculi papillares, when they contract, tend to bring the edges of the flaps together. The chordæ tendineæ are stronger and less numerous than in the right ventricle. Small bands, partly muscular partly tendinous, may often be found crossing the cavity of the ventricle in various directions. They are vestiges of the spongy structure of the cavity which is found during a part of embryonic life.

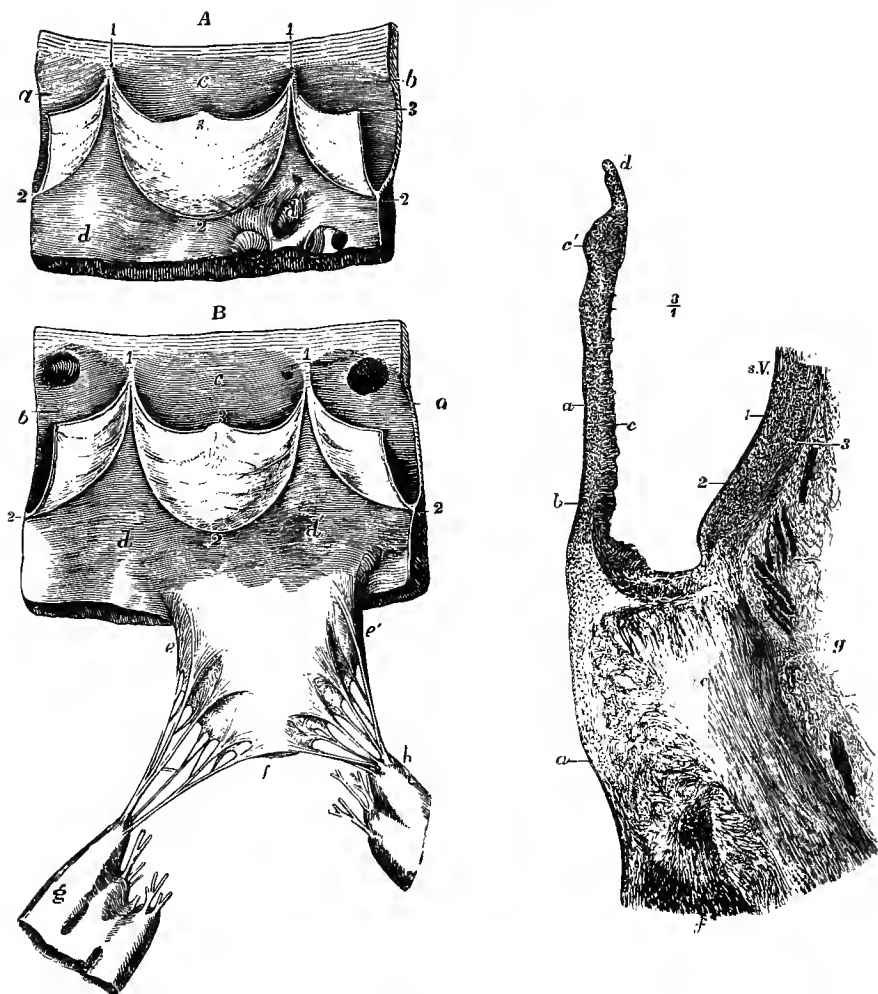


Fig. 315.—VIEWS OF PARTS OF THE SEMILUNAR AND MITRAL VALVES, AS SEEN FROM WITHIN THE VENTRICLE. (Allen Thomson.)

A, portion of the pulmonary artery and wall of the right ventricle with one entire segment and two half segments of the valve : *a, b, c*, sinuses of Valsalva opposite the segments ; *d, d'*, inner surface of the ventricle ; 1, 2, curved attached border of the segments ; 3, corpus Arantii, at the middle of the free border.

B, portion of the aorta and wall of the left ventricle with one entire segment and two half segments of the aortic valve, and the right or anterior segment of the mitral valve : *a, b, c*, sinuses of Valsalva opposite the segments ; in *a, and b*, the apertures of the coronary arteries are seen ; *d, d'*, the inner surface of the wall of the ventricle ; 1, 2, and 3, as before ; *e, e'*, the base of the anterior segment of the mitral valve ; *f*, its apex ; between *e, and c'*, and *f*, the attachment of the branched chordæ tendineæ to the margin and outer surface of the valve-segment ; *g, right, h*, left papillary muscle : the cut chordæ tendineæ are those which belong to the posterior segment and the small or intermediate segments.

Fig. 316.—SECTION THROUGH ONE OF THE FLAPS OF THE AORTIC VALVE AND PART OF THE CORRESPONDING SINUS OF VALSALVA, WITH THE ADJOINING PART OF THE VENTRICULAR WALL. (V. Horsley.) §

*a*, endocardium, prolonged over the valve ; *b*, subendocardial tissue ; *c*, fibrous tissue of the valve, thickened at *c'* near the free edge ; *d*, section of the lunula ; *e*, section of the fibrous ring ; *f*, muscular fibres of the ventricle attached to it ; *g*, loose areolar tissue at the base of the ventricle ; *s. V.*, sinus Valsalvæ ; 1, 2, 3, inner, middle, and outer coats of the aorta.

The arterial or *aortic orifice*, circular in form, and smaller than the auricular, is separated from it only by the attachment of the anterior segment of the mitral valve. As in the pulmonary artery, its valve consists of three semilunar or *sigmoid* (fig. 314, II), each of which is attached by its convex border to the side of the artery at the place where it joins the ventricle, while its other border, nearly straight, is free, and projects into the interior of the vessel.

The segments of these valves are composed of fibrous tissue covered by a prolongation of the endocardium on the one side, and of the inner coat of the artery on the other side. Their thickness varies at different parts. A tendinous band strengthens the free edge of the valve, and at the middle of that margin

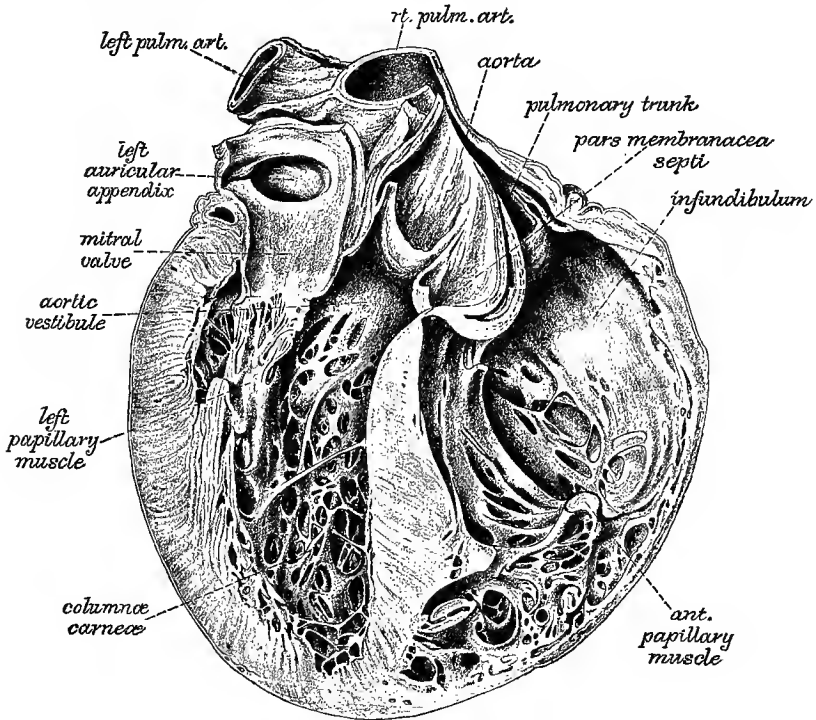


Fig. 317.—THE INTERIOR OF THE VENTRICLES OF THE HEART, FROM BEHIND, SHOWING THE MODE OF ORIGIN OF THE AORTA, THE MEMBRANOUS PART OF THE INTERVENTRICULAR SEPTUM, &c. (His.)  $\frac{2}{3}$

there is a slight thickening, the *nodulus* or *corpus Arantii* (fig. 315, 3). Other tendinous fibres, arising from the attached border, run in the valve towards the nodule, occupying its whole extent, except two narrow lunated portions, one on each side, adjoining the free margin of the valve. These parts, which are named *lunulae*, are therefore thinner than the rest. There is also a strengthening fibrous band along the attached border of each valve. The wall both of the aorta and pulmonary artery is bulged out opposite each semilunar flap: these bulgings are known as the *sinuses of Valsalva*. In the aorta these are situated one anteriorly and two posteriorly (right and left). From the anterior arises the right coronary artery, and from the left posterior the left coronary artery, these vessels being for the supply of blood to the substance of the heart.

The capacity of the sinuses of Valsalva is greater, and the tendinous tissue in

the valves is more strongly marked at the mouth of the aorta than at the beginning of the pulmonary artery.

Irregularities in the arrangement of the arterial valves are occasionally met with. The commonest is the presence of an additional (fourth) flap in the pulmonary valve. Either the aortic or the pulmonary valve may consist of only two segments; and the pulmonary valve has been seen formed by a single flap. An additional flap to the aortic valve is of rare occurrence.

The part of the left ventricle adjoining the root of the aorta forms a small compartment, the *aortic vestibule* of Sibson, the walls of which are fibrous, or at one part even fibro-cartilaginous, so that it remains uncollapsed, and allows space for the bulging flaps of the aortic valve to descend during diastole.

The interventricular septum is seen in fig. 311 to be of about the same thickness as the wall of the left ventricle; but it differs from the latter in being thickest below, and becoming gradually thinner above (fig. 310 and 317). At its upper and fore part there is a small region where muscular fibres are absent, and the septum consists only of a little fibrous tissue between the two endocardial layers. This is known as the *pars membranacea septi* or *undefended space*, and is the part derived from the lower end of the foetal aortic septum: it is placed at the inner and fore part of the aortic vestibule, below the adjacent ends of the anterior and right posterior segments of the aortic valve; and on the right side it is covered by the fore part of the septal flap of the tricuspid valve (below 8 in fig. 313). It is at this spot that an abnormal communication between the two ventricles is most likely to occur (persistence of the foetal interventricular foramen owing to defective development of the aortic septum). Posteriorly the *pars membranacea* is continued into a narrow portion of the septum which is situated below the attachment of the anterior flap of the mitral valve, but above that of the septal flap of the tricuspid valve (fig. 310; fig. 313, to the left of 5"), so that it separates the cavities of the right auricle and left ventricle, and which is strengthened by a process of the fibro-cartilage of the heart (p. 368).

#### POSITION OF THE PARTS OF THE HEART WITH RELATION TO THE WALL OF THE THORAX.

Fully two-thirds of the bulk of the heart lie to the left of the median plane (fig. 318). The *right auricle* (3') lies behind the sternal ends of the third, fourth, fifth and sixth costal cartilages, and the intervening portions of the intercostal spaces, and is also partly covered by the right edge of the sternum. The point of its auricular appendage is behind, or even slightly to the left of, the middle line on a level with the third costal cartilages (3). The *left auricle* extends vertically from the level of the lower border of the second left cartilage to the upper border of the fourth (sternal end), and in breadth corresponds to the body of the seventh dorsal vertebra and the heads of the adjoining ribs on the left side. The apex of its appendage (4) is behind the third costal cartilage, about an inch and a quarter to the left of the sternum. The *right ventricle* extends from above down from the third to the seventh cartilages on the left side. Its middle and lower region is as a rule the only part of the heart uncovered by lung; but sometimes, especially during expiration, a small portion of the left ventricle at the apex is also exposed. The *auriculo-ventricular sulcus* corresponds with a line drawn obliquely upwards from the sternal end of the sixth costal cartilage on the right side, to the third cartilage on the left. The *rounded margin* formed by the left ventricle extends on the left side from a spot on the third cartilage one inch and a half from the sternum to the apex of the heart in the fifth space. The *sharp margin* formed by the right ventricle passes from the sternal end of the sixth cartilage on the right nearly transversely behind the seventh

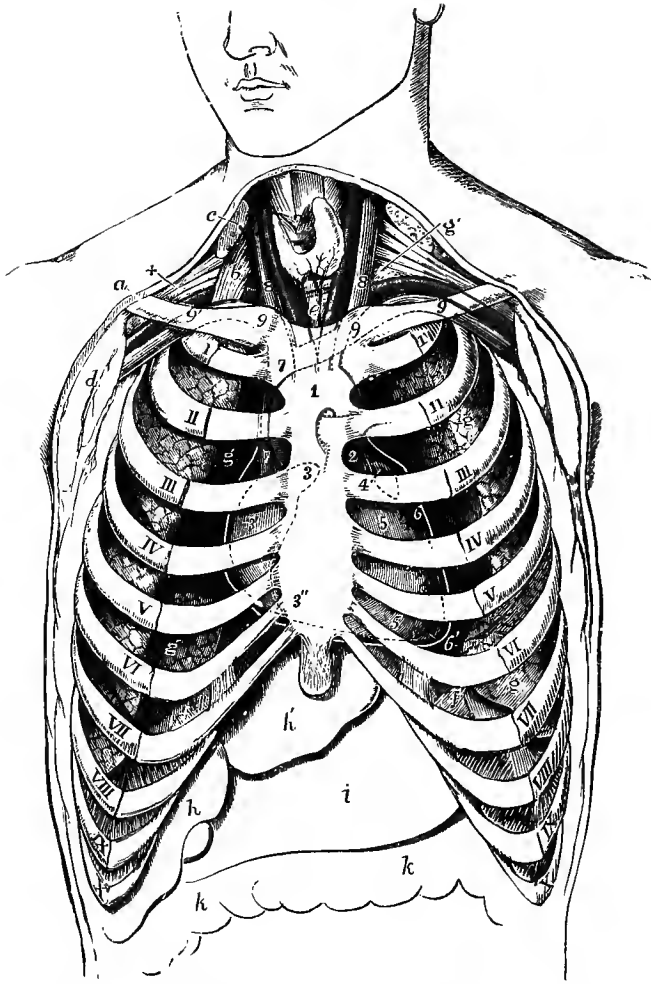


Fig. 318.—SEMIDIAGRAMMATIC REPRESENTATION OF THE CHEST, TO SHOW THE POSITION OF THE HEART AND GREAT VESSELS, AS SEEN BEHIND THE STERNUM AND COSTAL CARTILAGES. (A. Thomson, modified from Luschka.)  $\frac{1}{2}$

The lungs have shrunk from the front of the chest. The heart is slightly higher than during life, and the aorta more to the right. *a*, right clavicle; *b*, scalenus anticus muscle; *c*, sterno-mastoid muscle divided; *d*, pectoral muscles divided; +, nerves of brachial plexus above the subclavian artery; *e*, trachea below the isthmus of the thyroid body; *f*, *f*, upper surface of diaphragm; *g*, *g*, lungs; *g'*, on the left side, apex of the lung appearing in the neck; *h*, right, *h'*, left lobe of the liver; *i*, stomach; *k*, *k*, transverse colon; I, to X, first to tenth ribs near their cartilages; 1, placed on the lower part of the manubrium of the sternum, and over the arch of the aorta (indicated by outlines); 2', placed in the second left intercostal space, on the trunk of the pulmonary artery; 3, appendix of the right auricle; 3', on the atrium, behind the third space; 3'', its lower part at the junction of the sixth costal cartilage with the sternum; 4, left auricular appendix; 5, 5, right ventricle; 6, left ventricle; 6', apex of the heart: the white line outside the heart is intended to indicate the external pericardium, as if the anterior half were removed by a transverse incision; 7, 7, vena cava superior; 8, 8, internal jugular veins; 9, 9, subclavian veins, joining the jugular; 9-7, 9-7, innominate veins; the position of the first part of the innominate, left carotid and left subclavian arteries is indicated behind and below the left innominate vein; 9', 9', outer parts of the subclavian vessels. It is to be observed that in this figure the attachment of the sixth costal cartilage to the sternum is represented a little too high.



right cartilage, the base of the ensiform process, and the seventh and sixth left cartilages, to meet the other margin at the apex.

The *apex of the heart* (fig. 318, 6') is situated about  $3\frac{1}{2}$  inches to the left of the middle line, in the fifth intercostal space, just internal to the end of the fifth rib.

The *auriculo-ventricular openings* lie slightly to the left of the line of the auriculo-ventricular sulcus. The *right orifice* lies behind the sternum, on a level with the fourth intercostal space and fifth cartilage. The *left* is behind the inner end of the fourth left costal cartilage and adjacent part of the sternum. The *orifice of the pulmonary artery* is placed immediately to the left of the sternum, at the upper edge of the third cartilage, and the pulmonary trunk extends up to the second left cartilage. The *aortic orifice* is mainly behind the left half of the sternum, on a level with the lower border of the third costal cartilage: it is a little below and to the right of the pulmonary opening, by which it is covered to the extent of one-fourth of its diameter; and it lies exactly behind the upper part of the infundibulum of the right ventricle. The ascending aorta passes upwards behind the sternum to the inner end of the second right costal cartilage.

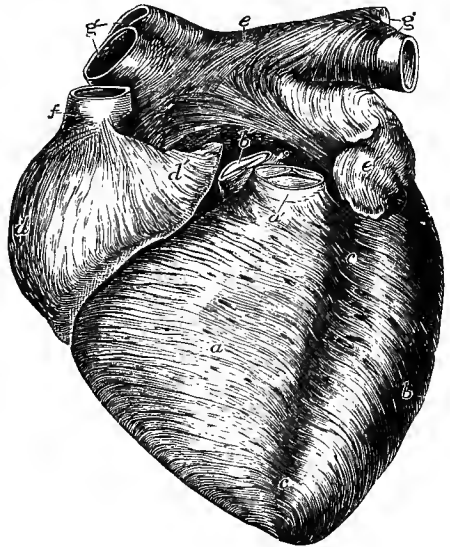
The position of the heart is subject to some degree of individual variation, and the extent of the several divisions will necessarily be dependent upon the stage of their action: the condition represented in fig. 318 is that met with after death, when all the cavities are in a state of relaxation. It is also influenced to a slight extent by the respiratory movements and the posture of the body (p. 355). In children the heart is relatively broader and projects more to the left side of the chest than in the adult, so that the apex-beat is often perceived in, or even external to, the nipple-line. In old persons the heart frequently occupies a much lower position than that given above.

#### INTIMATE STRUCTURE OF THE HEART.

The heart is closely invested by a serous membrane, the cardiac pericardium (*epicardium*), and its cavities are lined by a smooth membrane, termed the *endocardium*. The main substance of the organ is composed of muscular tissue (*myo-*

Fig. 319.—ANTERIOR VIEW OF HEART OF A YOUNG SUBJECT DISSECTED AFTER LONG BOILING, TO SHOW THE SUPERFICIAL MUSCULAR FIBRES. (Allen Thomson.)  $\frac{3}{4}$

This figure is planned after one of Luschka's, but its details were chiefly taken from an original preparation. The aorta, *b'*, and pulmonary artery, *a'*, have been cut short close to the semilunar valves, so as to show the anterior fibres of the auricles. *a*, superficial layer of the fibres of the right ventricle; *b*, that of the left; *c*, *c*, anterior interventricular groove; *d*, right auricle; *d'*, its appendix, both showing chiefly perpendicular fibres; *e*, upper part of the left auricle; between *c*, and *b'*, the transverse fibres which behind the aorta pass across both auricles; *e'*, appendix of left auricle; *f*, superior vena cava, around which, near the auricle, circular fibres are seen; *g*, *g'*, right and left pulmonary veins with circular bands of fibres surrounding them.



*cardium*), with interstitial areolar tissue and numerous blood-vessels, lymphatics, and, in some parts, nerves and ganglia. There is also a considerable amount of fat chiefly collected at the base of the heart and beneath the pericardium, while in connection with the large orifices at the base of the ventricles a mass of fibrous tissue and fibro-cartilage occurs, which in some animals, as the ox, is bony, and is

known as the *os cordis*. This central fibro-cartilage is placed in the angle between the aortic and the two auriculo-ventricular openings (see fig. 313), and from it processes pass in various directions. One of these, extending downwards to meet the fleshy septum of the ventricles, separates the left ventricle from the right auricle, forming the right boundary of the aortic vestibule (p. 365). These processes form the bases of what have been described by authors as the *fibrous* or *tendinous rings* of the auriculo-ventricular and arterial openings. The fibrous tissue of the rings is continuous with that which is found in the segments of the valves, strengthened on the sides next the septum by the processes from the fibro-cartilage. The rings of the arterial orifices give attachment below to some of the muscular fasciculi of the ventricle, whilst above they project between the flaps of the valves, with the curved border of which they are continuous, as well as with the middle coat of the artery. The fibres of the middle coat of the artery, here comparatively thin, are not arranged annularly, as in other parts of the vessel, but converge to the intervals between the sinuses of Valsalva, to be attached to the projections of the fibrous rings.

The tendinous rings of the aortic and left auricular orifices are confluent, so that when the fibrous tissue is destroyed by boiling the two apertures run into one.

#### MYOCARDIUM.

**Arrangement of the muscular fasciculi.**—The arrangement of the fasciculi (or “fibres,” as they are ordinarily termed) in the auricles and ventricles must be considered separately, for the muscular bundles of the two are not continuous, being

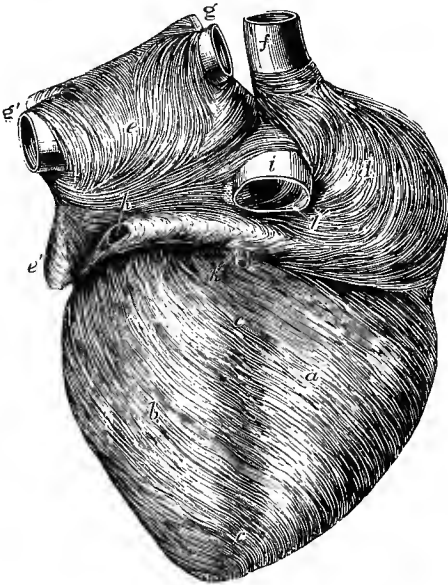


Fig. 320.—POSTERIOR VIEW OF THE SAME PREPARATION AS IS REPRESENTED IN THE PRECEDING FIGURE. (Allen Thomson.)  $\frac{2}{3}$

*a*, right ventricle; *b*, left ventricle; *c*, posterior interventricular groove; *d*, right auricle; *e*, the left; *f*, superior vena cava; *g*, *g'*, pulmonary veins cut short; *h*, sinus of the great coronary vein covered by muscular fibres; *h'*, middle cardiac vein joining the coronary sinus; *i*, inferior vena cava; *v*, Eustachian valve.

only connected by the fibrous tissue around the auriculo-ventricular orifices: in conformity with this it is seen that, after boiling the heart, the auricles may be easily separated from the ventricles.

**Fibres of the auricles.**—These consist of a superficial set, common to both cavities, and of deeper fibres proper to each. The *superficial fibres* run transversely over both venous

sinuses, and are most numerous on the anterior surface; some pass in at the interauricular septum (fig. 319). Of the deeper fibres, which are proper to each auricle, some pass over the auricle, and seem to be attached by both extremities to the corresponding auriculo-ventricular rings (*looped fibres*). Others, which are termed *annular fibres*, encircle the auricular appendages (fig. 319 *d'*, 320 *e'*), some longitudinal fibres running within them. Annular fibres also surround the terminations of the venæ cavæ (*f*, *i*) on the right, and of the coronary vein and the pulmonary

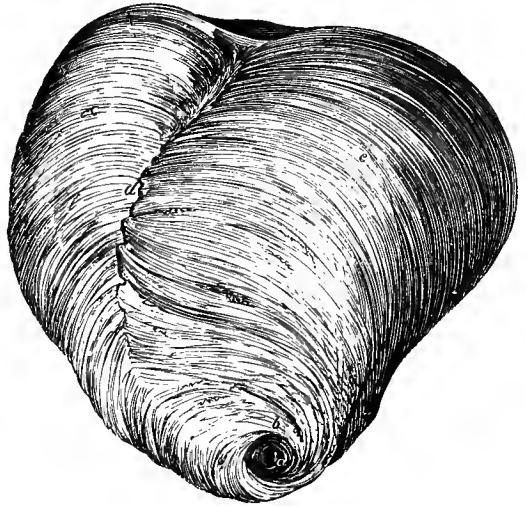
veins on the left side of the heart (*g, h*),—the muscular fibres extending for some distance from the auricle upon the veins,<sup>1</sup> especially upon the superior vena cava and the pulmonary veins. The fossa ovalis in the septum is also encircled by annular fibres.

**Fibres of the ventricles.**—The muscular fasciculi of the ventricles have a very intricate disposition, which has received great attention from anatomists. Many of the statements, however, are conflicting, and it must be confessed that the subject still requires farther investigation.<sup>1</sup>

The fibres on the outer surface of the ventricles (figs. 319, 320, *a, b*) extend from the base, where they are attached to the tendinous structures around the orifices, towards the apex of the heart, where they pass with an abrupt twist into the interior of the left ventricle. Their general direction is not vertical but oblique, especially in front (fig. 319), just as if while the base of the organ remained fixed the apex had been twisted half round in the direction of the motion of the hands

Fig. 321.—SURFACE FIBRES OF THE VENTRICLES OF THE HUMAN HEART FROM THE FRONT AND BELOW. (Reid.)

*b*, bundle of fibres emerging from the interior of the left ventricle at the vortex *a*, and crossing the lower part of the septum uninterruptedly. At *d*, the surface fibres are somewhat interrupted.



of a watch. They form a distinct thin superficial stratum, best marked at the back of the right ventricle, for here the direction of the fibres is quite different from those immediately beneath. At the back they pass over the septum without turning in: at the front they are somewhat interrupted by fibres which come out from the septum; except towards the base and apex, where they cross uninterruptedly from one ventricle to the other (fig. 321).

If the superficial fibres are traced into the interior of the left ventricle at the apex, it is found that they pass for the most part into continuity with the papillary muscles, and the adjacent parts of the inner layer of muscular fibres of that cavity. Most of those which are seen crossing over the front and left side of the heart can be traced towards the posterior papillary muscle, whilst those which pass over the back and right side of the heart, are chiefly continuous with the anterior papillary muscle. Many of the superficial fibres, however, after gaining the interior of the left ventricle, do not pass into the papillary muscles, but spread out as an inner vertical layer of muscular fasciculi, which pass upwards to be attached to the fibrous rings at the base of the ventricle.

The peculiar spiral concentration of the fibres of the heart at the apex is known as the *vortex* or *whorl*, and is produced, as already described, by the twisting or interlocking of the external fibres as they pass to be continuous with those in the interior.

<sup>1</sup> For convenience of description in the following account of the course of the fibres, the heart is supposed placed apex downwards, and with the anterior and posterior surfaces about equally occupied by the two ventricles (as represented in figs. 319, 320).

It has been thought that a similar continuity was the rule at the base of the heart also, and that few if any of the bundles are attached to the tendinous rings. But although some bundles may turn round at the auriculo-ventricular openings, this is by no means general, and most of the muscular fasciculi are attached to the fibrous and fibro-cartilaginous structures at the base, either directly or through the medium of the chordæ tendineæ and segments of the valves.

The greater part of the thickness of the wall of the left ventricle is formed of fibres which are attached above, like those just described, to the fibrous rings at the base. From there they pass obliquely downwards in the posterior and left wall, and more directly downwards in the anterior wall towards the apex. But before reaching this they are inclined, especially the anterior fibres, somewhat abruptly towards the front of the septum, which they enter near its lower end. They may now be divided into three sets. (1) Many pass at once obliquely upwards in the septum to be attached to the central fibro-cartilage, so that these may be regarded as forming simple V-shaped muscular loops around the cavity of the left ventricle. (2) Others cross in the septum in their passage upwards and pass to the posterior wall of the right ventricle, being partly continuous with its posterior papillary muscle. (3) Others again pass nearly horizontally into the posterior wall of the left ventricle, and take an annular course in it. But many of these annular fibres of the left ventricle (which are found about the middle of its thickness) are continuous with the deeper fibres of the right ventricle.

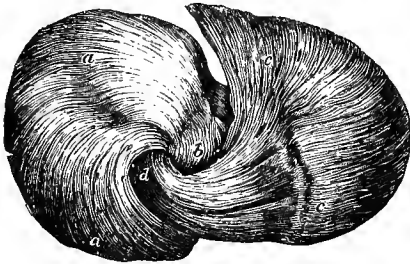


Fig. 322.—VIEW OF THE FIBRES OF THE SHEEP'S HEART, DISSECTED AT THE APEX TO SHOW THE "VORTEX." (Pettigrew.)

*a, a*, fibres entering the apex posteriorly at *b*  
*c, c*, fibres entering the apex anteriorly at *d*.

The right ventricle so far as regards the arrangement of its muscular fasciculi may be looked upon as an appendage of the left. Its superficial fibres are directly continuous, as we have seen, with the papillary muscles of the left ventricle. Its deeper fibres also mostly pass into continuity with those of the left ventricle. Attached above to the fibrous structure encircling the right auriculo-ventricular and the pulmonary apertures, either directly or (in the case of the papillary muscles) indirectly through the chordæ tendineæ they pass towards the septum. The posterior fibres enter this behind and pass forwards in it to the front of the left ventricle (as above described under 2); the anterior enter the septum in front and pass backwards in it, intercrossing with those just mentioned, to the posterior part of the left ventricle; while the middle set of fibres, derived chiefly from the external wall of the right ventricle, enter the lower part of the septum and are directed upwards in it to be attached to the central fibro-cartilage. Finally a considerable number of fasciculi pass straight across the septum without turning into it and appear to encircle both ventricles. There are besides certain sets of fibres which appear not readily assignable to any of those above described: some, for instance, which encircle the pulmonary orifice, and others which, as Sibson has shown, radiate upwards from the base of the anterior papillary muscle of the right ventricle, to be attached to the tendinous structures at the base of the heart, especially to the pulmonary ring, opposite the two anterior sinuses of Valsalva.

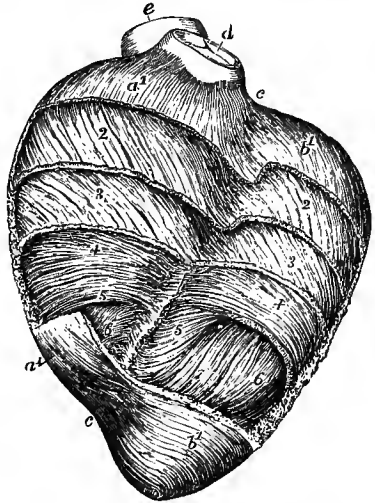
In the middle of the thickness of the ventricular wall the fibres are, as before said, annular and transverse (fig. 323, 4, 4'); but, as Ludwig showed, they pass by

the most gradual transition into the diagonal ones nearer the surfaces, so that any separation into layers which may be effected (with the exception of the superficial stratum over the right ventricle) must be looked upon as in a great degree artificial.

**Microscopical structure of the myocardium.**—The muscular fibres of the heart are cross-striated, but differ from the fibres of the voluntary muscles in being

Fig. 323.—VIEW OF A PARTIAL DISSECTION OF THE FIBRES OF THE ANTERIOR WALL OF THE VENTRICLES IN A SHEEP'S HEART, DESIGNED TO SHOW THE DIFFERENT DEGREES OF OBLIQUITY OF THE FIBRES. (Allen Thomson.)

At the base and apex the superficial fibres are displayed: in the intervening space, more and more of the fibres have been removed from above downwards, reaching to a greater depth on the left than on the right side. *a'*, *a'*, the superficial fibres of the right ventricle; *b'*, *b'*, the same of the left ventricle; at 2 these fibres have been removed so as to expose those underneath, which are seen to have the same direction as the superficial ones over the left ventricle, but different over the right; at 3 some of these have been removed, but the direction is only slightly different; 4, transverse or annular fibres occupying the middle of the thickness of the ventricular walls; 6, 7, internal fibres passing downwards towards the apex to emerge at the whorl; between *c*, *c*, the anterior coronary or interventricular groove, over which the superficial fibres are seen crossing; in the remaining part of the groove, some of the deeper fibres turn backwards into the septum; *d*, the pulmonary artery; *e*, the aorta.



constantly branched and united to one another so as to form a complete network or spongework with reticulating interstices. They are moreover composed in the manner described in Volume I. (p. 304) of somewhat oblong occasionally forked cells, cemented

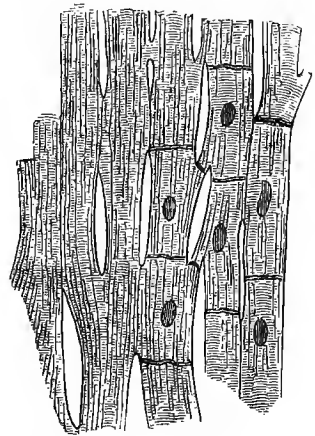
Fig. 324.—MUSCULAR FIBRES FROM THE HEART, MAGNIFIED, SHOWING THEIR CROSS STRIÆ, DIVISIONS, AND JUNCTIONS. (Schweigger-Seidel.)

The nuclei and cell-junctions are only represented on the right-hand side of the figure.

together end to end (fig. 324). The interstices between the fibres are filled by connective tissue, with numerous blood-vessels, lymphatics and nerves.

**Vessels.**—The muscular substance is supplied with blood by the coronary arteries, the origin and course of which, as well as of the cardiac veins, are elsewhere described. The smaller branches penetrate into every part of the muscular substance, the capillaries being very numerous and closely arranged. The cardiac valves are non-vascular, except where muscular tissue occurs in them, as is sometimes the case in the auriculo-ventricular valves (L. Langer).

**Lymphatics.**—The lymphatics (which are found in great number beneath both the epicardium and endocardium) are also, as was shown by Schweigger-Seidel, extensively distributed throughout the muscular substance, occurring in the form of freely communicating fissure-like spaces between the muscular bundles, and lined by endothelial cells, the mode of origin being thus to a certain extent lacunar. According to Skwartzoff, whose observations were made upon the heart of the rabbit, dog, and calf, the lymphatics of the ventricles are independent of those of the



auricles and are chiefly collected into a trunk which lies in the anterior longitudinal groove, turns to the left around the aorta, and passing between this vessel and the trachea enters the lymphatic gland or glands which are there situated. From these glands the lymph passes into the right innominate vein. Other of the cardiac lymphatics pass round at the reflection of the pericardium and over the parietal layer to reach the thoracic duct.

**Nerves.**—The nerves given off by the cardiac plexuses appear rather small in comparison with the bulk of the heart; they are derived partly from the cerebro-spinal and partly from the sympathetic system (more especially from the pneumogastric nerve, and from the cervical and superior thoracic ganglia of the sympathetic nerve).

From the cardiac plexuses at the base of the heart, nerves pass to the auricles and there join a plexus chiefly of non-medullated fibres, which is beset with numerous small groups of ganglion-cells. This gangliated plexus lies for the most part immediately beneath the pericardial covering of the auricles, but its branches penetrate into the muscular substance.

In the dog's heart Dogiel found three principal groups of ganglia, viz., one between the superior cava and the right auricular appendix, another between the same vein and the root of the aorta, and a third between the root of the aorta and the pulmonary veins. Schklarewski, in different mammals, describes them as occurring chiefly in the interauricular septum and in the auriculo-ventricular groove. The same is affirmed by Skwartzoff, who, however, found the ganglia on the auricular plexus to be most numerous over the left auricle; and Vignal states, with regard to the human heart, that it is especially near the orifices of the pulmonary veins that they occur in largest number.

Nerves are also given off from the cardiac plexuses, which, passing downwards along the commencement of the aorta and pulmonary artery, reach the coronary arteries, and accompanying these in their course form secondary plexuses (right and left coronary plexuses) around those vessels. From the coronary plexuses numerous branches proceed, which pass, for the most part, over the surface of the ventricles under the pericardium, but a few small branches are directed upwards to join the auricular plexus of nerves. Small microscopic groups of ganglion-cells occur, as was shown by Remak, both upon the coronary plexuses and also here and there along their branches for a certain distance.

The nerve-fibres which pass off from the gangliated plexuses of the auricles and of the base of the ventricles are non-medullated, and are distributed to every part of the muscular tissue of the heart. No ganglia are found upon them, however, in their further course, and no ganglion-cells at all have been found in the apical two-thirds of the ventricles. The nerve-fibres form a close plexus (ground-plexus) amongst the muscular bundles, and from this terminal branches (fibrils) pass off to the muscle-cells, each one ending by a slight enlargement or varicosity of the nerve fibril which is applied to the surface of the cell (*taches motrices* of Ranvier).

#### EPICARDIUM.

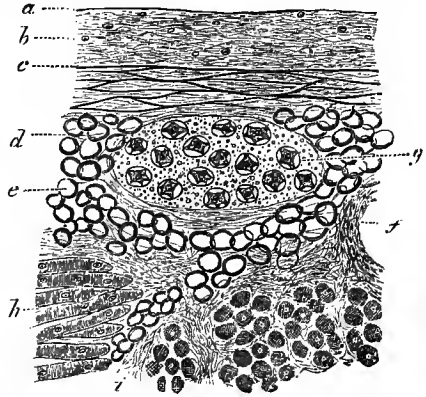
The **cardiac pericardium** or **epicardium** has the usual structure of a serous membrane. It is covered externally by a pavement epithelium (endothelium) of irregularly polygonal cells, and as in other serous membranes stomata are found here and there between these, permitting a communication between the pericardial cavity and the lymphatics of the membrane (Skwartzoff). The substance of the membrane is composed of connective tissue with much elastic tissue, chiefly collected into a well-developed network in the deeper layer (fig. 325, c).

The subserous areolar tissue is continuous with the interstitial tissue between

the fibres of the myocardium. In it run the vessels and nerves before dipping down into the muscular substance, and a system of lymphatic vessels, connected with the lymphatic spaces of the myocardium, also occurs here. The vessels and nerves are generally imbedded in a considerable amount of fat (fig. 325, *e*), which is espe-

Fig. 325.—SECTION OF A PART OF THE PERICARDIUM OF THE RIGHT AURICLE. (E. A. S.)

*a*, serous epithelium in section; *b*, connective tissue layer; *c*, elastic network; *d*, subserous areolar tissue; *e*, fat; *f*, section of a blood-vessel; *g*, a small ganglion; *h*, muscular fibres of the myocardium; *i*, intermuscular areolar tissue.



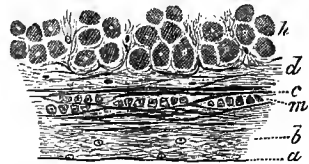
cially collected in the furrows, but may in fat subjects extend as a layer covering the greater part of the surface, and may even be found in the larger interspaces of the myocardium, and beneath the endocardium.

ENDOCARDIUM.

The **endocardium** furnishes a lining to all the cavities of the heart, following the inequalities of the inner surface of the organ, and becoming continuous at the venous and arterial orifices with the inner coat of the respective veins and arteries. A layer of endothelial cells covers and lines the inner surface (fig. 326, *a*), and

Fig. 326.—SECTION OF A PART OF THE ENDOCARDIUM OF THE RIGHT AURICLE. (E. A. S.)

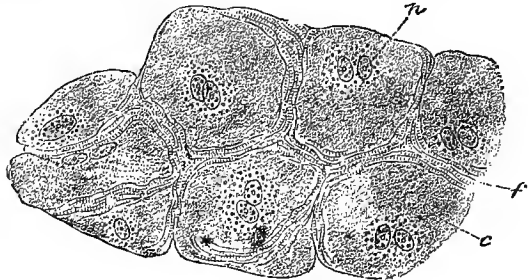
*a*, lining epithelium; *b*, connective tissue with fine elastic fibres; *c*, layer with coarser elastic fibres; *d*, subendocardial connective tissue continuous with the intermuscular tissue of the myocardium; *h*, muscular fibres of the myocardium; *m*, plain muscular tissue in the endocardium.



beneath this the endocardium consists of connective tissue with a close network of elastic fibres often passing into fenestrated membrane. Plain muscular fibres are present in some parts (*m*). The ordinary cardiac muscular fibres extend in many places close up to the endocardium, but in others are separated from it by some

Fig. 327.—FRAGMENT OF THE NETWORK OF PURKINJE FROM THE VENTRICULAR ENDOCARDIUM OF THE SHEEP. (Ranvier.) 300.

*c*, cell; *f*, striated substance; *n*, nuclei.



amount of areolar tissue. In this tissue, fat is often met with, especially in fat subjects and in fatted animals. In the ventricles of some animals, as

the horse and sheep, large beaded reticulating fibres are met with lying in the subendocardial tissue and, having been first described by Purkinje, are known by his name. When examined with the microscope these fibres of Purkinje are found to be composed of large clear cells, joined end to end, and containing in their centre one or two nuclei

(generally two) embedded in a more granular substance (fig. 327). The periphery of the cells in question is composed of transversely striated substance, and they appear to represent a condition of arrested development of cardiac muscular tissue. They have been found in one instance in the human heart (Gegenbaur), but according to Henle they do not as a rule occur after the first year in man. The endocardium is thicker in the auricles (the left especially) than in the ventricles; it is, however, very thin on the musculi pectinati of the auricles and on the columnæ carneæ of the ventricles. The endocardium does not receive any blood-vessels, and the same is true for both the auriculo-ventricular and the semilunar valves. There is a non-gangliated plexus of medullated nerve-fibres under the endocardium, to which fine nerve-fibres pass, but their mode of termination is not known (Toldt).

#### DIMENSIONS AND WEIGHT OF THE HEART.

**Size.**—It was stated by Laennec that the heart in its natural condition is about equal in size to the fist of the individual. It is about five inches long, three and a half in its greatest width, and two and a half in its extreme thickness from the sternal to the diaphragmatic surface; but linear measurements of a flaccid organ like the heart must be subject to so many accidental variations as to render them of little value.

**Weight.**—The weight of the heart in the adult is also subject to considerable variation, ranging between rather wide limits, which depend mainly on the general weight of the body and on the sex.

The mean weight of the heart is about 11 oz. (310 grammes) in the male, and 9 oz. (255 grammes) in the female. Its proportion to the body-weight is about 1 : 205.

The weight of the heart increases with the body-weight, but in a gradually diminishing ratio, so that with a higher body-weight the proportional weight of the heart is usually lower. At birth the heart weighs on an average  $13\frac{1}{2}$  drachms (24 grm.), and its proportion to the body-weight is about 1 : 130. The absolute weight increases rapidly during the first years of life, and then more slowly until the approach of puberty, when another period of somewhat more rapid growth sets in. After adult age is reached the heart continues to increase in weight slightly until about 70 years, when it begins to diminish. During the latter part of fetal life the muscular walls of the two ventricles are of equal bulk; but after birth the right grows much less rapidly than the left, so that by the end of the second year they are to one another as 1 : 2, a proportion which is thenceforward maintained. In the fœtus also the right auricle is the heavier; during the first month after birth the two become equal, but from the second year the right gains slightly again, and from puberty onwards exceeds the left by about 5.5 per cent. (Müller).

Similarly, the *volume* of the heart was found by Beneke to increase with age, at first rapidly then gradually. Thus in the new-born infant the average volume is 22 cubic centimeters: at the fifteenth year it is 150 cc. to 160 cc.; and at the twentieth year about 250 cc. After this it increases but slowly up to the fiftieth year, by which time it has arrived at 280 cc. Subsequent to this there is a slight gradual diminution. Up to the age of puberty the volume is about the same in both sexes, but after puberty it is 25 cc. to 30 cc. larger in the male. On account of the obvious difficulties of the investigation these statements can however only be regarded as approximate.

The auricles are generally stated to be rather less capacious than the ventricles. The right auricle is also said to be larger than the left. In the ordinary modes of death, the right ventricle is always found more capacious than the left, probably owing to its being distended with blood: the left ventricle, on the other hand, is found nearly empty, and thus becomes more fully contracted. There are good reasons for believing that during life scarcely any difference of capacity exists between the two cavities.

The right auriculo-ventricular opening and the orifice of the pulmonary artery are both found to be somewhat larger after death than the corresponding openings on the left side of the heart. Their average dimensions may be stated as follows<sup>1</sup>:—

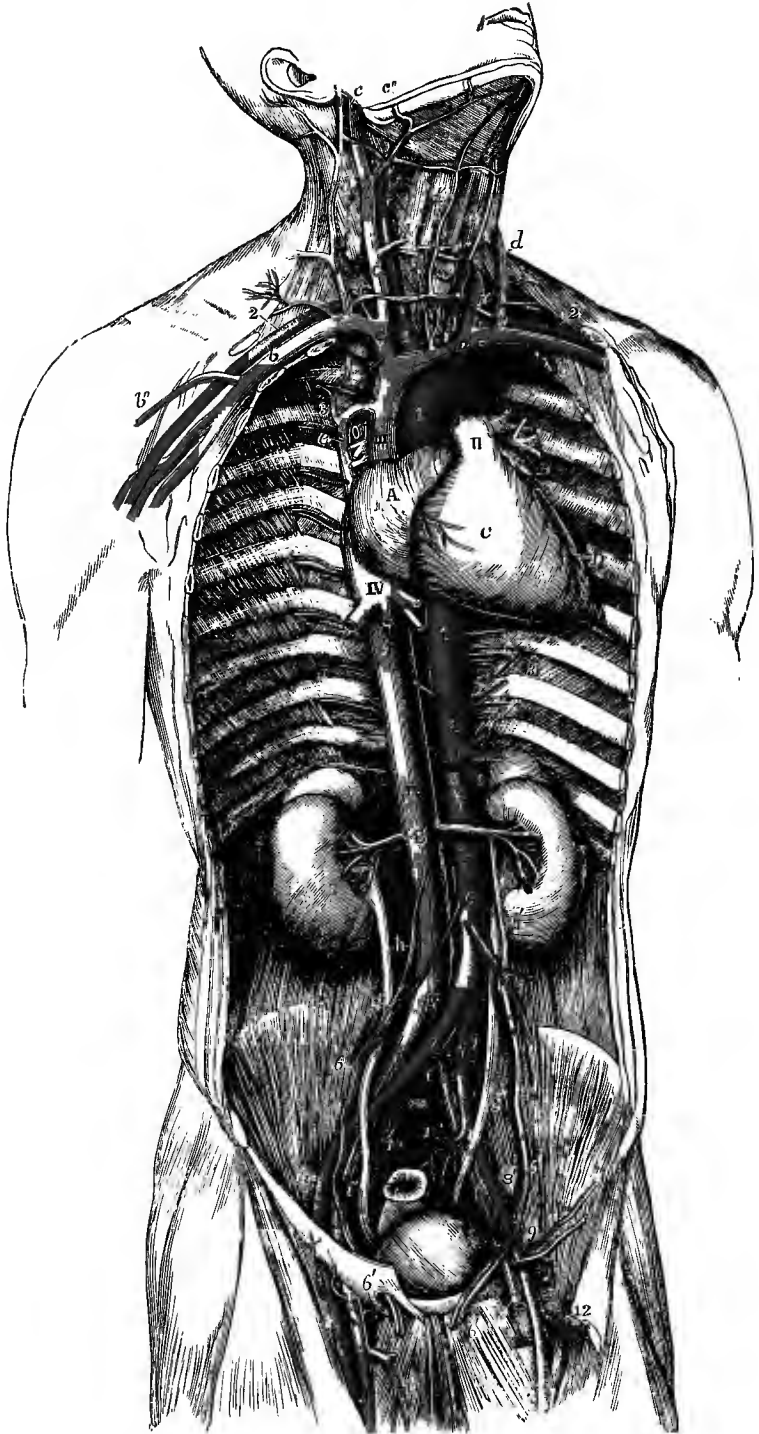
<sup>1</sup> Calculated from Peacock's tables in "Weight and Dimensions of the Heart in Health and Disease, reprinted from the Monthly Journ. of Med. Sci., 1854.



	Circumference.		Male.	Area.	Female.
	Male.	Female.			
Right auriculo-ventricular opening . . . . .	122 mm.	115 mm.	1194 sq. mm.		1017 sq. mm.
Left auriculo-ventricular opening . . . . .	103 "	101 "	855 "		804 "
Pulmonary opening . . . . .	91 "	89 "	660 "		615 "
Aortic opening . . . . .	81 "	76 "	530 "		452 "

## RECENT LITERATURE OF THE HEART.

- Bardeleben, K.**, *Ueber die anatomischen Verhältnisse der vorderen Brustwand und die Lage des Herzens*, Jenaische Sitzungsber., 1885.
- Berger, A.**, Bull. Soc. An. Paris, 1890. (Aortic valve of two segments.)
- Bond, C. J.**, *On the influence of the position of the body on the position of the heart and on intra-cardiac pressure*, Brit. Med. Journ., 1885.
- Brown, Macdonald**, *The construction of the ventricles in the mammalian heart*, Journ. Anat., xiii, 1889. (Papillary muscles and moderator band.)
- Clarke, J. J.**, *Quadruple pulmonary valve*, Proc. Anat. Soc., November, 1889, Journ. Anat., xxiv.
- Coen, E.**, *Ueber die Blutgefäße der Herzklappen*, Arch. f. mikrosk. Anat., xxvii, 1886.
- Darier, J.**, *Les vaisseaux des valvules du cœur, &c.*, Bull. Soc. Anat., Paris, 1887, and Archives de physiologie, 1888.
- Eisenlohr, L.**, *Ueber die Nerven und Ganglienzellen des menschlichen Herzens*, 1886.
- Foot, A. W.**, *Pulmonary artery with two valves*, Trans. Roy. Acad. Med. Ireland, vi, 1888.
- Giacomini, C.**, *Topografia del cuore*, Torino, 1886.
- Henke, W.**, *Construction der Lage des Herzens*, Tübingen, 1883.
- His, W.**, *Beiträge zur Anatomie des menschlichen Herzens*, Leipzig, 1886.
- His & Romberg**, *The innervation of the heart* (embryological and physiological), Verhandl. d. ix. Congress f. innere Medicin in Wien, 1890, p. 356. See also Centralblatt f. Physiologie, 1890, p. 601, and Brit. Med. Journal, 1890, vol. i.
- Krause, W.**, *Die Blutgefäße der Herzklappen*, Internat. Monatschr. f. Anat., iv, 1889.
- Krzywicki, C. v.**, *Das septum membranaceum ventriculorum cordis*, in Beiträge zur pathologischen Anatomie, 1889.
- Langer, L. v.**, *Ueber die Blutgefäße in den Herzklappen*, Arch. f. pathol. Anat., cix, 1887.
- Lawrence, T. W. P.**, *Abnormal aortic and pulmonary valves*, Proc. Anat. Soc., May, 1891, Journ. Anat., xxv.
- Luchsinger, B.**, *Zur Architectur der Semilunarklappen*, Archiv f. d. gesammte Physiologie, xxxiv, 1884.
- Martinotti**, *Le anomalie numeriche d. valvole semilunari d. cuore; &c.*, Gaz. d. Cliniche, and Anatom. Anzeiger, 1886.
- Martinotti, G., e Sperino, G.**, *S. anomalie numeriche d. valvole semilunari aortiche e polmonari*, Atti d. R. Accad. d. Medic. d. Torino, 1884 (French in Arch. ital. de biol., vi, 1885).
- Morin**, *Absence d'une des sigmoïdes de l'aorte*, Bull. Soc. Anat. Paris, 1883.
- Müller, W.**, *Die Massenverhältnisse des menschlichen Herzens*, 1883.
- Openchowski, Th. v.**, *Beitrag zur Kenntniss der Nervenendigungen im Herzen*, Arch. f. mikr. Anat., xxii, 1883.
- Oppenheimer, C.**, *Ueber die Wachstumsverhältnisse des Körpers und der Organe*, Zeitschr. f. Biologie, 1889.
- Ott, A.**, *Zur Kenntniss der Ganglienzellen des menschlichen Herzens*, Prag. med. Wochenschr., 1887, and Prag. Zeitschr. f. Heilkunde, 1888.
- Rolleston, H. D.**, *Quadruple pulmonary valve*, Proc. Anat. Soc., May, 1891.
- Röse, C.**, *Beiträge z. vergleichenden Anatomie des Herzens der Wirbeltiere*, Morphol. Jahrbuch, xvi, 1890.
- Schmaltz, R.**, *Die Purkinje'schen Fäden im Herzen der Haussäugethiere*, Arch. f. Thierheilkunde, xii, 1886.
- Sick, C.**, *Einige Untersuchungen über den Verlauf der Pleurablätter am Sternum, die Lage der arteriellen Herzklappen zur Brustwand und den Stand der rechten Zwerchfellkuppe*, Arch. f. Anat., 1885.
- Symington, J.**, *The topographical anatomy of the child*, 1887. (Position of heart.)
- Thoma, R.**, *Untersuchungen über die Grösse und das Gewicht der anatomischen Bestandtheile des menschlichen Körpers im gesunden und im kranken Zustande*, 1882.
- Töpken, J.**, *Ein Beitrag zur Bestimmung der Lage des Herzens beim Menschen*, Arch. f. Anat., 1885.
- Vaerst**, *Vorkommen, Entwicklung u. physiologische Bedeutung der Herzmuskeln bei Wiederkäuern*, Deutsche Zeitschr. f. Thiermedizin, xiii, 1886.
- Vierordt, H.**, *Anatomische, physiologische und physikalische Daten und Tabellen*, 1888; *Das Massenwachsthum der Körperorgane des Menschen*, Arch. f. Anat., 1890, Suppl. Bd.
- Viti, A.**, *Nuovi osservazioni e considerazioni s. anomalie congenite d. valvole semilunari d. cuore*, lo Sperimentale, 1886.



## 2.—BLOOD-VESSELS. ARTERIES AND VEINS.

The descriptive anatomy of the blood-vessels includes an account of their origin, extent, form, position, mode of division, distribution, anastomoses with each other, and relations to other parts. Seeing, however, that the blood-vessels are subject to numerous variations, while the most frequent forms and modes of distribution are described as the normal, it will be necessary to refer also to the more important varieties which have been observed among them.

The varieties of blood-vessels may consist of a deviation either from the usual size of the channels or from their usual position and their connection with other vessels. In the latter case they may be described as consisting in differences of origin from the main stem, or from a branch, or from quite another source than that which is the most common or usual. But some varieties are so common that it becomes doubtful which form is to be described as normal.

Fig. 328.—GENERAL VIEW OF THE HEART AND BLOOD-VESSELS OF THE TRUNK, FROM BEFORE, IN A MALE ADULT. (Allen Thomson.) †

A, Right auricle; B, left auricular appendix; C, right ventricle; D, part of left ventricle; I, I, aorta; II, trunk of pulmonary artery dividing into its right and left branches, and connected to the aorta by the cord of the ductus arteriosus; III, superior vena cava; IV, IV, inferior vena cava.

1, innominate artery and right carotid; 1', left carotid; 2, 2, right and left subclavian arteries; 3, intercostal vessels; 4, inferior phrenic arteries; below 4, the coeliac axis and superior mesenteric artery; 5, renal arteries; 6, 6', spermatic arteries; below 6, the inferior mesenteric; 7, 7', right and left common iliac arteries; 8, 8', external iliac arteries; 9, left epigastric and circumflex iliac arteries; 10, 10', internal iliac arteries; and between these two figures, the middle sacral artery; 11, 11, femoral arteries; 12, deep femoral artery of the left side.

*a*, right innominate vein; *a'*, the left; *b, b'*, right and left subclavian veins; *b''*, the cephalic vein of the right arm; *c, c'*, internal jugular veins; *c''*, right facial vein; *d, d'*, external jugular veins formed by the posterior auricular and part of the temporo-maxillary; *d''*, anterior jugular veins with the transverse branch joining them; *e*, azygos vein arching over the root of the right lung; *f*, hepatic veins; *g*, renal veins; to the sides are seen the kidneys and the suprarenal bodies; *g'*, right, *g''*, left ureter; *h, h'*, spermatic veins; *i, i'*, common iliac veins; *i'', i'''*, external iliac veins; *k, k'*, femoral veins; *l*, internal saphenous vein of the right side.

Many of these varieties are not only compatible with life, but cause no disturbance whatever in the performance of the ordinary functions of the body. Others are of such a nature as to be compatible only with the conditions of the circulation subsisting during intrauterine life, and therefore prove fatal at birth. Some are of considerable interest from their frequency, and others from their existing in situations where they are liable to affect the progress or results of surgical operations.

Many vascular varieties repeat forms which are natural in different species among the lower animals; others are obviously due to the persistence of early foetal forms of distribution; and not a few are explicable on the supposition of abnormal enlargement or diminution of naturally existing vessels.

For fuller information on the natural and abnormal distribution of the blood-vessels, the reader may consult the works of Haller, Tiedemann, and Barkow, and more especially the "Anatomy of the Arteries," by Richard Quain, 1844, and Henle's "Handbuch," vol. iii, part I, 2nd ed., 1876, in which a connected view of the varieties by W. Krause is given.

The dimensions of the arteries vary to some extent in different individuals and in the two sexes, as well as at different periods of life; for it is found that, as in the case of the heart, both the capacity and the thickness of the walls of the large arteries increase gradually with advancing years. At the same time they gain in length, and as a result of this and of a diminution in elasticity of their coats they often become markedly tortuous in old persons. The primary branches of the aortic trunk, and their secondary and tertiary ramifications are divided by Henle, accord-

ing to their average calibre (after injection), into six groups or orders, as shown in the annexed table ; and this classification will be adopted in the following descriptions, the order to which each principal artery belongs being indicated by Roman figures within a parenthesis after its name. The average diameter of the pulmonary artery and of the several parts of the aorta will be directly stated in millimeters, as will also that of the innominate, subclavian, common iliac and external iliac trunks, which are considerably larger than the arteries of the first order, but differ too widely in size from one another to be included in one group.

ORDER.	AVERAGE CALIBRE.	EXAMPLE.
I.	8 mm. ( $\frac{1}{3}$ inch)	Common carotid.
II.	6 mm. ( $\frac{1}{4}$ inch)	Brachial.
III.	5 mm. ( $\frac{1}{5}$ inch)	Ulnar.
IV.	3.5 mm. ( $\frac{1}{7}$ inch)	Radial.
V.	2 mm. ( $\frac{1}{12}$ inch)	Posterior auricular.
VI.	1 to .5 mm. ( $\frac{1}{25}$ to $\frac{1}{50}$ inch)	Supraorbital.

The sanguiferous system consists of two great divisions, comprehended in the lesser or pulmonic and the greater or systemic circulations. To the former belong the pulmonary artery and veins, which will be first described.

## PULMONARY ARTERY AND VEINS.

### PULMONARY ARTERY.

The pulmonary artery conveys the dark blood from the right side of the heart to the lungs. The main trunk is a short wide vessel (diameter 30 mm.), which arises from the summit of the infundibulum of the right ventricle, and runs for a distance of two inches or rather more backwards, as well as upwards, towards the concavity of the aortic arch ; a little below the latter, and about on a level with the disc between the fifth and sixth dorsal vertebræ, it divides into two branches—the right and left pulmonary arteries, which pass to the corresponding lungs. The mode of attachment of the pulmonary trunk to the base of the ventricle is noticed in the description of the heart. Contained entirely within the fibrous pericardium, it occupies a position in relation to the anterior chest-wall immediately to the left of the sternum, behind the anterior extremity of the second intercostal space, from which it is separated by the left lung and pleura. At each side of its commencement is the corresponding coronary artery springing from the aorta, and close to its sides are the two auricular appendages. It is at first in front of the aorta, but as it passes back it lies on the left side of that vessel, around which it describes a slight curve ; and its termination is in a plane altogether behind the ascending aorta. The two vessels are united together by connective tissue and by the serous layer of the pericardium, which forms a single tube around them. Below and behind, the pulmonary trunk rests upon the left auricle of the heart ; and on its left side (above the auricular appendage) it is only separated by the pericardium from the pleura and lung.

The **right pulmonary artery** (21 mm.), longer and somewhat larger than the left, runs almost transversely below the arch of the aorta, and behind the ascending aorta and the superior vena cava, to the root of the right lung. It lies above the left auricle of the heart, and crosses in front of the œsophagus. In the root of the lung it divides into two primary branches, the upper of which is distributed to the upper lobe of the lung, and the lower, much the larger, to the middle and lower lobes.

The **left pulmonary artery** (19 mm.), situated a little higher than the right, passes nearly horizontally outwards and backwards, in front of the left bronchus and the descending aorta, to the root of the left lung, and divides into two branches, of which the lower is the larger, for the upper and lower lobes of the lung. From the

upper aspect of this artery, a little to the left of the point of bifurcation of the main trunk, a short fibrous cord, the *ligamentum arteriosum*, passes obliquely upwards and backwards to join the under side of the aortic arch (fig. 309). This is the remains of the *ductus arteriosus*, which in the fœtus forms the continuation of the pulmonary trunk.

In the root of the lung on both sides the pulmonary artery lies in front of the bronchus, and behind the superior pulmonary vein. On the right side the bronchus is higher than the artery; while on the left the artery rises above the bronchus.

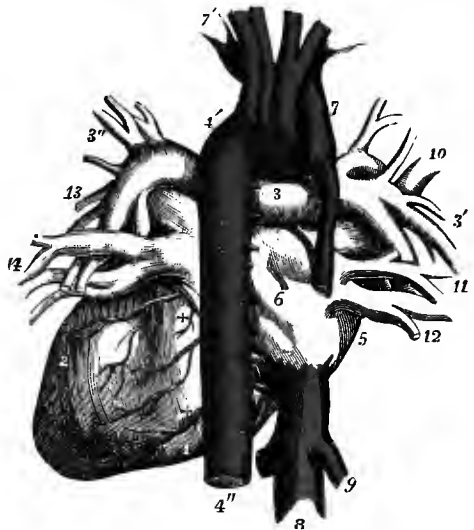
The varieties of the pulmonary artery will be referred to along with those of the aorta.

#### PULMONARY VEINS.

The pulmonary veins are four short trunks which convey the red blood from the lungs to the left side of the heart, and which are found, two on each side, in the root of the corresponding lung. On both sides the superior vein lies in front of, as

Fig. 329.—THE HEART AND GREAT VESSELS, FROM BEHIND. (R. Quain.)  $\frac{1}{3}$

1, right, 2, left ventricle; 3, right pulmonary artery near the division of the main trunk; 3', branches of the right pulmonary artery in the root of the right lung; 3'', the same of the left; 4, arch of the aorta; 4'', descending thoracic aorta; 5, right auricle; 6, is placed on the division between the right and left auricles; 7, superior vena cava, being joined by the large azygos vein; 7', left innominate vein; 8, inferior vena cava; 9, one of the hepatic veins; 10, upper, 11, middle (additional), and 12, lower right pulmonary vein; 13, upper, and 14, lower left pulmonary vein; +, +, branches of coronary arteries.



well as at a lower level than, the pulmonary artery; while the inferior vein is placed farther back, and below the other constituents of the root. The two veins of the *right* side pass behind the superior vena cava and the right auricle, to enter the left auricle; the upper vein receives one or more branches from the middle lobe of the right lung. The two *left* pulmonary veins pass in front of the descending aorta to reach the auricle. The pulmonary veins are joined, as they issue from the lung, by small anterior bronchial veins from the larger bronchia, the bronchial glands, and the back of the pericardium (Zuckerkanal).

The length of the pulmonary veins is generally less than three-quarters of an inch, and their diameter from 13 to 15 mm. Their relative size varies somewhat in different individuals, but usually the right upper is the largest, and the left upper the smallest of all. Their capacity does not exceed that of the arteries, and indeed is said by some anatomists to be rather less; according to C. Krause the united sectional area of the four pulmonary veins is to that of the right and left pulmonary arteries as 99 : 100. The pulmonary veins have no valves.

The length of the pulmonary veins is generally less than three-quarters of an inch, and their diameter from 13 to 15 mm. Their relative size varies somewhat in different individuals, but usually the right upper is the largest, and the left upper the smallest of all. Their capacity does not exceed that of the arteries, and indeed is said by some anatomists to be rather less; according to C. Krause the united sectional area of the four pulmonary veins is to that of the right and left pulmonary arteries as 99 : 100. The pulmonary veins have no valves.

**Varieties.**—The two veins of one side, more often the left, may unite into a common trunk before entering the auricle. There is frequently a third smaller vein on the right side, coming from the middle lobe of the lung. Other supernumerary veins are of rare occurrence. The upper pulmonary vein of the right side has been seen opening into the superior vena cava, that of the left side into the left innominate vein. In one instance the single right pulmonary vein was found joining the large azygos vein (F. J. Shepherd, *Journ. Anat.*, xxiv).

## SYSTEMIC ARTERIES.

## THE AORTA.

The aorta, the main trunk of the systemic arteries, is at its commencement generally a little smaller than the pulmonary artery, but in old persons it becomes rather larger than that vessel. Springing from the left ventricle of the heart, it

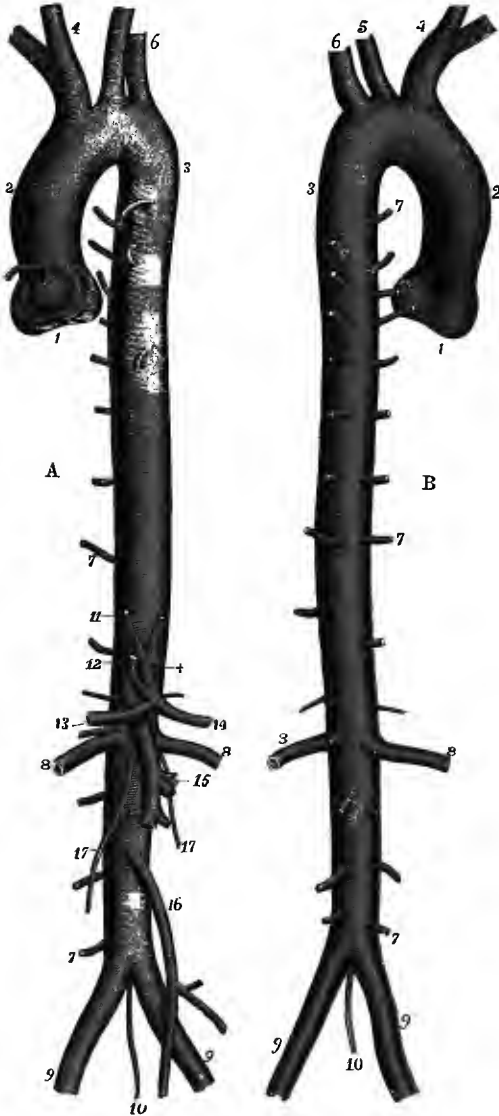


Fig. 330.—THE AORTA, A, FROM BEFORE, B, FROM BEHIND, WITH THE ORIGINS OF ITS PRINCIPAL BRANCHES. (R. Quain.)  $\frac{1}{2}$

1—2, ascending aorta; at 1, where the aorta has been separated from the left ventricle, are seen the semilunar valves in a closed condition, the sinuses of Valsalva, and the origins of the right and left coronary arteries; at 2, is the great sinus; 2—3, arch of aorta; 4, innominate artery; 5, left carotid; 6, left subclavian; 7, 7, 7, indicate three out of the series of intercostal and lumbar arteries: the bronchial and cesophageal arteries are also seen arising from the front of the descending thoracic aorta; 8, 8, right and left renal arteries; 9, 9, right and left common iliac arteries; 10, middle sacral artery; 11, one of the inferior phrenic arteries; +, cœliac axis; 12, gastric artery; 13, hepatic; 14, splenic; 15, superior mesenteric; 16, inferior mesenteric; 17, 17, right and left spermatic arteries.

arches over the root of the left lung, descends along the vertebral column, and, after passing through the diaphragm into the abdominal cavity, ends opposite the fourth lumbar vertebra, by dividing into the right and left common iliac arteries. In this course the aorta forms a continuous single trunk, which gradually diminishes in size from its commencement to its termination (from 28 to 17 mm.), and gives off larger or smaller branches at various points. It is divided into the *ascending aorta*, the short part which is contained in the pericardium, the *arch*, passing backwards to the spine, the *descending thoracic aorta*, the

comparatively straight part extending to the diaphragm, and the *abdominal aorta* below the diaphragm.<sup>1</sup>

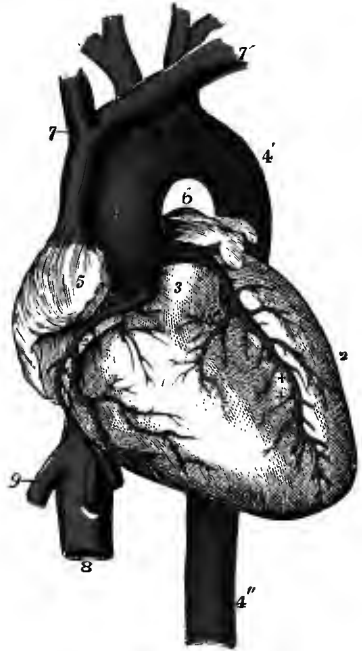<sup>1</sup> It has been usual in English text-books to describe the arch of the aorta as extending from the left ventricle of the heart to the lower border of the fifth dorsal vertebra, and being divided into three

## ASCENDING AORTA.

The ascending aorta (28 mm.) arises from the upper and fore part of the base of the left ventricle of the heart, under cover of the upper end of the infundibulum of the right ventricle. At its commencement it is placed behind the left half of the sternum, on a level with the lower border of the third costal cartilage. Thence it passes upwards and to the right side somewhat in the direction of the heart itself, but at the same time approaching nearer to the sternum, and gains the right border of that bone opposite the attachment of the second costal cartilage. At this spot the vessel changes its course, taking a direction backwards and to the left, and the

Fig. 331.—THE HEART AND GREAT SYSTEMIC VESSELS, FROM BEFORE. (R. Quain.)  $\frac{1}{2}$

The pulmonary artery has been cut short close to its origin in order to show the first part of the aorta. 1, right ventricle; 2, left ventricle; 3, root of pulmonary artery; 4—4', arch of the aorta; 4'', descending thoracic aorta; 5, right, and 6, left auricular appendix; 7, 7', innominate veins, joining to form the superior vena cava; 8, inferior vena cava; 9, one of the hepatic veins; +, placed in the right auriculo-ventricular groove, points to the right coronary artery; ++, placed in the anterior interventricular groove, points to the descending branch of the left coronary artery.



arch is considered to begin. The length of the ascending aorta is about two inches or two inches and a quarter, and it describes a slight curve with its concavity upwards, backwards, and to the left. Near the base of the heart the aorta is enlarged, and presents externally three small bulgings of nearly equal size, corresponding with the dilatations which form the sinuses of Valsalva, described with the heart. These sinuses are placed, one in front and two behind, and from the anterior and left posterior are given off the two coronary arteries of the heart.

In most cases there is also along the right side of the ascending aorta and the beginning of the arch another dilatation called the *great sinus of the aorta*. This dilatation varies in size in different bodies, and occasionally is not to be detected: it is commonly better marked in old persons.

The ascending aorta is entirely covered by the fibrous pericardium, and is enclosed with the pulmonary trunk in a common sheath of the visceral pericardium, in such a manner that both vessels are invested by the serous membrane except where they are in contact with each other. At its commencement it is concealed anteriorly by the pulmonary trunk and the right auricular appendage; but farther up, as the aorta passes forwards and to the right side, and the pulmonary trunk

parts called *ascending*, *transverse* and *descending*. But the first part differs so much from the rest of the vessel in respect of its intrapericardial position and its origin from the fetal aortic bulb as to justify its separation as a primary division of the trunk, whereas the third part is in no way marked off by differences in direction, relations, or mode of development from the remainder of the descending trunk, and the whole of the vessel which rests against the dorsal vertebræ, from the fourth onwards, is therefore here described as the *descending thoracic aorta*, the name *arch of the aorta* being confined to the portion passing backwards above the root of the lung.

backwards on the left, it comes very near the sternum, from which it is separated by the pericardium, by the right pleura with the narrow portion of the anterior mediastinum and a little fat, and to a variable extent by the thin anterior margin of the right lung. On its right side are the superior vena cava and the right auricle; on the left side is the pulmonary trunk; and behind are placed the left auricle of the heart and the right pulmonary artery.

**BRANCHES.**—The only branches of the ascending aorta are the coronary arteries, two comparatively small vessels for the supply of the heart. They arise from the root of the aorta, in the upper parts of two of the sinuses of Valsalva, and about on a level with the free margins of the corresponding semilunar flaps of the aortic valve.

The **right coronary artery (iv)** arises from the anterior sinus of Valsalva. It comes forwards between the pulmonary artery and right auricular appendix, then runs obliquely in the auriculo-ventricular groove on the right side and the posterior aspect of the heart, until it reaches the line of separation between the two ventricles, where it divides into two branches. The smaller of these (*transverse*) continues transversely in the groove between the left auricle and ventricle, approaching the termination of the transverse branch of the left coronary artery; while the other branch (*descending*) runs longitudinally downwards along the posterior interventricular groove, giving branches to each ventricle and to the septum between them.

In its course the right coronary artery gives, besides the offsets already noticed, small branches to the right auricle and ventricle, and also to the first part of the aorta and the pulmonary trunk. An *infundibular* branch ramifies over the front of the conus arteriosus of the right ventricle, and a larger *marginal* branch descends along the right border towards the apex of the heart, giving offsets to the anterior and posterior surfaces of the ventricle.

The **left coronary artery (iv)** is generally rather larger than the preceding, and arises from the left sinus of Valsalva. It passes behind and then to the left side of the pulmonary trunk, appearing between that vessel and the left auricular appendage, where it divides into two branches. Of these, the one (*posterior* or *transverse*) runs in the groove between the left ventricle and auricle, and approaches at the posterior aspect of the heart the transverse branch of the right coronary artery; the other branch (*anterior* or *descending*), much the larger, descends along the anterior interventricular groove, to the right of the apex of the heart.

The left coronary artery supplies at its beginning small branches to the pulmonary artery, ascending aorta, and the left auricle. Its anterior division furnishes offsets to both ventricles and the interventricular septum; while from its posterior division small branches pass to the left auricle and ventricle, and a considerable *marginal* branch usually runs along the left border of the heart posteriorly.

The two coronary arteries have fine anastomoses with one another on the surface of the heart, and they communicate also, by means of the small branches given to the coats of the great vessels, with the pericardial and bronchial arteries.

**Varieties.**—The level of the orifices of the coronary arteries in the sinuses of Valsalva varies somewhat, being often above, and sometimes below the free margin of the valve-segment. The two arteries have been seen commencing by a common trunk, or both arising from one sinus of Valsalva. The existence of three arteries is not unfrequent, and in a few instances four have been observed, the supplementary vessels being generally small, springing from the aorta near the main coronary trunk, and representing normal branches of the latter which have acquired an independent origin: the two divisions of the left artery occasionally come off separately from the left sinus of Valsalva. In some very rare cases an additional coronary artery has been found arising from the pulmonary trunk (W. Krause; H. St. John Brooks, two cases, Journ. Anat., xx).

A diminution in the size of one coronary artery is compensated by an increase in the other, which is then distributed over a larger area, especially on the back of the heart: the left artery may thus furnish the branch descending in the posterior interventricular furrow.



## ARCH OF THE AORTA.

From the right border of the sternum, at the level of the second costal cartilage, the aorta is directed at first upwards, backwards and to the left, and then directly backwards, forming a well-marked curve around the trachea, to the left side of the

Fig. 332.—VIEW OF THE THORACIC AND GREATER PART OF THE ABDOMINAL AORTA, SHOWING THEIR PRINCIPAL RELATIONS. (Allen Thomson.)  $\frac{1}{2}$

*a*, hyoid bone; *b, b*, placed on the anterior scalene muscles, point to the pneumo-gastric nerves; *c*, trachea below the isthmus of the thyroid body, and lower down the same letter is on the left bronchus; *c'*, one of the divisions of the right bronchus emerging from behind the aorta; in the hollow of the aortic arch, above 5, are seen the cord of the ductus arteriosus cut short, and the left recurrent nerve passing below the arch; +, is placed on the right side between the recurrent nerve and the vertebral artery as they pass upwards; *d*, oesophagus; *e, e'*, upon the right crus of the diaphragm, mark the receptaculum chyli of the thoracic duct, and its commencement by the lumbar and intestinal lymphatic trunks; *f, f, f*, on the third, seventh, and eleventh ribs, point to the vena azygos and intercostal veins of the right side; *g*, kidney; *g'*, suprarenal body; *h*, body of fourth lumbar vertebra.

*I*, ascending aorta: below this the aortic valve is seen closed and distended by injection; *I'*, termination of the arch; *I''*, descending thoracic aorta; *II*, abdominal aorta.

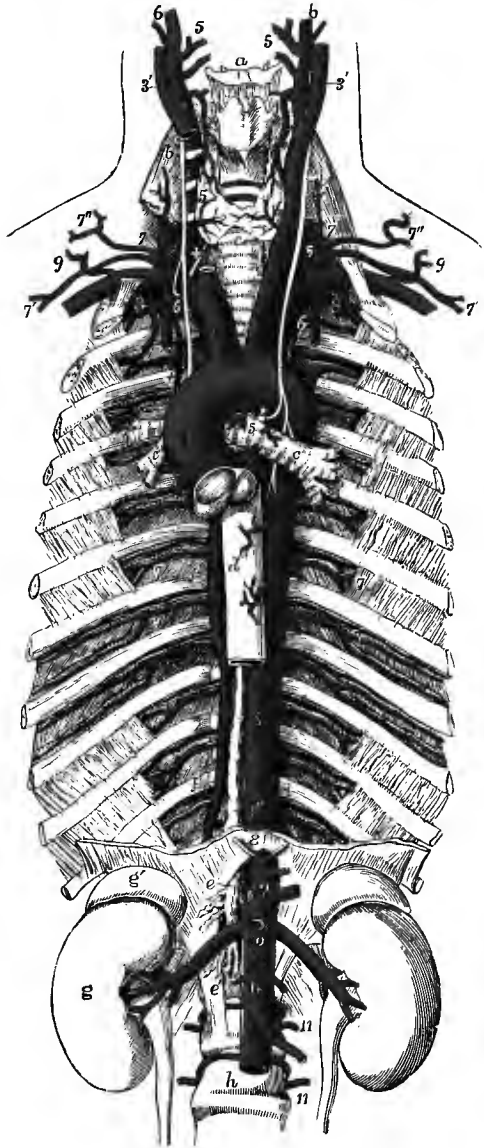
*Branches of the aorta in the thorax:* 1, right and left coronary arteries; 2, innominate; 3, left common carotid; 4, left subclavian; 5, bronchial; 6, 6, oesophageal; the lower figure points by a line to the thoracic duct; 7, intercostal arteries, marked in the sixth and seventh intercostal spaces.

*Branches of the abdominal aorta:* 8, inferior phrenic arteries cut short; 9, celiac axis with the gastric, splenic, and hepatic arteries cut short; 10, placed on the aorta below the superior mesenteric artery (cut short) and the origin of the renal arteries; a little below this the origin of the spermatic arteries; below *II*, the inferior mesenteric artery; 11, 11, two of the lumbar arteries.

body of the fourth dorsal vertebra. There it bends downwards, and at the lower border of that vertebra the arch terminates in the

descending thoracic aorta. Its upper border, as it crosses the median plane, is usually about one inch below the interclavicular notch of the manubrium.

The arch of the aorta is contained in the superior mediastinum, and at its commencement is separated from the manubrium by the fatty remains of the thymus gland; on each side of this it is covered, slightly on the right, to a much greater



extent on the left, by the pleura and lung. It is crossed on the left side by the left pneumo-gastric and phrenic, and the superficial cardiac nerves, as well as more posteriorly by the left superior intercostal vein; and the recurrent laryngeal branch of the pneumo-gastric turns upwards beneath it. Behind and to its right side are placed the trachea with the deep cardiac plexus, the left recurrent laryngeal nerve, the œsophagus and thoracic duct, and the body of the fourth dorsal vertebra. The upper border of the arch has in contact with it along its anterior half the left innominate vein; and from it are given off the large arteries (innominate, left carotid and left subclavian) which are furnished to the head and upper limbs. The lower or concave border overhangs the left bronchus and the bifurcation of the pulmonary artery, and is connected with the left branch of that artery by the ligamentous remains of the ductus arteriosus, which is attached to the aorta just beyond the place at which the left subclavian artery springs from its upper aspect (fig. 312). In the interval between the arch and the bifurcation of the pulmonary artery are lodged the superficial cardiac plexus and several large bronchial lymphatic glands; and along its lower and fore part the fibrous pericardium becomes united with its external coat.

The arch of the aorta is considerably reduced in size (to 23 mm.) after having given off the large branches, and it often presents, beyond the origin of the subclavian artery, at the part corresponding to the place of attachment of the ligament of the ductus arteriosus, a marked constriction known as the *aortic isthmus*, which is succeeded by a fusiform dilatation—the *aortic spindle* of His, extending to the beginning of the descending thoracic aorta.<sup>1</sup> In the fœtus the isthmus is more distinct, the entrance of the ductus arteriosus causing a sudden expansion of the contracted aortic trunk.

**BRANCHES.**—From the arch of the aorta are given off the three large primitive trunks, which supply the head and neck, the upper limbs, and, in part, the thorax. They arise from the upper aspect of the arch, in the following order:—first, the innominate or brachio-cephalic artery; second, the left common carotid; and third, the left subclavian artery. The origin of the left carotid artery is usually nearer to the innominate artery than it is to the subclavian artery of its own side.

**Varieties of the aorta, &c.**—It will be convenient to consider together in this place the varieties of the aorta generally, those of the pulmonary artery, and irregularities in the arrangement of the branches given off from the aortic arch. The conditions to be referred to are for the most part the result of abnormal modes of development affecting the primitive arterial trunks and arches of the embryo, such as irregular position or defective development of the aortic septum, the persistence of channels that are usually obliterated, with more or less extensive occlusion of the normal passages, and variations in the degree of fusion of adjacent vessels; and the manner in which some of the more important of these, as well as the normal arrangement, are related to the embryonic condition is shown in the diagrams in fig. 333. For a full account of the development of these arteries in the fœtus the reader is referred to the section on Embryology in Volume I.

1. The aorta may vary in its *position* and *extent*, without other irregularity in course or relations. Thus, the height to which the arch rises in the upper part of the chest is found to be subject to variation to the extent of one or two vertebræ; so that while in some instances the summit of the arch is on a level with the third dorsal vertebra, reaching as high as the top of the sternum, in other cases it is as low as the fifth dorsal vertebra.

The distance to which the aorta extends downwards depends on the seat of its division into the common iliac trunks, which frequently varies to the extent of a lumbar vertebra, so that the place of division may be as low down as the fifth or as high up as the third. In rare cases the division occurs still higher.

The position of the aorta with reference to the median plane or vertebral column is also subject to some variation, but such deviation to the side is more frequently the result of pathological changes than of congenital malformation.

<sup>1</sup> W. His, "Anatomie menschlicher Embryonen," iii. 196; H. Stahel, "Ueb. Artercienspindeln u. ih. d. Beziehung d. Wanddicke d. Arterien z. Blutdrucke," Arch. f. Anat., 1886.

2. A very remarkable malformation of the descending aorta consists in the greater or less division of the vessel through a part or the whole of its channel into two closely united tubes, by a median septum running from before backwards, or slanting from side to side, which, when not due to pathological changes, may admit of explanation on the supposition of the fusion of the original double embryonic aorta having remained incomplete.

3. The *Varieties of the Stems*, or of the ascending aorta and pulmonary trunk, are intimately connected and usually associated with malformations of the heart, and frequently with persistence of the ductus arteriosus. These first parts of the two great arteries, specially enclosed by the pericardium, are derived from the aortic bulb of the foetal heart, and are liable to variations which may be traced to deviations from the natural mode of their septal

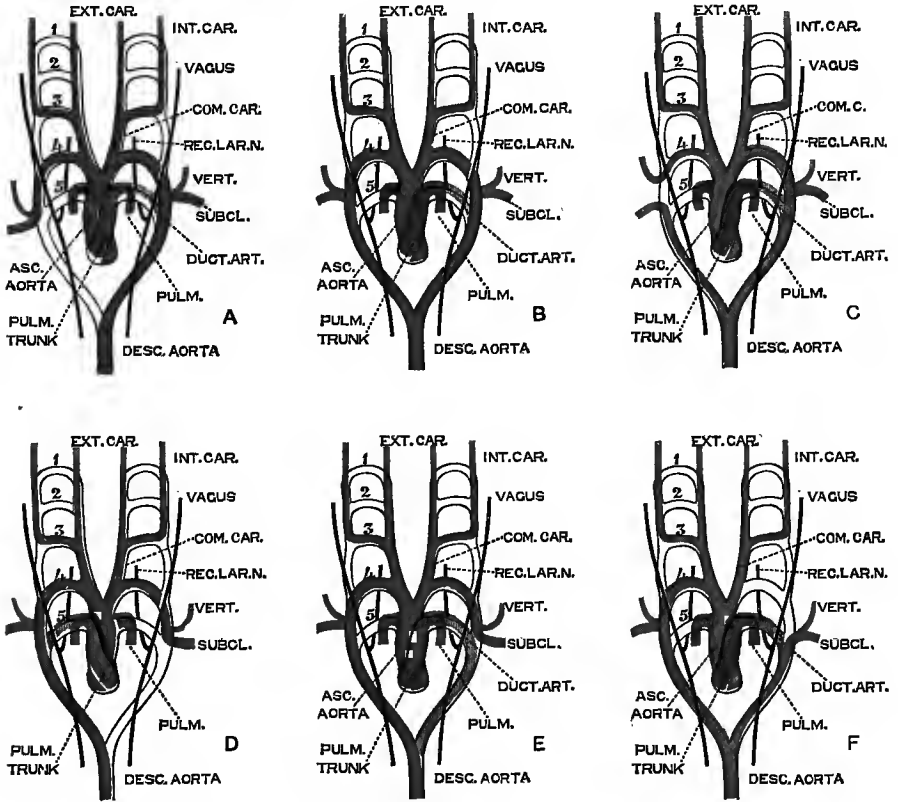


Fig. 333.—DIAGRAMS SHOWING THE MODE OF DEVELOPMENT OF THE GREAT ARTERIES IN THE NORMAL AND IN SOME ABNORMAL CONDITIONS. (After Rathke and Turner, with modifications and additions. G. D. T.)

A, the normal arrangement; B, double aortic arch; C, dorsal origin of the right subclavian artery, with ventral origin of the right vertebral; D, simple transposition, as in *situs inversus*; E, right aortic arch, with a left innominate artery; F, right aortic arch, with dorsal origin of the left subclavian and vertebral arteries.

division, and of their union with the left or right ventricles of the heart respectively. Thus, these two arterial trunks may be transposed, or each one may be connected with the ventricle to which it does not naturally belong, *i.e.*, the pulmonary artery with the left, and the aorta with the right ventricle. Or the arterial trunks may communicate together more or less freely by deficiency of the septum between them. Or one of the vessels may be nearly or entirely obliterated; while the other, from unnatural openings left between them, serves as the channel for the stream of blood belonging to both vessels. Or the aorta and pulmonary

artery may be entirely united in one simple stem in connection with a simple heart similar to that of fishes.

4. The *Varieties in the Aortic Arch* itself are intimately connected with the mode of development of the fourth arterial arches. The natural aortic arch of man, and of all mammalia, is a left one produced by the persistence and development of the left fourth arch; in birds it is the right fourth arch which forms the permanent aorta; and in reptiles both the right and left fourth arches remain patent.

Reference may here be made to the complete lateral transposition which is occasionally seen in the aortic arch and pulmonary arteries (fig. 333, D), as well as in the great veins and the several divisions of the heart, and which may affect only these parts (*dextrocardia*), or may be accompanied by a similar transposition of the viscera of the body generally (*situs inversus*). Such cases are usually unattended by any disturbance of function or other unnatural condition of structure. There is in fact only a change of position which may be compared to that in which the natural parts would appear if viewed by reflection from a mirror. From the direction of the apex of the heart towards the right, and other deviations from the natural position, the existence of this transposition is capable of being ascertained during life.

The aortic arch has been observed *completely double* in some rare cases, which may be explained on the supposition that both the right and left fourth arches have remained pervious and undergone development. The ascending aorta, having the usual relation to the pulmonary artery, divides above into two branches which pass backwards, embracing the trachea and œsophagus, and join on the left side of the spine to form the descending aorta. Each arch gives origin to the common carotid and subclavian arteries of its own side (fig. 333, B). Examples of this condition have been recorded by Hommel, Curnow, and some others. In one remarkable instance, however, known as Malacarne's case, the arrangement was different, and seems to have been the result of some unusual mode of formation of the arterial stem. The ascending aorta divided close to the heart, and the two arches embraced the trunk of the pulmonary artery, as well as the trachea and œsophagus; and each gave rise successively to a subclavian, an external, and an internal carotid artery, an arrangement which is inconsistent with the known modes of development of the vascular arches.

The existence of a *right aortic arch*, that is, one passing to the right of the trachea and gullet, instead of the usual left arch, is easily explained on the supposition of the right fourth arch having been developed instead of the left; and accordingly there are instances of this variety, in which no other deviation from the natural condition of the parts exists beyond what proceeds from the change of side taken by the aortic arch, leading to the innominate or brachio-cephalic artery being a left one, and the succeeding vessels being the right carotid and right subclavian (fig. 333, E): the recurrent laryngeal nerve forms its sling on the right side round the aortic arch, and on the left round the arch of the subclavian artery. But in the majority of cases of right aortic arch which have been recorded there has been a farther irregularity affecting the origin of the left subclavian artery, which arose independently of the carotid from the dorsal extremity of the arch in the manner described in the next group.

5. Varieties of the *posterior part of the arch* and *ductus arteriosus* belong properly to changes occurring in connection with that portion of the primitive dorsal aorta (or as it is often called the *posterior aortic root*) which intervenes between the termination of the fourth arch and the spot where the two trunks unite to form the single descending aorta. In the normal condition this part persists on the left side, but is obliterated on the right.

The most frequent variety of this group is that of the subclavian artery (of the right side when the aortic arch is left or normal) arising from the back part of the arch, or fourth in the series of vessels proceeding therefrom (fig. 334), a condition in which the subclavian artery is continued from the primitive dorsal aorta (fig. 333, C), while the natural channel through the fourth arch is closed. In such cases the subclavian artery takes its course behind the trachea and gullet to reach its natural place between the scalene muscles and over the first rib, and the inferior laryngeal nerve is not recurrent, but passes directly to the larynx without being drawn down as a loop by the subclavian artery.

A similar variety may occur with a right aortic arch, and the left subclavian artery is then found to arise from the dorsal extremity of the arch by means of a kind of pouch which represents the abnormally persistent part of the primitive dorsal aorta, and which receives the insertion of the ligamentum arteriosum (fig. 333, F). The left recurrent laryngeal nerve forms its loop below the arch thus constituted by the ligamentum arteriosum and the beginning of the subclavian artery. There are also many instances of transitions or gradations between these cases and the completely double aortic arch.

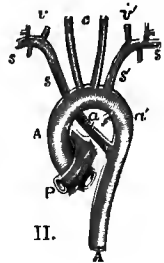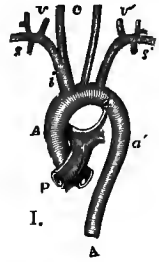
In many of the cases of aberrant subclavian artery of the kind now referred to, the vertebral artery is detached from the subclavian, and arises from the aorta in common with the right carotid artery. Here the subclavian is derived from the dorsal aorta, while the

vertebral is continued from the fourth arch, the connection of the latter with the dorsal aorta being obliterated (fig. 333, C). In such cases the inferior laryngeal nerve passes inwards to the larynx around the first part of the vertebral artery. There are also a few examples of the converse of this condition, the vertebral artery of the right side having a dorsal origin, and passing behind the trachea and œsophagus to its usual place, while the subclavian is continued from the fourth arch.

Under the same division may be brought the numerous varieties in the closure of the ductus arteriosus, and its union with the aorta or other vessels, which have been observed. The greater number of these it will be understood, from the nature of the change in the circulation which takes place at birth, are only compatible with intrauterine life. Such are those cases in which the pulmonary artery leads through the ductus arteriosus, or fifth arch of the left side, into the descending aorta, while the aortic arch itself is more or less separated by a constriction or even a complete closure of its tube in the situation of the aortic isthmus from the descending part of the aorta. It is remarkable, however, that in some rare cases of the kind now referred to, life has been prolonged after birth, and

Fig. 334.—DIAGRAM OF THE NATURAL ORIGIN OF VESSELS FROM THE AORTIC ARCH AS COMPARED WITH THE DISPLACED SUBCLAVIAN ARTERY. (Allen Thomson.)

I, the normal disposition; II, the right subclavian artery displaced or proceeding from the dorsal aorta. A, A, ascending and descending parts of the thoracic aorta; P, pulmonary trunk; *a*, ligamentum arteriosum; *a'*, part of the right primitive dorsal aorta; *a''*, the corresponding part of the left side; *c*, common carotid arteries; *i*, innominate artery; *s*, right, and *s'*, left subclavian artery; *v*, right, and *v'* left vertebral artery.



the ductus arteriosus having become closed, probably gradually, the descending aorta has come to receive a full supply of blood from enlarged anastomosing vessels (internal mammary, intercostal, &c.) passing between the vessels which arise from the arch and those connected with the descending aorta.

Along with the same division may also be classed the series of converse cases, in which the pulmonary trunk being closed below, the right and left pulmonary arteries have received their supply of blood from the aorta. Such examples of the origin of the pulmonary arteries from the aorta, as they have been styled, and examples of the origin of the left, or as a very rare occurrence of the right, subclavian artery from the ductus arteriosus or from one of the pulmonary arteries, are explicable by reference to the same group of developmental phenomena.

6. The varieties in the *number* and *position* of the *vessels springing from the arch* of the aorta are extremely numerous; some very frequent, others comparatively rare. These vessels may be all collected into one trunk, or they may arise separately from the aorta to the number of six. In the rare case of one trunk, we may suppose the origins of the right and left arches to be united, and the fourth left arch to be much shortened, thus bringing all the branches together, as naturally occurs in the horse, forming what is called the anterior aorta.

The cases of two vessels from the arch may be of two kinds; in the one, which is the commonest of all the varieties of the aortic vessels in man, and is the normal condition in most apes, the left carotid is united with the innominate artery into a common stem; in the other, which is exceedingly rare, there are two innominate trunks, as in birds.

Three is the normal number of branches arising separately from the arch in man and some other mammals. There is, however, a rare form of variety in which the number is the same, and in which, as occurs naturally in some cetacea, the subclavians are both separate vessels, and the two carotids spring from a common stem in the interval between them.

The commonest form of the condition in which there are four vessels taking origin from the aortic arch is that in which the left vertebral artery arises between the left carotid and subclavian arteries. The origin of four large arteries in the order, right carotid, left carotid, left subclavian, and right subclavian, has been referred to (p. 386). A much rarer form is that in which the vessels arising from the arch are successively the right subclavian, the right carotid, the left carotid, and the left subclavian arteries.

The number of five arteries proceeds from the separate origin of the right subclavian and left vertebral arteries.

In the case of six vessels proceeding from the single arch, of which there are a few instances described, the vessels were in the following order, which is that which might be anticipated from the mode of development, viz., right subclavian, vertebral and carotid, left carotid, vertebral and subclavian arteries.

Other branches which have been seen arising from the arch are the internal and external carotids, the internal mammary, the inferior thyroid, the thyroidea ima (*v. infra*), and one or both bronchial arteries (frequently).

(For more detailed information as to these and some other varieties of the great arteries see Turner, "On Irregularities of the Pulmonary Artery, Arch of the Aorta," &c., Brit. and For. Med. Chir. Rev., xxx, 1862; Allen Thomson, "Description of a Case of Right Aortic Arch," Glasgow Med. Journ., 1863; and Henle's "Handbuch.")

#### INNOMINATE ARTERY.

The innominate or brachio-cephalic artery (14 mm.), the largest of the vessels which proceed from the aorta, arises from the upper surface of the arch, before the left carotid artery. From this point the vessel ascends obliquely towards the right, until it arrives opposite the sterno-clavicular articulation of that side, on a level with the upper margin of the clavicle, where it divides into the right subclavian and common carotid arteries. The place of bifurcation would, in most cases, be reached by a probe passed backwards through the interval between the sternal and clavicular portions of the sterno-mastoid muscle. The length of the artery usually ranges from one to two inches.

This artery, lying for the most part within the thorax, is placed behind the sternum and the sterno-clavicular articulation, from which it is separated by the sterno-hyoid and sterno-thyroid muscles, by the remains of the thymus gland, and lower down by the left innominate vein, which crosses the artery at its root. The lower part of the innominate artery lies in front of the trachea, the upper against the pleura: on its left side is the left carotid artery below, and the trachea above; and to the right is the corresponding innominate vein.

There are usually no branches arising from this vessel.

**Varieties.**—The length of the innominate artery sometimes exceeds two inches, and occasionally it measures less than one inch. Its place of division is a point of surgical interest, inasmuch as upon it in a great measure depends the accessibility of the innominate in the neck, and the length of the right subclavian artery. It is sometimes found dividing a considerable distance below the clavicle, and sometimes, but rather less frequently, above it. Though usually destitute of branches, this vessel supplies occasionally a thyroid branch, the *thyroidea ima*, and, in rare cases, the internal mammary artery, or a thymic branch, or a bronchial artery, which descends in front of the trachea.

The *thyroidea ima* is an artery which occurs in about 10 per cent. of bodies. It most frequently arises from the innominate trunk, but in some instances it comes from the right common carotid, or from the aorta itself. More rarely it arises from the internal mammary or subclavian. It varies greatly in size in different bodies, and compensates in various degrees for deficiencies or absence of the other thyroid arteries. It ascends to its destination in front of the trachea, and its presence might therefore complicate the operation of tracheotomy.

#### COMMON CAROTID ARTERIES (1<sup>1</sup>).

**POSITION AND RELATIONS—DIFFERENCE ON THE TWO SIDES.**—The common carotid arteries of the right and left sides are nearly alike in their course and position while they are in the neck; but they differ materially in their place of origin, and consequently in their length, and position at their commencement. On the right side the carotid artery commences at the root of the neck behind the upper part of the sterno-clavicular articulation, at the bifurcation of the innominate artery; but on the left side the carotid arises within the thorax, from the middle part of the arch of the aorta, very near the origin of the innominate artery.

While WITHIN THE THORAX, the left carotid ascends obliquely behind and at some distance from the upper piece of the sternum and the sterno-hyoid and the sterno-

<sup>1</sup> This number indicates the order to which the artery belongs: see p. 378.

thyroid muscles; it is covered in front by the remains of the thymus gland, and is crossed by the left innominate vein. This part of the artery lies at first over the trachea, and then over the œsophagus and thoracic duct. The pneumo-gastric



Fig. 335.—VIEW OF THE RIGHT COMMON CAROTID AND SUBCLAVIAN ARTERIES, WITH THE ORIGIN OF THEIR BRANCHES AND THEIR RELATIONS. (R. Quain.)  $\frac{1}{2}$

The sterno-mastoid, sterno-thyroid, sterno-hyoid, and omo-hyoid muscles have been in great part removed, the trapezius has been detached from the outer part of the clavicle and turned backwards, and the inner part of the clavicle has been removed. *a*, parotid gland near the place where the duct leaves it; *b*, angle of the jaw and masseter muscle; *c*, submaxillary gland; *d*, upper part of sterno-mastoid; *e*, hyoid bone; *f*, thyroid cartilage; *g*, thyroid body; *h*, trachea; *i, i'*, sawn ends of the clavicle, the portion between them having been removed; *k*, first rib; *l*, sternum; *m*, scalenus medius; *n*, levator anguli scapulae; *o*, trapezius; *p*, on the rectus anticus major muscle, points to the pneumo-gastric nerve; IV, uppermost of the nerves of the brachial plexus; A, innominate artery; 1, right common carotid; 2, internal carotid; 2', upper part of the internal jugular vein, which has been removed between 2', and *i*; 3, and 4, external carotid; 3 is placed at the origin of the superior thyroid artery; 4, at that of the lingual; farther up the vessel may be seen the separation of the sterno-mastoid twig and the facial and occipital branches from the main vessel; 5, is placed on the thyro-hyoid muscle between the hyoid and laryngeal branches of 5', the superior thyroid artery; 6, facial artery, passing over the base of the jaw; 7, superficial temporal artery; 8, first part, 8', third part of subclavian artery; 8'', subclavian vein separated from the artery by the scalenus anticus; 9, is placed on the scalenus anticus in the angle between the superficial cervical and suprascapular branches of the thyroid axis; 10, outer part of suprascapular artery; 10', superficial cervical artery; 10'', posterior scapular artery; 11, on the scalenus anticus, points to the inferior thyro-hyoid artery near the place where the ascending cervical artery is given off; the phrenic nerve lies on the muscle to the outside of the figure; at *i*, the suprasternal twig of the suprascapular artery is shown.

nerve, pleura and lung are to its outer side ; and the thoracic stage of the left sub-clavian artery is placed farther back and a little more to the left.

IN THE NECK, the common carotid artery of each side reaches from the sterno-clavicular articulation to the level of, or a little above, the upper border of the thyroid cartilage, where it divides into two great branches, of which one is distributed to the superficial parts of the head and to the face, and the other to the brain and



Fig. 336.—SUPERFICIAL DISSECTION OF THE RIGHT SIDE OF THE NECK, TO SHOW THE CAROTID AND SUBCLAVIAN ARTERIES, &c. (R. Quain.)  $\frac{1}{2}$

*a*, angle of the jaw and masseter muscle ; *b*, parotid gland ; *c*, submaxillary gland ; *d*, mylohyoid muscle below the anterior belly of the digastric ; *e*, anterior, *e'*, posterior belly of omo-hyoid ; *f*, sterno-hyoid ; *g*, sterno-thyroid ; 1, upon the sterno-mastoid muscle, points by a line to the upper part of the common carotid artery ; 2, upon the scalenus anticus, points to the third part of the subclavian artery ; 3, upon the scalenus medius, points to the superficial cervical artery crossing the nerves of the brachial plexus ; 4, posterior scapular artery, passing under the levator scapulae muscle ; 5, supra-scapular artery ; 6, external carotid ; 6', internal carotid ; 7, upon the thyro-hyoid muscle, points to the superior thyroid artery giving superiorly its hyoid branch ; 8, lingual artery ; 9, placed on the stylo-hyoid muscle, indicates the facial artery ; 10, occipital artery, from the root of which the small sterno-mastoid artery is given off ; between the occipital and the facial arteries, +, upon the posterior belly of the digastric, points to the continuation of the external carotid before it passes under that muscle.

eye. From their destination, these divisions are

named respectively the *external* and *internal carotid arteries*.

The place of division of the common carotid artery is usually opposite the fourth cervical vertebra, and a little higher on the right side than on the left : it is as a rule higher in short-necked, and lower in long-necked persons. The length of the right artery is commonly from  $3\frac{1}{2}$  to 4 inches, of the left about an inch more.

The oblique course taken by the common carotid artery along the side of the neck is indicated by a line drawn from the sterno-clavicular articulation to a point midway between the angle of the jaw and the mastoid process of the temporal bone. At the root of the neck, the arteries of opposite sides are separated from each other only by a narrow interval, corresponding with the width of the trachea ; but, as they ascend, they are separated by a much larger interval, corresponding with the breadth of the larynx and pharynx. The carotid arteries have the appearance of being placed farther back at the upper than at the lower part of the neck, owing to the forward projection of the larynx above.



The common carotid artery is enclosed, together with the internal jugular vein and the pneumo-gastric nerve, in a common sheath, which is continuous with the deep cervical fascia (fig. 276, p. 297); the nerve, artery and vein have each, however, a separate investment of connective tissue within the sheath. The artery is deeply placed at the lower part of the neck, but is comparatively superficial towards its upper end. It is covered below by the sterno-mastoid, sterno-hyoid, and sterno-thyroid muscles, in addition to the platysma and the layers of fascia between and beneath the muscles; and it is crossed opposite or near the lower margin of the cricoid cartilage by the omo-hyoid muscle. From this point upwards to its bifurcation, the vessel is covered by the common integument, the platysma and fascia, and in the natural condition of the parts also by the sterno-mastoid; but in the dissected subject, in consequence of the retraction of this muscle when the fascia is removed, the upper portion of the artery is exposed in a triangular space, the sides of which are formed by the posterior belly of the digastric, the anterior belly of the omo-hyoid, and the sterno-mastoid muscles, and which is known as the *carotid triangle*. In this space the artery is crossed by the small sterno-mastoid branch of the superior thyroid artery.

Posteriorly, the artery rests against the longus colli and scalenus anticus muscles, which intervene between it and the transverse processes of the vertebræ. The inferior thyroid artery crosses behind the carotid sheath.

Internally, the vessel is in relation with the trachea, the thyroid body (which commonly overlaps the artery), the larynx, the œsophagus, and the pharynx. On the inner side of the point of division of the artery, and closely united to its wall, is placed the small vascular body known as the carotid gland (see Vol. I, p. 371).

*Relation to veins.*—The *internal jugular vein* is close to the artery at the upper part of the neck, but, on approaching the thorax, the two are separated on the right side by an angular interval, in which the commencement of the subclavian artery and the pneumo-gastric nerve are exposed; on the left side, the vein is usually nearer to the artery, and may even overlap it at the lower part of the neck.

Crossing over the upper part of the common carotid artery to join the jugular vein, is the *superior thyroid vein*, often double, and occasionally forming a sort of plexus over the artery. A *middle thyroid vein* frequently crosses the artery about half-way up the neck; and the *anterior jugular vein*, as it turns outwards under the sterno-mastoid, crosses the lower part of the artery, but is separated from it by the sterno-hyoid and sterno-thyroid muscles. There is also in many cases a *communicating branch*, sometimes of large size, between the facial and anterior jugular veins, which descends obliquely over the front of the artery, lying along the anterior border of the sterno-mastoid.

*Relation to nerves.*—The *descending branch of the hypoglossal nerve* passes down on the surface of the artery, crossing it very gradually from the outer to the inner side; and this nerve, together with the branches of the cervical nerves which join it, may be placed either within or on the front of the carotid sheath. The *pneumo-gastric nerve* lies within the sheath of the vessels between the artery and vein posteriorly. The *sympathetic nerve* is placed along the back of the sheath, between it and the prevertebral muscles, and the *recurrent laryngeal nerve* crosses upwards and inwards behind the lower part of the sheath.

The common carotid artery usually gives off no branch, except minute twigs to its areolar sheath and to the carotid gland, and therefore continues of equal size throughout its course until close to its bifurcation, where a slight dilatation is observable.<sup>1</sup>

<sup>1</sup> According to the measurements of Stahel the artery is largest at its commencement; it diminishes slightly to the middle of its length, and again enlarges towards the distal end (Arch. f. Anat., 1886).

**Varieties.**—*Origin.*—The *right carotid artery* occasionally arises directly from the aorta, either alone or in conjunction with the left carotid; and in the latter case it has been seen beginning on the left of the middle line, and crossing the front of the trachea above the upper border of the sternum to gain its usual position on the right side. When it arises from the aorta, it is usually the first large vessel from the arch, the subclavian being displaced; but it has been found to occupy the second place,—the right subclavian or, in cases of a right aortic arch, the left carotid being the first.

The place at which the right carotid artery commences varies with the point of bifurcation of the innominate artery. A change from the usual position on a level with the upper border of the clavicle was found by R. Quain in the proportion of about one case in eight and a half of those observed by him; and it was found to occur somewhat more frequently below than above that point.

The *left carotid artery* varies in its origin much more frequently than the right. In the greater number of its deviations from the ordinary place of origin, this artery arises from, or in conjunction with, the innominate artery; and in those cases in which the right subclavian is a separate branch of the aorta, the two carotids most frequently arise by a common trunk.

In cases of transposition, or of right aortic arch without other abnormality, the left common carotid springs from a left innominate artery, which is the first vessel to arise from the arch, and the right carotid is the second vessel.

*Place of division.*—This often deviates somewhat from its usual position; it does so more frequently in an upward than in a downward direction. It is often as high as the hyoid bone, and occasionally much higher. It is found occasionally opposite the middle of the larynx, and, in rare instances, opposite the lower margin of the cricoid cartilage, or even lower. One case was observed by Morgagni, in which the carotid artery, measuring one inch and a half in length, divided at the root of the neck. The carotid artery has been found, as a very rare occurrence, to ascend in the neck without dividing into the two usual branches; either the external or the internal carotid being altogether wanting.

In a few recorded cases there was no common carotid artery, the external and internal carotids arising directly from the arch of the aorta (Malacarne, *v.* p. 386; Power, Macalister, on right side; Gottschau, on left side), or from the termination of the innominate artery (Kosinski).

*Relation to nerves.*—The pneumo-gastric nerve has been observed to descend in front of the artery.

*Occasional branches.*—The common carotid artery sometimes gives origin at its upper end to the superior thyroid or ascending pharyngeal artery. In rarer cases it furnishes a laryngeal, or an inferior or accessory thyroid branch, or from its lower part the vertebral artery.

#### SURGICAL ANATOMY OF THE COMMON CAROTID ARTERY.

As the common carotid does not in ordinary cases furnish any branch, a ligature may be applied to any part of the vessel except close to its commencement or termination. It is usually tied either immediately above or below the omo-hyoid muscle, the former situation being preferred if possible, since the artery is here more superficial, and the operation is consequently free from the difficulties caused by the muscles lower down. An incision is made along the anterior border of the sterno-mastoid muscle, through the integuments and fascia, and in doing this the communicating vein above referred to (p. 391), if present, must be avoided, or it may if necessary be secured with two ligatures and then divided. The small branch of the superior thyroid artery to the sterno-mastoid muscle will also probably be cut. The sterno-mastoid is next everted, and the anterior belly of the omo-hyoid displayed and drawn inwards and downwards. The sheath is now exposed and is to be opened over the artery near the trachea, in order to avoid the internal jugular vein. The special sheath is next to be separated from the artery, and the aneurism needle should be passed from the outer side, for thus the vein and the pneumo-gastric nerve will be most effectually avoided. In opening the sheath the possible occurrence of a middle thyroid vein, crossing the artery at the level of the cricoid cartilage, should be borne in mind, and the descending branch of the hypoglossal nerve, if it comes into view, must be carefully preserved. Should the jugular vein overlap the artery, as it sometimes does, especially at the lower part of the neck on the left side, it will be a source of much difficulty in completing the operation, and great caution will be required in passing the needle round the artery. If the operation is performed at the lower part of the neck, some fibres of the muscles will require to be cut across in order to lay the artery bare with facility; and the necessity for this step increases in approaching the clavicle. Near the clavicle also the transverse lower portion of the anterior jugular vein crosses the line of the incision.

*Collateral circulation.*—After ligature of the common carotid trunk the blood is conveyed to

the cerebral and ophthalmic branches of the internal carotid from the vertebral arteries and the internal carotid of the opposite side, by means of the free communications existing between these vessels in the circle of Willis. The branches of the external carotid receive blood from the subclavian artery through the anastomoses of the superior and inferior thyroid arteries, and of the occipital with the ascending cervical, vertebral, and deep cervical arteries, and from the external carotid of the opposite side through the anastomoses of the two superior thyroid, lingual, facial, superficial temporal, and occipital arteries.

#### EXTERNAL CAROTID ARTERY (II).

**POSITION AND RELATIONS.**—The external carotid artery, distributed mainly to the face and to the walls of the cranium, is smaller than the internal in young persons; but the two are nearly of equal size in adults. It reaches from the point of division of the common carotid, opposite or a little above the upper margin of the thyroid cartilage, nearly to the neck of the lower jaw, where it divides into its two terminal branches, the superficial temporal and the internal maxillary. It is about  $2\frac{1}{2}$  inches long, and diminishes rapidly as it ascends, owing to the number and size of the branches which spring from it.

At first the external carotid lies in front of and somewhat nearer the median plane than the internal carotid; but it soon becomes superficial to that artery, inclining slightly backwards as it ascends to its place of division. In its lower part the artery is covered by the platysma myoides and the fascia, and in the natural condition of the parts it is overlapped by the sterno-mastoid (*cf.* p. 391); in its upper part it is deeply placed, passing first beneath the stylo-hyoid and digastric muscles, and finally becoming embedded in the substance of the parotid gland. At its commencement it is in contact with the pharynx and hyoid bone; farther up it is separated by a portion of the parotid gland from the back of the ramus of the lower jaw and the stylo-maxillary ligament, and rests upon the styloid process and the stylo-pharyngeus muscle, which, with the glosso-pharyngeal nerve, are interposed between it and the internal carotid artery.

**Relation to veins.**—This artery has usually no companion vein, but in the parotid gland the *temporo-maxillary* trunk is superficial to it, and the anterior division of this, passing down to join the facial vein, is sometimes placed with the artery beneath the digastric muscle; below the digastric it is crossed by the *facial* and *lingual veins* as they pass backwards to open into the internal jugular.

**Relation to nerves.**—Close to the lower border of the digastric muscle the external carotid artery is crossed by the *hypoglossal nerve*, and at a short distance from its upper end, in the substance of the parotid gland, by the *facial nerve*. The *glosso-pharyngeal nerve* lies between it and the internal carotid; and the *superior* and *external laryngeal nerves* are on the inner side of both vessels.

**BRANCHES.**—The branches of the external carotid artery are eight in number, viz., three directed forwards, the superior thyroid, the lingual, and the facial; two directed backwards, the occipital and posterior auricular; one on the inner side, the ascending pharyngeal; and the superficial temporal and internal maxillary, the two terminal branches into which the trunk divides.

In addition to the principal branches here enumerated, the external carotid gives off small offsets to the parotid gland, and to the masseter and internal pterygoid muscles.

**Varieties.**—The peculiarities in the origin of this vessel have been noticed along with the varieties of the common carotid artery. Absence of the external carotid artery has been met with in some rare cases, the several branches arising at intervals from a single trunk which represented the common and internal carotids. The branches are not unfrequently crowded together on the main stem, near the commencement, or at a higher point. Occasionally they take origin at regular distances in the whole length of the vessel. The usual number of branches may be diminished by the origin from another artery of one of the ordinary branches,

or by the union into a single trunk of two or three branches which are usually derived separately from the main artery: so also the number may be augmented by the transfer to this vessel of some branch not ordinarily derived from it, or by the addition of some unusual branch. The most frequent of these are an artery to the sterno-mastoid, generally derived from the occipital, the *inferior palatine* from the facial, and the *transverse facial* from the temporal, all of which are sometimes enumerated among the primary branches of the external carotid. In a few instances the trunk has been seen dividing about the level of the angle of the jaw into two parts which join again above, thus completing a loop.

#### BRANCHES OF THE EXTERNAL CAROTID ARTERY.

**1. Superior thyroid artery (iv).**—This, the first of the anterior set of branches, is given off close to the commencement of the external carotid, immediately below the great cornu of the hyoid bone. From this point the artery curves for-

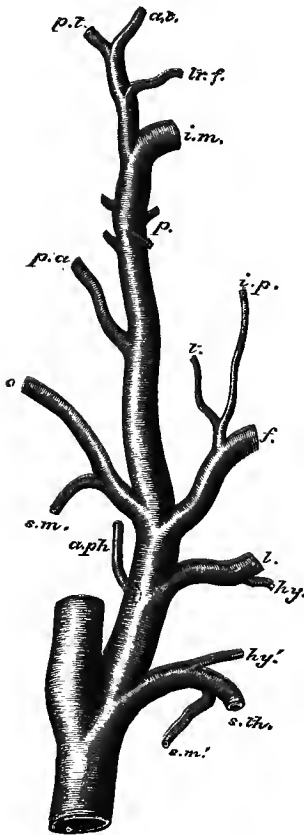


Fig. 337.—ORIGIN OF THE BRANCHES OF THE EXTERNAL CAROTID ARTERY: THE AVERAGE OF 121 DISSECTIONS (after Wyeth). (G. D. T.) Natural size.

*s. th.*, superior thyroid artery; *hy'*, its hyoid; *s. m'*, its sterno-mastoid branch; *l.*, lingual artery; *hy*, its hyoid branch; *f.*, facial artery; *t.*, its tonsillar, and *i. p.*, its inferior palatine branch, arising in common; *a. ph.*, ascending pharyngeal artery; *o.*, occipital artery; *s. m.*, its sterno-mastoid branch; *p. a.*, posterior auricular artery; *p.*, parotid and muscular branches; *i. m.*, internal maxillary artery; *tr. f.*, transverse facial artery; *a. t.*, anterior, and *p. t.*, posterior branch of the superficial temporal artery.

wards and downwards, and then descends for a short distance beneath the omo-hyoid, sterno-hyoid, and sterno-thyroid muscles, to all of which it furnishes offsets. At the apex of the lateral lobe of the thyroid gland it divides into branches which supply the upper part of that body, and anastomose with one another and with branches of the inferior thyroid artery. Its terminal distribution takes place generally by three branches, a *posterior*, an *external*, and an *anterior*, the last of which is the largest and most constant, and descends along the inner side of the lobe to the upper border of the isthmus, where it may form an arch with the opposite vessel: communications between the right and left arteries are however as a rule scanty.

*Branches.*—Besides the branches to the muscles which cover it, to the inferior constrictor of the pharynx, and to the thyroid body, the superior thyroid furnishes the following offsets:—

(a) The *hyoid*, a small branch, running transversely inwards immediately below the hyoid bone, and supplying the soft parts in the neighbourhood. It sometimes unites with its fellow of the opposite side.

(b) A *superficial descending* or *sterno-mastoid* branch, which passes downwards and backwards over the sheath of the carotid vessels, and ramifies in the sterno-mastoid muscle, as well as in the platysma and neighbouring integument.

(c) The *laryngeal* branch, or *superior laryngeal artery* (v), proceeding inwards beneath the thyro-hyoid muscle in company with the superior laryngeal nerve, and

piercing the thyro-hyoid membrane. On reaching the interior of the larynx, it ramifies in the muscles, the glands, and the mucous membrane of that organ.

(d) The *crico-thyroid* (vi), a small branch which crosses the membrane in the interval between the thyroid and cricoid cartilages, and forms an arch with the branch of the opposite side. It supplies the crico-thyroid muscle, and gives twigs through the crico-thyroid membrane to the interior of the larynx. This vessel may be a source of hæmorrhage in the operation of laryngotomy.

**Varieties.**—*Size.*—The superior thyroid artery is frequently larger or smaller than usual. In either case the deviation from the accustomed size is accompanied by an opposite alteration in other thyroid arteries. It has been seen extremely small, ending in branches to the sterno-mastoid muscle and the larynx: total absence on one side has also been recorded. (See the observations on the inferior thyroid artery.)

*Origin.*—The superior thyroid is often transferred to the upper part of the common carotid artery; and it is occasionally conjoined with the lingual branch, or with that and the facial branch of the external carotid.

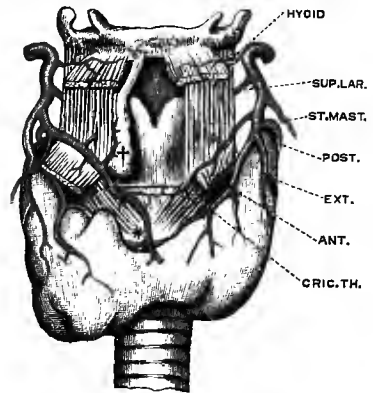
There are sometimes two superior thyroid arteries.

*Branches.*—The *hyoid* branch is frequently very small, or absent. The *laryngeal* branch often arises directly from the external carotid artery, rarely from the common carotid.

Fig. 338.—RAMIFICATION OF THE SUPERIOR THYROID ARTERY. (Modified from Streckeisen.) (G. D. T.)

\*, on the cricoid cartilage, occasional branch to isthmus of thyroid body; †, an accessory thyroid gland, resting on the thyroid cartilage.

Examples have occurred of this branch being of very large size, and terminating in the thyroid body. The laryngeal artery occasionally enters the larynx through a foramen in the thyroid cartilage, and it has also been observed to pass inwards below the cartilage. The *crico-thyroid artery* is sometimes of considerable size. A large branch often descends over the crico-thyroid membrane and the cricoid cartilage to the isthmus of the thyroid body (fig. 338). (A. Streckeisen, on the thyroid arteries in "Beiträge zur Morphologie der Schilddrüse," Virchow's Archiv, ciii, 1836.)



**2. Lingual artery (iv).**—The lingual artery (fig. 341, p. 402) arises from the fore part of the external carotid, between the superior thyroid and facial arteries, and generally opposite the great cornu of the hyoid bone. From its origin it first ascends for a short distance, and then bends sharply downwards, forming a loop which is crossed by the hypoglossal nerve. Disappearing beneath the digastric and stylo-hyoid muscles, it proceeds forwards along the upper border of the great cornu of the hyoid bone, and under cover of the hyo-glossus, to near the anterior border of that muscle; it there ascends almost perpendicularly to the under surface of the tongue, along which it is continued forwards to the tip, receiving the name of the *ranine artery*. The lingual artery lies upon the middle constrictor of the pharynx and the genio-glossus muscle; and the hypoglossal nerve, which courses forwards on the outer surface of the hyo-glossus, is placed above the level of the artery, except at the anterior border of the muscle, where the artery ascends and issues above the position of the nerve.

*Branches.*—(a) The *hyoid* branch runs along the upper border of the hyoid bone, and supplies the contiguous muscles and skin, anastomosing with the artery of the opposite side, and with the hyoid branch of the superior thyroid artery.

(b) The *dorsal artery of the tongue* arises beneath the hyo-glossus muscle, and ascends to supply the mucous membrane of the dorsum, and the substance of the tongue, as well as the tonsil, ramifying as far back as the epiglottis, and communi-

cating around the foramen cæcum with the corresponding branch of the opposite side. It is often replaced by several smaller offsets.

(c) The *sublingual* branch takes origin at the anterior margin of the hyo-glossus, and runs forwards between the genio-glossus muscle and the sublingual gland. It supplies the substance of the gland, and gives branches to the mylo-hyoid and other muscles connected with the lower jaw. Small branches are also distributed to the mucous membrane of the mouth and the inside of the gum, and a considerable offset anastomoses across the middle line with the artery of the other side.

(d) The *ranine artery* passes forwards with a tortuous course, giving numerous branches as it proceeds, and being for the most part embedded in the substance of the tongue between the genio-glossus and inferior lingualis muscles. Near the tip of the tongue it communicates with the opposite ranine artery in a small loop (Krause), but with this exception the right and left arteries do not form other than capillary anastomoses. In the last part of its course the ranine artery lies quite superficially, at the side of the frænum.

**Varieties.**—The lingual artery is often united at its origin with the facial; less frequently with the superior thyroid; and the three vessels occasionally arise by a common trunk. Instead of passing beneath the hinder border of the hyo-glossus, the artery sometimes pierces the origin of the muscle. The lingual artery has been seen replaced entirely or in large part by a branch of the internal maxillary, or of the submental branch of the facial. The *hyoid* branch is often absent; and it appears that this branch varies in size inversely with the hyoid branch of the superior thyroid artery. The *sublingual* branch is sometimes derived from the facial artery, and then perforates the mylo-hyoid muscle. The lingual artery has been observed to give off, as unusual branches, the superior laryngeal, the submental, and the ascending palatine.

**Surgical anatomy.**—The lingual artery may be tied either in the carotid triangle, before it passes under the digastric muscle, or farther forwards, while it is beneath the hyo-glossus; preferably in the latter situation, since its place of origin is subject to variation and its relation to the tip of the great cornu of the hyoid bone is therefore not constant. To reach the artery in the submaxillary triangle, a curved incision, reaching from a point a little outside the symphysis nearly to the angle of the lower jaw and descending in the middle to the hyoid bone, is made through the integuments, the platysma and the deep fascia, and the submaxillary gland is drawn upwards, when the intermediate tendon of the digastric is brought into view, together with portions of its two bellies, and the lower end of the stylo-hyoid muscle. Crossing the angle formed by the two bellies of the digastric the hypoglossal nerve is seen, accompanied by the ranine vein and passing forwards beneath the hinder border of the mylo-hyoid; and some fibres of the last muscle may be cut if necessary. By then dividing carefully the hyo-glossus muscle in the interval between the hypoglossal nerve and the tendon of the digastric the lingual artery is exposed and may be secured. The facial vein is frequently seen in the posterior angle of the wound, and may be injured if the primary incision is made too freely.

**3. Facial artery (iv).**—The facial artery (external maxillary), taking origin a little above the lingual, is at first directed upwards, beneath the digastric and stylo-hyoid muscles, and enters the hinder part of the submaxillary triangle; it then runs horizontally forwards under cover of the base of the lower jaw, resting on the mylo-hyoid muscle, and being lodged in a groove on the deep surface of the submaxillary gland. Emerging from beneath the gland, it turns sharply upwards and crosses the base of the jaw immediately in front of the masseter, being covered only by the platysma and the integuments: here the pulsation of the artery is easily felt, and the circulation through it may be controlled by pressure against the bone; at this point also the vessel may be readily ligatured.

On the side of the face the artery ascends obliquely, passing near the angle of the mouth and by the side of the nose, to the inner canthus of the eye, where it ends by inosculating with the nasal branch of the ophthalmic artery. In this part of its course the artery is exceedingly tortuous, a circumstance connected with the great mobility of the parts on which it rests. It is crossed by the risorius and the zygomaticus major muscles; it lies upon the buccinator, the levator anguli oris

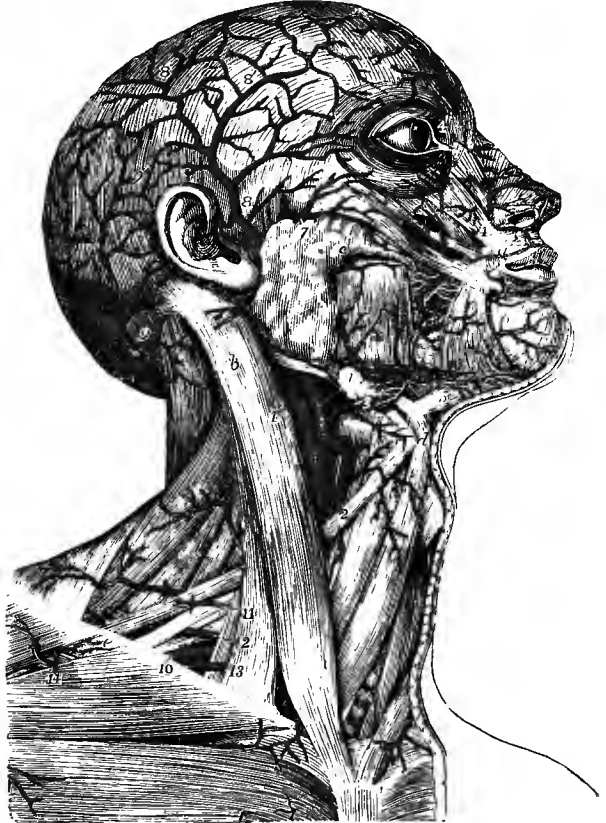and the levator labii superioris (sometimes under the last muscle); and near its ending it is embedded in the fibres of the levator labii superioris *alæque nasi*.

The *facial vein* is to the outer side of the artery and separated from it by a considerable interval in the face; at the base of the jaw the vein is close to the artery; and in the neck the vein is more superficial, being separated from the artery by the submaxillary gland.

Branches of the *facial nerve* cross the vessel; and the *infraorbital nerve* is beneath it, separated by the fibres of the elevator of the upper lip.

Fig. 339.—SUPERFICIAL VIEW OF THE ARTERIES OF THE HEAD AND NECK. (Tiedemann.)  $\frac{1}{2}$

*a*, orbicularis oris; *b*, sterno-mastoid; *c*, parotid gland near its duct; *d*, hyoid bone; *e*, clavicle; 1, trunk of common carotid artery near its division into external and internal carotids; 1', internal carotid; 2, placed on the anterior belly of the omo-hyoid muscle, points to the superior thyroid artery; 3, lingual artery and its hyoid branch; 4, placed on the submaxillary gland at the place where the facial artery sinks beneath it, and again where the artery turns over the lower jaw; 4', termination of the facial artery by division into the angular and lateral nasal branches; 4'', is between the frontal and nasal branches of the ophthalmic artery; 5, submental branch of the facial artery; 6, inferior labial branch; 7, transverse facial artery; 8, superficial temporal artery, passing over the zygoma and distributed by 8', 8', its anterior and posterior divisions on the surface of the cranium; 9, occipital artery; 9', its distribution and anastomoses with the superficial temporal and posterior auricular arteries; 10, third part of the subclavian artery; 11, superficial cervical, and 12, posterior scapular arteries; 13, suprascapular artery; 14, acromio-thoracic branch of the axillary artery.



**A. Cervical branches.**—The following branches are derived from the facial artery below the jaw:—

(a) The *inferior* or *ascending palatine artery*, a considerable branch, ascends between the stylo-glossus and stylo-pharyngeus muscles, and then between the internal pterygoid and the wall of the pharynx, to near the base of the skull, giving small branches to the surrounding muscles, to the tonsil, and to the Eustachian tube. Meeting the levator palati, it turns downwards and passes with that muscle above the upper border of the superior constrictor into the soft palate, where it is distributed to the mucous membrane, the glands, and the muscles, and anastomoses with the artery of the opposite side. The place of this artery in the palate is frequently taken by the ascending pharyngeal.

(b) The *tonsillar* branch ascends on the outer side of the stylo-glossus muscle, and, penetrating the superior constrictor of the pharynx, terminates in small vessels upon the tonsil and the side of the tongue near its root. This branch is often represented by one or more twigs from the inferior palatine artery.

(c) The *glandular* branches are several short vessels which enter the substance of the submaxillary gland, while the facial artery is in contact with it. Small *muscular* twigs are also furnished from this part of the artery to the stylo-hyoid, internal pterygoid, and masseter.

(d) The *submental* branch is the largest arising from the facial in the neck. Leaving the artery just before it turns upwards to the face, this branch runs forwards below the base of the jaw, on the surface of the mylo-hyoid muscle, and gives branches to the surrounding muscles and the integuments, as well as others which perforate the mylo-hyoid to anastomose with the sublingual artery. Much diminished in size it turns over the border of the jaw near the symphysis, and terminates in branches to the depressor labii inferioris and levator menti muscles, and the other structures of the chin and lower lip, forming anastomoses with the inferior labial and mental arteries, and with the corresponding branch of the opposite side.

*B. Facial branches.*—From the outer side of the artery in its facial portion small offsets proceed which are distributed to the muscles—masseter, buccinator, &c., and anastomose with the transverse facial, buccal, and infraorbital arteries. The larger branches are directed inwards, and are as follows:—

(a) The *inferior labial* branch arises soon after the facial artery has turned over the lower border of the mandible, and, running forwards beneath the depressor anguli oris, distributes branches to the skin and muscles of the lower lip, anastomosing with the inferior coronary, submental, and mental arteries. This is frequently an offset of the following branch.

(b) The *coronary artery of the lower lip* (v). Arising at the outer border of the depressor anguli oris, this branch takes a transverse and tortuous course beneath that muscle, and between the orbicularis oris and the mucous membrane near the free margin of the lip, and inosculates with the corresponding artery of the opposite side. Small twigs from it supply the orbicular and depressor muscles, the glands, and other structures of the lower lip; and some descend towards the chin to communicate there with other branches.

(c) The *coronary artery of the upper lip* (v) arises beneath the zygomaticus major muscle. It runs across between the muscle and mucous membrane of the upper lip, and inosculates with its fellow of the opposite side. In addition to supplying the whole thickness of the upper lip, it gives two or three small branches to the nose. One of these, named the *artery of the septum narium*, runs along the border of the columna nasi, on which it ramifies as far as the point of the nose.

(d) The *lateral nasal artery*, often replaced by two or three smaller branches, turns inwards to the side of the nose, over which it ramifies, sending offsets to the ala and the dorsum. It anastomoses with the nasal branch of the ophthalmic, with the artery of the septum, and with the corresponding artery of the opposite side.

(e) *Angular artery.*—Under this name is recognised the slender terminal part of the facial artery, which inosculates at the inner side of the orbit with the nasal branch of the ophthalmic artery.

*Varieties.*—*Origin and course.*—The facial artery frequently arises by a common trunk with the lingual. Occasionally it arises above its usual position, and then descends beneath the angle of the jaw to assume its ordinary course. The arch formed by the facial artery above the submaxillary gland often extends upwards (especially in old persons) for some distance beneath the ramus of the jaw, lying between the internal pterygoid and stylo-glossus muscles.



*Size.*—This artery varies much in size, and in the extent of its distribution. It has been observed, very rarely however, to end as the submental, not reaching the side of the face: in some cases it supplies the face only as high as the lower lip; and it often fails to supply the lateral nasal and angular branches. The deficiency of the facial artery is most frequently compensated for by an enlargement of the nasal branch of the ophthalmic at the inner side of the orbit; occasionally by branches from the transverse facial, or internal maxillary artery. As a rare occurrence it has been found larger than usual, and replacing the nasal and frontal branches of the ophthalmic.

*Branches.*—The *ascending palatine artery* is in some instances transferred to the external carotid. This branch varies in size and the extent to which it reaches. Not unfrequently it is expended without furnishing any branch to the soft palate. When it is thus reduced in size, the pharyngeal artery takes its place in the soft palate. The *submental* branch has been observed to take its rise from the sublingual artery. On the other hand, the facial artery, instead of the lingual, sometimes furnishes the branch which supplies the sublingual gland. The two *coronary arteries* sometimes arise by a common trunk; and one or other of these vessels may be smaller than usual, the corresponding artery of the opposite side being enlarged and supplying the deficiency.

**4. Occipital artery (iv).**—The occipital artery, arising from the posterior part of the external carotid, usually opposite the facial or a little higher up, is directed upwards and backwards, beneath the posterior belly of the digastric muscle, to the interval between the transverse process of the atlas and the mastoid process of the temporal bone. Here it turns backwards along the skull, lying in the occipital groove of the temporal bone, internal to the mastoid process and the sterno-mastoid, splenius, trachelo-mastoid and digastric muscles, and resting on the rectus lateralis, obliquus superior, and complexus. Lastly, issuing between the cranial attachments of the sterno-mastoid and trapezius, it ascends beneath the integument on the back of the head, accompanied by the great occipital nerve, and divides into branches, which are distributed upon the upper and back part of the cranium. While in the neck, the occipital artery crosses over the internal carotid artery, the pneumo-gastric and spinal accessory nerves, and the internal jugular vein; and the hypoglossal nerve winds from behind forwards over it at its origin.

*Branches.*—(a) Small *muscular* offsets to the digastric, stylo-hyoid, splenius, and trachelo-mastoid muscles, and one of larger size to the sterno-mastoid. This *sterno-mastoid* branch is very constant: arising generally from the occipital artery close to its commencement, but not unfrequently from the trunk of the external carotid, it turns downwards over the loop formed by the hypoglossal nerve, and enters the muscle in company with the spinal accessory nerve.

(b) A small twig, the *mastoid* branch, enters the skull through the mastoid foramen, and ramifies in the diploe and the dura mater.

(c) The *cervical* branch, *ramus cervicalis princeps*, is distributed to the muscles of the upper and back part of the neck. Descending a short way, this vessel divides into a superficial and a deep branch. The former ramifies beneath the splenius, sending offsets through that muscle to the trapezius; while the deep branch passes beneath the complexus, and anastomoses with branches of the vertebral artery, and with the deep cervical artery. The size of this branch varies much, and it is often represented by two or more smaller offsets.

(d) The *superficial* or *cranial* branches pursue a tortuous course between the integument and the occipito-frontalis muscle; and in proceeding upwards on the skull they separate into diverging branches, which anastomose freely with one another, as well as with the branches of the opposite artery, of the posterior auricular artery, and of the superficial temporal artery.

*Varieties.*—*Origin.*—The occipital artery is occasionally derived from the internal carotid, or from the ascending cervical branch of the inferior thyroid—an offset of the subclavian artery.

*Course.*—The occipital artery sometimes passes outside the trachelo-mastoid instead of internal to it. The chief portion of the vessel has been found to pass over the sterno-mastoid

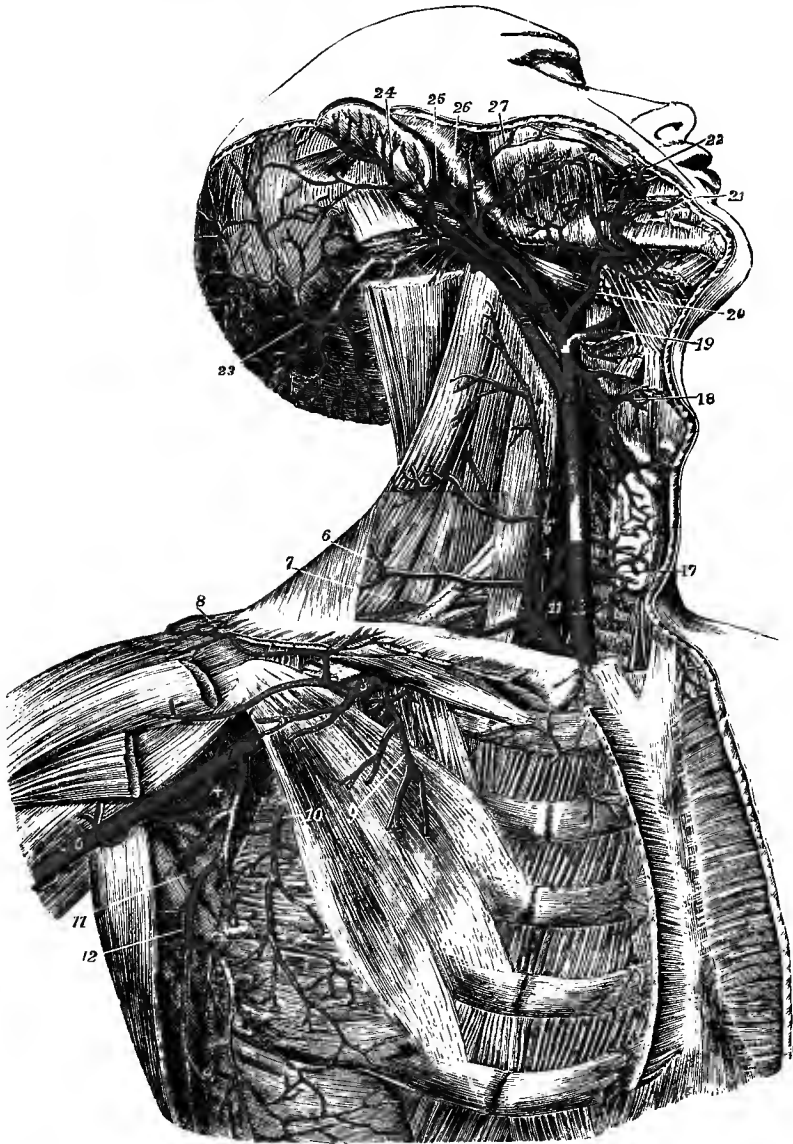

Fig. 340.—THE CAROTID, SUBCLAVIAN, AND AXILLARY ARTERIES. (Tiedemann.)  $\frac{1}{2}$

The great pectoral, the sterno-mastoid, and the sterno-hyoid and sterno-thyroid muscles have been removed; the front part of the deltoid has been divided near the clavicle; and the greater part of the digastric muscle has been removed, and the upper part of the splenius capitis and trachelo-mastoid divided near the mastoid process. For the explanation of the references from 1 to 12, see p. 433. 13, 14, common carotid artery; 15, external carotid; 16, internal carotid; 17, 17, inside the thyroid axis of the subclavian, and pointing to the inferior thyroid artery where it is distributed to the gland; 18, superior thyroid; 19, lingual artery, exposed by the removal of part of the hyo-glossus muscle; 20, facial artery, giving off the palatine, tonsillar and submental branches; 21, inferior, 22, superior coronary; 23, occipital; 24, posterior auricular; 25, superficial temporal; 26, internal maxillary; 27, transverse facial, in this instance double, and given off directly by the external carotid.

muscle, only a small artery being placed in the usual position. In a few instances the artery has been seen to turn backwards below the transverse process of the atlas.

*Branches.*—A *posterior meningeal* branch is sometimes given from the occipital artery,

ascending on the internal jugular vein, and passing through the jugular foramen to ramify in the dura mater of the posterior fossa of the base of the skull. The *parietal* branch is an occasional offset which springs from one of the terminal branches of the occipital artery, and enters the skull by the parietal foramen to be distributed to the surrounding dura mater. The occipital artery sometimes gives origin to the stylo-mastoid branch (normally an offset of the posterior auricular), to the posterior auricular artery, or to the ascending pharyngeal artery.

**5. Posterior auricular artery (v).**—The posterior auricular artery arises from the external carotid a little higher up than the occipital. It ascends under cover of the parotid gland, resting on the styloid process of the temporal bone and being crossed by the facial nerve, reaches the groove formed by the cartilage of the ear with the mastoid process, and there divides into two terminal branches, auricular and mastoid, which are distributed to the auricle and to the scalp behind and above the ear.

*Branches.*—(a) Small branches to the parotid gland, and to the digastric and styloid muscles.

(b) The *stylo-mastoid* branch, long and slender, enters the foramen of the same name in the temporal bone in company with the facial nerve. It sends small branches backwards to the mastoid cells, and others forwards to the stapedius muscle and the tympanum. One of the latter branches is constantly found in young subjects to form, with the tympanic branch of the internal maxillary artery, a vascular circle around the margin of the tympanic membrane, from which delicate offsets are distributed to that structure. The continuation of the stylo-mastoid branch is a minute twig which runs forwards in the aqueduct of Fallopius and anastomoses with the petrosal branch of the large middle meningeal artery. The stylo-mastoid branch frequently arises from the occipital artery.

(c) The *auricular* branch ascends behind the ear, passing beneath the retrahens auriculam which it supplies, and is expended mainly in offsets to the auricle, a small branch being prolonged to the integument of the hinder part of the temporal region, and anastomosing with the posterior branch of the superficial temporal artery. The offsets to the auricle are two or more in number; they supply the inner surface of the pinna, and to a great extent also the outer surface by means of branches which perforate the cartilage or turn over its margin.

(d) The *mastoid* or *occipital* branch is directed backwards over the insertion of the sterno-mastoid, supplies the occipitalis muscle and overlying integument, and anastomoses with the occipital artery.

*Varieties.*—The posterior auricular artery is frequently very small, and has been seen to end in the stylo-mastoid branch. On the other hand it may be larger than usual and compensate for a deficiency of the occipital or superficial temporal artery. It is often a branch of the occipital.

**6. Ascending pharyngeal artery (v).**—This artery, the smallest branch of the external carotid that has received a distinctive designation, is a long straight vessel which arises most commonly from half an inch to an inch above the beginning of the external carotid, and runs upwards to the base of the skull on the mesial side of the internal carotid artery, between that and the wall of the pharynx.

*Branches.*—These are numerous, but very small and inconstant in their arrangement. They may be divided as follows:—

(a) The *pharyngeal* branches pass inwards, for the most part to the pharynx. One or two small and variable branches ramify in the middle and inferior constrictor muscles, and anastomose with the superior thyroid artery. Higher up than these is a larger and more regular branch, which runs upon the upper constrictor, and sends small ramifications to the Eustachian tube, to the tensor and levator palati muscles, and to the tonsil.

The last mentioned, or *palatine*, branch is sometimes of considerable size, and supplies the soft palate, taking the place of the inferior palatine branch of the facial artery, which in such cases is small. It divides into an anterior and a posterior twig, both of which anastomose across the middle line with their fellows of the opposite side.

(b) The *prevertebral* branches, small and irregular, are distributed to the longus colli and recti antici muscles, to the upper cervical ganglion of the sympathetic nerve and some of the cranial nerves as they issue from the skull, and to lymphatic glands. Some of them anastomose with the ascending cervical branch of the sub-clavian artery.

(c) The *meningeal* branches are terminal twigs, which pass through the

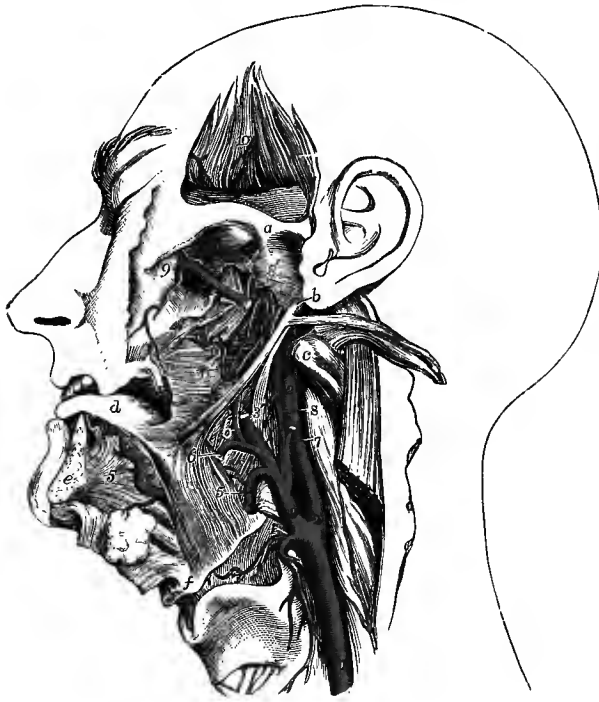

Fig. 341.—THE LINGUAL AND ASCENDING PHARYNGEAL ARTERIES. (R. Quain.)  $\frac{1}{3}$

The left half of the lower jaw has been removed, with the external and internal pterygoid muscles, and the temporal muscle has been turned up from within the zygoma. *a*, base of the zygoma, above the glenoid cavity; *b*, placed on the lobule of the ear, points by a line to the styloid process, from which the styloglossus and stylo-pharyngeus are seen passing downwards and forwards, while the stylohyoid, detached from the hyoid bone, is thrown backwards with the digastric muscle; *c*, transverse process of atlas; *d*, upper surface of tongue; *e*, sawn surface of lower jaw; *f*, hyoid bone; 1, common carotid artery; 2, internal carotid; 3, external carotid; 3', placed on the stylo-pharyngeus muscle, points by a line to the upper part of the external carotid, divided where it enters the parotid gland; 4, superior thyroid artery, its laryngeal branch passing upon the thyro-hyoid membrane; 5, lingual artery, about to pass

beneath the hyo-glossus; 5', placed on the genio-glossus, points to the continuation of the lingual artery as the ranine; 6, facial artery cut short; 6', its inferior palatine branch; 7, occipital artery cut short; 8, ascending pharyngeal artery; 8', its upper part turning down upon the pharynx; 9, internal maxillary artery as it passes into the spheno-maxillary fossa, and gives the posterior dental and the infraorbital arteries; 9', middle meningeal artery; 10, placed on the deep surface of the temporal muscle, which shows some cut branches of the deep temporal arteries.

foramen lacerum, jugular foramen, and anterior condylar foramen, to end in the dura mater.

(d) The *tympanic* branch is a minute twig accompanying the tympanic branch of the glosso-pharyngeal nerve to the inner wall of the tympanum.

**Varieties.**—This artery varies greatly in its place of origin from the external carotid. It sometimes springs from the occipital, from the internal carotid, or from the bifurcation of the common carotid artery. It is occasionally double, and in a few cases three arteries have been seen.

**7. Superficial temporal artery (iv).**—The superficial temporal artery, one of the terminal branches of the external carotid, continues upwards in the direction of

the main trunk, while the other branch (the internal maxillary) curves forwards under cover of the jaw. The temporal artery is at first embedded in the substance of the parotid gland, in the interval between the meatus of the ear and the condyle of the lower jaw. Thence it ascends over the posterior root of the zygoma, against which it may readily be compressed. From this point onwards, it lies close beneath the skin, upon the temporal fascia; and, a variable distance above the zygoma, it divides into two branches, which again subdivide and ramify beneath the integument on the side and upper part of the head.

*Branches.*—Besides several small offsets to the parotid gland, some branches to the articulation of the lower jaw, and one or two to the masseter muscle, the temporal artery gives off the following branches :—

(a) The *transverse facial artery* arises while the temporal artery is deeply seated in the parotid gland, beneath the anterior part of which it runs nearly horizontally forwards; placed above the parotid duct, it rests on the masseter muscle, and is accompanied by the infraorbital branches of the facial nerve. It gives small vessels to the parotid gland, the masseter muscle, and the neighbouring integument, and divides into three or four branches, which are distributed to the side of the face, anastomosing with the buccal, infraorbital and facial arteries.

(b) The *middle temporal artery* perforates the temporal fascia close above the zygoma and ascends in a slight groove on the squamous part of the temporal bone, giving branches to the temporal muscle, which communicate with the posterior deep temporal branch of the internal maxillary artery.

(c) The *anterior auricular* branches, two or more in number, *superior* and *inferior*, are distributed to the fore part of the pinna, the lobule of the ear, and a part of the external meatus, anastomosing with the ramifications of the posterior auricular artery.

(d) The *orbital* branch, sometimes arising from the middle temporal, runs forwards above the zygoma, and between the layers of the temporal fascia, to supply the outer part of the orbicularis palpebrarum muscle and the skin. This branch varies much in size, and it is not unfrequently absent.

(e) The *anterior temporal* branch is one of the two terminal branches of the temporal artery. This vessel inclines forwards as it ascends over the temporal fascia, and ramifies extensively upon the fore part of the head, supplying the orbicular and frontal muscles, the pericranium, and the skin, and communicating with the supraorbital and frontal branches of the ophthalmic artery, as well as with offsets of the posterior temporal branch. On the upper part of the cranium the branches of this artery are directed from before backwards.

(f) The *posterior temporal* branch, which is usually larger than the anterior, ascends on the side of the head, over the temporal fascia; its branches ramify freely in the coverings of the cranium, both upwards to the vertex, where they communicate with the corresponding vessel of the opposite side, and backwards to join with the occipital and posterior auricular arteries.

*Varieties.*—The terminal branches of the temporal artery are frequently very tortuous, especially in aged persons. The *anterior temporal* branch is sometimes larger than the posterior, and, passing backwards over the vertex of the head, communicates with the occipital. The *transverse facial artery* varies in size; occasionally it is much larger than usual, and takes the place of a defective facial artery. It is frequently double. In many instances the transverse artery arises directly from the external carotid (fig. 340). The *orbital* branch is sometimes of considerable size, and extends into the eyelids; it has been seen to communicate with the supraorbital artery and supply a large part of the forehead (Cruveilhier).

**8. Internal maxillary artery (iii).**—The internal maxillary or deep facial artery, the largest of the branches of the external carotid, is concealed by the

parotid gland at its origin below the condyle of the jaw. It runs with a tortuous course through the zygomatic fossa at the base of the skull, furnishing numerous branches to the walls of the cranium and the deep parts of the face; and for convenience of arrangement it is usually divided into three parts.

In the *first part* the artery is directed nearly horizontally forwards beneath the ramus of the jaw and along the lower border of the external pterygoid muscle, having to its inner side the internal lateral ligament of the temporo-maxillary articulation and the inferior dental nerve. It is accompanied by the internal maxillary vein, and the auriculo-temporal nerve is above the vessels. The *second part* courses obliquely upwards and forwards either on the outer or inner side of the lower head of the external pterygoid, in the former case being covered by the insertion of the temporal muscle; while if occupying the deeper position the vessel lies above the internal pterygoid muscle, crosses over the lingual nerve, and then emerges with the buccal nerve (which is above the artery) through the interval between the heads of the external pterygoid. In its *third part* the artery winds inwards over the back of the superior maxilla to the speno-maxillary fossa, where it ends close to the speno-palatine foramen, and just below the superior maxillary nerve, by dividing into its terminal branches—descending palatine, vidian, pterygo-palatine and nasal. The second and third parts of the artery are thickly surrounded by veins belonging to the pterygoid plexus.

*Branches.*—A. *Of the first part.*—(a) The *deep auricular* branch, of small size, and often arising in common with the next offset, perforates the anterior wall of the external auditory meatus, and supplies the skin and outer part of the tympanic membrane.

(b) The *tympanic* branch, also small and variable in its origin, enters the tympanum by the fissure of Glaser, and is distributed to the structures within that cavity and the tympanic membrane, anastomosing with the stylo-mastoid artery (see p. 401).

(c) The *middle or great meningeal artery* (v), the largest branch of the internal maxillary, passes directly upwards under cover of the external pterygoid muscle, between the two roots of the auriculo-temporal nerve, and enters the skull by the foramen spinosum of the sphenoid bone. Within the cranium, it ascends towards the anterior inferior angle of the parietal bone, and divides into two branches, which subdivide and ramify in deep arborescent grooves on the inner surface of the calvaria, passing upwards on the parietal bone as high as the vertex, forwards to the frontal bone, and backwards to the occipital bone.

Immediately on entering the cranium the meningeal artery gives offsets to the Gasserian ganglion and the surrounding dura mater, a small *petrosal* branch which enters the hiatus Fallopii and anastomoses with the stylo-mastoid branch of the posterior auricular artery, and minute *tympanic* twigs through the petro-squamous fissure. Higher up an *orbital* branch passes from the trunk, or its anterior division, to the outer end of the sphenoidal fissure, and communicates with the lachrymal artery of the ophthalmic.

(d) The *small meningeal artery*, usually arising from the preceding, ascends on the inner side of the inferior maxillary nerve, and enters the skull through the foramen ovale to supply the Gasserian ganglion and the dura mater in the middle fossa.

(e) The *inferior dental artery*, passing downwards, enters the dental canal with the inferior dental nerve, and subsequently escapes on the face by the mental foramen. As it enters the canal, it gives off the *mylo-hyoid* branch, which, with the nerve bearing the same name, runs in a groove on the inner surface of the jaw, below the dental foramen, and ramifies on the under surface of the mylo-hyoid muscle. In its course through the bone, the inferior dental artery gives off small

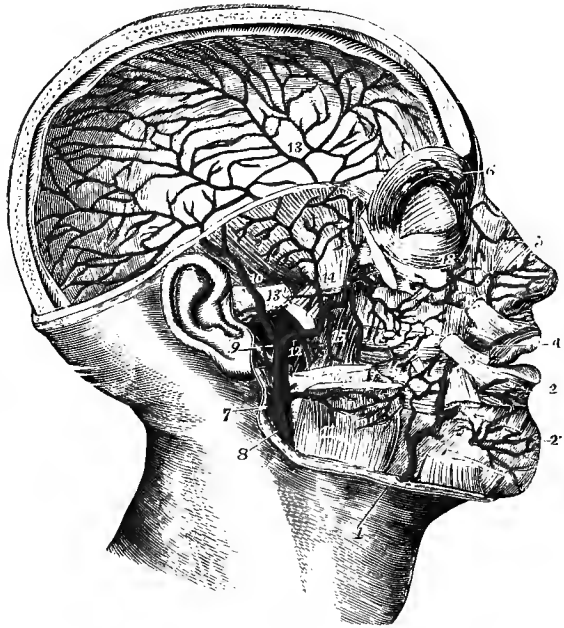
offsets, which ascend to enter the minute apertures in the extremities of the fangs of the teeth, and supply the pulp of each ; before emerging at the mental foramen, it sends forwards a branch which supplies the incisor teeth and communicates with its fellow of the opposite side. The terminal or *mental* branch anastomoses with the inferior coronary, inferior labial, and submental arteries.

(f) A small branch, arising either from the inferior dental artery or from the internal maxillary trunk, descends with the lingual nerve, and is distributed to the mucons membrane of the mouth.

B. *Of the second part.*—(a) The *anterior* and *posterior deep temporal* branches ascend to the temporal fossa, where they lie close to the bone and supply the temporal muscle. They anastomose together, the posterior also with the middle temporal artery, and the anterior with branches of the lachrymal artery through small

Fig. 342.—DEEP DISSECTION OF THE HEAD AND FACE, TO SHOW THE INTERNAL MAXILLARY ARTERY AND ITS BRANCHES. (Tiedemann.)  $\frac{1}{2}$

The right half of the calvaria, the zygomatic arch, and the upper half of the ramus of the lower jaw, with the external pterygoid muscle, have been removed ; some of the superficial muscles of the face have been divided, and the internal pterygoid and buccinator muscles are exposed. 1, facial artery, rising over the edge of the lower jaw ; 2, inferior coronary artery ; 2', mental branch of the inferior dental artery ; 3, facial artery continued ; 4, superior coronary ; 5, lateral nasal ; 6, frontal branch of the ophthalmic artery, from which the nasal artery is seen descending on the nose ; 7, internal carotid artery ; 8, external carotid ; 9, division of the external carotid into superficial temporal and internal maxillary arteries ; 10, superficial temporal ; 11, masseteric branch of the external carotid artery ; 12, internal maxillary artery, at the origin of its inferior dental branch ; 13, on the base of the zygoma, points to the origin of the middle meningeal branch, and on the dura mater above, to its distribution ; 14, on the lower part of the temporal muscle, is between the deep temporal branches of the artery ; 15, pterygoid branches ; 16, buccal artery ; 17, posterior dental, and deepest part of the internal maxillary artery where it enters the speno-maxillary fossa ; 18, infraorbital artery issuing upon the face.



foramina in the outer wall of the orbit. When the main artery passes beneath the external pterygoid, the posterior temporal branch arises from the first part in common with the inferior dental, and the anterior temporal is given off as the artery issues between the heads of the muscle.

(b) The *masseteric* is a small but regular branch which passes from within outwards, with the nerve of the same name, through the sigmoid notch of the lower jaw, to the deep surface of the masseter muscle. It is usually joined at its origin with the posterior temporal branch.

(c) The *pterygoid* branches, small, short offsets, irregular in number and origin, are distributed to the pterygoid muscles.

(d) The *buccal* branch runs obliquely downwards and forwards upon the

buccinator muscle with the buccal nerve; it is distributed to the muscles and mucous membrane of the cheek, and anastomoses with the branches of the facial and other arteries of this region.

C. *Of the third part.*—(a) The *posterior dental* or *alveolar* branch, arising near the back of the superior maxilla, frequently in common with the infra-orbital branch, runs tortuously downwards upon the zygomatic surface of the bone, and gives off branches which enter the posterior dental canals, and supply the upper molar and bicuspid teeth, besides ramifying in the lining membrane of the maxillary sinus. Other small branches supply the gum.

(b) The *infraorbital artery* runs horizontally forwards into the infraorbital canal, and having traversed that canal along with the superior maxillary nerve, emerges upon the face at the infraorbital foramen.

While in the canal, it sends upwards into the orbit small branches, which enter the inferior rectus and the inferior oblique muscles of the eye and the lachrymal gland, and an *anterior dental* branch (sometimes two) which descends in the canal of the same name to supply the front teeth and the mucous membrane of the antrum. On the face it gives branches upwards, to the lachrymal sac and inner angle of the orbit, anastomosing with branches of the ophthalmic and facial arteries, and sends other branches downwards, beneath the levator labii superioris, which join the ramifications of the transverse facial, buccal, and facial arteries.

(c) The *descending* or *superior palatine artery* descends through the posterior palatine canal, with the large palatine nerve, and runs along the hard palate, supplying the mucous membrane, the glands, and the gum. In front it ends in a small vessel which ascends through the incisor foramen, and anastomoses with the nasopalatine artery. On its way downwards, this artery sends off twigs through the smaller palatine canals, which are distributed to the soft palate and tonsil, and communicate with the ascending palatine branch of the facial artery.

(d) The *Vidian* branch traverses the Vidian canal with the nerve of the same name, and supplies the Eustachian tube, the levator palati muscle, and the upper and lateral part of the pharynx.

(e) The *pterygo-palatine*, a very small branch, passes backwards through the pterygo-palatine canal to reach the top of the pharynx, to which, and to the sphenoidal sinus, it is distributed.

(f) The *nasal* or *spheno-palatine* artery enters the nasal fossa by the spheno-palatine foramen, and divides into branches, some of which ramify extensively over the spongy bones, while others supply the ethmoidal cells, the frontal sinus, and the antrum. One long branch, the *naso-palatine artery* or *artery of the septum*, runs downwards and forwards in the groove on the vomer, and ends in a small vessel which enters the incisor foramen to communicate with the descending palatine artery.

**Varieties.**—The internal maxillary artery is very constant in its place of origin. It has, however, in several cases been seen to arise from the facial; and in two instances, after leaving the temporal artery below the angle of the jaw, it pierced the internal pterygoid muscle in its course upwards into the zygomatic fossa (Joessel, W. Gruber).

Out of 447 cases (arteries) examined the artery was found to be superficial to the external pterygoid in nearly 55 per cent., and deeper than the muscle in 45 per cent.; in three instances it pierced the lower head of the muscle; and in one it passed beneath the whole muscle and emerged between the upper head and the great wing of the sphenoid (J. J. Long). The disposition was in most cases the same on the two sides. When placed beneath the muscle the artery sometimes passed on the inner side also of the inferior dental and lingual nerves, less frequently between the two trunks, the dental being on the outer side of the vessel, and in five instances it pierced the inferior dental. (Report of Committee of Collective Investigation of Anat. Soc., by Arthur Thomson, Journ. Anat., xxv, 1890.)

The deep position of the artery is general among the lower mammals and would appear to be the primary one. When the artery is so placed in man, the common trunk by which the



inferior dental and posterior deep temporal arteries arise is often continued forwards over the external pterygoid by means of a muscular and anastomotic branch, to join the anterior deep temporal or buccal, thus affording an indication of the manner in which the superficial course has been acquired.

The number of branches arising from the internal maxillary artery is frequently reduced owing to two or more taking origin by a common trunk. The *middle meningeal artery* occasionally furnishes the lachrymal, or even the ophthalmic artery itself; and on the other hand the ophthalmic has been seen to give off the middle meningeal, peculiarities which may be explained as resulting from the enlargement of the ordinary anastomosing branch. The *anterior deep temporal artery* may reinforce or replace the lachrymal artery by a similar enlargement of an anastomosing branch. The *buccal, posterior dental, or infraorbital artery* may be larger than usual, supplying a deficiency of the facial artery.

### INTERNAL CAROTID ARTERY (II).

**COURSE AND RELATIONS.**—The internal carotid artery is distributed to the brain, to the eye with its appendages, and in part to the forehead and nose. It extends directly upwards from the termination of the common carotid artery, just above the thyroid cartilage, to the carotid canal of the temporal bone. Traversing this canal, it enters the cranial cavity by the inner part of the foramen lacerum, and then passes forwards in the carotid groove on the side of the body of the sphenoid bone, at the fore part of which it makes a sharp bend with its convexity directed forwards. Lastly, it turns upwards on the inner side of the anterior clinoid process to reach the *vallecula Sylvii* at the inner end of the Sylvian fissure of the brain, where it terminates by dividing into the anterior and middle cerebral arteries.

**IN THE NECK,** the internal carotid artery lies at first behind the external carotid, and is covered only by the sterno-mastoid muscle with the platysma myoides and fascia. It soon, however, passes beneath the digastric and stylo-hyoid muscles, gaining the inner side of the external carotid trunk, and is then deeply placed beneath the parotid gland, the styloid process and the stylo-pharyngeus muscle. Behind the artery are the vertebræ covered by the *rectus anticus major* muscle, and on its inner side is the pharynx. The *internal jugular vein* is in contact with the artery as far as the base of the skull, lying on its outer and posterior aspect, and the two are enclosed, together with the pneumo-gastric nerve, in a prolongation of the carotid sheath. The vessel is crossed by the *occipital artery* beneath the digastric, and by the *posterior auricular artery* above that muscle. The *pneumo-gastric nerve* and the *upper cervical ganglion of the sympathetic* are placed deeply behind the artery; the *hypoglossal nerve* crosses it superficially near the lower border of the digastric, and higher up the *glosso-pharyngeal nerve* and the *pharyngeal branch of the pneumo-gastric* pass forwards between the external and internal carotids; while the *superior and external laryngeal nerves* are internal to both vessels. Close to the base of the skull the *glosso-pharyngeal, pneumo-gastric, spinal accessory and hypoglossal nerves* issue between the artery and its companion vein.

**IN THE CAROTID CANAL,** the artery first ascends for a short distance, being placed immediately in front of the tympanum and the cochlea of the internal ear, and then passes horizontally forwards and inwards to the foramen lacerum, where it turns upwards in the groove of the sphenoid between the lingula and the petrosal process. It is here accompanied by the *ascending branch of the upper cervical ganglion of the sympathetic*, and surrounded by a venous plexus. The bend formed by the artery within the carotid canal is crossed on the outer side by the Eustachian tube; and not unfrequently it extends backwards beneath the lower and fore part of the inner wall of the tympanum, being separated from that cavity only by a thin plate of bone, which may even be deficient in part.<sup>1</sup> Farther forwards, the Gasserian ganglion lies

<sup>1</sup> W. Anderson, "The Relation of the Internal Carotid Artery to the Inner Wall of the Tympanum," St. Thomas's Hospital Reports, xix.

immediately over the horizontal part of the canal, the roof of which is usually formed for a considerable part of its extent only by fibrous membrane, so that the ganglion comes into close relation with the artery.

WITHIN THE CRANIUM, the internal carotid artery lies in the cavernous sinus as it passes forwards on the side of the body of the sphenoid; it is surrounded by filaments of the *sympathetic*, the *sixth nerve* is in contact with its outer side, and it receives, in company with these nerves, an investment from the thin lining membrane of the sinus. Perforating the upper wall of the sinus on the inner side of the anterior clinoid process, the artery ascends between the *second* and *third nerves* to the anterior perforated spot at the base of the brain, where it divides into its two terminal branches.

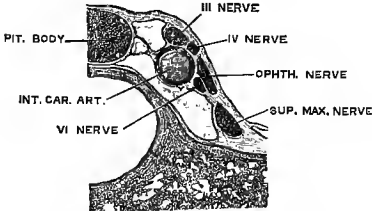


Fig. 343.—TRANSVERSE SECTION OF THE CAVERNOUS SINUS. (Langer.)

BRANCHES.—In the neck the internal carotid artery gives usually no branch. While in the carotid canal it sends a small offset to the tympanum, which anastomoses with the other tympanic arteries. Within the cavernous sinus some small branches proceed from it to supply the pituitary body, the Gasserian ganglion, the nerves in the outer wall of the cavernous sinus, and the adjacent dura mater.

The last form anastomoses with branches of the meningeal, and recurrent branches of the ophthalmic and lachrymal arteries. Immediately after it has pierced the dura mater, the internal carotid gives off the ophthalmic artery and small twigs to the optic commissure and the beginning of the optic nerve; and in the vallicula Sylvii, before dividing into the anterior and middle cerebral arteries, it usually furnishes the posterior communicating and the anterior choroid arteries.

**Varieties.**—The cervical part of this artery is sometimes tortuous. In some very rare cases the internal carotid has arisen directly from the arch of the aorta or from the division of the innominate artery (p. 392). A few examples of its entire absence are recorded. Its lower part occasionally gives origin to the occipital or the ascending pharyngeal artery; and in one case its intracranial portion furnished a considerable meningeal offset to the posterior fossa of the skull (Curnow). In several instances a large communicating branch has been seen passing from the part of the internal carotid within the cavernous sinus backwards to the trunk of the basilar artery.

#### BRANCHES OF THE INTERNAL CAROTID ARTERY.

**1. Ophthalmic artery (v).**—This artery, arising from the internal carotid on the inner side of the anterior clinoid process, enters the orbit by the optic foramen, below the optic nerve. Having pierced the sheath of dura mater, it soon changes its direction, passing round the outer side of, and then over the nerve to reach the inner wall of the orbit, along which it runs forwards between the superior oblique and internal rectus muscles; and it ends opposite the internal angular process of the frontal bone by dividing into the nasal and frontal arteries. The trunk and branches of the ophthalmic artery are markedly tortuous.

*Branches.*—(a) The *central artery of the retina*, a very small vessel, arises close to the optic foramen, as a rule in common with the internal ciliary trunk, less frequently with the external, and seldom independently. About half an inch behind the eyeball it pierces the lower and outer part of the optic nerve, in the centre of which it is then continued to the retina.

(b) The *ciliary arteries* are divided into two sets, posterior and anterior. The *posterior* arise in two chief trunks, an inner and an outer, from the ophthalmic artery while it is below the optic nerve. Each trunk divides into branches (from 3

to 10) which pass forwards, surrounding the optic nerve, to the back of the eyeball. Piercing the sclerotic coat near the entrance of the optic nerve, the greater number (*short ciliary arteries*) pass at once into the choroid coat; but two, which are somewhat larger than the others, extend forwards, one on each side of the eye, between the sclerotic and choroid coats to the ciliary muscle and iris, and are distinguished as the *long ciliary arteries*. The *anterior ciliary arteries*, six to eight, are derived from the muscular and lachrymal branches; they form a vascular ring beneath the conjunctiva at the fore part of the eyeball, and then pierce the sclerotic within a line or two of the margin of the cornea. The mode of distribution of these arteries within the eyeball is described in the account of the anatomy of the eye in Vol. III.

(c) The *lachrymal artery*, arising on the outer side of the optic nerve, passes forwards along the upper border of the external rectus muscle to the lachrymal gland, in which the greater number of its branches are distributed. Some of the branches pass onwards to the conjunctiva and eyelids, two of them, named *external palpebral*, forming arches in the lids with the internal palpebral arteries from the termination of the ophthalmic. Two small offsets accompany the temporal and malar branches of the superior maxillary nerve, and anastomose respectively with the anterior deep temporal and transverse facial arteries. The lachrymal artery also communicates through the outer end of the sphenoidal fissure (or a special aperture in the great wing of the sphenoid) with an offset of the middle meningeal artery.

(d) One or two minute *recurrent* branches, springing from the ophthalmic trunk or from the beginning of the lachrymal artery, pass through the sphenoidal fissure to join offsets of the internal carotid artery. Other twigs run backwards in the sheath of dura mater surrounding the optic nerve, and anastomose in the optic foramen with vaginal branches from the internal carotid or beginning of the ophthalmic artery.

(e) Small *muscular* offsets arise at uncertain intervals from the trunk of the artery, as well as from the lachrymal and supraorbital branches; in addition to these there are two more regular branches, an *external*, which is distributed to the upper and outer muscles of the orbit, and an *internal*, larger and more constant, to the lower and inner muscles.

(f) The *supraorbital* branch, arising as the artery crosses the optic nerve, ascends on the inner side of the superior rectus and levator palpebræ muscles, courses forwards to the supraorbital notch in company with the nerve of the same name, and terminates on the forehead. It gives branches to the upper eyelid, and communicates with the superficial temporal and frontal arteries.

(g) The *ethmoidal arteries* are two in number, a posterior and an anterior. The *posterior* is small, and very frequently arises in common with the supraorbital: it enters the posterior internal orbital canal, and is distributed to the mucous mem-

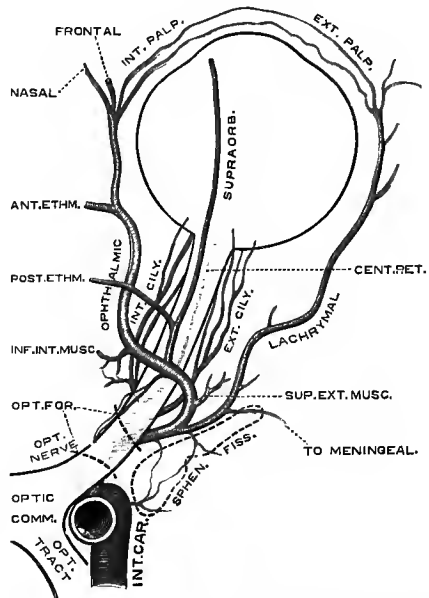


Fig. 344.—PLAN OF THE OPHTHALMIC ARTERY, SHOWING THE TYPICAL MODE OF ORIGIN OF ITS BRANCHES (after Meyer). (G. D. T.)

vaginal branches from the internal carotid

brane of the posterior ethmoidal cells and upper part of the nose. The *anterior* is larger, and passes with the nasal nerve into the cranial cavity, where it gives off small *anterior meningeal* branches to the dura mater in the anterior fossa, and then descends into the nose (*anterior nasal artery*). It supplies the mucous membrane of the fore part of the nasal fossa, frontal sinus and anterior ethmoidal cells, and one small twig accompanies the termination of the nasal nerve to the skin of the nose.

(h) The two *palpebral* branches, *superior* and *inferior*, arise near the front of the orbit, usually together, but soon diverge, one lying above, the other below the

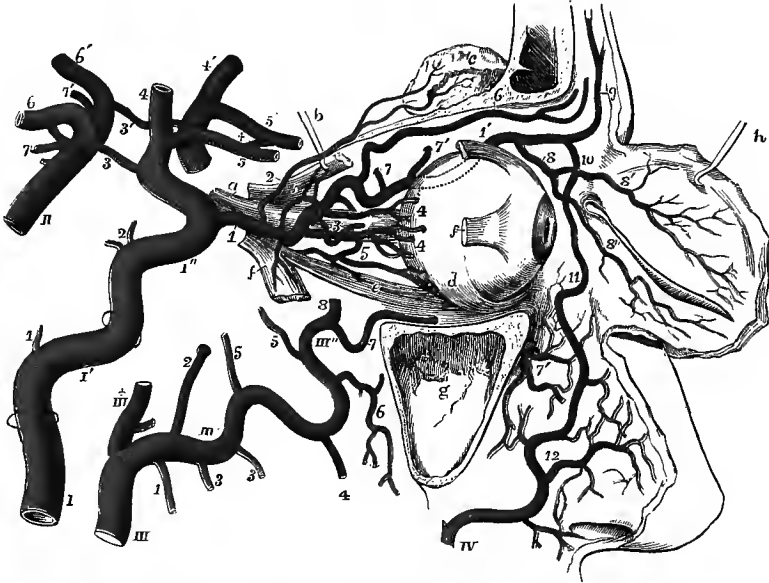

Fig. 345.—SEMIDIAGRAMMATIC VIEW OF THE ARTERIES OF THE ORBIT AND NEIGHBOURING PARTS, WITH THEIR BRANCHES AND ANASTOMOSES. (Allen Thomson.)

The outer wall of the orbit has been removed, the maxillary sinus is laid open, the eyelids are turned forwards, and the external and superior recti, and the superior oblique muscles have been partially removed: *a*, optic nerve; *b*, hook, holding up the posterior part of the superior rectus muscle, the anterior part of which is left attached to the eyeball; *c*, lacrimal gland, thrown up on the frontal bone; *d*, inferior oblique muscle; *e*, inferior rectus; *f*, *f*, anterior and posterior portions of the external rectus; *g*, maxillary sinus; *h*, hook, holding up the eyelids, of which the deep surface is shown.

I, internal carotid artery below the inferior aperture of the carotid canal, which is indicated higher up by a ring surrounding the artery; 1', the part of the artery situated within the temporal bone, a second ring indicating the place of the foramen lacerum; 1'', the part of the artery situated on the sphenoid bone; from this artery, 1, twig to the tympanum; 2, twigs in the cavernous sinus; 3, posterior communicating artery; 4, middle cerebral; 5, anterior cerebral.

II, basilar artery; from this artery, 6, posterior cerebral; 7, superior cerebellar: the accented numbers, 3', 4', 5', 6', 7', indicate, on the left side, the arteries already named under the same numbers on the right side, which with these and the anterior communicating branch marked by +, complete the circle of Willis.

III, upper part of the external carotid artery, dividing into III +, the superficial temporal, and III', III'', the internal maxillary artery; from the latter artery, 1, inferior dental branch; 2, middle meningeal; 3, 3, masseteric and pterygoid branches; 4, buccal; 5, 5, anterior and posterior deep temporal; 6, posterior dental; 7, infraorbital; 7', branches of the same issuing upon the face; 8, part of the internal maxillary which passes into the spheno-maxillary fossa.

IV, facial artery, terminating at 11, in the angular, and giving off, at 12, the lateral nasal branch, and others which communicate with the infraorbital.

In the orbit the following numbers indicate the ophthalmic artery and its branches: 1, the ophthalmic at its origin from the internal carotid; 1', the same artery continued on the upper and inner side of the orbit; 2, lacrimal; 3, central artery of retina; 4, 4, posterior ciliary; 5, 5, muscular; 6, supraorbital; 7, 7', posterior and anterior ethmoidal; 8, 8', 8'', palpebral; 9, frontal; 10, nasal, anastomosing with the angular of the facial.

internal tarsal ligament. They send small branches to the conjunctiva, the caruncle and the lachrymal sac, and then pass outwards between the orbicularis muscle and the tarsus, to form arches, one near the free margin of each lid, with the palpebral branches of the lachrymal artery.

(i) The *nasal* branch courses forwards above the internal tarsal ligament to the root of the nose, where it ramifies, maintaining a free communication with the nasal and angular branches of the facial artery.

(j) The *frontal artery* turns upwards round the inner end of the orbital arch, and is distributed to the integument, muscles and periosteum of the mesial part of the forehead, anastomosing with the supraorbital artery and with the corresponding artery of the other side.

**Varieties.**—The ophthalmic artery sometimes (15 per cent.) crosses beneath, instead of over, the optic nerve, and it may then in its intraorbital course lie entirely to the inner side of the nerve. It has been seen occasionally entering the orbit through the sphenoidal fissure. The lachrymal artery not unfrequently, and in rarer cases a large part or even the whole of the ophthalmic itself, arises from the middle meningeal artery; or the ophthalmic artery has been seen to give off the middle meningeal. The lachrymal may also be reinforced by the anterior deep temporal artery. All the above varieties may be explained as resulting from the enlargement of normal anastomotic channels, the regular trunk being more or less diminished or even obliterated. The mode of origin of the branches of the ophthalmic artery is subject to great variation. There are often one or two additional ciliary trunks. The supraorbital and posterior ethmoidal are both inconstant. The nasal branch is sometimes large and supplies a deficiency of the facial artery. (F. Meyer, "Zur Anatomie der Orbitalarterien," *Morph. Jahrb.*, xii, 1886.)

**2. The posterior communicating artery** passes backwards across the outer angle of the interpeduncular space of the cerebrum, and above the third nerve, to join the posterior cerebral branch of the basilar artery in front of the crus cerebri. It varies much in size, and the arteries of the two sides are commonly unequal: the right is more frequently the larger. The posterior communicating artery gives off small twigs to the parts in the interpeduncular space, and one or two larger branches which pass in between the crus cerebri and the corpus albicans to supply the inner and fore part of the optic thalamus.

**3. The anterior choroid artery** runs outwards and backwards in the cleft between the temporal lobe of the cerebral hemisphere and the crus cerebri, to reach the choroid plexus in the descending cornu of the lateral ventricle. It also supplies branches to the posterior half of the optic tract, to the uncinata convolution, and to the posterior limb of the internal capsule.<sup>1</sup>

**4. The anterior cerebral artery (iv)**, from the division of the internal carotid in the vallecula Sylvii, runs nearly horizontally forwards and inwards above the optic nerve to the beginning of the longitudinal fissure between the cerebral hemispheres in front of the optic chiasma. As it enters this fissure it is connected with the vessel of the opposite side by the *anterior communicating artery*, a small transverse branch not more than two lines in length. The two anterior cerebral arteries, lying close together, then turn round the genu of the corpus callosum, giving off branches to the hemisphere, and terminate in the posterior internal frontal arteries (*v. infra*).

**5. The middle cerebral artery (iii)** forms both in size and direction the continuation of the internal carotid (fig. 345). It passes upwards and outwards in the fissure of Sylvius, and soon divides into its terminal branches which ramify over the outer surface of the hemisphere.

**Varieties of the cerebral arteries.**—In some instances the anterior cerebral arteries are united into a single trunk, like the basilar artery behind, and this again divides into right

<sup>1</sup> A. Kolisko, "Ueber die Beziehung der Arteria choroidea anterior zum hinteren Schenkel der inneren Kapsel des Gehirnes," Wien, 1891.

and left arteries (4 per cent.). The two arteries frequently differ in size at their origin, and the larger one reinforces the other through the anterior communicating artery: this may proceed so far that both anterior cerebral arteries spring from one internal carotid, by means of a common trunk which bifurcates as it enters the longitudinal fissure. The two arteries have also been seen united in a single trunk, which runs in the longitudinal fissure, giving off branches to both hemispheres. On the other hand, a third artery, *middle anterior cerebral*, arising from the anterior communicating is not uncommon (4.5 per cent.). The anterior communicating is sometimes double (7 per cent.).

The posterior communicating artery is sometimes connected with the middle cerebral artery instead of the trunk of the internal carotid. The posterior cerebral artery frequently arises by an enlarged posterior communicating artery from the internal carotid, and is connected only by a slender vessel with the basilar (on the right side only in 5.5, on the left side only in 4.5, and on both sides in 2 per cent.). The opposite condition, in which the middle cerebral artery is derived from the posterior, has been recorded by Hyrtl. The posterior communicating artery is sometimes wanting, or the branch representing it fails to join the posterior cerebral (on the right side only in 4.5, on the left side only in 6.5, and on both sides

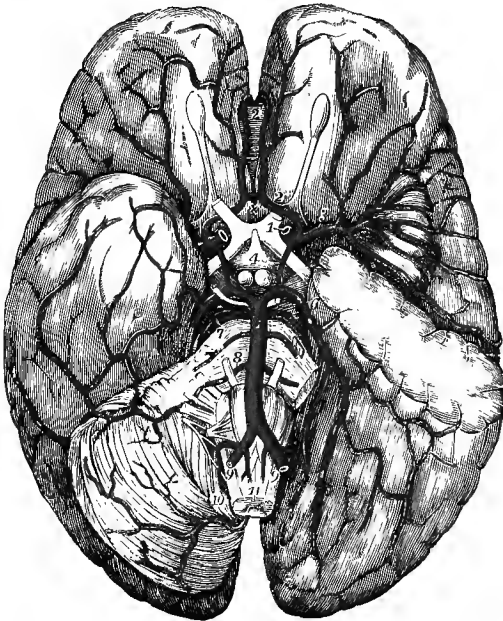


Fig. 346.—THE DISTRIBUTION OF THE INTERNAL CAROTID AND VERTEBRAL ARTERIES AT THE BASE OF THE BRAIN. (Allen Thomson.)  $\frac{1}{2}$

On the left side a portion of the temporal lobe of the cerebrum has been removed, so as to open up the fissure of Sylvius and expose the island of Reil; and the left half of the cerebellum has been removed to show the lower surface of the posterior part of the cerebral hemisphere. 1, placed on the optic commissure, points to the divided left internal carotid artery; 2, left anterior cerebral artery, exposed fully by the removal of the optic nerve; 2', placed on the genu of the corpus callosum between the two anterior cerebral arteries; x, placed on the lamina cinerea in front of the optic commissure, marks the anterior communicating artery; 3, left middle cerebral artery, passing into the fissure of Sylvius and distributing its branches over the convolutions of the island of Reil and others beyond; 4, placed between the infundibulum and the corpora albicantia, points by a line to the left posterior communicating artery; 5, basilar artery; 6, left posterior cerebral artery; 7, placed on the pons Varolii,

points to the right superior cerebellar artery; 8, anterior cerebellar artery; between 7 and 8, one of the largest of the transverse branches of the basilar artery; 9, 9, right and left vertebral arteries; 10, inferior cerebellar artery; 11, anterior spinal arteries.

in 1.5 per cent.). The anterior choroid artery is occasionally derived from the middle cerebral or posterior communicating: it may be represented by two or three smaller branches. (B. C. A. Windle, "On the Arteries forming the Circle of Willis," *Journ. Anat.*, xxii, 1888. A determination of the frequency of the different variations in 200 cases, of which 119 were normal).

**Circle of Willis.**—A remarkable anastomosis exists between the branches of the vertebral and internal carotid arteries within the cranium, by which the circulation is equalised in different parts of the brain, and any deficiency which might arise from the obliteration of one, or even two of the vessels, may be remedied by a corresponding increase in the supply through the others. This anastomosis, known as the *circle of Willis*, is formed in the following manner. The anterior cerebral arteries are connected together, as already mentioned, by the anterior communicating artery. The right and left internal carotids, the trunks from which the anterior cerebral

arteries arise, are united by the posterior communicating arteries to the posterior cerebral arteries, and these arise behind from a single trunk—the basilar artery. Within or opposite to the area of this vascular circle are the following parts of the encephalon, viz., the optic commissure, infundibulum and tuber cinereum, corpora albicantia, and posterior perforated spot.

#### DISTRIBUTION OF THE CEREBRAL ARTERIES.

From the three cerebral arteries—anterior, middle and posterior—two distinct systems of vessels proceed. The first of these, consisting of branches given off by the arteries while still within or immediately after leaving the circle of Willis, is destined for the great central ganglia, and is called the *central system of arteries*. The vessels of the second set ramify in the pia mater, and are distributed to the grey matter of the convolutions and the subjacent white matter: they constitute the *cortical system of arteries*. These two systems are independent of each other, and the vessels of the central system are all “terminal arteries,” that is, do not form anastomoses together; but the cortical arteries communicate more or less freely on the surface of the hemisphere through their secondary and tertiary ramifications. The cortical arteries break up into fine branches in the pia mater before entering the cerebral substance.

The **anterior cerebral artery** has a very limited central distribution, giving only a few small branches (and these not constantly) which constitute the *antero-mesial group of central arteries*. They pierce the inner part of the anterior perforated space, and supply the anterior extremity of the caudate nucleus. Two or three twigs, which are sometimes included in this group, commonly pass from the anterior communicating artery to the lamina cinerea, the rostrum of the corpus callosum and the adjacent part of the septum lucidum. Its *cortical* branches are (*a*) two to four small *inferior internal frontal arteries* to the internal orbital convolution, supplying also the olfactory lobe; (*b*) the *anterior internal frontal artery*, distributed to the lower part of the marginal convolution and the superior and middle frontal convolutions; (*c*) the *middle internal frontal artery* to the callosal convolution and upper part of the marginal convolution; and (*d*) the *posterior internal frontal artery*, supplying the quadrate lobule and giving off the *artery of the corpus callosum*, which runs backwards on the upper surface of that body to its posterior extremity.

The **middle cerebral artery** immediately after leaving the internal carotid gives off the more numerous *antero-lateral central arteries*, which pass directly upwards through the foramina of the anterior perforated space to the base of the corpus striatum. They are divided by Duret into *lenticular arteries* supplying the internal and middle segments of the lenticular nucleus and the internal capsule, *lenticulo-striate arteries* to the outer segment of the lenticular nucleus, external capsule and caudate nucleus, and *lenticulo-optic arteries* to the outer and posterior part of the lenticular nucleus and the outer part of the optic thalamus. One of the lenticulo-striate arteries, larger than the rest, is especially noteworthy as being a frequent seat of cerebral hæmorrhage: it passes outwards and upwards at the junction of the anterior and middle thirds of the lenticular nucleus, between the latter and the external capsule, and perforates the internal capsule to end in the caudate nucleus. The main trunk of the middle cerebral passes upwards and outwards in the fissure of Sylvius to the surface of the island of Reil, where it divides into the following four branches:—(*a*) the *inferior external frontal* is limited in its distribution to the outer part of the orbital surface of the hemisphere and the adjacent inferior frontal convolution; (*b*) the *ascending frontal* is distributed to the convolution of the same name, together with the root of the middle frontal convolution; (*c*) the *ascending*

*parietal* supplies the ascending parietal convolution and the fore part of the superior parietal lobule; and (*d*) the *parieto-temporal*, much the largest and often double, runs backwards in the posterior limb of the fissure of Sylvius, and ramifies upwards

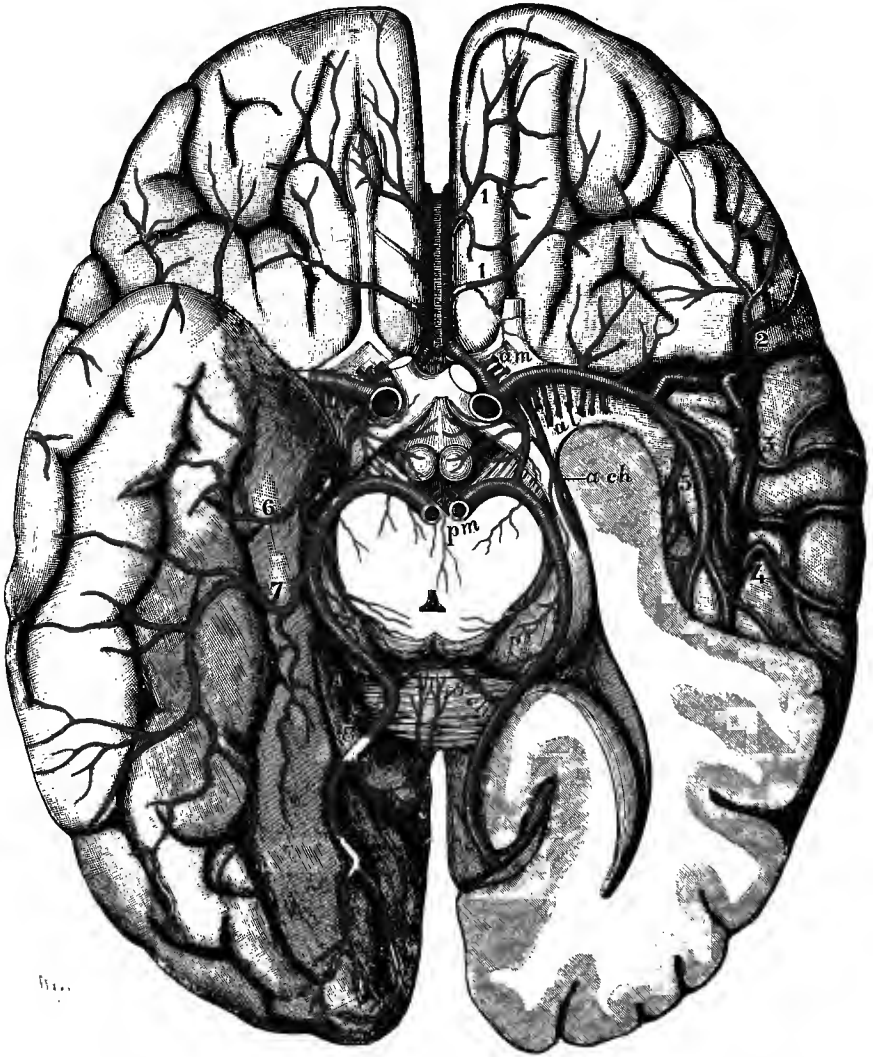


Fig. 347.—THE ARTERIES OF THE BASE OF THE CEREBRUM (after Merkel, and from nature).  
(G. D. T.)

On the left side the greater part of the temporal lobe and the lower part of the occipital lobe are taken away, so as to open the inferior and posterior cornua of the lateral ventricle; the midbrain is divided close above the pons, and the posterior cerebral arteries are cut at their origin from the basilar.

*Central arteries:* *am*, antero-mesial group, arising from the anterior cerebral; *al*, antero-lateral group, from the middle cerebral; *pm*, and *pl* (on the optic thalamus), postero-mesial and postero-lateral groups, from the posterior cerebral. *Choroid arteries:* *a ch*, anterior, from the internal carotid; *p ch* (on the splenium of the corpus callosum), posterior, from the posterior cerebral. *Cortical arteries:* 1, 1, inferior internal frontal, from the anterior cerebral; 2, inferior external frontal, 3, ascending frontal, 4, ascending parietal, and 5, parieto-temporal, from the middle cerebral; 6, anterior temporal, 7, posterior temporal, and 8, occipital, from the posterior cerebral.



over the inferior parietal and the hinder part of the superior parietal lobules, and downwards over the superior and the upper part of the middle temporal convolutions.

The **posterior cerebral artery** (the origin and course of which are described on p. 423) gives off close to its commencement the *postero-mesial central arteries*, which ascend through the posterior perforated space to the inner part of the crus cerebri, the optic thalamus and the wall of the third ventricle. It also furnishes two or three small twigs to the crus as it passes over that body, the *postero-lateral group of central arteries*, which arise on the outer side of the crus and supply the corpora quadrigemina and the hinder part of the optic thalamus, and one or two

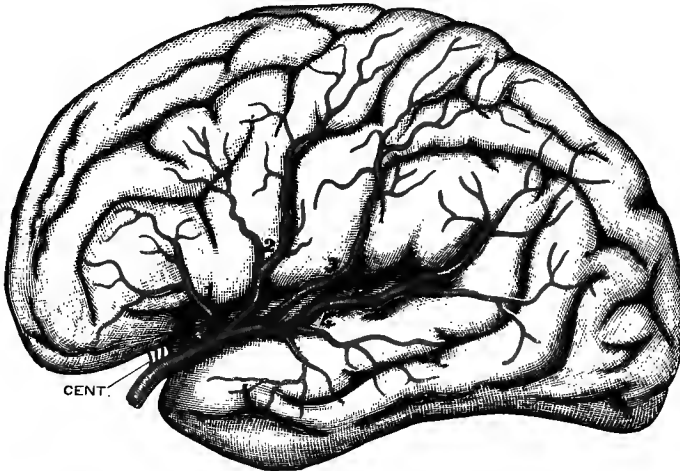


Fig. 348.—CORTICAL DISTRIBUTION OF THE MIDDLE CEREBRAL ARTERY (semidiagrammatic, after Charcot). (G. D. T.)

Cent., antero-lateral group of central branches; 1, inferior external frontal artery; 2, ascending frontal artery; 3, ascending parietal artery; 4, parieto-temporal artery.

*posterior choroid arteries* to the velum interpositum and upper part of the choroid plexus. Its cortical branches are three in number:—(a) the *anterior temporal* is distributed to the anterior part of the uncinatè gyrus and its immediate vicinity; (b) the *posterior temporal* supplies the middle part of the uncinatè, the external occipito-temporal, and the lower temporal convolutions; and (c) the *occipital*, lying in the calcarine fissure, supplies the occipital lobe on its inner and outer surfaces.

(On this subject see Heubner, *Centralbl. f. d. med. Wissensch.*, 1872, and "Die luetische Erkrankung der Hirnarterien," Leipzig, 1874; and H. Duret, *Arch. de Physiol.*, 1874.)

#### SUBCLAVIAN ARTERIES.

The subclavian artery is the first portion of a long trunk which forms the main artery of the upper limb, and which is artificially divided for purposes of description into three parts, named the subclavian, axillary, and brachial arteries.

The subclavian artery, arising on the right side from the extremity of the innominate stem, and on the left from the arch of the aorta, passes a short way up into the neck, arches outwards over the pleura and lung, and rests between the scalenus anticus and scalenus medius muscles on the first rib. At the outer border of the first rib it ceases to be called subclavian, and is continued into the axillary

artery. It has an average length of about three inches on the right side, an inch more on the left. The subclavian artery is considerably larger than the common carotid; and as the trunk gives origin to several large branches it diminishes in size towards its termination (from 11 to 9 mm.). The left artery is almost constantly a little smaller than the right.

Each subclavian artery is conveniently divided into three parts,—the *first* part extending from the origin of the vessel to the inner border of the anterior scalenus muscle; the *second* consisting of the portion of the vessel situated behind that muscle; and the *third* reaching outwards to the external border of the first rib. In examining each of these portions in detail, it will be necessary to give a separate description of the first part on the right and the left sides, as there is a material difference in the origin, course, and relations of the two vessels.

THE FIRST PART OF THE RIGHT SUBCLAVIAN ARTERY commences close to the trachea, at the division of the innominate artery, behind the upper part of the sterno-clavicular articulation, and ends at the inner margin of the anterior scalenus muscle. Diverging gradually from the carotid artery, it arches upwards and outwards, and ascends above the level of the clavicle to an extent which varies in different cases. It is deeply placed, being covered by the sterno-mastoid, the sterno-hyoid, and sterno-thyroid muscles, and the deep cervical fascia. It is in contact with the pleura below and behind; and the apex of the lung separates it from the first dorsal vertebra and the adjoining parts of the first and second ribs.

*Relation to veins.*—The *right innominate vein* lies below and somewhat in front of this part of the artery, while the *internal jugular* and *vertebral veins*, in their course to join the innominate, descend over its anterior surface. Farther forwards the *anterior jugular vein* passes transversely outwards, but is separated from the artery by the sterno-hyoid and sterno-thyroid muscles.

*Relation to nerves.*—The *pneumo-gastric nerve* crosses the front of the artery to the inner side of the internal jugular vein, and its *recurrent laryngeal* branch, turning round below the artery, ascends behind. Some *cardiac nerves* and a loop or two of the *sympathetic* descend over the artery, while the main trunk of the latter passes behind.

THE FIRST PART OF THE LEFT SUBCLAVIAN ARTERY arises from the upper aspect of the arch of the aorta near its posterior extremity, and is, therefore, much longer than the first part of the right subclavian. It ascends almost vertically out of the thorax to the root of the neck, where it turns sharply outwards, across the apex of the lung, to reach the interval between the scaleni muscles. Deeply placed in the superior mediastinum, it has the left carotid artery in front of, but not in contact with it, and it is covered on the left side by the pleura. It rests for a short distance on the œsophagus (here deviating to the left side) and the thoracic duct, and afterwards on the longus colli muscle. To the inner or right side of the vessel is at first the trachea, and higher up are the œsophagus and the thoracic duct. The thoracic duct arches from behind forwards and outwards over this part of the artery in its course to the angle of union of the internal jugular and subclavian veins.

*Relation to veins.*—The *internal jugular* and *vertebral veins* are immediately in front of the artery, where it turns outwards from the thorax, close to the scalenus muscle; and lower down the *left innominate vein* is anterior to it.

*Relation to nerves.*—The *pneumo-gastric nerve* is in front of and parallel to the first part of the left subclavian artery, but in contact with it only at its lower part. The *phrenic nerve* descends over the artery along the inner margin of the scalenus muscle, immediately outside the thyroid axis. The *cardiac nerves* of the left side, descending from the neck, are close to the artery, the cord of the *sympathetic* is behind, and the *inferior laryngeal nerve* ascends on its inner side.

THE SECOND PART OF THE SUBCLAVIAN ARTERY, the short portion concealed

by the anterior scalenus muscle, forms the highest part of the arch described by the vessel across the root of the neck. Somewhat less deeply placed than the first part, it is covered by the sterno-mastoid and anterior scalenus muscles, with layers of cervical fascia. Behind and below, it lies on the pleura.

*Relation to veins and nerves.*—The *subclavian vein* is farther forwards and lower than the artery, and is separated from it by the anterior scalenus muscle. The *phrenic nerve*, which descends obliquely inwards over that muscle, crosses the first part of the subclavian artery of the left side close to the muscle, while on the right side, not having quite reached the margin of the muscle at the level of the artery, it is usually separated by the muscle from the second part of the artery.



Fig. 349.—VIEW OF THE RIGHT COMMON CAROTID AND SUBCLAVIAN ARTERIES, WITH THE ORIGIN OF THEIR BRANCHES AND THEIR RELATIONS. (R. Quain.)  $\frac{1}{3}$

For the explanation of the references in the upper part of this figure, see p. 389. The following relate to the subclavian artery and its branches: 3, first part, 3', third part of subclavian artery; 3'', subclavian vein, shown by the removal of a portion of the clavicle; 9, is placed on the scalenus anticus, in the angle between the superficial cervical and suprascapular branches of the thyroid axis; 10, outer part of the suprascapular artery; 10', superficial cervical artery, passing into the deep surface of the trapezius; 10'', posterior scapular artery, arising from the third part of the subclavian artery, and passing through the brachial plexus of nerves and under the levator anguli scapulae; 11, on the scalenus anticus, points to the inferior thyroid artery, near the place where the ascending cervical artery is given off; the phrenic nerve lies on the muscle to its outer side; *i*, the suprasternal twig of the suprascapular artery; *k*, first rib; *l*, perforating branch of internal mammary artery.

THE THIRD PART OF THE SUBCLAVIAN ARTERY lies for its greater part in a small triangular space, the sides of which are formed by the omo-hyoid muscle and clavicle, and the base by the anterior scalenus. The artery is nearer to the surface here than elsewhere, being covered only by the integument, platysma, and layers of cervical fascia; but towards its termination it becomes deeper, sinking under the clavicle and the subclavius muscle. It rests upon the first rib; and behind it is the scalenus medius.

*Relation to veins.*—The *subclavian vein* is still anterior to, and lower than, the artery. The *external jugular vein* crosses in front of the artery, and receives on the outer side from the shoulder the two veins which accompany the suprascapular and transverse cervical arteries. These veins in some cases form a sort of plexus over the artery.

*Relation to nerves.*—Above the vessel are placed the *nerves of the brachial plexus*, the lowest trunk, formed by the union of the last cervical and the first dorsal nerves,

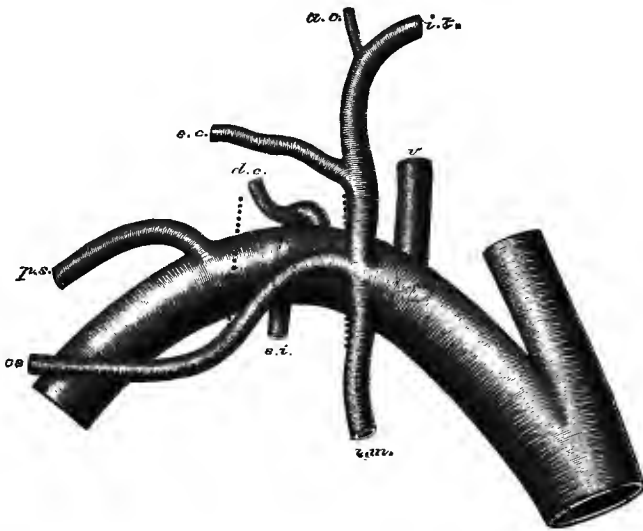


Fig. 350.—ORIGIN OF THE BRANCHES OF THE RIGHT SUBCLAVIAN ARTERY (modified from Wyeth).  
(G. D. T.) Natural size.

*v*, vertebral artery; *i.t.*, inferior thyroid artery, giving off *a.c.*, the ascending cervical; *s.c.*, superficial cervical artery; *ss*, suprascapular artery; the last three arising together by the thyroid axis; *i.m.*, internal mammary artery; *s.i.*, superior intercostal artery, from which arises *d.c.*, the deep cervical; *p.s.*, posterior scapular artery. The thick dotted lines indicate the position of the inner and outer borders of the anterior scalenus muscle.

being behind and in close contact with it. The small *nerve to the subclavius* passes down over the artery, and the space which lodges the artery is crossed in front by the *descending superficial branches* from the *cervical plexus* of nerves.

**BRANCHES.**—Four branches are commonly described as arising from each subclavian artery. Of these, three, namely, the vertebral, the internal mammary, and the thyroid axis, usually spring close together from the first part of the artery, near the inner side of the anterior scalenus muscle; while the fourth branch, the superior intercostal, is generally found also internal to that muscle on the left side, but arising under cover of it, from the second part of the artery, on the right.

The vertebral artery springs from the upper and back part of the subclavian, and ascends in the neck to reach the interior of the skull; the internal mammary

proceeds from the lower side of the vessel, and descends into the fore part of the chest and abdomen; the thyroid axis arises from the front of the artery, and divides into three branches, one of which, the inferior thyroid, is distributed in the fore part of the neck, while the other two, the suprascapular and the transverse cervical, pass outwards across the neck to the shoulder; lastly, the superior intercostal and deep cervical arise by a common stem from the back part of the artery, and pass into the upper part of the thoracic wall and the posterior muscles of the neck. The deep cervical is reckoned by some writers as a fifth branch of the subclavian artery, but it usually arises in common with the superior intercostal artery.

Another branch, in the majority of instances, arises from the second or third part of the artery. This is most frequently the posterior scapular artery, a branch which otherwise is derived from the transverse cervical, one of the divisions of the thyroid axis; but it may be the transverse cervical itself, or the suprascapular, or a common trunk for the posterior scapular and suprascapular arteries; and in rare cases the thyroid axis or internal mammary is found arising in this situation.

**Varieties.**—The variations in *origin* of the subclavian arteries have been considered along with the peculiarities of the arch of the aorta.

**Course and relations.**—The height to which these vessels reach in the neck is liable to some variation. Most commonly the second part of the artery is placed from half to three-quarters of an inch above the clavicle (the shoulder being depressed to the full extent), but it is sometimes, especially on the right side, placed as high as an inch, or even an inch and a half above the level of the bone; or on the other hand it may be entirely under cover of the clavicle. The third part of the artery is not unfrequently concealed by the posterior belly of the omo-hyoid, when that muscle has an attachment to the clavicle (p. 300) or is bound down to the bone by the fascia. More rarely the artery is covered by an unusually wide clavicular attachment of the trapezius (p. 205), or crossed by a sterno-scapular muscle (p. 212). Occasionally the subclavian artery perforates the anterior scalenus muscle; and in rarer cases it has been found altogether in front of the muscle, and close to the subclavian vein. The vein has also been seen to pass with the artery behind the scalenus muscle; and two or three cases are recorded in which the positions of the artery and vein were reversed.

**Branches.**—The places of origin of the several branches of the subclavian artery are subject to frequent slight variations, and it occasionally happens that one or more of the first three branches are moved considerably inwards from their usual position, or outwards to another division of the subclavian. Sometimes two, and much more rarely three, branches arise from the third part of the vessel. A small muscular and spinal branch is frequently given off from the second part of the artery.

**Aberrent artery.**—This is a small vessel arising from the right subclavian artery near the vertebral, and descending to the left between the œsophagus and spine to join the aorta near the termination of the arch: it is a vestige of the right aortic root (p. 386). A branch arising in this situation, and terminating on the trachea and œsophagus, is not uncommon. (J. Wood, *Trans. Path. Soc.*, x, 123; F. J. Shepherd, *Journ. Anat.*, xxiv, 71.)

#### BRANCHES OF THE SUBCLAVIAN ARTERY.

**1. Vertebral artery (iii).**—The vertebral artery arises from the upper and back part of the subclavian, on the right side generally about three-quarters of an inch from its commencement, on the left side from the bend formed by the main trunk as it turns outwards at the root of the neck. Passing upwards, and a little backwards and outwards, the artery enters the foramen in the transverse process of the sixth cervical vertebra. It then ascends in a vertical direction through the series of foramina in the transverse processes, as far as the upper border of the axis, where it is curved outwards to reach the corresponding foramen of the atlas. After passing through that aperture it winds backwards and inwards in the vertebral groove of the atlas, and beneath the arched band of the posterior occipito-atlantal ligament (p. 158). Immediately piercing the dura mater and arachnoid, it turns upwards and forwards in the subarachnoid space, enters the skull through the foramen magnum, and finally, inclining from the side to the front of the medulla oblongata, it unites with the vessel of the opposite side, at the lower border of the pons Varolii, to form the basilar artery.

At its commencement the vertebral artery lies behind the internal jugular, as well as its own companion vein, and on approaching the vertebræ it passes between the longus colli and the scalenus anticus muscles. On the left side, the thoracic duct crosses in front of the artery from within outwards.

While within the foramina of the cervical vertebræ, the artery is accompanied by a fine plexus of the sympathetic nerve and surrounded by the plexiform vertebral vein: the cervical nerves as they emerge from the intervertebral foramina pass behind it. In the groove of the atlas the artery is at first covered by the superior

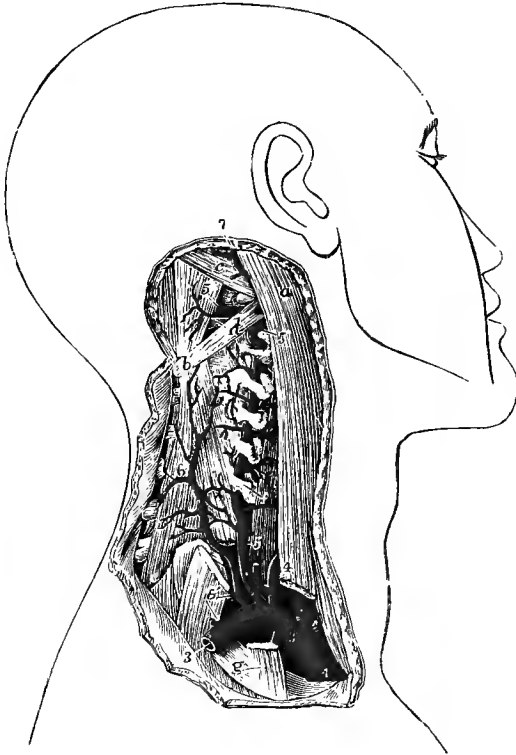


Fig. 351.—DEEP DISSECTION OF THE NECK, SHOWING THE ORIGIN AND COURSE OF THE VERTEBRAL ARTERY. (Tiedemann.)  $\frac{1}{3}$

*a*, upper part of sterno-mastoid muscle; its clavicular part is divided below; *b*, spinous process of axis; *c*, superior oblique muscle; *d*, on the inferior oblique muscle, points by a line to the posterior arch of the atlas; *e*, semispinalis colli; *f*, placed on the longus colli, points to the transverse process of the sixth cervical vertebra; *g*, on the first rib, points to the scalenus anticus muscle, cut near its attachment; 1, innominate artery; 2, right common carotid; 3, right subclavian; below it, the origin of the internal mammary artery; above it, 4, the thyroid axis; 5, 5, vertebral artery, passing up through the transverse processes and giving branches to the muscles; 5', on the rectus posticus major, points to its horizontal part on the arch of the atlas; 6, deep cervical artery, arising in common with 6', the superior intercostal; 7, occipital artery, emerging from beneath the sterno-mastoid.

oblique muscle, and then appears in the suboccipital triangle: the suboccipital nerve here lies between the artery and the bone.

As it enters the subarachnoid space, the artery is crossed by the first tooth of the ligamentum denticulatum (fig. 182, p. 156); and then, passing forwards between the origin of the hypoglossal and the anterior root of the suboccipital nerves, it ascends between the anterior surface of the medulla oblongata and the basilar process of the occipital bone.

The vertebral artery lies loosely in the large foramen of the transverse process of the atlas, and this, together with the bend which it forms between the axis and atlas (fig. 351), allows of the rotation of the latter bone without undue stretching of the vessel. In extreme movements, however, the artery is somewhat compressed on the side from which the head is turned, while on the side towards which the movement is taking place the pressure is diminished (L. Gerlach, in "Beiträge zur Morphologie," &c., Stuttgart, 1884).

*Branches.*—A. *In the neck.*—(*a*) *Lateral spinal branches.*—These are several small offsets which pass through the intervertebral foramina into the spinal canal, and there divide, each into two branches; one of these passes along the roots of the spinal nerve, supplying them and the spinal cord, and anastomoses with the other

spinal arteries ; the other branch ramifies on the back part of the bodies of the vertebræ in the same manner as similar branches derived from the intercostal and lumbar arteries (see p. 422).

(b) *Muscular* branches of variable size are distributed to the deep-seated cervical muscles, and anastomose with the ascending cervical, deep cervical and occipital arteries.

(c) The *posterior meningeal artery* is a small branch, sometimes double, which arises just before the artery pierces the dura mater, and ascends through the foramen magnum to ramify in the lower occipital fossa, and in the falx cerebelli.

B. *Within the cranium.*—(a) The *posterior spinal artery* (vi) arises from the vertebral immediately after it has perforated the dura mater, and inclines downwards to reach the side of the spinal cord ; reinforced by a number of small arteries (5 to 12 on one side) as it descends, it may be traced as a small tortuous vessel or anastomotic chain in front of the posterior roots of the nerves as far as the lower end of the cord, where it terminates by communicating with the lower part of the anterior spinal artery. Offsets from this postero-lateral vessel ramify and anastomose together in the pia mater investing the cord, especially on its hinder surface, where they form more or less regularly a second longitudinal anastomosis behind the posterior nerve-roots.

(b) The (*posterior*) *inferior cerebellar artery* (v), the largest of the branches, arises a little above, or often in common with, the foregoing. It turns backwards, passing first between the roots of the hypoglossal nerve, and then between the vagus and spinal accessory nerves, and runs over the side of the restiform body and near the lower lateral margin of the fourth ventricle, to enter the fore part of the vallicula, where it divides into two branches. One of these is continued backwards in the sulcus between the cerebellar hemisphere and the inferior vermiform process, its offsets being distributed mainly to the latter structure, and anastomosing with those of the opposite artery ; while the other inclines outwards and ramifies on the under surface of the hemisphere as far as its outer border, over which the ultimate divisions of both branches anastomose with those of the superior cerebellar artery. Before dividing, this artery gives branches to the medulla oblongata and the choroid plexus of the fourth ventricle.

(c) The *anterior spinal artery* (vi) arises near the end of the vertebral, and descends obliquely on the front of the medulla oblongata. One is usually much larger than the other, and forms the commencement of the median anterior artery of the cord, receiving at a variable level a small communicating branch from the opposite vessel : in exceptional cases the median artery results from the union of equal, or nearly equal, branches of the two vertebrales. The vessel thus constituted is continued along the whole length of the cord by means of a series of arteries which pass up with the anterior nerve-roots, and divide each into an ascending and a descending branch ; by the union of adjacent branches a longitudinal vessel is produced, varying in size in different regions, and terminating below as a slender branch on the filum terminale. The number of these reinforcing arteries is commonly from five to ten, and the last one, which ascends on one of the lowest dorsal or upper lumbar nerves, is constantly larger than the rest.<sup>1</sup> From the anterior spinal artery numerous offsets pass backwards into the anterior median fissure, and outwards on the surface of the cord where they anastomose freely with one another and with the branches of the posterior spinal arteries.

(d) *Bulbar branches.*—Numerous small branches springing from the vertebral, as well as from the beginning of the inferior cerebellar and anterior spinal arteries,

<sup>1</sup> A. Adamkiewicz, "Die Blutgefäße des menschlichen Rückenmarkes," Wiener Sitzungsber., 1881-2 ; H. Kadyi, "Die Blutgefäße des menschlichen Rückenmarkes," Lemberg, 1889.

are furnished to the medulla oblongata, which they penetrate mainly along the roots of the nerves and in the anterior median fissure.

**Varieties.—Origin.**—While the vertebral artery arises, in the great majority of cases, on the right side from the subclavian between half an inch and an inch from its beginning, and on the left side from the same trunk as it bends outwards, its range of origin extends over the whole of the first part of the subclavian artery. In those cases in which the right subclavian artery is given off independently from the posterior part of the arch of the aorta, the right vertebral artery sometimes arises from the common carotid of the same side. In some rare instances the right vertebral artery has been seen arising from the aorta, between the right subclavian and carotid (p. 387), between the innominate and left carotid, or beyond the left subclavian artery and passing to its usual place behind the œsophagus.

The left vertebral artery is not unfrequently derived from the aorta, in which case it generally arises between the left carotid and subclavian arteries, but it has been observed arising last of the branches from the arch.

Either vertebral artery may as a rare occurrence arise by two roots, both proceeding from the subclavian artery, or one from the subclavian and the other from the aorta or from the inferior thyroid artery. One example of three roots to a vertebral artery (right) is recorded (R. Quain, pl. 24, fig. 2).

**Course and division.**—The vertebral artery not unfrequently enters the foramen of the fifth or fourth cervical vertebra; more rarely the third, or even the second. On the other hand, it has been seen to enter the foramen of the seventh vertebra. Rare varieties that have been met with are—division of the artery close to its origin into two branches which join again into a single trunk (R. J. Anderson, Journ. Anat., xiv. 250); division of the trunk above the axis, one part entering the spinal canal with the second cervical nerve, while the other pursues the normal course and unites with the first after piercing the dura mater (Herberg, Kadyi); and the formation of a similar, but smaller, loop around the hypoglossal nerve within the cranium (Tarenetzky).

**Size.**—One vertebral artery, more frequently the left, is sometimes much larger than the other.

**Branches.**—The vertebral artery has been found, though very rarely, to give off the inferior thyroid or superior intercostal artery. The inferior cerebellar artery is often wanting on one side.

**Arteries of the spinal canal.**—It will be convenient here to refer generally to the arrangement of the intraspinal arteries, which pass in from various sources through the intervertebral foramina, and are distributed in a similar manner throughout the whole length of the canal. They are derived from the vertebral and deep cervical arteries in the neck, the intercostal arteries in the dorsal region, and below this from the lumbar, ilio-lumbar, and lateral sacral arteries. A branch enters each intervertebral foramen, and there divides, one part being distributed to the walls of the canal, and the other piercing the sheath of dura mater on the issuing nerve. The latter division in the majority of cases is small, and ends by supplying the nerve-roots; but some of these branches are larger, and are continued to the spinal cord, where they enter the longitudinal anastomoses in the manner described above. There are no arteries passing to the cord below the third lumbar nerve, and only exceptionally are there medullary arteries on the anterior and posterior roots of the same nerve (Kadyi).

The larger parietal portion of the spinal artery immediately divides into two principal branches which are distributed to the bones and ligaments in the following manner:—one curves upwards on the back of the body of the vertebra above, near to the attachment of the pedicle, while the other descends in a similar manner on the vertebra below; and each communicates with a corresponding branch from the neighbouring spinal artery. As this arrangement prevails on both sides and throughout the whole length of the spine, there is formed a double series of arterial arches behind the bodies of the vertebræ, the convexities of which are turned towards each other. From the arches on opposite sides offsets are directed inwards at intervals to reinforce a median longitudinal vessel, which extends along the spine like the single artery on the front of the spinal cord. The arches are moreover joined



together across the bodies of the vertebræ by transverse branches. Other small twigs pass backwards from the spinal branch, and anastomosing with their fellows form an irregular network on the anterior surface of the arches of the vertebræ and the ligamenta subflava. From these interlacings numerous minute ramifications proceed to the ligaments, the periosteum and the bones.

The **basilar artery (iii)**, the single trunk formed by the junction of the right and left vertebral arteries, extends from the lower to the upper border of the pons Varolii, along the median groove of which it lies under cover of the arachnoid. The length of this artery is therefore about equal to the depth of the pons, at the upper border of which it ends by dividing into the two posterior cerebral arteries.

*Branches.*—Besides numerous small branches to the substance of the pons, the basilar artery gives off the following :—

(a) The *transverse arteries*, several on each side, pass directly outwards. One, the *auditory artery*, accompanies the nerve of the same name into the internal auditory meatus and supplies the labyrinth of the ear.

(b) The *anterior (inferior) cerebellar arteries* (vi) pass backwards, one on each side, to the anterior part of the under surface of the cerebellum, anastomosing with the inferior cerebellar branches of the vertebral arteries.

(c) The *superior cerebellar arteries* (v) arise so close to the bifurcation of the basilar, that this artery is often described as dividing into four branches. Each one passes outwards immediately below the third nerve, and, entering the groove between the pons Varolii and the crus cerebri, turns backwards round the latter, close to the fourth nerve, to reach the upper surface of the cerebellum, where it divides into branches. Of these, some extend outwards, and one or more backwards along the superior vermiform process, to reach the circumference of the cerebellum, where they anastomose with the branches of the inferior cerebellar artery; while others run inwards to supply the vermiform process and the valve of Vieussens, and in part the velum interpositum.

The **posterior cerebral artery (iv)** passes outwards, on each side, parallel to the superior cerebellar artery, and separated therefrom at its origin by the third nerve, which comes forwards between the two vessels. It turns backwards round the crus cerebri, giving outwards its anterior and posterior temporal branches to the temporal lobe of the cerebral hemisphere, and then crosses the uncinate gyrus, passing below the splenium of the corpus callosum, to enter the calcarine fissure (fig. 347). It furnishes the postero-mesial and postero-lateral groups of central arteries, as well as one or two posterior choroid arteries, and its terminal branches supply the occipital lobe of the cerebrum (see p. 415).

*Varieties.*—The basilar artery is originally formed by the coalescence of two separate vertebral arteries, and traces of a septum are sometimes found in its interior. The occurrence of a perforation of the vessel, which is occasionally seen, may be likewise attributed to the incomplete fusion of the two arteries.

The posterior cerebral artery is sometimes given off on one side from the internal carotid, by an enlargement of the posterior communicating branch (p. 412).

**2. Thyroid axis (ii).**—The thyroid axis springs from the fore part of the subclavian artery, close to the inner side of the anterior scalenus muscle. It is a short thick trunk, and receives the name of “axis,” because, two or three lines from its origin, it divides into branches which diverge in different directions: these are—the inferior or ascending thyroid, the suprascapular, and a third branch, which is either the transverse cervical, or one of the branches into which that artery, when present, divides, viz., the superficial cervical.

*Varieties.*—The thyroid axis has been seen arising beyond the scalenus anticus muscle. It may be associated at its origin with another branch; most frequently with the internal mammary; rarely with the vertebral, superior intercostal, or deep

cervical artery. In some cases the axis is absent, the three branches arising separately from the subclavian. (On the various modes of origin of the branches usually derived from the thyroid axis, and their relative frequency, see "Second Report of Committee of Collective Investigation of Anat. Soc.," 1890-91, by Arthur Thomson, Journ. Anat., xxvi.)

A. The **inferior thyroid artery (iv)** (fig. 355, p. 433) passes directly upwards in front of the vertebral artery to about the level of the cricoid cartilage, where it bends inwards and downwards behind the sheath of the large cervical vessels, and also behind the sympathetic nerve, the middle cervical ganglion of which, when present, often rests upon this vessel. Then making another curve in the opposite direction, the artery divides behind the lower part of the lateral lobe of the thyroid body into two branches, a *superior* which ascends to supply the hinder part, and an *inferior* distributed to the lower end of the lobe. The artery may cross either in front of or behind the recurrent laryngeal nerve, the former especially frequently on

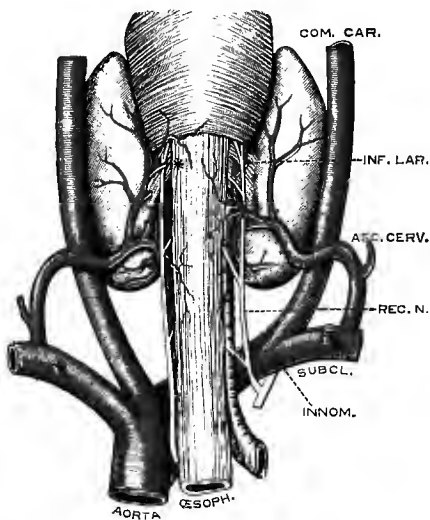


Fig. 352. — DISTRIBUTION OF THE INFERIOR THYROID ARTERY. (Modified from Streck-eisen.) (G. D. T.)

The lateral lobes of the thyroid body are drawn outwards to show the ramifications of the artery. \*, branch of artery piercing the suspensory ligament of the gland to reach the isthmus.

the left side; or the nerve may lie between the divisions of the vessel.<sup>1</sup> The glandular branches of the artery communicate with those of the superior thyroid artery, and with the corresponding artery of the other side.

*Branches.*—(a) *Muscular* branches to the scalenus anticus, longus colli, inferior constrictor of the pharynx, and the infrahyoid muscles.

(b) The *ascending cervical* branch (v) arises at the point where the inferior

thyroid turns inwards behind the carotid artery; it proceeds upwards, close to the phrenic nerve, in the groove between the scalenus anticus and rectus anticus major, giving *muscular* branches to both, and a few which pass transversely outwards across the neck and communicate with others sent outwards from the vertebral artery. Its terminal ramifications anastomose with branches of the occipital and ascending pharyngeal arteries. To the spinal canal the ascending cervical artery often sends two or three *spinal* branches, which enter the intervertebral foramina along the cervical nerves, and assist in supplying the bodies of the vertebræ, and the spinal cord and its membranes.

(c) An *inferior laryngeal* branch ascends with the recurrent nerve to the back of the larynx, and is distributed to the muscles and mucous membrane in that situation.

(d) *Tracheal* branches ramify over the trachea, and anastomose below with the bronchial arteries.

(e) One or more *oesophageal* branches descend upon the oesophagus into the chest, and anastomose with the oesophageal branches of the aorta.

<sup>1</sup> Streckeisen, *op. cit.*, p. 395; T. Dwight, "The Relations of the Inferior Thyroid Artery and the Recurrent Laryngeal Nerve," *Anatom. Anz.*, 1886; Drobnik, "Ueber das Verhältniss des Nervus recurrens zur unteren Schilddrüsenarterie," *Gazeta lekarska*, 1886; K. Taguchi, "Die Lage des Nervus recurrens Vagi zur Arteria thyroidea inferior," *Arch. f. Anat.*, 1889.

**Varieties.**—The inferior thyroid artery occasionally arises as an independent branch from the subclavian; rarely from the common carotid or the vertebral. The primary division of the artery often takes place behind the common carotid, and in rare cases there are two inferior thyroid arteries arising separately from the subclavian. The artery, or one of its divisions, has been seen crossing in front of the common carotid artery. A considerable branch often passes forwards around the upper end of the trachea to the fore part of the thyroid body. The inferior thyroid artery varies much in size, and occasionally is altogether wanting. The several thyroid arteries are developed in inverse proportion to one another, diminution or absence of one being compensated for by an increased size of the others, or by an accessory artery, the *thyroidea ima* (p. 388).

The *ascending cervical artery* is occasionally derived from the subclavian or from one of the other branches of that vessel, as from the transverse cervical or the suprascapular. It is sometimes much larger than usual, and takes the place of the occipital artery. A branch from it not unfrequently compensates for the small size of the deep cervical artery.

**B. The suprascapular artery (iv)** (transverse scapular, or transverse humeral) arises from the thyroid axis, and courses from within outwards, being deeply placed at the root of the neck. At first it descends obliquely towards the clavicle, resting upon the scalenus anticus, and covered by the sterno-mastoid muscle; it then crosses the subclavian artery, and runs transversely outwards behind and parallel with the clavicle to the upper border of the scapula, where it is joined by the suprascapular nerve. Here the nerve passes through the suprascapular notch and beneath the ligament of the same name, but the artery usually crosses over that band, and inclining downwards enters the supraspinous fossa. It gives off branches which ramify beneath the supraspinatus muscle, and is then continued down behind the neck of the scapula into the infraspinous fossa, where it terminates by anastomosing with the dorsal and posterior scapular arteries.

*Branches.*—(a) *Muscular* branches to the sterno-mastoid, subclavius, and other neighbouring muscles.

(b) A *suprasternal* twig crosses the inner end of the clavicle and is distributed to the skin at the upper and mesial part of the chest.

(c) The *medullary artery* of the clavicle enters the canal on the posterior surface of that bone.

(d) The *supra-acromial* branch passes outwards through the attachment of the trapezius to reach the surface of the acromion, on which it ramifies, anastomosing with offsets from the acromio-thoracic artery.

(e) A small *subscapular* branch, given off as the artery passes over the notch, anastomoses with the posterior scapular and subscapular arteries in the subscapular fossa and substance of the subscapularis muscle.

(f) Branches enter the dorsal scapular muscles, the bone and shoulder-joint.

**Varieties.**—The suprascapular artery in some cases springs independently from the second or third part of the subclavian; or it may arise from that vessel by a common trunk with the transverse cervical or posterior scapular, or more rarely with the internal mammary. It has also been found to proceed from the axillary artery, and from the subscapular branch of that vessel. This artery is sometimes very small, in which case the deficiency is supplied by a branch of the posterior scapular or by the dorsal scapular artery.

**C. The transverse cervical artery**, the third branch of the thyroid axis passes outwards a short distance above the clavicle, and therefore higher than the suprascapular artery. It crosses over the scaleni muscles and the brachial plexus, sometimes passing between the nerves of the latter, and is crossed by the omo-hyoid muscle. Beneath the upper margin of the trapezius, and near the anterior edge of the levator anguli scapulæ, it divides into two branches, the superficial cervical and the posterior scapular.

The *superficial cervical artery* (v) ascends beneath the trapezius, and distributes branches to that muscle, the levator anguli scapulæ and splenius muscles, as well as

to the cervical glands and the integument. When the posterior scapular arises separately from the subclavian, the name superficial cervical may be given to the remaining part of the transverse cervical artery.

The *posterior scapular artery* (iv), whether arising from the transverse cervical artery or directly from the subclavian, passes backwards to the upper angle of the

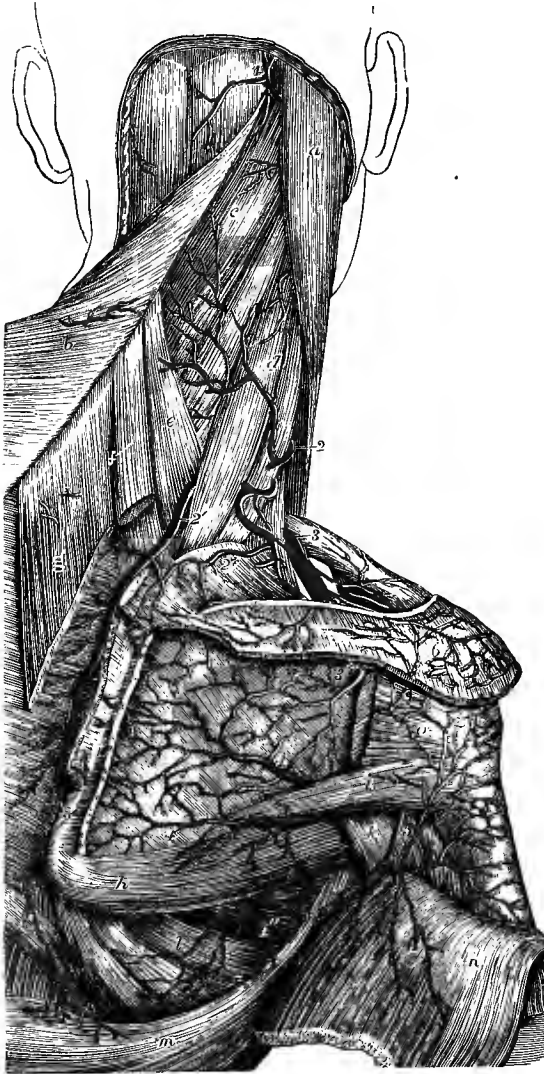


Fig. 353.—THE ARTERIES OF THE SHOULDER AND DORSUM OF THE SCAPULA, WITH THEIR ANASTOMOSES. (Tiedemann.)

$\frac{1}{2}$

*a*, sterno-mastoid muscle; *b*, trapezius, turned inwards; *c*, splenius capitis, and below it splenius colli; *d*, levator anguli scapulae; *e*, serratus posticus superior; *f*, *g*, rhomboideus minor and major, divided near the scapula; *h*, teres major; *i*, teres minor; *k*, long head of triceps; *l*, serratus magnus; *m*, latissimus dorsi; *n*, deltoid muscle, turned down; *o*, portion of infraspinatus muscle attached to the great tuberosity of the humerus, the rest having been removed from the infraspinatus fossa; 1, occipital artery, appearing between the trapezius and sterno-mastoid muscles; 2, superficial cervical artery; 2', 2'', posterior scapular artery; 2 +, its suprascapular branch; 3, suprascapular artery; 3', the same after passing into the infraspinatus fossa, where it anastomoses with 4, the dorsal scapular artery; 4', descending branch of dorsal scapular; 4'', thoracic branches of subscapular artery; 5, posterior circumflex artery, emerging from the quadrangular space, and sending branches upwards to the shoulder-joint, forwards round the humerus, and downwards into the deltoid muscle; 6, anastomosis of acromial branches of suprascapular and acromio-thoracic arteries.

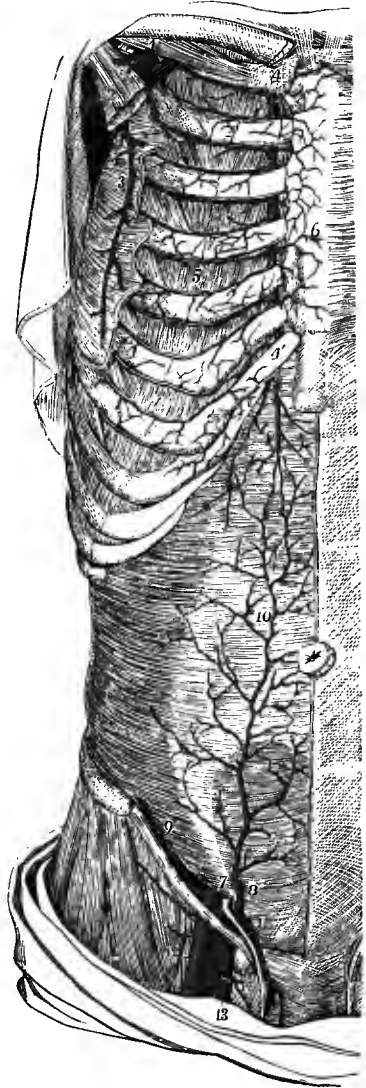scapula, under cover of the levator anguli scapulae, and then, changing its direction, runs downwards beneath the rhomboid muscles, as far as the inferior angle of that bone. It

anastomoses freely on both surfaces of the scapula with the divisions of the suprascapular and subscapular arteries, and supplies branches to the rhomboidei, serratus magnus, and latissimus dorsi muscles, communicating at the same time with the posterior branches of some of the intercostal arteries. Near the upper angle of the scapula this artery gives off a considerable *suprascapular* branch, which ramifies on the surface of the suprascapular and supplies that muscle together with the overlying portion of the trapezius and skin.

**Varieties.**—The transverse cervical branch of the thyroid axis not unfrequently consists solely of the superficial cervical artery; and it often happens that the vessel derived from the thyroid axis is very small, and represents only in part the superficial cervical artery, a large vessel being given off from the second or third part of the subclavian and dividing near the levator anguli scapulae into two branches, of which one ascends and represents

Fig. 354.—DISSECTION OF THE ANTERIOR THORACIC AND ABDOMINAL WALL, TO SHOW THE ANASTOMOSES OF THE INTERNAL MAMMARY, INTERCOSTAL, AND EPI-GASTRIC ARTERIES. (Allen Thomson, after Tiedemann.)  $\frac{1}{4}$

The fore part of the serratus magnus, the external and internal oblique, and the rectus abdominis muscles have been removed. 1, upon the subclavius muscle, points to the first part of the axillary artery, giving rise to the acromio-thoracic artery, which is cut short; 2, upon the pectoralis minor, points to the lower part of the axillary artery and vein; 3, long thoracic artery; 4, on the cartilage of the first rib, the upper part of the internal mammary artery; 4', the lower part of the same artery, giving its abdominal branch behind the cartilage of the seventh rib; 5, in the fourth intercostal space, the anastomosis of the internal mammary and intercostal arteries; 6, perforating branches of the internal mammary artery sending offsets over the front of the sternum; 7, on the transversalis muscle immediately above the internal abdominal ring, points to the last part of the external iliac artery, from which are seen arising, 8, the deep epigastric artery, and 9, the deep circumflex iliac; 10, the anastomosis of the epigastric with the abdominal branch of the internal mammary artery; 11, spermatic cord and cremasteric twig of the epigastric artery; 12, femoral artery; 13, femoral vein; 14, a lymphatic gland in the femoral ring.



the larger portion of the superficial cervical artery, while the other forms the posterior scapular.

The transverse cervical artery is sometimes derived directly from the subclavian, beneath or even beyond the scalenus anticus muscle. The transverse or superficial cervical sometimes gives off the ascending cervical artery.

When the *superficial cervical* is separated from the posterior scapular, it sometimes arises from other sources than the thyroid axis, as from the suprascapular or the subclavian artery.

### 3. Internal mammary artery (iv).—

The internal mammary artery, remarkable for its length and the number of its branches, arises from the lower and fore part of the subclavian, opposite the thyroid axis. It runs at first forwards and downwards, as well as slightly inwards, to the hinder surface of the cartilage of the first rib, lying between this and the sac of the pleura; from this point it descends vertically behind the costal cartilages, about half an inch from the border of the sternum, as far as the interval between the sixth and seventh cartilages, where it ends by dividing into two branches, which are known as the musculo-phrenic and superior epigastric arteries. The internal mammary artery is covered at its origin by the subclavian vein; and as it passes forwards it arches round the upper end of the innominate vein, and is crossed from without inwards by the phrenic nerve. In the chest it has the costal cartilages and the internal intercostal muscles, as well as the

upper six intercostal nerves, in front ; it lies at first upon the pleura, but lower down it is separated therefrom by the triangularis sterni muscle. This artery has two companion veins, which are united into a single trunk at the upper part of the chest.

*Branches.*—(a) The *superior phrenic artery* or *comes nervi phrenici*, a long slender branch, arises from the artery at the upper part of the thorax, and descends, in company with the phrenic nerve, between the pleura and pericardium, to the diaphragm. It gives small offsets to the pericardium ; and its terminal branches supply the fore part of the diaphragm and anastomose with the inferior phrenic (from the aorta) and musculo-phrenic arteries.

(b) The *mediastinal* branches, of very small size, ramify in the loose connective tissue of the mediastinal space, and supply the thymus body or its remains. *Pericardial* branches are given off to the pericardium ; and branches named *sternal* are supplied to the triangularis sterni muscle, and to the posterior surface of the sternum. These small vessels form with offsets from the superior phrenic, bronchial, and intercostal arteries a fine wide-meshed network beneath the pleura, to which Turner has given the name of *subpleural mediastinal plexus*.<sup>1</sup>

(c) The *anterior intercostal arteries*, two in each of the upper six spaces, arise from the internal mammary, either separately, or by a trunk common to the two, which soon divides. The arteries pass outwards, at first between the pleura and the internal intercostal muscles, and afterwards between the two layers of intercostals ; they lie, one near the upper and one near the lower rib, and inosculate with the corresponding branches derived from the aortic intercostals. These branches supply the intercostal and pectoral muscles, and give some offsets to the mamma and integument.

(d) The *anterior* or *perforating* branches pass forwards through the upper six intercostal spaces, and turning outwards ramify partly in the pectoralis major, and partly in the integument on the front of the chest. Those placed nearest to the mammary gland supply that organ, and in the female they are of comparatively large size, especially during lactation. Some small offsets ramify on the sternum.

(e) The *musculo-phrenic artery*, the outer of the two branches into which the internal mammary divides, inclines downwards and outwards behind the cartilages of the false ribs, perforating the attachment of the diaphragm, and becoming gradually reduced in size as it reaches the tenth cartilage. It gives branches backwards into the diaphragm ; others, which pass outwards to form the anterior intercostals of the seventh, eighth and ninth spaces, and are disposed like those which are derived higher up from the main trunk ; and some which descend into the abdominal muscles.

(f) The *abdominal* branch, or *superior epigastric artery*, descends between the sternal and costal portions of the diaphragm into the wall of the abdomen, where it lies at first behind the rectus, between the muscle and its sheath ; afterwards, entering the muscle, the artery terminates in its substance, and anastomoses with the epigastric artery from the external iliac. It supplies branches to the broad muscles of the belly, to the skin, and to the diaphragm ; one offset runs forwards upon the front of the ensiform process, and anastomoses with that of the opposite side ; and small twigs pass backwards into the falciform ligament of the liver and form communications with the hepatic artery.

*Varieties.*—The internal mammary artery is sometimes found connected at its origin with the thyroid axis, or with one or both of the scapular arteries—these being detached from the thyroid. It occasionally springs from the second or third part of the subclavian artery, the latter being the more frequent position of the two. In very rare instances it has been found

<sup>1</sup> Brit. and For. Med. Chir. Rev., Jan., 1865.

arising from the axillary, the innominate, or the aorta. The trunk of the artery has been seen to cross the front of the fifth or sixth costal cartilage.

An unusual *lateral* branch, of considerable size, occasionally comes off from the upper part of this artery, and passes downwards and outwards, crossing several of the ribs, on their inner surface, about midway between the spine and sternum, or somewhat farther forwards. The internal mammary artery may likewise furnish a bronchial branch.

**4. Superior intercostal artery (iv).**—This artery arises from the back part of the subclavian, generally behind the anterior scalenus on the right side, and immediately internal to that muscle on the left. Taking its course backwards and at first slightly upwards, it speedily gives off the deep cervical branch, and then bends downwards in front of the neck of the first rib, to be distributed in the first and second intercostal spaces. On the neck of the first rib, the artery is situated between the first thoracic ganglion of the sympathetic internally and the anterior primary division of the first dorsal nerve externally.

The branches of the first and second intercostal spaces are distributed in the same way as the intercostal arteries derived from the aorta (p. 455), and that in the second space is frequently joined by an offset from the first aortic intercostal.

**Varieties.**—The superior intercostal artery has been found, in a few instances, to proceed from the vertebral artery or from the thyroid axis. It has also been observed to descend between the necks of one or two ribs and the transverse processes of the corresponding dorsal vertebra; and in one case, after arising from the vertebral artery, it passed in addition through the foramen in the transverse process of the last cervical vertebra (R. Quain, pl. 22, fig. 5). This artery is sometimes, though very rarely, wanting. On the other hand it may be larger than usual, and supply three or even four spaces. It has been seen to furnish a lateral branch descending on the inner surface of the ribs, similar to that occasionally derived from the internal mammary artery (Blandin).

The **deep cervical artery** (fig. 351, 6), often described as a separate branch of the subclavian, arises in most cases from the superior intercostal. Resembling the posterior branch of an aortic intercostal artery, it passes backwards in the interval between the transverse process of the last cervical vertebra and the first rib, to reach the posterior aspect of the neck, where it ascends under cover of the complexus muscle, and resting upon the semispinalis colli, to the level of the axis. Its branches supply the surrounding muscles, and anastomose with offsets of the vertebral, the cervical branch of the occipital, and the ascending cervical arteries. A *spinal* branch enters the canal with the last cervical nerve.

**Varieties.**—The deep cervical artery sometimes arises separately from the subclavian; more rarely from the posterior scapular. It occasionally passes back between the sixth and seventh cervical vertebra, and sometimes between the first and second dorsal, or even below the second. It has been seen to pass between the first rib and the transverse process of the first dorsal vertebra. This artery is not unfrequently supplemented by a branch of the ascending cervical artery, turning backwards between two of the cervical transverse processes; or by an enlarged dorsal branch from the superior intercostal artery in the first space; or in rare instances by an offset from the posterior scapular or inferior thyroid artery.

#### SURGICAL ANATOMY OF THE SUBCLAVIAN ARTERIES.

The depth of the subclavian artery, its intimate and numerous connections with important parts, and the large size of its branches, render operations on this vessel peculiarly difficult.

The *third division* of the artery, situated beyond the anterior scalenus muscle, is the part which is most favourably circumstanced for the application of a ligature, inasmuch as the vessel is here nearest to the surface, and the spot selected is remote from the origin of the large branches. The artery is generally easy of access above the clavicle while the parts are in their natural position, but when they are displaced by an aneurism in the axilla, the clavicle may be so much elevated by the tumour as to be placed in front of the

vessel, or even above it; and such a condition may require special modifications of the operation.

In the operation of passing a ligature round the third part of the subclavian artery, an incision is made a little above and parallel to the middle third of the clavicle; and in doing this, if the integument be drawn downwards over the clavicle, the parts covering the bone may be divided with freedom.

Along with the integument, the platysma and some descending superficial nerves are divided in this incision, but no vessel is endangered, except in those rare instances in which the cephalic vein or the external jugular crosses over the clavicle. It will, in some cases, be an advantage to add a short vertical incision, directed downwards to the middle of the horizontal one. Should the clavicular attachment of the sterno-mastoid or trapezius muscle be broader than usual, so that the interval between the two is insufficient for the farther steps of the operation, a portion of one, or even of both muscles, must be divided.

The external jugular vein, joined by the veins from the shoulder, is usually over the artery, and it must be held aside, or if necessary divided between two ligatures. The lower end of the vessel requires the application of a ligature as well as the upper one, in consequence of the reflux of blood from the subclavian vein, and the danger of air being drawn into the circulation. The omo-hyoid muscle will also be drawn upwards if necessary, but as a rule it is not exposed. The artery is now covered only by the areolar tissue of the supra-clavicular fossa and a layer of the deep cervical fascia (upper part of the axillary sheath), and in making the deeper dissection to reach the vessel, it will be best to divide these structures cautiously with a director or some blunt instrument, in order to avoid wounding the veins which pass inwards above the clavicle. At this stage of the operation the anterior scalenus muscle should be sought for, as it forms the best guide to the artery. This will be found descending nearly vertically behind the clavicular head of the sterno-mastoid, and if the finger be carried down along the outer border of the muscle, it will pass over the front of the artery, and reach the more or less prominent scalene tubercle on the upper surface of the first rib, which in cases of difficulty is of service as a farther guide to the vessel. The part of the artery to which the ligature is to be applied is placed above, and at the same time somewhat to the outer side of and behind the tubercle. The nerves of the brachial plexus are here very close to the artery, and great care is necessary in separating the lowest trunk from the vessel. The artery is to be distinguished by its becoming flattened beneath the finger, while the nerves have a rounded cord-like feel, and (in the living subject) by its pulsation, although it is to be observed that this movement is frequently transmitted to the adjacent nervous trunk owing to the close connection of the two structures. The needle should be passed from behind forwards in order to avoid the nerves, as the vein is placed at some little distance below and in front of this part of the artery, and ordinarily does not come into view during the operation. The nerve to the subclavius may be exposed on the front of the artery, and if so it is to be carefully preserved, since it not unfrequently furnishes an accessory root to the phrenic nerve. The latter nerve itself has also been seen crossing the third part of the artery.

With reference to the choice of the exact place at which the ligature is to be passed round this part of the artery, it should always be borne in mind that in the majority of cases a considerable branch is given off from the main trunk in the immediate neighbourhood of the outer border of the scalenus muscle. This branch is most frequently the posterior scapular; but in rarer cases it may be the transverse cervical or suprascapular, or even the internal mammary.

The *second division* of the subclavian artery is the part which rises highest in the neck, and on this account it may be advantageously selected for the application of a ligature when the vessel is difficult of access beyond the muscle. The chief objections to operating on this part of the artery arise from the contiguity of the large branches, and its close connection with the pleura. The steps of the operation are similar to those described above, but the primary incision is made somewhat farther inwards, and it will be necessary to divide the clavicular head of the sterno-mastoid and the scalenus anticus muscles. In doing this, care must be taken not to injure the anterior jugular vein and the phrenic nerve, and it is farther advisable not to carry the incision through the whole breadth of the scalenus, but to leave the inner portion of the muscle undivided, in order to avoid wounding the internal jugular vein or the branches of the thyroid axis.

Difficulties may arise from the occurrence of an unusual position of the artery, as when it passes through the substance of the anterior scalenus, or when it is in front of that muscle; but such cases are of very rare occurrence.

The *first part* of the subclavian artery on the left side may be said to be inaccessible for the application of a ligature, in consequence of its depth and its close connection with the lung and other important structures, such as the internal jugular and innominate veins, and the thoracic duct.



On the right side, though deeply placed and closely connected with important parts, the first division of the subclavian artery may be tied in the interval between the common carotid artery and the internal jugular vein without extreme difficulty. But inasmuch as the distance between the bifurcation of the innominate on the one hand, and the origin of the vertebral artery on the other, seldom measures more than an inch, and is often much less, the success of the operation is exceedingly doubtful.

In order to place a ligature on the portion of the right subclavian artery here referred to, it is necessary to divide the three muscles which cover it, together with the layers of fascia between and beneath them. In doing this the anterior jugular vein must be avoided, and the suprasternal branch of the suprascapular artery will probably require to be secured. In the farther steps of the operation, the exact relations of the artery to the internal jugular, vertebral and innominate veins, the pneumo-gastric nerve with its recurrent branch, and the pleura, are to be well kept in view.

It is to be remembered also that the first part of the right subclavian artery is occasionally more deeply placed than usual; as in those cases in which it springs from the back part of the aortic arch, or, more frequently, when it merely separates from the innominate behind the carotid.

The circulation in the subclavian artery may be arrested by pressure directed backwards and downwards in the suprascapular fossa, so as to compress the third part of the vessel against the subjacent first rib.

*Collateral circulation.*—After ligature of the third part of the subclavian artery, blood is supplied to the upper limb through the anastomoses upon the scapula between the suprascapular, posterior scapular and subscapular arteries, and those formed by branches of the internal mammary and intercostal arteries with the thoracic branches of the axillary artery. After ligature of the first part of the artery, blood is conveyed to the distal portion of the trunk mainly by the vertebral artery, to a less extent by the inferior thyroid, internal mammary and superior intercostal arteries: the axillary artery receives blood also through the anastomoses formed by its thoracic branches, and the fore part of the thoracic wall is supplied by the intercostal and epigastric arteries.

#### AXILLARY ARTERY (I).

The axillary artery is that part of the artery of the upper limb which extends from the outer border of the first rib to the lower margin of the teres major muscle. In this course it passes through the axilla, lying to the inner side of the shoulder-joint and upper part of the humerus, and its direction varies with the position of the limb, being curved downwards or upwards, or being straight, according as the arm hangs by the side, or is elevated to a greater or less degree. With the arm raised to the level of the shoulder, a line drawn from the most prominent part of the clavicle to the inner side of the eminence formed by the biceps and coracobrachialis muscles will indicate the position of the vessel.

The axillary artery is crossed in front by the pectoralis minor muscle, and is thus conveniently divided into three parts: the first part lies above the pectoralis minor and is about one inch long; the second part, placed behind that muscle, is somewhat longer; and the third part, beyond it, is rather over three inches in length.

In the **FIRST PART** of its course the artery is deeply placed, being covered by the pectoralis major, by a quantity of areolar and fatty tissue, and by a prolongation of the costo-coracoid membrane, as well as by the lower part of the subclavius muscle when the shoulder is depressed. This part of the artery is also invested by the axillary sheath, a membranous structure continued downwards from the deep cervical fascia (p. 298) and surrounding both the trunks of the vessels and the brachial plexus of nerves. It rests upon the first intercostal space and the first digitation of the serratus magnus. The *axillary vein* lies to the inner side and somewhat in front of the artery, and the *cephalic* and *acromio-thoracic veins* cross it to reach the main trunk. The *nerves of the brachial plexus* are to the outer side, the *external anterior thoracic nerve* crosses in front, and the *internal anterior thoracic* and *posterior thoracic nerves* pass behind it.

In the **SECOND PART** of its course the artery is covered in front by the pectoralis

major and minor muscles; the *vein* is on its inner side; and the *three cords of the brachial plexus* are placed, one on the outer side, the second behind, and the third on the inner side, the last, together with the *internal anterior thoracic nerve*, intervening between the artery and vein.

The *third part* of the axillary artery is covered anteriorly for the upper half of its extent by the pectoralis major muscle; in its lower half it is superficial, being placed immediately beneath the deep fascia of the arm, and here the flow of blood in the vessel may be readily controlled by pressure directed from within outwards against the humerus. It rests upon the subscapularis muscle and the tendons of the latissimus dorsi and teres major; and on its outer side is the coraco-brachialis muscle.

The *axillary vein* is still on its thoracic side, and the lower portion of the artery is accompanied also by one or both of the *brachial venæ comites*. The nerves resulting from the division of the brachial plexus are disposed around the artery as follows, viz., behind are the *circumflex* and *musculo-spiral*; to its inner side the *ulnar* (between the artery and vein), and the *small internal cutaneous* (internal to the vein); to its outer side the *external cutaneous* and *median*; while the *large internal cutaneous* is usually in front of the artery, and the *inner head of the median* crosses it obliquely from within outwards.

BRANCHES.—The branches of the axillary artery are very variable in their number, size, and mode of origin. They comprise *thoracic* branches furnished to the muscles of the chest, the *subscapular* branch to the shoulder, and two *circumflex* branches to the upper part of the arm. Small irregular twigs are also given to the serratus magnus, subscapularis and coraco-brachialis muscles, and to the skin. One more constant branch passes through the loop formed by the two heads of the median nerve to the pectoral muscles and the upper part of the biceps, and is often continued downwards to anastomose with the bicipital branch of the brachial artery.

1. The **superior** or **short thoracic artery** is a small branch, which arises near the lower border of the subclavius muscle. It inclines downwards and inwards across the first intercostal space, and terminates in the two pectoral muscles, giving off also branches which supply the upper part of the serratus magnus and the subjacent intercostal muscles, and anastomose with the intercostal arteries.

2. The **acromio-thoracic artery**, of considerable size, and the most constant of the thoracic branches of the axillary artery, arises from its fore part at the upper border of the pectoralis minor muscle, and soon divides into branches which take different directions.

(a) The *acromial* branches pass partly to the deltoid and partly through that muscle to the upper surface of the acromion, forming anastomoses with the supra-scapular and posterior circumflex arteries.

(b) The *descending* or *humeral* branch passes down in company with the cephalic vein in the interval between the pectoralis major and deltoid muscles, and is distributed to their margins, and to the integument.

(c) The *thoracic* branches are distributed to the serratus magnus and pectoral muscles, and anastomose with the other thoracic arteries.

(d) The *clavicular* branch, very small, passes upwards to the subclavius muscle.

3. The **long thoracic artery** (external mammary) is directed downwards and inwards, along the lower border of the pectoralis minor, and is distributed to the serratus and pectoral muscles, and to the mamma, forming anastomoses with branches of the intercostal arteries.

4. The **alar thoracic** branch is a very small vessel and not constant, its place being frequently supplied by branches from the thoracic and subscapular arteries. It is distributed to the lymphatic glands and the fatty tissue in the axilla.

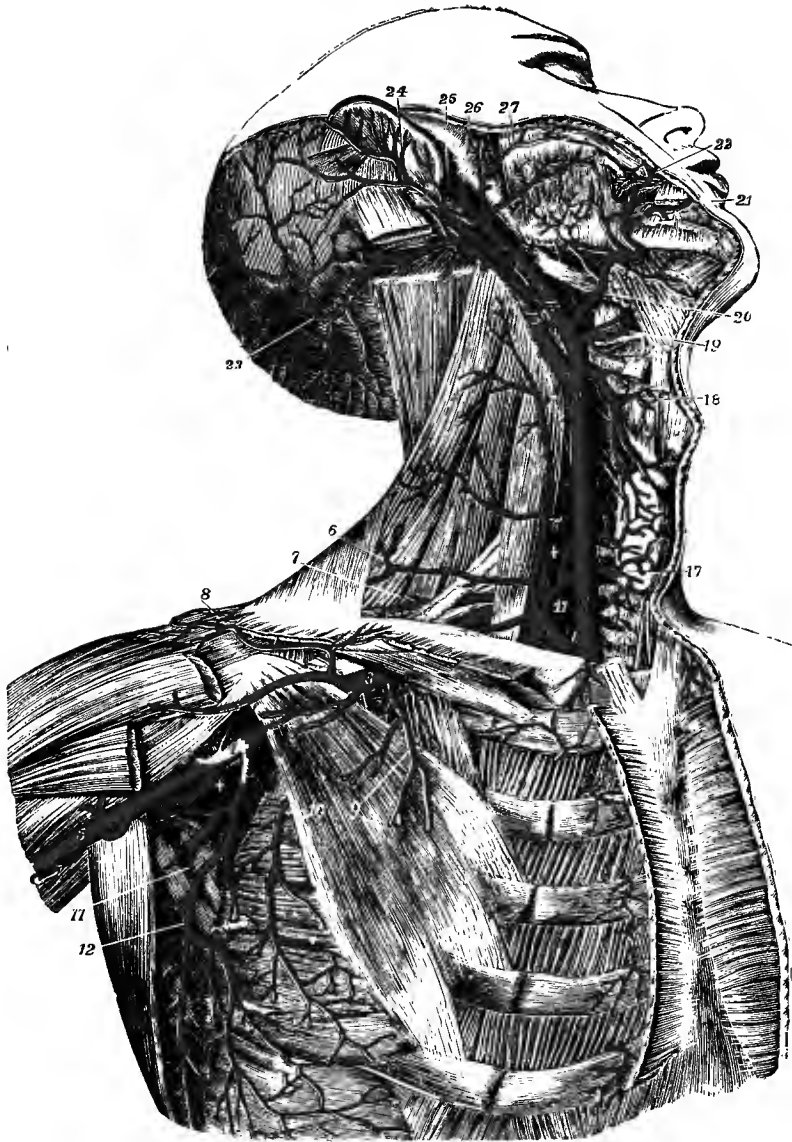


Fig. 355.—THE CAROTID, SUBCLAVIAN, AND AXILLARY ARTERIES. (Tiedemann.)  $\frac{1}{2}$

The great pectoral, sterno-mastoid, sterno-hyoid and sterno-thyroid muscles have been removed; the front part of the deltoid has been divided near the clavicle. *Subclavian artery and its branches.*—1, first part of subclavian artery giving rise to the thyroid axis and internal mammary, and also to +, the vertebral artery; 2, third part of subclavian artery; 3, first part of axillary artery; 4, third part of axillary artery; 5, commencement of brachial artery; 6, superficial cervical artery giving off in this instance 6', the ascending cervical branch; 7, posterior scapular artery, arising from the subclavian behind the scalenus anticus; 8, acromial branch of acromio-thoracic; 9, superior thoracic, in this case of large size; 10, long thoracic artery below the pectoralis minor muscle; +, posterior circumflex branch of the axillary artery (the anterior circumflex is seen arising from the opposite side of the same part of the axillary trunk); 11, dorsal scapular artery, passing backwards between the subscapularis and teres major muscles; 12, continuation of the subscapular artery. For explanation of references 13 to 27, see p. 400.

5. The **subscapular artery** (iv), the largest branch of the axillary artery, arises near the lower border of the subscapularis muscle, along which it proceeds downwards and backwards, towards the inferior angle of the scapula, accompanied by the long subscapular nerve. It soon becomes considerably diminished in size, owing to its giving off a large branch to the dorsum of the scapula, and it terminates in branches to the subscapularis, serratus magnus, teres major and latissimus dorsi muscles. Its final ramifications anastomose with the long thoracic, the intercostal, and the posterior scapular arteries.

The *dorsal* branch leaves the subscapular artery about an inch from its origin, and is commonly larger than the continuation of the vessel. Directed backwards through the triangular interval bounded above by the subscapularis, below by the teres major, and externally by the long head of the triceps muscle, and turning closely round the border of the scapula, which is commonly grooved to receive it, it

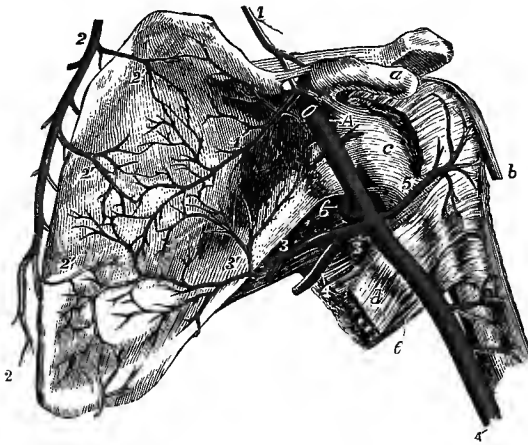


Fig. 356. — ANASTOMOSES OF THE ARTERIES OF THE VENTRAL SURFACE OF THE SCAPULA, &c. (R. Quain.)  $\frac{1}{2}$

a, coracoid process; b, tendon of long head of biceps; c, capsular ligament of shoulder-joint; d, tendon of latissimus dorsi; e, teres major; A, axillary, and A', brachial artery; 1, suprascapular artery, giving off 1', its subscapular branch, as it passes over the suprascapular ligament; 2, 2, posterior scapular artery; 2', 2', its ventral branches; 3, 3, stem of the subscapular artery at its origin from the axillary, continued into the dorsal scapular artery, which is turning to the back of the scapula, and gives off 3', its ventral branch, proceeding to anastomose with the ventral branches of the suprascapular and posterior scapular arteries; 4,

thoracic division of the subscapular artery; 5, anterior circumflex artery; 6, posterior circumflex, in this case arising above the subscapular, and passing back through the quadrilateral intermuscular space.

passes between the teres minor and the bone and ramifies in the infraspinous fossa, where it anastomoses with the suprascapular and posterior scapular arteries (fig. 353).

The dorsal scapular artery gives off, as it passes through the triangular space, one or two slender *ventral* branches (fig. 356, 3'), which ramify in the subscapular fossa beneath the subscapularis muscle, and anastomose with twigs from the suprascapular and posterior scapular arteries; and a considerable *descending* branch (fig. 353, 4') which runs in the groove between the origins of the teres minor and major, supplying both muscles, to the lower angle of the scapula. Small offsets are also furnished to the long head of the triceps and the hinder part of the deltoid muscle.

6. The **posterior circumflex artery**, a considerable vessel but smaller than the subscapular, immediately below which it arises, is directed backwards in company with the circumflex nerve, passing through the quadrilateral space between the teres muscles, the humerus, and the long head of the triceps, and therefore separated by the last from the dorsal scapular artery. It winds round the humerus, and terminates by ramifying in the deltoid muscle, giving branches also to the shoulder-joint, to the teres muscles, to the long and outer heads of the triceps, and to the skin, and anastomosing with the anterior circumflex and acromio-thoracic arteries, as well as with the superior profunda branch of the brachial.

**7. The anterior circumflex artery**, much smaller than the posterior, arises nearly opposite that from the outer side of the axillary artery. It passes outwards, beneath the inner head of the biceps and the coraco-brachialis muscle, and resting on the fore part of the humerus, until it reaches the bicipital groove. There it divides into two branches, of which one ascends in the groove with the long head of the biceps to the head of the bone and the capsule of the joint, while the other continues outwards, and anastomoses with the posterior circumflex branch.

**Varieties.**—The most important variety in the trunk of the axillary artery consists in its giving off a much larger branch than usual,—an arrangement which has been observed in the proportion of one out of every ten cases. In one set of cases this large branch is continued as one of the arteries of the forearm, most frequently the radial (about 1 in 33), sometimes the ulnar (1 in 72), less frequently a *vas aberrans*, and very rarely the interosseous artery. In another set of cases the large branch gives origin to the subscapular, the two circumflex, and the two profunda arteries of the arm; but sometimes only one of the circumflex, or only one of the deep humeral arteries arises from it. In the second class of cases the divisions of the brachial plexus of nerves surround the common stem of the branches instead of the main vessel. This disposition may be explained by supposing that the stem of the branches was originally the brachial artery, but that in early life it had become obstructed in its distal part, and that there had become developed in its place, as an apparent brachial artery for the supply of the lower portions of the limb, a *vas aberrans*, such as is sometimes seen arising from the brachial artery and uniting with one of its branches (p. 440). The proximal portion of this aberrant vessel is represented normally by the muscular branch passing through the loop of the median nerve.

The superior thoracic artery is so frequently given off by the acromio-thoracic, that some anatomists have described that as the normal arrangement, giving the common trunk the name of *thoracic axis*. The long thoracic artery often arises from the acromio-thoracic, or is replaced by enlargement of the normal branches of that artery, and not unfrequently is given off by the subscapular.

The subscapular artery is often united at its origin with the posterior circumflex: on the other hand, the dorsal scapular branch sometimes springs directly from the axillary artery.

The posterior circumflex artery is sometimes removed from the axillary to the superior profunda branch of the brachial, in which case it ascends behind the *teres major* muscle. In another class of cases, not quite so numerous, the posterior circumflex gives off one or more branches usually derived from other sources: as for example (placing them in the order of frequency), the anterior circumflex, the superior profunda, the dorsal scapular, the anterior circumflex and superior profunda together, or some other rarer combination of those vessels. The posterior circumflex is sometimes double; and so is the anterior, but more seldom.

An accessory *external mammary* branch is not unfrequently present, arising from the axillary beyond the circumflex arteries, and running downwards and inwards to the side of the chest behind the long thoracic. The following branches, usually derived from the subclavian artery, have been seen in rare cases to arise from the axillary, viz., internal mammary, suprascapular, and posterior scapular; as have also the superior profunda, inferior profunda, and anastomotic arteries, normally branches of the brachial.

The third part of the axillary artery is frequently crossed by a muscular slip (axillary arch) passing from the *latissimus dorsi* to the anterior wall of the axilla (p. 205).

#### SURGICAL ANATOMY OF THE AXILLARY ARTERY.

The artery is usually tied in the third part of its course, as it lies upon the tendon of the *latissimus dorsi*. The limb having been carried away from the chest, an incision is made parallel to and a little behind the anterior fold of the axilla. On cutting through the deep fascia the vein is exposed, and by drawing this downwards the artery is brought into view, surrounded by the nerves from the brachial plexus. The ligature is to be passed from within outwards. Another and simpler mode of operating is that recommended by Malgaigne, according to which the incision is made along the inner border of the coraco-brachialis muscle, and the median nerve then serves as a guide to the artery, while the vein is not exposed. In the rest of its course the artery is so deeply placed, and in such close relation with the vein and nerves, that an operation on the third part of the subclavian is both easier and more successful.

**Collateral circulation.**—After ligation of the third part of the axillary artery, the circulation in the upper limb is carried on by means of the anastomoses of the posterior circumflex and superior profunda arteries, and of smaller branches of the axillary and brachial arteries in the coraco-brachialis, biceps, and triceps muscles.

## BRACHIAL ARTERY (II).

The brachial or humeral artery, the continuation of the axillary, extends from the lower border of the *teres major* muscle to about a finger's breadth below the bend of the elbow, or to a point opposite the inner border of the neck of the radius, where it divides into the radial and ulnar arteries. The artery gradually inclines from the inner side to the fore part of the limb, lying in the depression along the inner border of the *coraco-brachialis* and *biceps* muscles; and a line drawn on the surface of the arm along this hollow will indicate the course of the vessel. To command the flow of blood through the artery at its upper part pressure should be directed outwards, while over the lower end of the vessel the pressure should be made from before backwards.

The brachial artery lies beneath the integument and fascia of the arm as far as the bend of the elbow, where it sinks deeply in the interval between the *pronator teres* and *supinator longus* muscles, and is covered by the semilunar fascia of the

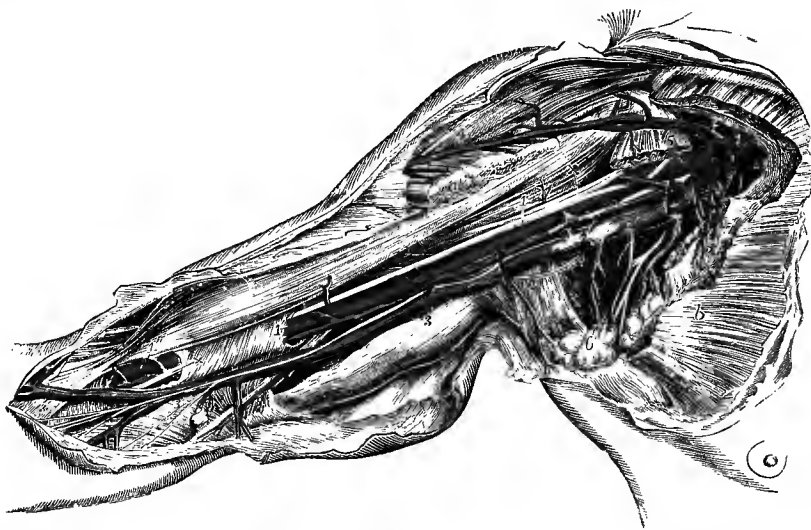


Fig. 357.—DISSECTION OF THE AXILLA AND INNER SIDE OF THE ARM, TO SHOW THE AXILLARY AND BRACHIAL VESSELS. (R. Quain.)  $\frac{1}{2}$

Portions of the pectoral muscles have been removed so as to expose the axillary vessels: *a*, insertion, and *b*, origin of the *pectoralis major*; 1, 1, axillary artery; 1', placed on a part of the sheath of the brachial vessels, and 1'', on the lower part of the *biceps* muscle, point to the brachial artery embraced by its *venæ comites*; 2, 2, axillary vein; 3, 3, basilic vein; the upper figure is placed on the *triceps* muscle, the lower on the fascia near the junction of the ulnar veins; on the basilic vein is the internal cutaneous nerve; +, +, median nerve; 4, on the *deltoid*, and 4', near the clavicular part of the great pectoral muscle, mark the cephalic vein joining the axillary vein; 5, 5, on the divided portions of the *pectoralis minor*, point to the origin and branches of the *acromio-thoracic* artery; 6, on a group of axillary glands, indicates the *alar thoracic* and *subscapular* vessels; 7, on the trunk of the axillary vein, points to one of the *brachial venæ comites*, which, being joined by the other higher up, passes into the axillary vein; the ulnar nerve is seen passing behind the basilic vein towards the inner condyle; near 1, on the *coraco-brachialis*, is the *musculo-cutaneous* nerve before it passes through that muscle; near 2, on the tendon of the *latissimus dorsi*, a portion of the nerve of *Wrisberg*.

*biceps*. It rests at first, for a short distance, on the long head of the *triceps*, the *musculo-spiral* nerve and the *superior profunda* artery intervening, and then on the inner head of the same muscle; at the middle of the arm it crosses the insertion of the *coraco-brachialis* muscle; and in the rest of its course it lies on the *brachialis anticus*. On its outer side it is in apposition first with the *coraco-brachialis*, and

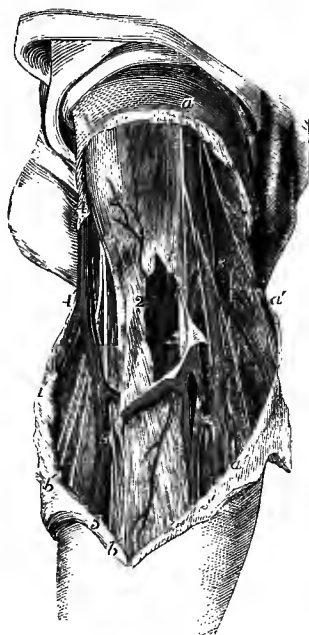afterwards and for the greater part of its length with the biceps, the inner border of one or both muscles overlapping it to a greater or less extent according to the muscular development of the individual.

*Relation to veins.*—Two *venæ comites* are in close contact with the brachial artery, short transverse branches of communication passing between them, so as at many points to encircle it. The *basilic vein* is placed to the inner side of the artery, but is separated from it by the deep fascia of the limb in the lower half or more, according to the level at which the vein perforates that membrane; and at the bend of the elbow the *median-basilic vein* crosses over the artery, the semilunar fascia of the biceps lying between them.

*Relation to nerves.*—The *median nerve* descends in contact with the artery, lying on its outer side in the upper half of the arm, directly in front of it below the

Fig. 358.—SUPERFICIAL DISSECTION OF THE BLOOD-VESSELS AND NERVES AT THE FRONT OF THE ELBOW. (R. Quain.)  $\frac{1}{2}$

*a*, internal cutaneous nerve; *a' a''*, descending twigs of the same nerve; *b*, placed over the biceps near its insertion and close to the external cutaneous nerve; *b', b'*, branches of this nerve descending along the outer part of the forearm; *1*, placed on the fascia of the arm near the bend of the elbow, above the place where it has been opened to show the lower part of the brachial artery with its *venæ comites*, of which one is entire, marked 2, and the other has been divided; *+*, is placed between the artery and the median nerve; *3*, basilic vein; *3', 3'*, ulnar veins; *4*, cephalic vein; *4'*, radial vein; *5, 5*, median vein; *3', 5*, median-basilic vein; *4', 5*, median-cephalic vein.



middle, and on the inner side at the elbow. The *large internal cutaneous nerve* accompanies the artery, being placed over or to the inner side of the vessel, until it pierces the fascia about the middle of the arm. The *ulnar nerve* lies on the inner side of the artery as far as the insertion of the coraco-brachialis; and the *musculo-spiral nerve* is behind it for a short distance at its upper end.

*BRANCHES.*—In addition to the four named branches which are described below, and which proceed backwards from the main trunk, the brachial artery gives small offsets to the integument of the arm, and a variable number of *muscular* branches, which pass forwards and outwards to the coraco-brachialis, biceps and brachialis anticus muscles. One more constant branch, arising from the upper part of the artery (sometimes from the superior profunda), passes outwards transversely in front of the humerus and terminates in the lower part of the deltoid muscle. A special *bicipital* branch, which varies much in size, is usually present, arising at or somewhat above the middle of the arm, and descending outwards in front of the median nerve to the inner part of the biceps muscle.

**1. The superior profunda artery (iv)**, the largest of the branches, arises from the posterior part of the brachial artery, just below the border of the *teres major*, and inclines backwards as it descends to reach the interval between the inner and long heads of the *triceps* muscle. Accompanying the *musculo-spiral nerve*, it then winds round the back of the humerus, in the spiral groove, and under cover of the outer head of the *triceps*. In its course it gives off several branches to the three heads of the *triceps*; one offset passes upwards between the long and outer heads of that muscle, to anastomose beneath the hinder part of the deltoid

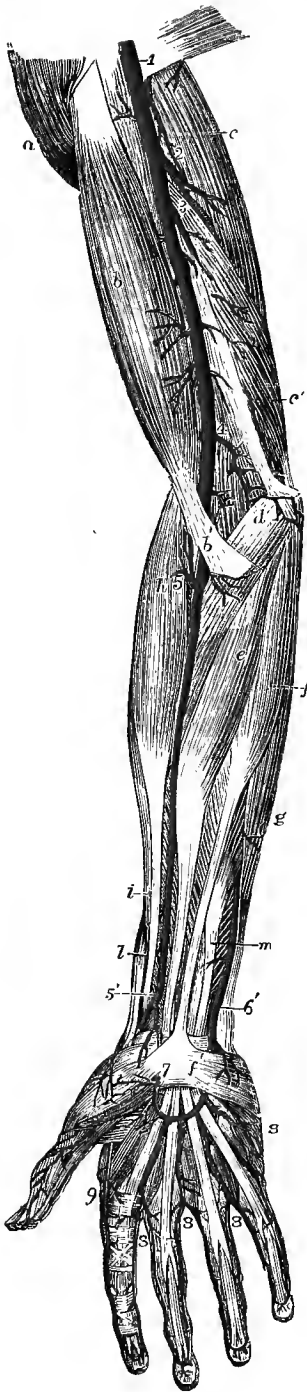

Fig. 359.—SUPERFICIAL VIEW OF THE ARTERIES OF THE FRONT OF THE ARM, FOREARM AND HAND. (Tiedemann.)  $\frac{1}{2}$

*a*, deltoid muscle; *b*, biceps; *b'*, its semilunar fascia; *c*, long head of triceps; *c'*, its inner head; *d*, pronator teres; *e*, flexor carpi radialis; *f*, palmaris longus; *f'*, its tendon spreading in the upper part of the palmar fascia, from which, on the inner side, the palmaris brevis muscle is seen arising; *g*, flexor carpi ulnaris; *h*, supinator longus; *i*, extensor carpi radialis longior; *l*, extensor ossis metacarpi pollicis; *m*, flexor sublimis digitorum; 1, on the tendon of the latissimus dorsi, the lower part of the axillary artery continued into the brachial; 2, superior profunda; 3, inferior profunda; 4, anastomotic; 5, near the division of the brachial artery into ulnar and radial, indicates the origin of the radial recurrent artery; 5', lower part of the radial artery, where it gives off the superficial volar, and turns round the wrist; 6', the lower part of the ulnar artery, near the place where it passes down to form the superficial palmar arch; 7, the superficial volar, which joins it; 8, 8, 8, digital branches of the superficial arch; 9, radialis indicis; on the thumb are seen the two branches of the princeps pollicis artery.

with the posterior circumflex artery; and another of considerable size descends in the inner head of the triceps, and joins in the anastomoses above the elbow-joint. A *medullary* branch enters the foramen on the back of the humerus (p. 93). Much reduced in size as it arrives at the outer side of the humerus, the artery ends by dividing into two branches; the one of which, much the smaller, passes on with the musculo-spiral nerve through the external intermuscular septum, into the interval between the supinator longus and brachialis anticus muscles, and anastomoses with the recurrent branch of the radial artery; while the other descends along the back of the external intermuscular septum, and anastomoses behind the outer condyle of the humerus with the posterior interosseous recurrent artery (fig. 367), and across the back of the bone with the inferior profunda and anastomotic arteries (fig. 362). Small twigs are also given to the skin along with the external cutaneous branches of the musculo-spiral nerve.

2. The **inferior profunda artery**, of small size, arises from the brachial artery about the middle of the arm, and is directed to the back part of the inner condyle of the humerus. It descends in company with the ulnar nerve, lying behind the internal intermuscular septum on the inner head of the triceps muscle, to which it gives branches, and it ends by anastomosing with the posterior recurrent branch of the ulnar artery, and with the anastomotic branch of the brachial.

3. The chief **medullary artery** of the humerus is a small branch given off by the brachial about the middle of the arm, or by one of its collateral branches. It inclines downwards, enters the canal in the humerus near the insertion of the coraco-brachialis muscle, and is distributed in the interior of the bone.



4. The **anastomotic artery** is a very constant branch of moderate size. Arising from the brachial artery about two inches above the bend of the elbow, it is directed backwards and inwards on the brachialis anticus muscle, above the inner

Fig. 360.—HIGH ORIGIN OF THE RADIAL ARTERY FROM THE BRACHIAL, AND AN ENLARGED MEDIAN ARTERY IN THE FOREARM. (Tiedemann.)  $\frac{1}{4}$

1, on the tendon of the latissimus dorsi, points to the upper part of the brachial artery; 2, the brachial artery (ulnar-interosseous) after giving off the radial; 3, the radial, arising in the upper third of the arm and descending in its usual situation in the forearm; 3', its superficial volar branch; 4, the ulnar artery in its usual course, forming at 5, the superficial palmar arch, from which three of the palmar digital arteries and the princeps pollicis take origin, the radial supplying the branches to the index finger and one side of the middle finger; 6, superior profunda artery; 7, inferior profunda; 8, anastomotic; 9, recurrent radial; 10, anterior interosseus, giving an unusually large median branch which descends over the wrist to join the superficial palmar arch.

condyle of the humerus, and, after perforating the intermuscular septum, turns outwards behind the bone, under cover of the triceps muscle, to form with the superior profunda an arch across the humerus, immediately above the olecranon fossa. In front of the humerus the anastomotic artery furnishes a branch which ramifies beneath the pronator teres, and anastomoses with the anterior ulnar recurrent branch. Behind the inner condyle another offset joins with the posterior ulnar recurrent, and several branches are given to the joint and the muscles.

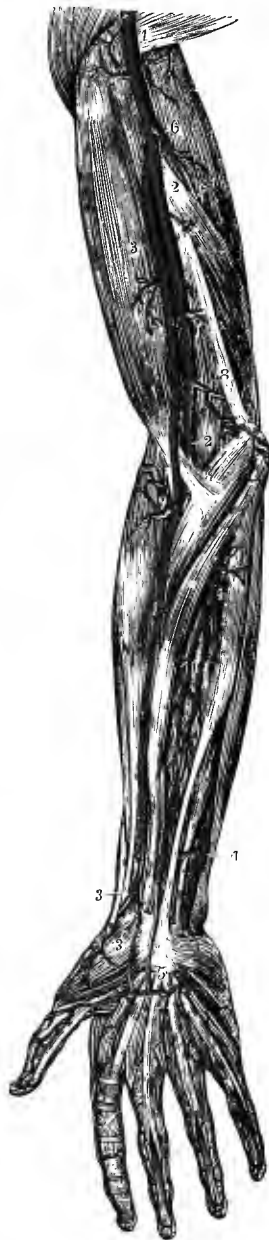**Varieties.**—From their comparative frequency, and surgical interest, the peculiarities of the brachial artery, especially those which affect its trunk, deserve particular attention.

**Course.**—The brachial artery sometimes, though rarely, descends, accompanied by the median nerve, towards the inner condyle of the humerus, and regains its usual position at the bend of the elbow by passing forwards underneath a fibrous arch, from which the pronator teres in these cases arises, and which descends to the inner condyle from the occasional prominence called the supracondylar process. This variety resembles the condition normally existing in the Felidæ and many other animals, in which the brachial artery and median nerve are directed forwards and outwards through a supracondylar foramen (see p. 95).

**Division.**—As an extremely rare condition, the artery has been found dividing near its commencement into two vessels, which unite again near the elbow, forming a single trunk from which the radial and ulnar arteries are given off in the usual manner.

The most frequent change from the ordinary arrangement of the brachial artery is connected with its division into terminal branches.

Out of 481 examples recorded by R. Quain, the vessel was found in 386 to divide at its usual position, a little below the elbow-joint. In one case only (and that complicated by another peculiarity, viz., the existence of a *vas aberrans* proceeding from the axillary to the radial) was the place of division lower than usual, being between two and three inches below the elbow-joint. In 64 cases the brachial artery divided *above* the usual point, at various heights upwards to the lower border of the axilla. The branch prematurely separated from the rest of the trunk in an early division is, in the proportion of nearly three cases out of four, the



radial artery (fig. 360); sometimes the ulnar is the branch given off (fig. 364), that is to say, a branch corresponding to the ulnar in its distribution below the middle of the forearm separates from a trunk which afterwards divides into the normal radial artery and the interosseous of the forearm, which last is normally derived from the ulnar artery. More rarely the branch given off is a *vas aberrans*; or the proper trunk is continued into the interosseous artery of the forearm, while the radial artery and the superficial part of the ulnar are derived from the accessory vessel. In one instance the posterior interosseous artery was thus given off in the arm (Allen Thomson).

The point at which the division took place in cases of high origin of one or other of the arteries of the forearm, without reference to the particular branch given off, was found to be most frequently in the upper, less so in the lower, and least so in the middle third of the arm.

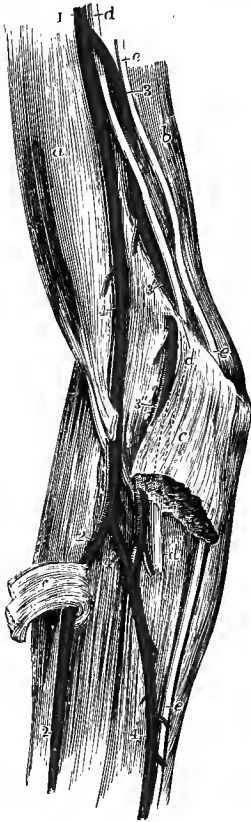

Fig. 361.—LARGE ACCESSORY VESSEL LEAVING THE BRACHIAL ARTERY IN THE MIDDLE OF THE ARM, AND FURNISHING THE RADIAL AND THE GREATER PART OF THE ULNAR ARTERIES: THE BRACHIAL TRUNK MUCH REDUCED IN SIZE PASSING BEHIND A SUPRACONDYLAR PROCESS INTO THE ULNAR ARTERY. (R. Quain.)  $\frac{1}{2}$

*a*, biceps muscle; *b*, triceps; *c*, *c*, divided pronator teres; *d*, median nerve; *e*, ulnar nerve; 1, brachial artery, continued mainly into the aberrant vessel; 2, radial artery; 3, proper continuation of the brachial trunk, with the median nerve crossing it, passing at 3', behind a supracondylar process; 3'', the same farther down, and opening at 4', into the first part of the ulnar artery.

But the early division of the main artery of the upper limb may, as mentioned in connection with the varieties of the axillary artery, take place within the axilla, in which case it follows that the brachial portion of the vessel is replaced, throughout its whole extent, by two separate trunks. In 94 cases out of the 481 observed by R. Quain, or about one in five, there were two arteries instead of one in some part of the arm.

The position of the two arteries in these cases is also of surgical interest. Usually they are close together, occupying the ordinary position of the brachial artery, and the abnormal vessel is generally the more superficial, being separated from the normal trunk by the median nerve; but the *radial artery*, when thus given off in the arm, often arises from the inner side of the brachial, then runs parallel with the larger vessel (the brachial or ulnar-interosseous), and crosses over it, occasionally under it, opposite the elbow, still covered by the fascia. The radial artery has also been found, in a few instances, to perforate the fascia near the bend of the elbow, and run immediately under the skin for some distance. As a rare occurrence it passes behind the tendon of the biceps to its usual place in the forearm.

When the *ulnar* is the branch arising high, it often inclines from the position of the brachial, at the lower part of the arm, towards the inner condyle of the humerus (fig. 364). This vessel generally lies beneath the fascia as it descends, and superficial to the flexor muscles of the forearm, sometimes however crossing beneath the palmaris longus. It is occasionally placed between the integument and the fascia; and in one case only was it found by R. Quain beneath the muscles. In two instances the ulnar artery given off from the brachial at the middle of the arm has been observed to descend superficially behind the inner condyle.

Lastly, when the radial arises high in the arm, or when the radial and a part of the ulnar are derived from an accessory vessel thus given off, the prolongation of the normal trunk may descend, accompanied by the median nerve, along the intermuscular septum towards the inner condyle of the humerus, and turn forwards round a supracondylar process to the front of the elbow (fig. 361).

The two arteries occupying the place of the brachial are in some instances connected near the bend of the arm by an intervening trunk, which varies in its size, form, and course.

The *aberrant arteries*, "*vasa aberrantia*," alluded to above, are long slender vessels, which arise from either the brachial or the axillary artery, and end by joining one of the arteries of the forearm, or one of their branches. In eight cases out of nine, observed by R. Quain, this unusual vessel joined the radial; in the remaining case it joined the radial recurrent, which arose irregularly from the ulnar artery. Very rarely the aberrant vessel joins the ulnar. The existence of these aberrant vessels affords in some measure an explanation of the cases of

high division, since it is obvious that the latter condition would result if the normal origin of one of the forearm arteries at the elbow were obliterated, and the detached vessel were continued from an enlarged aberrant artery. The bicipital branch of the brachial artery passing in front of the median nerve appears to be the remains of such an aberrant vessel. It is probable that that form of variety in which the radial artery arises in the arm, while the continuation of the brachial trunk passes behind a supracondylar process, represents a more primitive condition. (G. Ruge, "Beiträge zur Gefäßlehre des Menschen," Morph. Jahrb., ix, 1884.)

In most cases of high division of the brachial artery the condition of the vessels is not the same in the right and left arms. In 61 bodies in which the high division existed, it occurred on one side only in 43; on both sides, in different positions, in 13; and on both sides, in the same position, in the remaining 5.

A *median artery* of large size (pp. 443, 446) has also been seen arising from the brachial, and in one or two cases this vessel passed downwards over the muscles of the forearm to reach the palm of the hand.

In a very few cases the three arteries of the forearm, radial, ulnar, and interosseous, have arisen together from the end of the brachial trunk, at the usual distance below the elbow.

*Relations.*—The brachial artery is occasionally covered in some part of the arm by a fleshy slip connected with the coraco-brachialis, biceps, brachialis anticus, or pronator teres muscle.

The median nerve sometimes passes behind, instead of in front of, the brachial artery, and in these cases it will be generally found that the axillary artery presents the variety referred to on p. 435, in which several of the large branches are arising by a common trunk.

*Branches.*—It has been already mentioned that the *superior profunda* may give origin to the posterior circumflex artery, and that its own origin is sometimes transferred to a branch arising from the axillary artery.

The *inferior profunda* is occasionally absent. It is frequently united at its origin with the superior profunda.

The *anastomotic* artery is sometimes much reduced in size, and in that case the inferior profunda takes its place behind the humerus.

#### SURGICAL ANATOMY OF THE BRACHIAL ARTERY.

The brachial artery may be easily reached for the application of a ligature in any part of its course. In the middle third of the arm the inner edge of the biceps muscle, where its pulsation may commonly be felt, is the guide for the incision. From the thinness of the parts covering the artery, however, and the proximity of superficial veins, especially the basilic, the integuments and fascia must be divided with caution. The inner border of the biceps having been exposed, the muscle is to be drawn outwards; and the median nerve, which now comes into view, is to be carefully isolated and drawn to one side, when the artery is seen lying between its two companion veins. The aneurism-needle should be passed from the nerve. Occasionally it is found necessary to divide some muscular fibres before the artery is reached.

In the lower third of the arm, the median nerve being placed to the inner side, the artery is more fully exposed after division of the fascia, but here care is necessary in passing the ligature round the artery, to avoid the *venæ comites* or their communicating cross branches, which cling very closely to the artery.

From the very frequent occurrence of varieties in the mode of division of the brachial artery into the vessels derived from it, the surgeon must be prepared for many deviations from the usual condition of the parts, and especially for the presence of two arteries in place of one in the lower third of the brachial region. In such cases the two arteries are most frequently close together and nearly parallel, and it will be easy to tie both vessels, should this be rendered necessary by the nature of the injury for which the operation is performed. But, as will be seen from what has previously been said of the abnormal forms of the brachial artery, the position of one or both the vessels may be subject to very considerable variation in different instances; and in some of these, while one of the vessels is near the usual position, the other may be at some distance, as for example, when it passes beneath a supracondylar process of the humerus.

At the bend of the elbow, the brachial artery is exposed to the risk of injury during the operation of venesection, for which the median-basilic vein is commonly selected. This vein lies here in front of the artery, the semilunar fascia being stretched between them. Instances are known in which the artery has been wounded by the lancet transfixing the vein and fascia, and a communication has thus been established between the vein and artery. On this account the incision into the vein must be made with due care, and indeed the median-cephalic, if of sufficient size, may be selected for the operation.

*Collateral circulation.*—When the brachial artery has been tied in the middle of the arm,

the superior profunda branch forms the principal channel through which the circulation is carried on, by means of its anastomoses with the radial recurrent, interosseous recurrent, and anastomotic arteries. If the ligature has been placed on the artery near the elbow, the inferior profunda and anastomotic arteries will assist by their communications with the ulnar recurrents.

### ULNAR ARTERY (III).

The ulnar artery, the larger of the two vessels into which the brachial divides, extends along the inner side of the forearm into the palm of the hand, where it forms the superficial palmar arch. In this course it inclines at first downwards and inwards, describing a slight curve the convexity of which is directed inwards, and passes between the superficial and deep layers of muscles; somewhat above the middle of the forearm the artery comes into contact with the ulnar nerve, which was previously separated from it by a considerable interval, and thence descends vertically with the nerve towards the inner border of the palm of the hand. Lying along the radial border of the tendon of the flexor carpi ulnaris muscle, the ulnar artery reaches the outer side of the pisiform bone, where, still accompanied by the nerve, it passes over the anterior annular ligament of the wrist into the palm of the hand. Its disposition in the hand will be separately described.

In the first half of its course through the forearm, the artery is deeply seated, being covered by the muscles arising from the inner condyle of the humerus, viz., pronator teres, flexor carpi radialis, palmaris longus, and flexor sublimis digitorum. From the middle of the forearm it is overlapped by the flexor carpi ulnaris till within an inch of the wrist, where it lies immediately under the fascia. Beneath the tendon of the flexor carpi ulnaris the artery is also covered by a thin layer of membrane by which it is bound down to the muscle beneath. At first the ulnar artery lies on the insertion of the brachialis anticus, then on the flexor profundus digitorum in the rest of the forearm, and lastly on the annular ligament of the wrist. Below the point at which it emerges from under the flexor carpi ulnaris, the tendon of that muscle is on its inner or ulnar side.

*Relation to veins.*—The ulnar artery is accompanied by two veins (*venæ comites*), which are united by numerous cross branches.

*Relation to nerves.*—The *median nerve* lies at first immediately on the inner side of the ulnar artery, but being directed down the middle of the forearm it soon passes over the vessel, separated from it at the point of crossing by the deep head of the pronator teres muscle. As the *ulnar nerve* descends behind the inner condyle of the humerus, it is separated from the ulnar artery by a considerable interval at the upper part of the forearm; but as the vessel inclines inwards, it approaches the nerve, and is accompanied by it in the lower half or more of its course—the nerve lying close to its inner side. The small *palmar cutaneous* branch of the ulnar nerve descends upon the lower part of the artery.

**BRANCHES.**—The ulnar artery in the forearm gives numerous *muscular* branches, of small size, to the surrounding muscles, and the following named offsets, viz. :—

**1.** The **anterior ulnar recurrent artery**, a small branch, arches inwards and upwards from the upper part of the ulnar artery, in front of the inner condyle, lying on the brachialis anticus, and covered by the pronator teres, both of which muscles it partly supplies. It ends by communicating with the anastomotic branch of the brachial.

**2.** The **posterior ulnar recurrent artery**, larger than the preceding, comes off a little lower down; but not unfrequently the two vessels arise by a short common trunk. The posterior recurrent runs inwards and backwards beneath the flexor sublimis, and then ascends behind the inner condyle. In the interval

between that process and the olecranon it lies beneath the flexor carpi ulnaris, and, passing between the heads of this muscle along the ulnar nerve, supplies branches to the muscles, to the elbow-joint, and to the nerve itself. This branch communicates with the inferior profunda, the anastomotic, and over the olecranon also with the posterior interosseous recurrent.

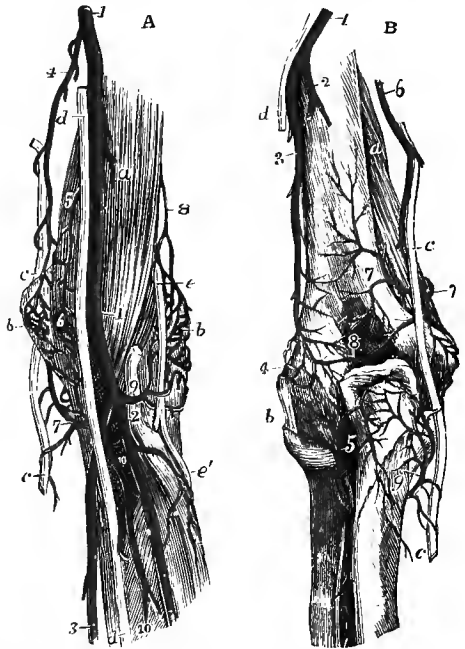
**3.** The **interosseous or common interosseous artery (iv)**, the largest branch, is a short trunk which arises from the ulnar artery about an inch from its commencement, and inclines backwards to reach the upper border of the interosseous membrane, where it divides into the anterior and posterior interosseous arteries.

The **anterior interosseous artery** descends upon the front of the interosseous membrane, accompanied by the interosseous branch of the median nerve and venæ

Fig. 362.—THE ANASTOMOSES OF THE ELBOW: A, FROM BEFORE; B, FROM BEHIND. (R. Quain.)  $\frac{1}{2}$

A. *a*, brachialis anticus muscle; *b*, external condyle, covered by the anastomoses of the superior profunda and radial recurrent arteries; *c*, ulnar nerve; *d*, median nerve; *e*, musculo-spiral nerve; *e'*, its posterior interosseous branch; its radial branch is cut short; 1, brachial artery; 2, radial; 3, ulnar; 4, inferior profunda; 5, anastomotic; 6, anterior ulnar recurrent, anastomosing with the anterior branch of the anastomotic; 7, posterior ulnar recurrent, passing up behind the inner condyle to anastomose with the inferior profunda and posterior branch of the anastomotic; 8, anterior terminal branch of superior profunda; 9, on the tendon of the biceps muscle, points to the radial recurrent artery; 10, 10, interosseous artery and its anterior branch.

B. *a*, brachialis anticus muscle; *b*, external lateral ligament of the elbow-joint; *c*, ulnar nerve; *d*, a small part of the musculo-spiral nerve; 1, superior profunda artery; 2, branch which descends in the inner head of the triceps muscle; 3, its posterior terminal branch; 4, branches of the radial recurrent; 5, posterior interosseous recurrent, anastomosing with the preceding and with the posterior ulnar recurrent; 6, inferior profunda; 7, 7, anastomotic; 8, anastomosis of the inferior profunda and anastomotic with the superior profunda; 9, posterior ulnar recurrent, anastomosing with the inferior profunda and anastomotic.



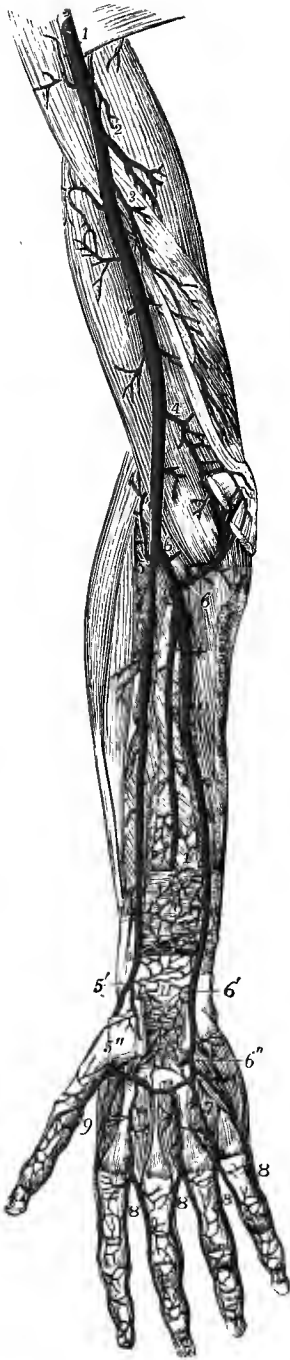comites, and overlapped by the contiguous borders of the flexor profundus digitorum and flexor longus pollicis muscles. It continues its course directly downwards as far as the upper border of the pronator quadratus muscle, then pierces the interosseous membrane, and descends to the back of the carpus. It gives off the following branches:—

(a) The *median artery*, a long slender branch, which accompanies the median nerve, and sends offsets into its substance and to the flexor sublimis digitorum. This artery is sometimes much enlarged and assists in supplying the hand, as will be hereafter noticed.

(b) *Muscular branches* to the flexor profundus, flexor longus pollicis, and pronator quadratus muscles, and others which perforate the interosseous membrane to supply the extensors of the thumb.

(c) The *medullary arteries* of the radius and ulna, which enter the foramina in those bones to be distributed in their interior.

Fig. 363.—DEEP ANTERIOR VIEW OF THE ARTERIES OF THE ARM, FOREARM, AND HAND. (Tiedemann.)  $\frac{1}{2}$



The biceps, the muscles arising from the inner condyle, the supinator longus, the lower part of the flexor longus pollicis and flexor profundus digitorum, the anterior annular ligament, and the muscles of the ball of the thumb have been removed: *n*, pronator quadratus muscle; 1, lower part of the axillary artery continued into the brachial; 2, superior profunda; 3, inferior profunda; 4, anastomotic; 5, upper part of the radial artery and radial recurrent; 5', lower part of the radial artery, giving off the superficial volar branch; 5'', radial artery, emerging from between the heads of the abductor indicis muscle; 6, 6, upper part of the ulnar artery with the anterior and posterior ulnar recurrent branches; 6', ulnar artery, approaching the wrist and descending into the superficial palmar arch which has been cut short; 6'', deep branch of the ulnar artery uniting with the deep palmar arch; 7, (marked only on one) interosseous branches from the deep palmar arch joining the palmar digital arteries 8, 8, 8, which have been cut away from their origin from the superficial arch to near their division into the collateral digital arteries; the ulnar collateral of the little finger is arising in this instance from the deep palmar arch; 9, placed between the princeps pollicis and radialis indicis branches of the radial artery; 10, lower part of the anterior interosseous artery passing behind the pronator quadratus muscle; 11, anastomosis of the anterior carpal branches of the radial and ulnar arteries with twigs from the anterior interosseous artery and recurrent branches from the deep palmar arch.

(*d*) An *anterior communicating* branch, given off before the artery pierces the interosseous membrane, and descending beneath the pronator quadratus muscle to anastomose with the anterior carpal arteries.

(*e*) *Terminal* twigs anastomosing with the posterior carpal arteries.

The **posterior interosseous artery**, passing backwards through the interval between the oblique ligament and the upper border of the interosseous membrane, appears on the back of the forearm between the supinator brevis and extensor ossis metacarpi pollicis muscles, and gives off here its recurrent branch. Continuing its course downwards between the superficial and deep layers of extensor muscles, to both of which it distributes branches, it reaches the back of the wrist much diminished in size, and ends by anastomosing with the anterior interosseous and posterior carpal arteries.

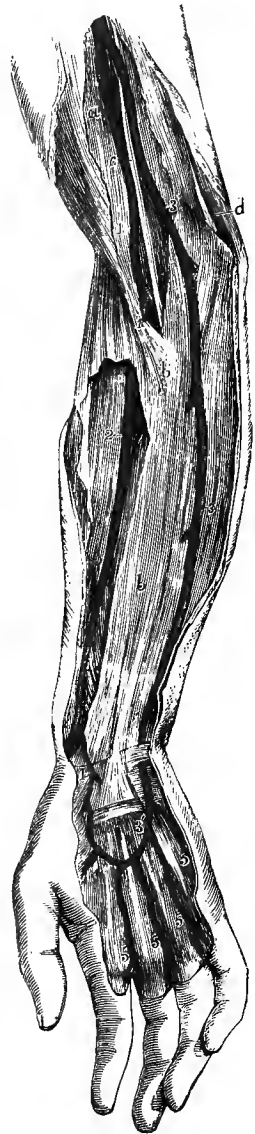The *posterior interosseous recurrent artery* passes directly upwards, covered by the anconeus, to reach the interval between the olecranon and external condyle, where it divides into several offsets which anastomose with the superior profunda, the posterior ulnar recurrent and the radial recurrent arteries.

**4.** The **posterior ulnar carpal** branch, of variable size, arises a little above the pisiform bone, and winds back under the tendon of the flexor carpi ulnaris to gain the dorsal surface of the carpus. It gives a small *metacarpal* branch (sometimes derived separately from the ulnar) which runs along the ulnar side of the fifth metacarpal bone; and then passing transversely outwards beneath the extensor tendons, it anastomoses with the posterior carpal branch of the radial artery, so as

to form the *posterior carpal arch*. From this arch are derived the *second* and *third dorsal interosseous arteries*, which descend over the spaces between the third and fourth and the fourth and fifth metacarpal bones, and are reinforced at the upper

Fig. 364.—HIGH ORIGIN AND SUPERFICIAL COURSE OF THE ULNAR ARTERY. †

*a*, biceps muscle covered by the deep fascia ; *b*, *b*, fascia of the forearm, which has been opened in a considerable extent to show the radial artery subjacent to it ; *c*, median nerve ; *d*, ulnar nerve ; 1, on the biceps muscle, points to the brachial artery after having given off the ulnar artery higher up, and dividing at 1', into the radial artery and a deep vessel corresponding to the interosseous and a part of the normal ulnar ; 2, on the supinator longus muscle, points to the radial artery ; 3, 3, artery which is given off by the brachial in the arm, and which, descending upon the fascia, takes the place of the ulnar at the wrist ; 3', the same continued into the superficial palmar arch ; 4, superficial volar branch of the radial ; 5, 5, digital branches.



ends of those spaces by the junction of the superior perforating branches of the deep palmar arch.

5. The **anterior ulnar carpal** branch is a very small artery, which runs on the anterior surface of the carpus beneath the flexor profundus, anastomoses with a similar offset from the radial artery, and supplies the carpal bones and articulations.

**Varieties.**—*Origin.*—In the whole number of cases observed by R. Quain, the ulnar artery was found to deviate from its usual mode of origin nearly in the proportion of one in thirteen. The brachial artery was, more frequently than the axillary, the source from which it sprang ; and the lower part of the brachial more frequently than the upper. In one case of high origin of the ulnar artery, the vessel was connected with the brachial opposite the elbow-joint by means of a transverse branch.<sup>1</sup> See, on this subject, the remarks on the varieties of the axillary and brachial arteries.

*Course.*—The position of the ulnar artery in the forearm is more frequently altered than that of the radial.

In cases of high origin it almost invariably descends over the muscles arising from the inner condyle of the humerus, only one exception to this rule having been met with by R. Quain. In one instance the ulnar artery taking this course divided just below the elbow into a superficial and deep branch.<sup>1</sup>

Most commonly in such cases it is covered by the fascia of the forearm ; but instances also occur in which the artery rests on the fascia, and either continues in that position or again sinks beneath the fascia lower down, while the vessel thus disposed is distributed below after the manner of the normal ulnar artery. The vessel from which the high ulnar separates is afterwards divided into the radial artery and the interosseous ; it appears therefore probable that the abnormal arrangement results from early obstruction of the ulnar artery below the origin of the interosseous, and the development of a superficial *vas aberrans*, which unites the portion of vessel below the obstruction with the axillary or brachial trunk. The interosseous artery in such cases of abnormality thus comprises not only the ordinary interosseous branch, but likewise the portion of ulnar artery above the obstruction ; and, in accordance with this view, we find that the recurrent branches are derived from it.

The ulnar artery has been seen occasionally taking a superficial course when arising in the usual situation, and in these cases also the recurrent and interosseous arteries are given off by the radial trunk.

† W. Gruber, *Archiv für Anatomic*, 1871.

As to *size*, the ulnar artery presents some varieties which are generally accompanied by deviations of an opposite and compensating character in the radial artery; but as these influence the extent of the distribution of the ulnar artery in the hand, they will be noticed in connection with the varieties of the vessels of that part.

*Branches.*—The *anterior* and *posterior ulnar recurrent* branches frequently arise by a common trunk. One or both have been seen to arise from the brachial artery.

The *anterior* and *posterior interosseous arteries* are occasionally given separately from the ulnar. The anterior interosseous artery has been seen of large size, reinforcing the radial or, more rarely, the ulnar artery by means of a transversely directed branch joining the main trunk at the wrist (enlargement of an anterior carpal artery); or its posterior branch has been seen joining the radial on the back of the hand. More frequently it gives off a large median artery.

*Median artery.*—The branch accompanying the median nerve is sometimes much enlarged, and in such cases may be regarded as a reinforcing vessel. It is generally a branch of the anterior interosseous, but sometimes of the ulnar; and more rarely a median branch has been met with descending from the brachial or axillary artery. Generally accompanying the median nerve beneath the annular ligament, occasionally however passing over the front of the ligament, it enters the palm of the hand and there ends, most frequently by joining the superficial palmar arch, sometimes by forming digital branches, and in other cases by joining digital branches given from other sources (figs. 360, 369).

#### SUPERFICIAL PALMAR ARCH (IV).

The superficial palmar arch is the continuation of the ulnar artery in the hand. As it passes over the anterior annular ligament the ulnar artery gives off its deep branch, and a little below that band it turns outwards across the palm of the hand towards the middle of the muscles of the thumb. In this course the vessel describes a curve, having its convexity directed towards the fingers, and extending downwards somewhat lower than a line on a level with the metacarpo-phalangeal articulation of the thumb. The arch is sometimes completed on the outer side by inosculating with the superficial volar branch of the radial artery, and in many cases it is connected also, by a small branch, with the *radialis indicis* or *princeps pollicis* artery at the lower border of the *adductor transversus pollicis* muscle.

The superficial palmar arch rests at its commencement on the annular ligament of the wrist, and slightly on the short muscles of the little finger; then on the tendons of the superficial flexor of the fingers, and the divisions of the median and ulnar nerves, the latter nerve accompanying the vessel for a short distance. It is covered towards the ulnar border of the hand by the *palmaris brevis*, and afterwards by the palmar fascia and the integument.

*BRANCHES.*—The superficial palmar arch gives off small twigs to the superficial muscles and integument of the palm, and the following larger branches to the fingers:—

The **digital arteries** (▼), usually four in number, proceed downwards from the convexity of the palmar arch to supply both sides of the inner three fingers, and the ulnar side of the fore finger. The *first digital* branch (often derived from the deep arch) inclines inwards to the ulnar border of the hand, and, after giving minute offsets to the muscles of the little finger, runs along the inner margin of its phalanges. The *second* runs along the fourth intermetacarpal space, and at the root of the fingers divides into two *collateral* branches, which proceed along the contiguous borders of the ring and little fingers. The *third* is similarly distributed to the ring and middle fingers; and the *fourth* to the middle and index fingers. The thumb and the radial side of the index finger are supplied from the radial artery.

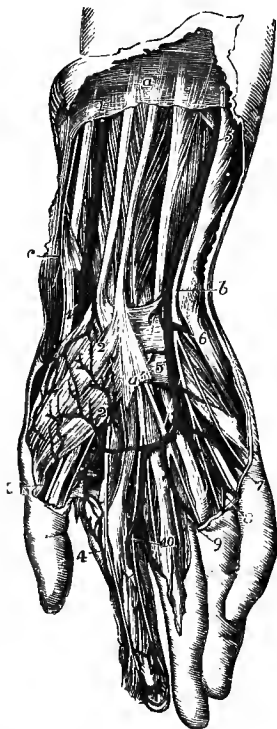
The digital arteries descend in the intervals between the flexor tendons, resting upon the digital nerves and *lumbricales* muscles, as far as the clefts of the fingers,



where they are joined by the palmar interosseous arteries from the deep arch, and by inferior perforating arteries from the back of the hand. On the sides of the fingers, each collateral artery lies beneath the corresponding nerve, and gives branches which supply the sheaths of the tendons and the joints, some of them anastomosing across the front of the bones with similar branches from the opposite side. At about the middle of the last phalanx, the two arteries of each finger converge and form an arch, from which numerous branches proceed to supply the skin and subcutaneous tissue of the tip of the finger. Other offsets pass to the

Fig. 365.—SUPERFICIAL DISSECTION OF THE LOWER PART OF THE FOREARM AND THE HAND, SHOWING THE RADIAL AND ULNAR ARTERIES, THE SUPERFICIAL PALMAR ARCH, AND THE ACCOMPANYING NERVES. (R. Quain.)  $\frac{1}{2}$

*a*, on the deep fascia of the forearm, between the tendons of the palmaris longus and flexor carpi radialis muscles; *b*, points by a line crossing the pisiform bone to the ulnar nerve; *c*, points to the styloid process of the radius and twigs of the radial nerve; 1, radial artery lying on the flexor longus pollicis; 1', the same passing beneath the tendons of the ext. ossis metacarpi and ext. brevis pollicis; 2, superficial volar branch, piercing the short muscles of the thumb and emerging below to join the superficial palmar arch; 3, external branch of the princeps pollicis; 4, radialis indicis; a branch from the superficial arch is seen joining the internal branch of the princeps pollicis; 5, ulnar artery lying upon the flexor profundus digitorum; 5', the same descending on the anterior annular ligament to form the superficial palmar arch; 6, deep branch of the ulnar artery passing between the abductor and flexor minimi digiti to join the deep arch, accompanied by the deep branch of the ulnar nerve; 7, 8, 9, 10, digital arteries from the superficial arch; 7, and 8, are accompanied by the digital branches of the ulnar nerve, and 3, 4, 9, and 10, by branches of the median nerve.



structures on the back of the second and third phalanges, and form a close plexus beneath the matrix of the nail.

The varieties observed in the branches of the superficial palmar arch will be noticed after the description of the deep arteries of the hand.

THE DEEP BRANCH OF THE ULNAR ARTERY arises at the commencement of the superficial palmar arch, immediately below the pisiform bone; passing deeply into the palm between the abductor and short flexor muscles of the little finger, it inosculates with the termination of the radial artery, and so completes the deep palmar arch.

#### RADIAL ARTERY (IV).

The radial artery appears by its direction to be the continuation of the brachial, although it does not equal the ulnar in size. It extends along the front of the forearm as far as the lower end of the radius, below which it turns round the outer border of the wrist, and descends to the upper end of the space between the metacarpal bones of the thumb and fore finger: there it passes forwards into the palm of the hand, supplies digital branches to the thumb and index finger, and terminates in the deep palmar arch. In consequence of the changes in its direction, the course, relations and branches of the radial artery may be separately described in the forearm, at the wrist and in the hand.

IN THE FOREARM.—The radial artery, commencing at the point of bifurcation

of the brachial opposite the neck of the radius, descends with a nearly straight course, along the outer part of the front of the forearm, to the styloid process of the radius. Its position is indicated by a line drawn from the middle of the bend of the elbow to the narrow interval between the scaphoid bone and the tendons of the extensors of the thumb, which can be readily felt on the outer border of the wrist.

The radial artery is nearer to the surface than the ulnar; it is covered in its upper half by the fleshy part of the supinator longus muscle, which must be drawn

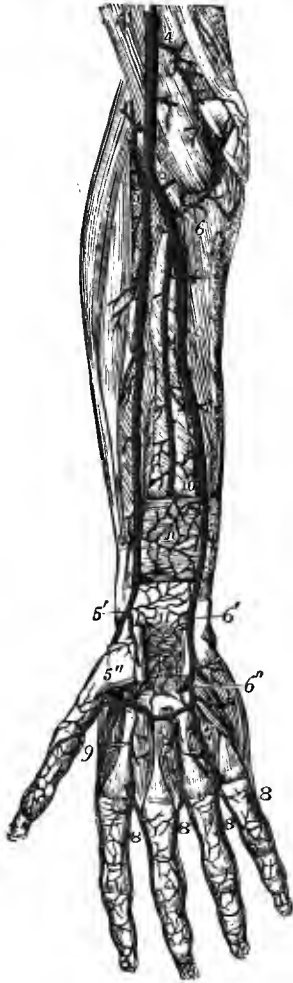


Fig. 366.—DEEP ANTERIOR VIEW OF THE ARTERIES OF THE FOREARM AND HAND. (Tiedemann.)  $\frac{1}{4}$

For the full description of this figure, see p. 444. The following numbers refer to the radial artery and its branches: 5, upper part of the radial artery and radial recurrent; 5', lower part of the radial artery, giving off the anterior carpal and superficial volar branches; 5'', the radial artery, emerging from between the heads of the abductor indicis muscle and forming the deep palmar arch; 9, placed between the princeps pollicis and radialis indicis branches of the radial artery.

aside in order to bring the vessel into view, in its lower half, only by the integument and fascia. At first it is in contact with the tendon of the biceps, and is supported by the fatty tissue contained in the hollow at the front of the elbow, which separates it from the short supinator muscle. It then rests in succession on the insertion of the pronator teres, the thin radial origin of the flexor sublimis, the flexor longus pollicis, the pronator quadratus, and the lower end of the radius. It is at this last point that the pulse is usually felt during life. To the inner side of this vessel lie the pronator teres in the upper part of its course, and the flexor carpi radialis in the remainder; and on the outer side, in its whole course along the forearm, is the supinator longus muscle.

*Relation to veins.*—The artery is accompanied by *venæ comites*, which have the usual arrangement of those veins.

*Relation to nerves.*—The *radial nerve* is near the artery, on its outer side, in the middle third of its course. At the elbow this nerve is separated from the artery by a considerable interval; and towards the lower end of the forearm it turns backwards beneath the tendon of the supinator longus, to reach the dorsal aspect of the limb, and thus loses all connection with the artery. Some filaments of

the *external cutaneous nerve* pierce the fascia to reach the lower part of the artery, which they accompany to the back of the carpus.

**BRANCHES.**—In the forearm the radial artery gives many small *muscular* offsets to the surrounding muscles and the following named branches, viz. :—

**1. The radial recurrent artery**, which varies much in size, arches upwards from the radial soon after its origin, running between the branches of the musculospiral nerve. It lies at first on the supinator brevis, and then on the brachialis

Fig. 367.—ARTERIES OF THE OUTER AND BACK PART OF THE ARM AND HAND, SUPERFICIAL VIEW. (Tiedemann.)  $\frac{1}{2}$

*a*, deltoid muscle; *b*, outer head of triceps; *c*, biceps; *d*, brachialis anticus; *e*, supinator longus; *f*, ext. carpi radialis longior; *g*, brevior; *h*, ext. communis digitorum and minimi digiti; *i*, ext. carpi ulnaris; *k*, anconeus; *l*, flexor carpi ulnaris; *m*, ext. ossis metacarpi pollicis; *n*, ext. brevis pollicis; *o*, ext. longus pollicis; 1, 1, cutaneous and posterior terminal branches of the superior profunda artery, the latter descending to anastomose with the branches of the interosseous and radial recurrent arteries; 2, above the posterior annular ligament, the anterior interosseous artery; 3, posterior carpal branch of the ulnar artery; 4, radial artery, taking its course between the external lateral ligament of the wrist-joint and the tendons of the extensor muscles before passing near 5, between the two heads of the abductor indicis; beneath the extensor tendons is seen the posterior carpal arch, giving in this case the three dorsal interosseous arteries; 6, the inner dorsal artery of the thumb; 7, the outer dorsal artery of the index finger; 7', the metacarpal branch of the ulnar artery, and between 7, and 7', the remaining dorsal digital arteries, formed by the bifurcation of the dorsal interosseous arteries.

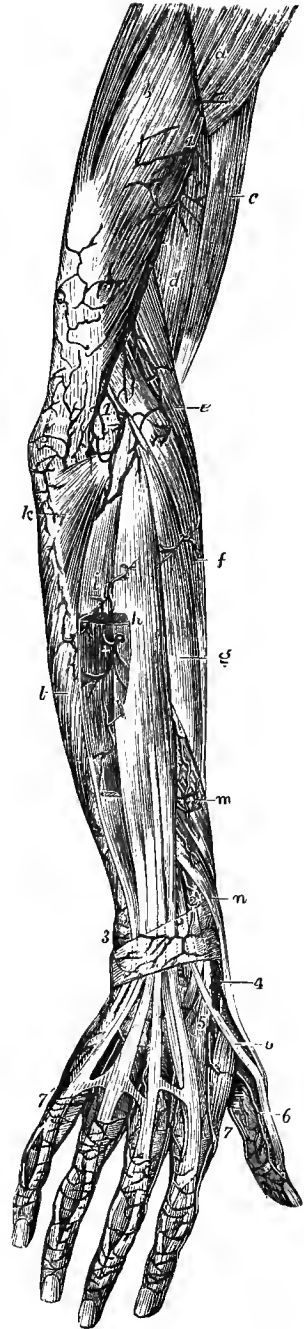
anticus, being covered by the supinator longus. In the interval between the last two muscles, it anastomoses with the anterior terminal branch of the superior profunda.

From the lower or convex side of this artery are given off several branches; one or more, of considerable size, to the supinator and radial extensor muscles, and some beneath the latter to anastomose with the posterior interosseous recurrent. It also supplies the supinator brevis and brachialis anticus in part.

2. The **anterior radial carpal** is a small branch which arises near the lower border of the pronator quadratus muscle, and runs inwards in front of the wrist to anastomose with a similar branch of the ulnar artery. The arch thus formed (*anterior carpal arch*) is joined above by communicating offsets from the anterior interosseous artery, and below by the recurrent branches of the deep palmar arch, thus giving rise to a network over the front of the wrist, from which twigs are supplied to the carpal bones and articulations.

3. The **superficial volar artery**, arising from the radial near the place where it leaves the front of the forearm, passes onwards into the hand. In size it is variable; in most instances it is small, and ends in the muscles of the thumb; but in others it attains considerable size, and crossing these muscles, terminates by inosculating with the radial extremity of the superficial palmar arch, which it thus completes.

AT THE WRIST.—Below the styloid process of the radius, the radial artery turns backwards, passing beneath the tendons of the extensor ossis metacarpi and extensor brevis pollicis, and resting upon the external lateral ligament of the wrist-



joint. It then runs downwards for a short distance over the scaphoid bone and trapezium, being crossed by the tendon of the extensor longus pollicis, and reaches the upper end of the space between the first and second metacarpal bones, where it turns forwards into the palm of the hand, by passing between the heads of the first dorsal interosseous muscle.

As it turns round below the end of the radius the artery is deeply seated, but afterwards it comes nearer to the surface. It is accompanied by two veins and by some filaments of the external cutaneous nerve, and is crossed by subcutaneous veins and by branches of the radial nerve.

**BRANCHES.**—1. The **posterior radial carpal** is a small but constant branch. It arises beneath the extensor tendons of the thumb, and running inwards on the back of the carpus anastomoses with the posterior ulnar carpal branch, completing the *posterior carpal arch*, from which the dorsal interosseous arteries of the third and fourth spaces spring. It anastomoses, also, with the terminal branch of the anterior interosseous of the forearm.

2. The **first dorsal interosseous artery**, arising beneath the extensor tendons of the thumb, frequently in common with the posterior carpal branch, passes to the interval between the second and third metacarpal bones, receives the first superior perforating branch of the deep palmar arch, and descends on the second dorsal interosseous muscle to the level of the metacarpo-phalangeal articulations. It here sends forwards a slender *inferior perforating* branch to join the corresponding palmar digital artery, and ends by dividing into two *dorsal digital* branches which ramify on the adjacent margins of the index and middle fingers, as far as the base of the second phalanx, and anastomose on the sides of the fingers with the palmar collateral arteries.

The second and third dorsal interosseous arteries, springing from the posterior carpal arch, are distributed in a similar manner in the third and fourth interdigital spaces, but their inferior perforating branches are often wanting.

3. The **dorsal arteries of the thumb**, two small branches, arising separately or together opposite the base of the metacarpal bone, run upon the dorsal aspect of the thumb-bones, one at the radial, the other at the ulnar border.

4. The **dorsal artery of the index finger**, a very small branch, arises below the preceding, and, sending branches to the abductor indicis, runs along the radial side of the back of the index finger.

**IN THE HAND.**—The radial artery, entering the palm between the heads of the abductor indicis muscle, immediately gives off, under cover of the adductor obliquus pollicis, the large artery of the thumb and the radial branch of the index finger, and turns inwards to form the deep palmar arch by inosculating with the deep branch of the ulnar artery.

The **large artery of the thumb** (*art. princeps pollicis*) passes downwards in front of the abductor indicis, between the metacarpal bone of the thumb and the muscles covering it, to the space between the heads of the flexor brevis pollicis. At that point, and beneath the tendon of the long flexor, it divides into two *collateral* branches, which course along the borders of the phalanges, on their palmar aspect, and unite in front of the last phalanx, to form an arch similar in arrangement to that on the other fingers.

The **radial branch of the index finger** (*art. radialis indicis*) descends between the abductor indicis and adductor pollicis muscles, and continues along the radial border of the index finger, forming its *radial collateral* branch, and anastomosing in the usual manner on the last phalanx with the ulnar collateral branch derived from the superficial palmar arch. This artery sometimes arises by a common trunk with the foregoing, or more frequently is united with the inner collateral artery of the thumb.

**Varieties.**—*Origin.*—In the observations of Richard Quain, the radial artery was found to arise higher up than usual in nearly one case in eight. Its origin was much more frequently from the axillary, or from the upper part of the brachial, than from the lower part of the latter artery. Low origin of the radial artery is much less frequent (see p. 439), but it has been found arising below the upper third of the forearm (Tiedemann).

*Course.*—The radial artery more rarely deviates from its usual position along the forearm than the ulnar. It has been found lying upon the semilunar fascia of the biceps, and over the aponeurosis of the forearm, instead of beneath those structures. It occasionally turns backwards over, instead of beneath, the tendons of the extensor muscles of the thumb; and in rarer cases it has been seen passing backwards over the supinator longus, above the middle of the forearm, and descending across the thumb-muscles to the wrist. In cases of low origin the radial artery passes beneath the pronator teres and the radial origin of the flexor sublimis digitorum to its usual position between the tendons of the supinator longus and flexor carpi radialis, and in two or three of these cases it has been seen joined by a vas aberrans as it makes its appearance superficially. As has been previously stated (p. 440), the vasa aberrantia occasionally derived from the brachial or axillary artery commonly end by joining the radial, or one of its branches.

*Size.*—The radial artery is sometimes much smaller than usual, and it has been seen terminating in the carpal and superficial volar offsets, or in muscular offsets at a variable level in the forearm. A few instances of absence of the radial artery are also recorded, the brachial artery being continued directly into the ulnar-interosseous trunk, and giving off only a radial recurrent branch at the usual place of division. In these cases the deficiency is generally supplied by the ulnar artery in the hand, or by a large median artery; more rarely by a branch of the anterior interosseous, directed outwards in front of the wrist, or joining the diminished radial trunk at the back of the hand (p. 446).

*Branches.*—The *radial recurrent* is sometimes very large, or it may be replaced by several separate branches. One considerable branch occasionally passes backwards on the surface of the supinator brevis muscle, and turns upwards behind the outer condyle of the humerus, replacing the posterior interosseous recurrent artery. When the radial itself arises high up, the recurrent artery usually comes from the residual brachial trunk, or sometimes from the ulnar artery, or more rarely from the interosseous. When given from the brachial trunk, the radial recurrent has been found crossing beneath the tendon of the biceps.

The *superficial volar* branch is sometimes enlarged, and furnishes one or two digital branches (generally to the thumb and index finger), and along with this the communication with the superficial arch may be absent. This branch occasionally arises much higher than usual; and in a few cases the radial artery has been found dividing in the upper part of the forearm into two branches of nearly equal size, the one of which descends into the palm of the hand as the superficial volar artery, giving off also the carpal and dorsal digital branches, while the other passes backwards at a variable level, over the extensor tendons, in the manner described above.

The *posterior carpal* and *dorsal interosseous* branches of the radial are sometimes very small, their place being supplied by the perforating offset of the anterior interosseous, apparently by an enlargement of the ordinary anastomosis between them.

The *first dorsal interosseous* branch is not unfrequently much enlarged, and furnishes the collateral digital arteries to the index and middle fingers. The *dorsal artery of the index finger* may similarly, though more rarely, supply one or both of the collateral arteries of the adjacent sides of the thumb and index finger.

#### DEEP PALMAR ARCH (V).

The deep palmar arch, the continuation of the radial artery, commences at the upper end of the first interosseous space, extends transversely across the palm towards the fifth metacarpal bone, and is completed by the deep branch of the ulnar artery. The convexity of the arch thus formed is directed downwards. It rests on the interosseous muscles and on the metacarpal bones immediately below their carpal extremities, and is covered by the adductor obliquus pollicis, the flexor tendons of the fingers, and the opponens and flexor brevis minimi digiti. It is nearer to the carpus than the superficial arch, and differs from it in retaining its size almost undiminished. It is accompanied for some distance by the deep branch of the ulnar nerve, which runs from the inner end of the arch outwards.

**BRANCHES.**—1. The **recurrent** branches ascend from the upper concave side of the arch, and anastomose with the branches of the anterior carpal arch.

2. The **superior perforating** branches, three in number, frequently arise in common with the following branches; they pass backwards through the upper extremities of the inner three interosseous spaces to inosculate with the dorsal interosseous arteries.

3. The **palmar interosseous arteries**, usually three in number, but very liable to variation, lie in front of the interosseous spaces, supply the muscles there, and inosculate at the clefts of the fingers with the digital branches from the superficial arch. There is generally also a communicating branch passing from the inner-

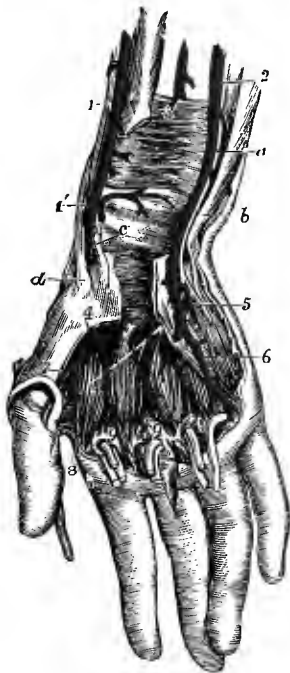


Fig. 368.—DEEP ARTERIES OF THE WRIST AND PALM.  
(R. Quain.)  $\frac{1}{2}$

The anterior annular ligament of the wrist has been divided; the lower parts of the common flexors and the long flexor of the thumb have been removed, and portions of these tendons are turned down upon the fingers with parts of the lumbricales muscles; the superficial palmar arch is removed, and the interosseous muscles are exposed: *a*, ulnar nerve; *b*, tendon of flexor carpi radialis; *c*, tendon of flexor carpi radialis; *d*, tendon of extensor ossis metacarpi pollicis; 1, radial artery; 1', its lower part giving off the anterior carpal and superficial ulnar branches, the latter cut short; 2, ulnar artery; 3, anterior interosseous artery, passing behind the pronator quadratus; 4, radial artery, appearing deeply in the palm between the first and second metacarpal bones and passing into the deep palmar arch; 5, deep branch of the ulnar artery, dipping between the abductor and flexor brevis minimi digiti to join the deep arch, and accompanied by the deep branch of the ulnar nerve; 6, a digital artery, arising from the first part of the superficial palmar arch; 7, princeps pollicis, and 8, radialis indicis arteries; 9, 9, 9, interosseous branches of the deep palmar arch, proceeding down on the interosseous muscles to join the palmar digital arteries from the superficial arch.

most interosseous artery, or from the deep arch itself, to the digital artery of the inner side of the little finger.

It is by an enlargement of these small vessels that the deep palmar arch sometimes supplies the corresponding digital arteries when those derived from the superficial arch are small or absent.

**Varieties of the arteries of the hand.**—The arteries of the hand frequently vary from their usual mode of distribution.

(*a*) By far the larger number of deviations consist of a deficiency in either the radial or ulnar system of arteries, accompanied by a corresponding increase in the other; and it may be observed that the defect is much more commonly on the part of the superficial, and the increase on the part of the deep set.

(*b*) In the second and smaller class of variations a deficiency in one or other of the two systems is supplied, either by the enlargement of branches which descend in front of the limb, as the superficial volar (from the radial), or the median artery (from the anterior interosseous, as shown in fig. 369), or by the enlargement of an interosseous branch (from the radial) on the back of the hand.

In illustration of these general remarks, the following mode of arrangement of the vessels may be mentioned:—

In the greater number of cases the superficial palmar arch is diminished, and gives off fewer digital branches than usual. Generally only one branch is wanting, viz., that which supplies the adjacent sides of the fore and middle fingers; but sometimes two or three branches are absent, or even all four, as when the ulnar artery, after giving branches to the short muscles of the little finger, ends in the deep palmar arch. In the last-mentioned case, which is rare, it is obvious that the superficial arch is altogether wanting.

These various deficiencies in the superficial palmar arch and its branches are usually compensated by an enlargement of the deep arch, the palmar interosseous branches of which, being increased in size, divide at the clefts of the fingers, and form such collateral digital branches as are not derived from the usual source. But a defective superficial arch may, as

before mentioned, be reinforced from other vessels, viz., from the superficial volar, from an enlarged median artery, or from a large dorsal interosseous branch.

It sometimes, but less frequently, happens that the deep system of vessels is deficient, in which case the superficial arch may supply all the digital arteries to the thumb and fingers,

Fig. 369.—AN ENLARGED MEDIAN ARTERY REPLACING THE RADIAL AND ULNAR IN THE SUPPLY OF PALMAR ARTERIES TO HALF THE DIGITS. (Tiedemann.)  $\frac{1}{4}$

1, lower part of brachial artery; 2, radial artery, not giving any superficial volar branch; 3, recurrent radial; 4, ulnar artery, passing over the wrist and supplying at 4', 4', 4', digital arteries to half the hand; 5, the enlarged median artery, passing in front of the annular ligament of the wrist and supplying 5', 5', digital branches to the outer half of the hand.

or one or more of these may be derived from the superficial volar, the median, or a dorsal interosseous artery.

The superficial palmar arch has occasionally been seen double, the superficial part of the ulnar artery and the superficial volar branch of the radial being each divided into two communicating branches. Two of the digital arteries frequently arise by a common trunk.

#### SURGICAL ANATOMY OF THE ULNAR AND RADIAL ARTERIES.

In the upper third of the forearm, the depth at which the *ulnar artery* is placed beneath the muscles, and the origin of the large interosseous branch prevent the application of a ligature to this part of the vessel.

In the middle third, the artery may be tied as it approaches the ulnar nerve. An incision is made along a line drawn from the internal condyle of the humerus to the pisiform bone, and the intermuscular space between the flexor sublimis digitorum and flexor carpi ulnaris opened up, when the ulnar nerve comes into view. The artery, accompanied by its *venæ comites*, will be found to the outer side of the nerve, a little way removed from it, and under cover of the flexor sublimis digitorum, if the spot selected be above the middle of the forearm.

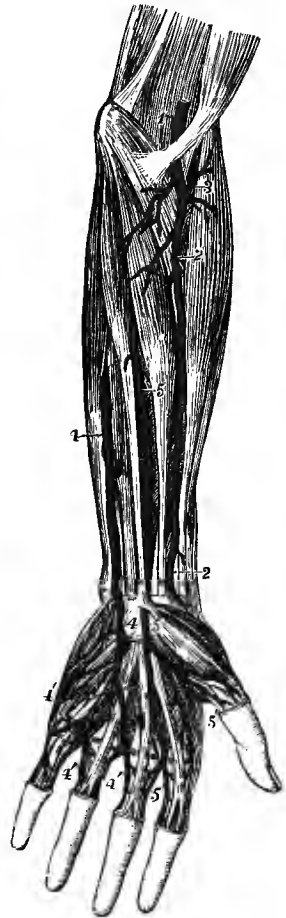
Near the wrist, the artery is readily exposed by an incision along the outer border of the flexor carpi ulnaris tendon. After drawing inwards this tendon, a deep layer of fascia is seen covering the vessels, and on dividing this the artery is laid bare with the nerve to its inner side.

The *radial artery* may be ligatured in any part of its extent in the forearm by means of an incision carried through the skin and fascia in the course of the vessel, *i.e.*, along a line from the centre of the bend of the elbow to the fore part of the styloid process of the radius. In the upper half of the forearm, the fleshy belly of the supinator longus will have to be drawn outwards; in the lower half, the artery lies close to the outer side of the tendon of the flexor carpi radialis, which forms a guide to the vessel. When exposing the radial artery near the wrist its superficial position must be borne in mind, and the first incision should divide only the skin and fat.

At the wrist, the radial artery may also be readily secured, the incision being made midway between the tendons of the extensor ossis metacarpi and longus pollicis. The radial vein is at once exposed, and must not be mistaken for the artery, which is much deeper and lies obliquely to the line of the incision. It is generally preferable, however, to tie the artery at the lower part of the forearm.

*Collateral circulation.*—The communications between the branches of the ulnar and radial arteries, about the wrist and in the palm, are so numerous and free that the circulation in the hand is carried on without difficulty after occlusion of either of the main trunks.

It is important to bear in mind, in connection with wounds of the palmar arteries, the possibility of blood being conveyed to the hand by other channels than the ulnar and radial trunks, viz., by a large median artery, or a terminal branch of the anterior interosseous,



## DESCENDING THORACIC AORTA.

From the point at which its arch is considered to terminate—the lower margin of the fourth dorsal vertebra, the aorta descends along the spine to the fourth lumbar vertebra, where it divides into the common iliac arteries. The direction of this part of the vessel is not vertical, for, as it follows the bend of the spine, upon which it rests, it is necessarily concave forwards in the dorsal region, and convex forwards in the lumbar. Again, as its commencement is on the left side of the bodies of the vertebræ, and its termination nearly in the middle line, there is a general inclination inwards in its whole length, but more marked in the upper half. Within the thorax, where the offsets are small, the aorta diminishes only slightly in size (from 23 to 21 mm.); in the abdomen the diminution is considerable (from 21 to 17 mm.), in consequence of large branches being furnished to the viscera of that cavity.

That part of the descending aorta which is situated in the thorax is called the *descending thoracic aorta*; it extends from the lower border of the fourth dorsal vertebra, on the left side, to the upper margin of the opening between the crura of the diaphragm below the last dorsal vertebra, and has a length of from seven to eight inches. It lies in the posterior mediastinum, resting against the spine, and covered in front by the root of the left lung, the pericardium, and the vertebral portion of the diaphragm; on the left side it is in contact with the corresponding pleura and lung; and close to it on the right side are the large azygos vein, the thoracic duct, and the œsophagus. The œsophagus, however, towards the lower part of the thorax is in front of the artery, and near the diaphragm gets somewhat to the left side. The left or small azygos veins lie behind the descending thoracic aorta.

The BRANCHES derived from the descending thoracic aorta are numerous, but small. They are distributed to the walls of the thorax, and to the viscera contained within it—the parietal branches being the larger and more numerous.

A. Branches to the viscera:—

The **pericardial** branches are some very small and irregular vessels which pass forwards and ramify on the pericardium.

The **bronchial arteries** are the nutrient arteries of the substance of the lung, and they supply also the bronchial glands, and in part the pericardium and œsophagus. These vessels vary frequently in number, and in their mode of origin. On the right side there is usually one bronchial artery which arises from the first aortic intercostal artery, or by a common trunk with the upper left bronchial artery from the descending thoracic aorta; on the left side there are generally two arteries, both of which arise from the descending thoracic aorta, one near the commencement of that trunk, and the other, named *inferior bronchial*, lower down. Each artery is directed to the back part of the corresponding bronchus, along which it runs, dividing and subdividing with the successive bronchial ramifications in the substance of the lung.

**Varieties.**—The place of origin of the bronchial arteries is liable to much variation. The artery of the right side has been found to arise singly from the aorta, from the internal mammary, or from the inferior thyroid. The bronchial arteries of the two sides have been seen to arise by a common trunk from the subclavian (Haller). Two common trunks, each furnishing a branch to the right and left lungs, have been observed in a single case to descend into the thorax, after arising, one from the internal mammary, and the other from the superior intercostal artery (R. Quain). In some cases they arise from the under surface of the arch, instead of from the descending thoracic aorta. Instances also occur of two distinct bronchial arteries for each lung.

The **œsophageal arteries** are variable in size and number. There are usually four or five, which arise from the fore part or right side of the aorta, and run downwards upon the œsophagus, supplying its coats. Their lower branches anastomose

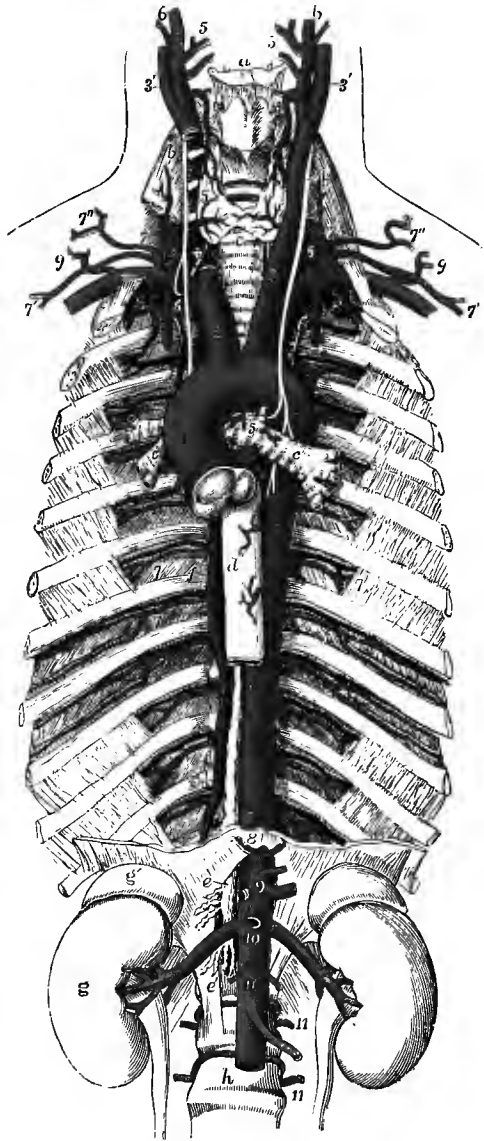


with the ascending offsets of the coronary artery of the stomach and with the phrenic arteries, while their upper branches communicate with those of the inferior thyroid artery.

**Posterior mediastinal** branches small and irregular, supply the glands, areolar

Fig. 370.—THE THORACIC AND GREATER PART OF THE ABDOMINAL AORTA, &c. (Allen Thomson.)  $\frac{1}{4}$

For the general description of this figure, see p. 383. The following numbers indicate the branches of the aorta: 1, placed between the origins of the right and left coronary arteries; 2, innominate; 3, left carotid; 4, left subclavian; 5, bronchial; 6, 6, cesophageal; 7, 7, intercostal arteries (sixth and seventh); 8, inferior phrenic; 9, coeliac axis; 10, below the superior mesenteric and opposite the origin of the renal arteries; 11, 11, two of the lumbar arteries.



tissue, and other structures in the posterior mediastinum, as well as the vertebral portion of the diaphragm.

B. Branches to the wall of the thorax:—

The **intercostal arteries** (iv) arise from the posterior part of the aorta, and run outwards upon the bodies of the vertebræ, to reach the intercostal spaces. They are usually nine in number—the upper two spaces being supplied by the superior intercostal branch of the subclavian artery. Owing to the position of the aorta on the left side of the spine, the right aortic intercostals cross over the front of the vertebræ, furnishing small branches to their interior, and are longer than the arteries of the left side. The vessels of both sides pass outwards behind the pleura, and are crossed by the sympathetic nerve: those of the right side also pass behind the cesophagus, the thoracic duct, and the large azygos vein.

In each intercostal space the artery, passing outwards more horizontally than the ribs, crosses the space obliquely, so as to gain the lower border of the upper rib near its angle. It lies upon the deep surface of the external intercostal muscle, and in the back of the space is separated from the pleura only by a thin fascia, but farther outwards it lies between the two layers of intercostal muscles. Extending forwards in the subcostal groove of the upper rib, it finally

anastomoses with one of the anterior intercostal branches derived from the internal mammary artery.

The first of the aortic intercostal arteries has an anastomosis with the superior intercostal artery from the subclavian, and not unfrequently sends upwards a considerable branch, which supplies the second space wholly or in great part. The last two are prolonged into the abdominal wall, where they communicate with the epigastric artery, and with the lumbar branches of the abdominal aorta.

Each intercostal artery is accompanied, as it runs outwards between the ribs, by a corresponding vein, and by an intercostal nerve; the vein being usually above, and the nerve below it.

*Branches.*—(a) The *posterior* or *dorsal* branch of each intercostal artery passes backwards to the inner side of the superior costo-transverse ligaments, along with the posterior branch of the corresponding nerve; and, having furnished an offset to the spinal canal, reaches the muscles of the back, and divides into an internal and an external branch. The internal branch is directed towards the spinous processes, on or through the multifidus spinæ, and ramifies in the muscles and the skin. The external branch turns outwards under the longissimus dorsi, and is distributed between that muscle and the ilio-costalis; some twigs reach the superficial muscles and the integuments.

The *spinal* branch is distributed partly to the cord and its membranes, and partly to the bones, in the manner described on p. 422.

(b) The *collateral intercostal* branch, long and slender, arises near the angle of the upper rib of the space, inclines downwards, and is continued along the border of the lower rib, to anastomose in front with an anterior intercostal branch of the internal mammary artery. There are thus in each intercostal space two terminal branches of the intercostal artery communicating with branches of the internal mammary.

Both the main trunk and the collateral branch give offsets to the intercostal muscles and ribs, and small twigs which anastomose beneath the pleura with one another and with branches of the internal mammary and bronchial arteries (see p. 428). Other branches supply the muscles covering the thorax and anastomose with the thoracic branches of the axillary artery, and one accompanies the lateral cutaneous branch of the intercostal nerve to the skin. From the arteries in the third, fourth, and fifth spaces branches are sent to the mammary gland in the female.

Small anastomotic branches may often be found uniting adjacent intercostal arteries both in front of and behind the necks of the ribs. Similar anastomoses occur between the posterior branches behind the transverse processes.<sup>1</sup>

*Varieties.*—The number of trunks by which the intercostal arteries arise is subject to much variation: two or even three arteries of the same side, especially the upper ones, sometimes arise by a single stem. One or two of these vessels may be absent on one side, the corresponding spaces being supplied by branches from the neighbouring intercostal arteries.

#### ABDOMINAL AORTA.

The aorta, after having passed the diaphragm, is thus named. It commences about the lower border of the last dorsal vertebra, and terminates below by dividing into the two common iliac arteries. The bifurcation usually takes place about half-way down the body of the fourth lumbar vertebra and a little to the left of the middle line,—a point which is nearly on a level with a line drawn from the highest part of one iliac crest to the other, and which corresponds to a spot on the front of the abdomen slightly below and to the left side of the umbilicus. Its length is about five inches.

<sup>1</sup> W. J. Walsham, Journ. Anat., xvi, 443, 1882.

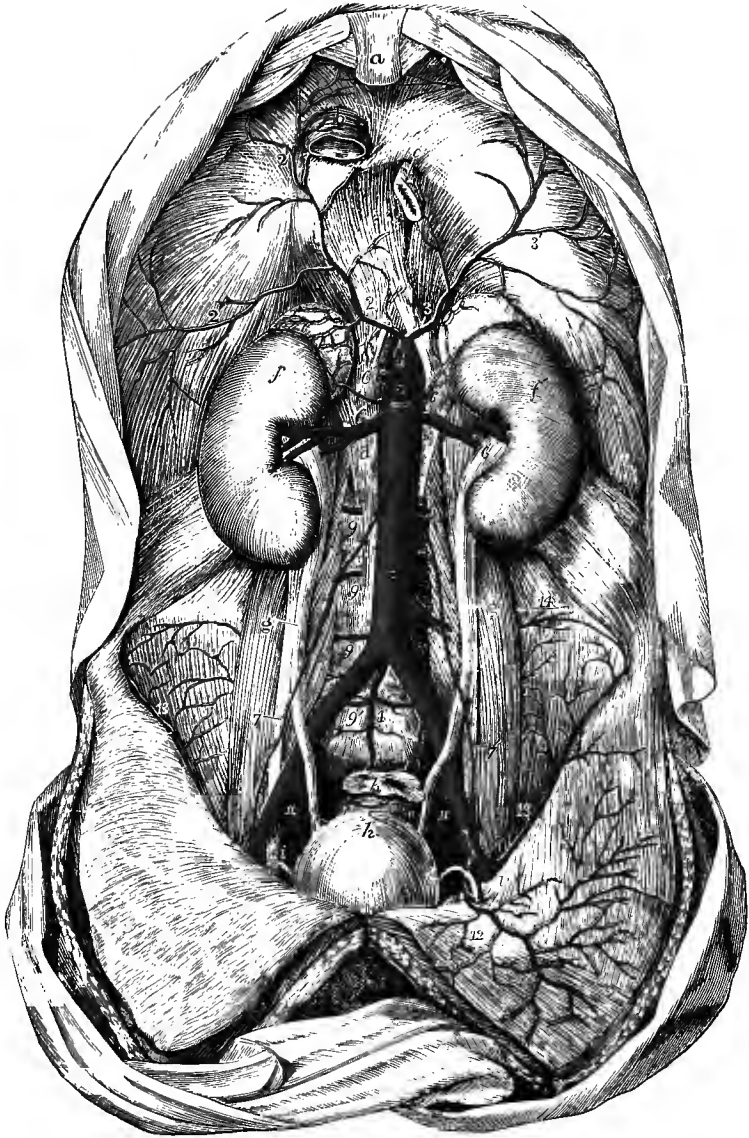


Fig. 371.—THE ABDOMINAL AORTA AND ITS PRINCIPAL BRANCHES. (Tiedemann.)  $\frac{1}{2}$

*a*, ensiform process; *b*, inferior vena cava, passing through the tendon of the diaphragm; *c*, cesophagus, passing through the muscular portion; *d* and *e*, right and left crura; *f*, *f'*, right and left kidneys with the suprarenal bodies; *g*, *g'*, ureters; *h*, urinary bladder; *i*, *i'*, right and left vasa deferentia, passing from the internal abdominal rings to the bladder; *k*, rectum, divided near its upper end; 1, 1, abdominal aorta; 1', middle sacral artery; 2, 2', right, 3, 3', left inferior phrenic artery, arising by a short common stem from the front of the aorta immediately below the meeting of the crura of the diaphragm; 4, celiac axis; 5, superior mesenteric artery; 6, 6, renal arteries; 6', 6', suprarenal arteries, arising partly from the aorta and partly from the inferior phrenic; 7, 7', placed on the front of the aorta below the origin of the spermatic arteries; 7, 7', placed on the psoas muscles, point to the right and left spermatic arteries as they descend to the internal abdominal rings; 8, inferior mesenteric artery; 9, 9, 9, lumbar arteries; 10, 10, common iliac arteries; 11, between the external and internal iliac arteries; 12, left epigastric artery; 13, circumflex iliac; 14, branches of the ilio-lumbar.

The anterior surface of the abdominal aorta is successively in apposition with the pancreas and the splenic vein, the left renal vein, the third portion of the duodenum, and the peritoneum. The vena cava lies along its right side, the right crus of the diaphragm being interposed at the upper part; close to the same side are the thoracic duct and the large azygos vein, which are placed between the aorta and the crus of the diaphragm. The aorta is also covered in front by the solar and aortic plexuses of the sympathetic nerve, by numerous lymphatic vessels and glands, and by a layer of dense areolar tissue. Behind it are the bodies of the vertebræ and the left lumbar veins.

**BRANCHES.**—The abdominal aorta gives numerous branches, which may be divided into two sets, viz., those which supply the viscera, and those which are distributed to the walls of the abdomen. The former consists of the cœliac artery, the superior mesenteric, the inferior mesenteric, the suprarenal, the renal, and the spermatic arteries; while in the latter are included the phrenic, the lumbar, and the middle sacral arteries. The first three of the visceral branches are single arteries.

**Varieties.**—*Place of division.*—In more than three-fourths of a considerable number of cases, the aorta divided either upon the fourth lumbar vertebra, or upon the intervertebral disc below it; in one case out of nine it was below, and in about one out of eleven above the spot thus indicated: in ten bodies out of every thirteen, the division of the great artery took place within half an inch above or below the level of the iliac crest (R. Quain). An instance of bifurcation immediately below the origin of the right renal artery is recorded by Haller; and division opposite the second lumbar vertebra has been observed by Boinet, Cruveilhier, and Eckhard.

*Unusual branch.*—Two remarkable cases are recorded of the existence of a large pulmonary branch, which arose from the abdominal aorta close to the cœliac axis, and, after passing upwards through the œsophageal opening in the diaphragm, divided into two branches, which were distributed to the lungs near their bases.

#### A.—VISCERAL BRANCHES OF THE ABDOMINAL AORTA.

The **cœliac artery** or **axis (i)** is a short wide vessel, usually not more than half an inch in length, which arises from the front of the aorta close to the margin of the opening in the diaphragm. It is directed nearly horizontally forwards at the upper border of the pancreas, being placed behind the small omentum and close to the left side of the Spigelian lobe of the liver. The two semilunar ganglia of the sympathetic are also contiguous to it, one on each side. The artery divides into three branches, viz., the coronary artery of the stomach, the hepatic, and the splenic, which separate simultaneously from the end of the trunk like radii from an axis.

**Varieties.**—The cœliac axis is occasionally partly covered at its origin by the diaphragm. It may be longer than usual, in which case its branches are not given off together; or it may be entirely wanting, the coronary, hepatic, and splenic arteries arising separately from the aorta. In some cases the cœliac artery gives off only two branches at its division (the coronary and the splenic), the hepatic being supplied from another source. Rarely, it gives more than three branches to the viscera, the additional vessel being a second coronary, or a separate gastro-duodenal artery. One or both phrenic arteries are frequently derived from this trunk. Cases have been met with in which a connection existed between the cœliac axis and the superior mesenteric artery close to their origin.

**A. The coronary artery of the stomach (iii-iv)**, the smallest of the three branches derived from the cœliac axis, runs at first upwards and to the left side, in a special fold of the peritoneum, and reaches the cardiac orifice of the stomach. It then turns sharply forwards and downwards, and is continued from left to right along the small curvature of the stomach, distributing branches to both surfaces

of that viscus, and finally inosculating with the pyloric branch of the hepatic artery.

Where it first reaches the stomach, this artery sends upwards *œsophageal* branches, which anastomose with the aortic *œsophageal* arteries. The branches to the stomach, descending on the front and back of the organ, anastomose with branches from the arterial arch on the great curvature.

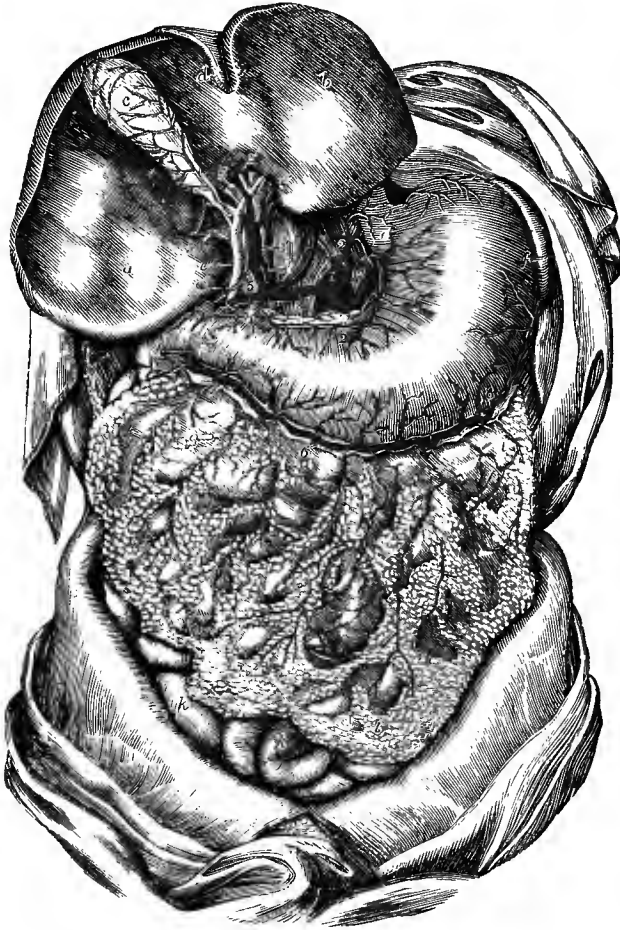


Fig. 372.—THE ARTERIES OF THE STOMACH, LIVER, AND OMENTUM. (Tiedemann.)  $\frac{1}{2}$

The liver is turned up so as to show its lower surface with the portal fissure, and the vessels and ducts entering it : *a*, right lobe of liver ; *b*, left lobe ; *c*, gall-bladder ; *c'*, hepatic ducts ; *a''*, common bile-duct ; *d*, umbilical fissure and round ligament ; *e*, cardiac orifice of stomach ; *f*, on the great curvature of the stomach near its cardiac end, points to the spleen ; *g*, pylorus ; *h*, duodenum ; *i*, *i*, great omentum ; *k*, *k*, coils of small intestine in the lower part of the abdomen ; 1, upon the trunk of the abdominal aorta, below the root of the inferior phrenic arteries, and above the celiac axis ; 2, placed on the meeting of the crura of the diaphragm, coronary artery of the stomach ; 2', the same artery proceeding round the small curvature of the stomach and ending by inosculating with the pyloric ; 3, the main hepatic artery, continued at 3', as proper hepatic artery to the liver ; 4, pyloric artery ; 4', another pyloric branch ; 5, trunk of portal vein ; 5', 5', 5', its branches in the transverse fissure ; 6, gastro-duodenal artery ; 6', 6', its continuation as right gastro-epiploic ; 7, on the left crus of the diaphragm, splenic artery ; 8, its left gastro-epiploic branch, proceeding round the great curvature of the stomach to communicate with the right gastro-epiploic artery ; both of these vessels are seen giving long epiploic as well as gastric branches.

**Varieties.**—The coronary artery of the stomach is sometimes given off directly from the aorta, and is occasionally replaced by two separate vessels. It sometimes furnishes the left or an additional hepatic artery. According to Hyrtl there is constantly a small branch which ascends to the left end of the transverse fissure of the liver and anastomoses with an offset of the left hepatic artery: in the infant, this branch is relatively of larger size (Toldt).

**B. The hepatic artery (ii)** is in the adult intermediate in size between the coronary and splenic arteries, but in the fœtus it is the largest of the three. It is directed at first forwards and to the right, passing over the upper border of the pancreas, and below the foramen of Winslow, to the upper margin of the pyloric orifice of the stomach, where it gives off its gastro-duodenal branch. It then ascends between the layers of the small omentum, and in front of the foramen of Winslow, towards the transverse fissure of the liver; and in this course it lies upon the portal vein, and to the left of the common bile-duct. Near the liver, it ends by dividing into right and left branches, which supply the corresponding lobes of that organ.

**Branches.**—(a) The *gastro-duodenal artery* (iv) descends near the pylorus behind the first part of the duodenum, and divides at the lower border of that viscus into a smaller superior pancreatico-duodenal and a larger right gastro-epiploic artery. The *superior pancreatico-duodenal artery* descends along the inner margin of the duodenum, between that and the pancreas, and, after furnishing several branches to both these organs, anastomoses with the inferior pancreatico-duodenal from the superior mesenteric artery. The *right gastro-epiploic artery*, the continuation of the gastro-duodenal, runs from right to left along the great curvature of the stomach, between the layers of the great omentum, and ends by inosculating with the left gastro-epiploic from the splenic artery. It sends branches upwards to both surfaces of the stomach, and long slender vessels downwards in the omentum.

(b) The *pyloric artery*, descending from its origin and coming in contact with the stomach at the upper border of the pylorus, extends from right to left along the small curvature, and inosculates with the coronary artery. It is sometimes a branch of the gastro-duodenal.

(c) The *right hepatic* branch inclines outwards behind the hepatic and cystic ducts (occasionally in front of the hepatic), giving off the cystic artery as it passes these, and reaches the right end of the transverse fissure, where it divides into two or three branches as it enters the liver substance. The *cystic artery* (vi) turns forwards between the cystic and hepatic ducts to the neck of the gall-bladder, and divides into two smaller branches, of which one ramifies between the coats on the inferior surface, the other between the bladder and the liver.

(d) The *left hepatic* branch, smaller than the right, from which it diverges at an acute angle, gives off one or two branches to the Spigelian lobe, and enters the liver at the left end of the transverse fissure. The ramifications of the hepatic artery in the liver accompany the divisions of the portal vein and hepatic duct.

**Varieties.**—The hepatic artery sometimes arises from the superior mesenteric artery, or from the aorta itself. The left hepatic artery is not unfrequently derived from the coronary artery of the stomach, occasionally from the superior mesenteric, rarely from the splenic. Accessory hepatic arteries are sometimes met with, generally coming from the coronary artery, less frequently from the superior mesenteric, the aorta, the right renal, or the inferior mesenteric. The hepatic artery has been found to furnish a phrenic branch. The cystic artery has been seen arising from the superior mesenteric.

**C. The splenic artery (ii)**, in the adult the largest branch of the cœliac axis, supplies the spleen, and in part the stomach and pancreas. Waving and often tortuous in its course, it passes along the upper border of the pancreas, across the front

of the left kidney, and divides near the spleen into several branches, which are distributed to that organ and to the left portion of the stomach.

*Branches.*—(a) *Pancreatic* branches, variable in size and number, are given off while the artery is passing along the pancreas, the body and tail of which they supply. One of larger size not unfrequently runs from left to right in the direction of the pancreatic duct, and is called *arteria pancreatica magna*.

(b) The *splenic* branches are five or six, or even more, in number, and vary in length and size; they pass between the layers of the lieno-renal ligament, and enter the spleen by the hilum on its anterior surface to ramify within that organ.

(c) The *short gastric* branches (*vasa brevia*), from four to six in number, are directed forwards in the gastro-splenic omentum, some issuing from the trunk of the splenic artery, others from its terminal branches: they reach the left extremity of the stomach, where they divide and spread out between its coats, communicating with the coronary and left gastro-epiploic arteries.

(d) The left *gastro-epiploic artery* runs from left to right along the great curva-

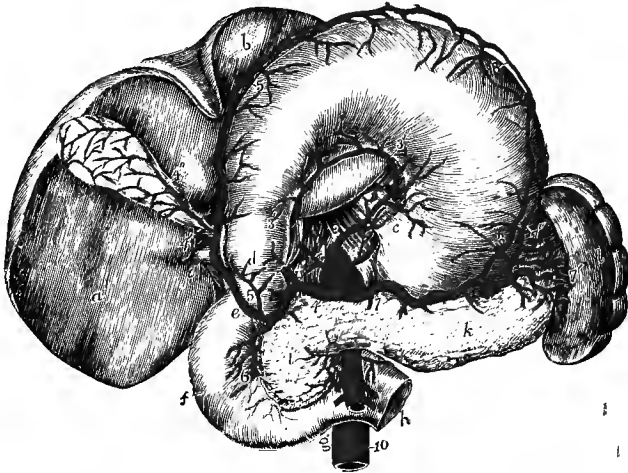


Fig. 373.—THE ARTERIES OF THE STOMACH, DUODENUM, PANCREAS, AND SPLEEN. (Tiedemann.) †

The stomach and liver are turned upwards; the jejunum is divided at its commencement: *a*, right lobe of liver; *b*, left lobe; *c*, cardiac orifice of stomach; *d*, pylorus; *e*, first part, *f*, second part, and *g*, third part of duodenum; *h*, commencement of jejunum; *i*, head, and *k*, body of pancreas; *l*, spleen; *1*, *1'*, right and left inferior phrenic arteries passing from the aorta upon the crura of the diaphragm; *2*, placed on the aorta close to the celiac axis; *3*, *3'*, coronary artery; *4*, common hepatic; *4'*, proper hepatic artery and its right branch; *4''*, cystic artery; *5*, *5*, right gastro-epiploic, and *6*, superior pancreatico-duodenal, the two divisions of the gastro-duodenal; *7*, splenic artery; *7'*, splenic branches; *7''*, one of the *vasa brevia* to the stomach; *8*, *8*, left gastro-epiploic artery, uniting with the right on the great curvature of the stomach; *9*, trunk of the superior mesenteric artery, giving off the inferior pancreatico-duodenal; *10*, inferior mesenteric.

ture of the stomach, supplying branches to both surfaces of the stomach and to the omentum on the left side, and inosculates with the right gastro-epiploic branch from the hepatic artery.

*Varieties.*—These are not frequent. The splenic artery has been seen to give off the left hepatic artery, the middle colic artery, and in one case, together with the last, the inferior mesenteric artery.

The **superior mesenteric artery** (*i*) supplies the whole of the small intestine beyond the duodenum, and half of the large intestine. It arises from the fore part of the aorta, a little below the celiac axis, and under cover of the pancreas and

splenic vein. Emerging below the pancreas, it crosses the third part of the duodenum, and descends between the layers of the mesentery. Much diminished in size owing to the large number of its branches, it inclines below towards the right iliac fossa, and ends near the junction of the ileum with the large intestine by inosculating with its own ileo-colic branch.

*Branches.*—(a) The *inferior pancreatico-duodenal*, generally arising from the first intestinal branch and directed transversely to the right behind the main trunk, runs

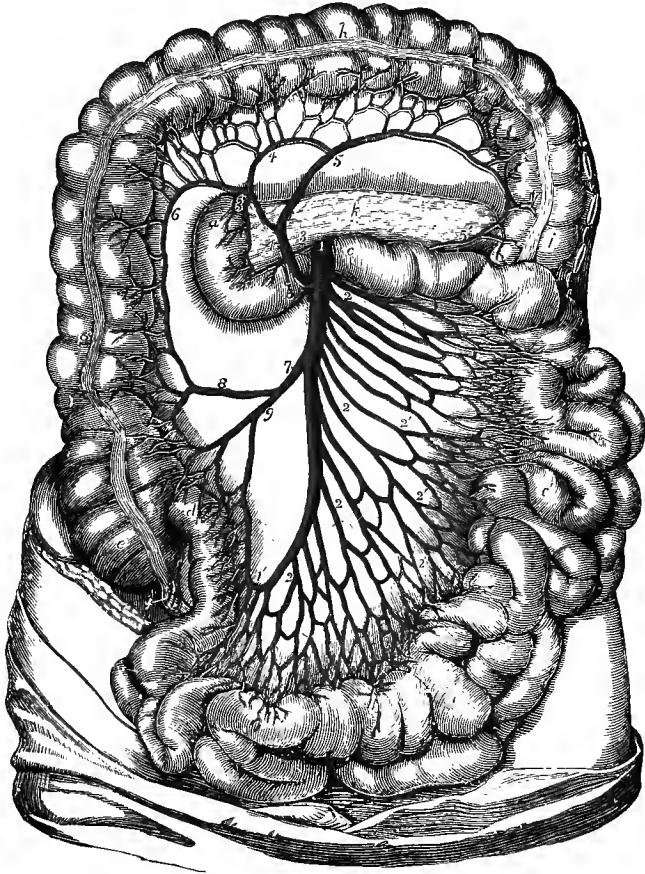


Fig. 374.—THE SUPERIOR MESENTERIC ARTERY AND ITS BRANCHES. (Tiedemann.)  $\frac{1}{4}$

The transverse colon is turned upwards, the jejunum and ileum are drawn to the left, and the posterior layer of the transverse mesocolon and the anterior layer of the mesentery are removed: *a*, second part of the duodenum; *b*, third part; *c*, commencement of the jejunum; *c'*, *c'*, jejunum and ileum; *d*, termination of the ileum in the large intestine; *e*, cæcum; *f*, vermiform appendix; *g*, ascending colon; *h*, transverse colon; *i*, descending colon; *k*, pancreas; 1, trunk of the superior mesenteric artery; 1', its termination where it inosculates with a branch of the ileo-colic artery; 2, 2, intestinal branches; 2', 2', their loops in the mesentery; 3, inferior pancreatico-duodenal branch, passing to the right to unite with 3', the branch from the gastro-duodenal; 4, middle colic branch; 5, its left branch, passing at 5', to unite with a branch of the left colic of the inferior mesenteric; 6, its right branch; 7, right colic and ileo-colic arteries in one trunk; 8, right colic, uniting by a loop with the middle colic; 9, ileo-colic, uniting with the end of the superior mesenteric artery.

along the concave border of the duodenum, and joins with the superior pancreatico-duodenal artery.

(b) The *intestinal* branches, supplying the jejunum and ileum, spring from the



convex or left side of the vessel. They are usually twelve or more in number, and are all included between the layers of the mesentery. They run parallel to one another for some distance, and then divide into two branches, each of which forms an arch with the neighbouring branch. From the first set of arches other branches issue, which divide and communicate in the same way, until finally, after forming from three to five such tiers of arches, the smaller as they are nearer to the intestine, the ultimate divisions proceed directly to the intestine, spreading upon both sides, and ramifying in its coats. Small offsets are also furnished to the glands and other structures between the layers of the mesentery.

(c) The *colic* branches arise from the right or concave side of the artery, and are usually three in number.

1. The *ileo-colic artery*, the first in order from below upwards, inclines downwards and to the right side, towards the cæcum, and divides into two branches: one of these descends to inosculate with the termination of the mesenteric artery itself, and to form an arch, from the convexity of which branches proceed to supply the junction of the small with the large intestine, and the cæcum and its appendix; the other division ascends and inosculates with the next mentioned branch. The ileo-colic artery is not always distinct from the termination of the superior mesenteric.

2. The *right colic artery* passes transversely towards the right side, beneath the peritoneum, to the middle of the ascending colon, opposite which it divides into two branches: of these one descends to communicate with the ileo-colic artery, while the other ascends to join in an arch with the middle colic. This artery and the ileo-colic often arise by a common trunk.

3. The *middle colic artery* runs forwards between the layers of the transverse mesocolon towards the transverse colon, and divides in a manner exactly similar to that of the vessels just noticed. One of its branches inclines to the right, where it inosculates with the preceding vessel; the other passes to the left side, and forms a similar communication with the left colic branch, derived from the inferior mesenteric artery. From the arches of inosculation thus formed, small branches pass to the colon for the supply of its coats.

Those branches of the superior mesenteric artery which supply the ascending colon have a layer of peritoneum only on their anterior aspect; the others lie between two strata.

**Varieties.**—The number of the branches of the superior mesenteric artery, both intestinal and colic, is by no means constant. It also frequently gives off accessory branches to the neighbouring viscera; of these that to the liver is the most common. An offset of this artery may replace the gastro-duodenal or its chief branch, the right gastro-epiploic, or it may give accessory pancreatic and splenic branches (Hyrtl), or the artery to the gall-bladder. It has also been seen to give off the left colic artery, and in one case in which the inferior mesenteric was absent also the superior hæmorrhoidal (Fleischmann). A rare anomaly is the presence of an omphalo-mesenteric artery, arising either from the main stem or from one of the branches of the superior mesenteric. In one case it ran directly to the umbilicus, where it gave a branch to the urachus (Haller). In another it reached the anterior wall of the abdomen rather below the umbilicus, and after giving a branch to the rectus, which anastomosed with the deep epigastric, it terminated by ascending in the round ligament, and forming a capillary network in the falciform ligament of the liver (Hyrtl).

The **inferior mesenteric artery (iii-iv)** arises from the front of the aorta between one and two inches above its bifurcation, and supplies the lower half of the large intestine. Inclining slightly to the left, it passes downwards close to the aorta, gives off branches to the descending colon and the sigmoid flexure, and is continued under the name of *superior hæmorrhoidal artery* over the left common iliac vessels to the back of the rectum.

**Branches.**—(a) The *left colic artery* is directed to the left side behind the peri-

toneum, and across the left kidney, to reach the descending colon. It divides into two branches, which form a series of arches in the same way as the colic vessels of the opposite side. One of these two branches passes upwards along the colon, and inosculates with the left branch of the middle colic; while the other descends and anastomoses with the sigmoid artery.

(b) The *sigmoid artery* runs obliquely downwards to the sigmoid flexure of the colon, where it divides into branches, which form arches like the other arteries; the highest branch joins the left colic, the lower ones turn downwards to the rectum and

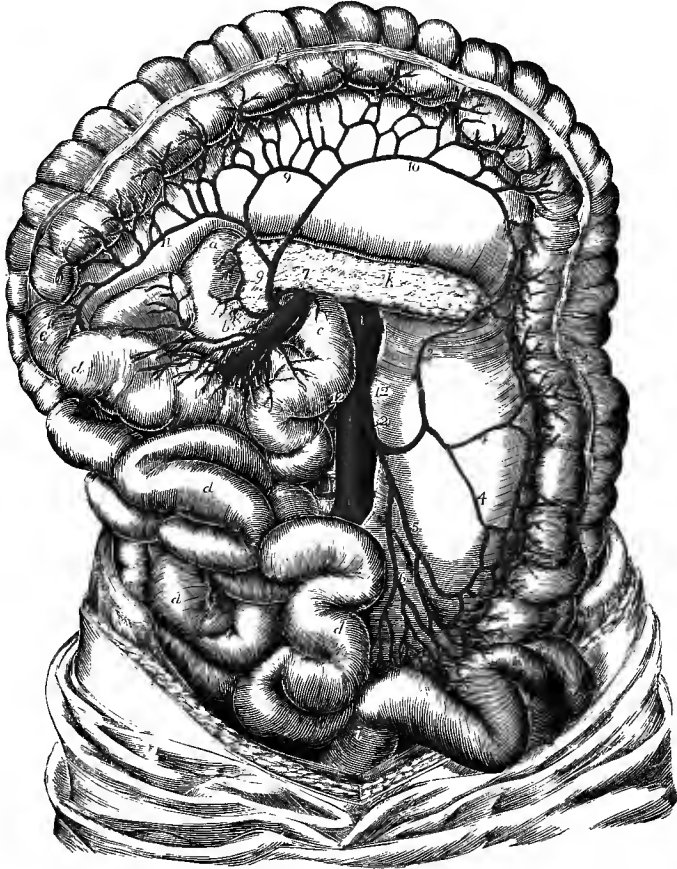


Fig. 375.—THE INFERIOR MESENTERIC ARTERY. (Tiedemann.)  $\frac{1}{4}$

The jejunum and ileum with the superior mesenteric artery are turned towards the right side, the pancreas is exposed, and the large intestine is stretched out: *a, b*, duodenum; *c*, commencement of the jejunum; *d, d*, jejunum and ileum; *e*, ascending colon; *f*, transverse colon; *g*, descending colon; *h*, sigmoid flexure; *i*, commencement of the rectum; *k*, pancreas; *l*, placed on the trunk of the abdominal aorta at the origin of the renal arteries; *l'*, on the same at the origin of the inferior mesenteric; *l''*, near the division into the common iliac arteries; *2*, inferior mesenteric, giving off the left colic; *3*, ascending branch of the left colic; *4, 4*, descending branch of the same; *5*, sigmoid artery; *6*, superior hæmorrhoidal artery; *7*, trunk of the superior mesenteric, issuing from behind the pancreas; *8*, some of its intestinal branches; *9*, middle colic artery; *10*, its left branch, forming a loop of communication with the left colic; *11*, its right branch; *12, 12*, spermatic arteries.

anastomose with the following artery. Instead of a single sigmoid artery, two or three branches are sometimes present.

(c) The *superior hæmorrhoidal artery*, the continuation of the inferior mesenteric, passes downwards, over the left common iliac vessels, into the pelvis behind the rectum, lying at first in the mesorectum, and then divides into two branches which extend one on each side of the intestine towards the lower end. About five inches from the anus these subdivide each into three or four branches which pierce the muscular coat some two inches lower down. In the wall of the intestine, these arteries, placed at regular distances from each other, descend between the mucous and muscular coats to the end of the gut, where they communicate in loops opposite the internal sphincter, and anastomose with the middle and inferior hæmorrhoidal arteries.

**Varieties.**—Absence of the inferior mesenteric artery has been met with, its branches being given off by the superior mesenteric. It has also been found giving origin to the middle colic artery, and accessory branches to the liver and kidneys.

A *middle mesenteric artery*, arising from the common iliac and supplying vessels to the transverse and descending colon, has been seen by Hyrtl.

**Anastomoses on the alimentary canal.**—The arteries distributed to the alimentary canal communicate freely with each other over the whole length of that tube. The arteries of the great intestine, derived from the two mesenteric trunks, form a series of vascular arches along the colon and rectum, at the lower end of which they anastomose with the middle and inferior hæmorrhoidal arteries, given off from the internal iliac and pudic arteries. The branches from the left side of the superior mesenteric form another series of arches along the small intestine, which is connected with the former by the ileo-colic artery. Farther, the inferior pancreatico-duodenal branch of the superior mesenteric joins upon the duodenum with the superior pancreatico-duodenal artery. The latter is derived from the same source as the pyloric artery; and so likewise, through the coronary artery of the stomach and its ascending branches, a similar connection is formed with the œsophageal arteries, even up to the pharynx.

The **middle suprarenal or capsular arteries (vi)** are two very small vessels which arise from the aorta on a level with the superior mesenteric artery, and pass obliquely outwards upon the crura of the diaphragm to reach the suprarenal capsules, to which bodies they are distributed, anastomosing at the same time with the upper and lower suprarenal branches derived respectively from the phrenic and the renal arteries. In the foetus these arteries are relatively of large size.

**Varieties.**—This artery is often very small, its place being supplied by the superior and inferior suprarenals. The middle suprarenal sometimes gives off the spermatic artery, more frequently on the left than on the right side.

The **renal or emulgent arteries (ii)**, of large size in proportion to the bulk of the organs which they supply, arise from the sides of the aorta, about half an inch below the superior mesenteric artery, that of the right side being generally a little lower down than that of the left. Each is directed outwards so as to form nearly a right angle with the aorta. In consequence of the position of the aorta upon the spine, the right renal artery has to run a somewhat longer course than the left, and it also crosses behind the inferior vena cava. Both right and left arteries are overlapped by the accompanying renal veins. Before reaching the hilum of the kidney, each artery divides into four or five branches, the greater number of which usually lie between the vein in front and the pelvis of the ureter behind. These branches, after having passed deeply into the sinus of the kidney, subdivide and are distributed in the gland, in the manner described in the account of the structure of that organ.

Each renal artery, before entering the hilum of the kidney, furnishes one or two small branches to the suprarenal body (*inferior suprarenal arteries*), to the ureter, to the lumbar lymphatic glands, and several twigs which ramify in the connective tissue and fat around the kidney.

**Varieties.**—Irregularities of the renal arteries are met with in about 25 per cent. The commonest is the presence of an additional vessel (in about 20 per cent.), an accessory artery

arising above the normal trunk being more frequent than one arising below: the supernumerary vessel would appear to be more frequent on the left side than on the right. Three arteries on one side occur in about 3 per cent.; and in rarer cases four, five, or even six separate vessels have been seen. An intermediate condition is that in which the trunk divides into branches immediately after its origin from the aorta. An accessory renal artery may proceed from the inferior phrenic, the spermatic, a lumbar artery, or the inferior mesenteric, from the bifurcation of the aorta, or the middle sacral artery, from the common iliac (in about 1 per cent.), and very rarely from the internal or external iliac. Portal found in one instance the right and left renal arteries arising by a common trunk from the fore part of the aorta.

The branches of the renal artery, or an accessory artery, instead of entering at the hilum, sometimes reach and penetrate the gland near its upper or lower end, or on its anterior surface. The right renal artery has been seen to cross the vena cava in front instead of behind. Supernumerary branches are also often found. The most frequent are the diaphragmatic arising in common with the inferior suprarenal, the middle suprarenal, the spermatic, and one or more lumbar arteries. In rare instances a hepatic branch from the right renal, branches to the large and small intestines, and to the pancreas have been observed. (A. Macalister, "Multiple Renal Arteries," *Journ. Anat.*, xvii, 1883; Report of Committee of Collective Investigation of Anat. Soc., by Arthur Thomson, *Journ. Anat.*, xxv, 1890.)

**Spermatic and ovarian arteries (v).**—The **spermatic arteries** of the male, two small and very long vessels, arise close together from the fore part of the aorta a little below the renal arteries. Each artery is directed downwards and somewhat outwards immediately beneath the peritoneum, resting on the psoas muscle, that of the right side passing also in front of the inferior vena cava; it crosses obliquely over the ureter and the lower part of the external iliac artery, and reaches the internal abdominal ring. There it comes into contact with the vas deferens, and passes with the other constituents of the spermatic cord along the inguinal canal, forming anastomoses with the cremasteric branch of the epigastric artery. Issuing by the external abdominal ring, it descends to the scrotum, where it becomes tortuous, and, approaching the back part of the testis, divides into branches which pierce the fibrous capsule of that body. One or two branches ramify on the epididymis and anastomose with the artery of the vas deferens.

In the female, the **ovarian arteries**, corresponding to the spermatic arteries in the male, are shorter than these vessels, and do not pass out of the abdominal cavity. The origin, direction, and relations of the artery in the first part of its course are the same as in the male; but at the margin of the pelvis it inclines inwards, and, running tortuously between the layers of the broad ligament of the uterus, is guided to the attached margin of the ovary, which it supplies with branches. One small offset extends along the round ligament into the inguinal canal, another along the Fallopian tube, and a third, of considerable size, running inwards towards the uterine, joins with the uterine artery. During pregnancy the ovarian artery becomes considerably enlarged.

In early foetal life the spermatic and ovarian arteries are short, as the testes and the ovaries are at first placed close to the kidneys, but the arteries become lengthened as these organs descend to their ultimate positions. Small branches to the subperitoneal tissue are given off from the spermatic artery throughout its course, and those arising in the lower part of the abdomen take a recurrent direction in consequence of the shifting of their place of origin with the elongation of the parent vessel (C. B. Lockwood, "Development and Transition of the Testis," *Journ. Anat.*, xxii, 1888).

**Varieties.**—The spermatic artery is frequently derived from the renal, occasionally from the suprarenal, on one side. The right and left arteries occasionally arise by a common trunk. Two spermatic arteries are not unfrequently met with on one side; both of these usually arise from the aorta, though sometimes one is a branch of the renal artery. A case has occurred of three arteries on one side,—two from the aorta and the third from the renal (R. Quain).

## B. PARIETAL BRANCHES OF THE ABDOMINAL AORTA.

**Inferior phrenic arteries (v).**—The inferior phrenic or diaphragmatic arteries are two small vessels, which arise, either separately or by a short common trunk, from the aorta on a level with the upper margin of its orifice in the diaphragm, or from one of the upper branches of the aorta, most frequently the celiac axis. They soon diverge from each other, and, passing across the crura of the diaphragm, incline upwards and outwards on its under surface, the artery of the left side passing behind the œsophagus, while that of the right side passes behind the vena cava. Before reaching the central tendon of the diaphragm, each of the arteries divides into two branches, of which one runs forwards towards the anterior margin of the thorax, and anastomoses with the corresponding artery of the opposite side, and with the superior phrenic and musculo-phrenic branches of the internal mammary artery, while the other pursues a transverse direction towards the side of the thorax, and communicates with offsets of the lower intercostal arteries.

Besides supplying the diaphragm, each phrenic artery gives small branches (*superior suprarenal*) to the suprarenal body of its own side; the left artery sends some branches to the œsophagus, which anastomose with the other œsophageal arteries; and the artery of the right side gives some twigs to the upper part of the vena cava. Small offsets pass also to the liver between the layers of the peritoneum, and anastomose with branches of the hepatic artery.

**Varieties.**—The phrenic arteries vary greatly in their mode of origin, but these deviations seem to have little influence on their course and distribution. In the first place they may arise either separately, or by a common trunk; and it would appear that the latter mode of origin is nearly as frequent as the former. When the two arteries are joined at their origin, the common trunk arises most frequently from the aorta; though, sometimes, it springs from the celiac axis. When arising separately, the phrenic arteries are given off sometimes from the aorta, more frequently from the celiac axis, and occasionally from the coronary artery of the stomach, or the renal; but it most commonly happens that the artery of the right side is derived from one, and that of the left side from another of these sources. One artery has also been seen arising from the superior mesenteric. In only one out of thirty-six cases observed by R. Quain did these arteries arise as two separate vessels from the abdominal aorta. An additional phrenic artery, derived from the left hepatic, has been met with (R. Quain).

**Lumbar arteries (iv-v).**—The lumbar arteries resemble the intercostal arteries, not only in their mode of origin, but also in a great measure in the manner of their distribution. They arise from the back part of the aorta, and are usually five in number on each side. They pass outwards, the first one over the body of the last dorsal vertebra, while the others rest on the upper four lumbar vertebræ, and soon dip deeply under the psoas muscle. The upper arteries are likewise behind the pillars of the diaphragm; and those on the right side are covered by the vena cava. At the interval between the transverse processes, each lumbar artery divides into an abdominal and a dorsal branch.

**Branches.**—(a) The *abdominal* branch runs outwards, generally behind the quadratus lumborum, but that of the first artery passes in front of this muscle with the anterior division of the last dorsal nerve, and a similar position is not unfrequently taken by one or two of the lower ones. Continuing outwards between the abdominal muscles, the vessel ramifies in their substance, and the several arteries form anastomoses with one another, with the branches of the epigastric and internal mammary in front, with the terminal branches of the lowest intercostals above, and with offsets of the ilio-lumbar and circumflex iliac arteries below.

(b) The *dorsal* branch, like the posterior branch of an intercostal artery, gives off immediately after its origin an offset to the spinal canal, and then, proceeding

backwards between the transverse processes with the posterior division of the corresponding spinal nerve, divides into smaller vessels which are distributed to the muscles and integument of the back.

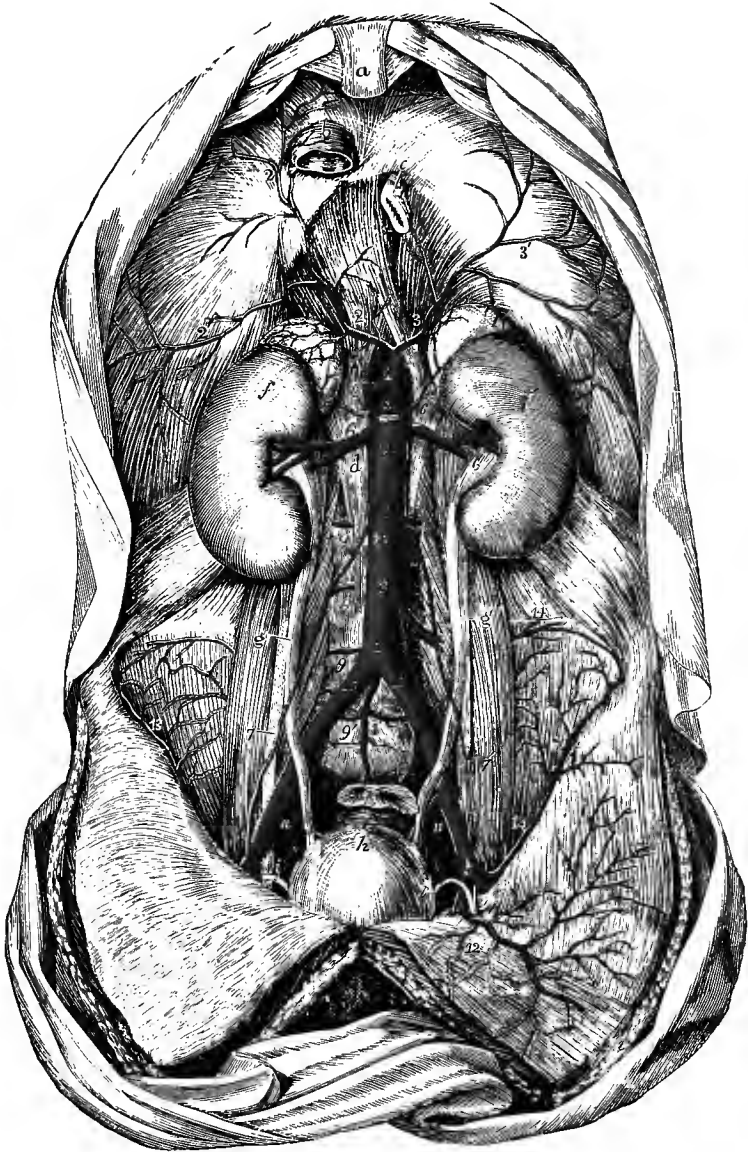


Fig. 376.—THE ABDOMINAL AORTA AND ITS PRINCIPAL BRANCHES. (Tiedemann.) 4

For the detailed description of this figure, see p. 457. 6, renal arteries; 6', 6', middle suprarenal arteries; the upper suprarenal arteries are seen proceeding from the inferior phrenic; 7, placed on the abdominal aorta below the origin of the spermatic arteries; 7', lower down, the same arteries descending on the psoas muscles and crossing the ureters, that on the left side entering the internal abdominal ring with the vas deferens *i*; 8, inferior mesenteric artery; 9, lumbar arteries; 9', a lowest lumbar artery, arising from the middle sacral 1' (see varieties of the latter vessel); 10, 10', right and left common iliac arteries; 11, 11, between the external and internal iliac arteries; 12, left epigastric artery; 13, deep circumflex iliac artery.

The *spinal* branch enters the spinal canal through the corresponding intervertebral foramen, and is distributed in the manner described on p. 422.

**Varieties.**—The lumbar arteries of opposite sides, instead of taking their origin separately from the aorta, occasionally commence by a common trunk, the branches of which pass out laterally, and continue their course in the ordinary way. Two arteries of the same side are sometimes conjoined at their origin. One or both of the last pair of lumbar arteries may arise in common with the middle sacral. On the fifth lumbar vertebra, the place of a lumbar artery is often taken by a branch from the middle sacral artery, and the ilio-lumbar compensates for the absence of the lumbar vessel amongst the muscles.

#### MINUTE ANASTOMOSES OF THE VISCERAL AND PARIETAL BRANCHES OF THE ABDOMINAL AORTA.

The extent and nature of the minute communications between some of the visceral and the parietal branches of the abdominal aorta were first clearly demonstrated by Turner,<sup>1</sup> who showed that they form an extensive network in the subperitoneal tissue. This *subperitoneal arterial plexus* occupies the lumbar region from the diaphragm downwards into the iliac regions and pelvis, and establishes communication between the parietal vessels and those of the viscera, chiefly, though not exclusively, through branches of the arteries of those viscera which are situated behind the peritoneum. It belongs to the hepatic, the renal and suprarenal arteries, those of the pancreas and duodenum, the cæcum, and the ascending and descending parts of the colon. It extends also to the vessels of the rectum, and to the spermatic arteries, both in their descent through the abdomen and in the inguinal canal and scrotum.

In these situations it was found that the injected material (coloured gelatine), when thrown into the vessels of the viscus, so as to fill them completely, extended through the subperitoneal plexus in various ways, so as to reach one or other set of parietal vessels, such as the phrenic, lumbar, ilio-lumbar, circumflex iliac, lower intercostal, and epigastric arteries; in the pelvis, the middle and lateral sacral arteries; and in the scrotum, the superficial pudic and perineal arteries.

**Middle sacral artery (iv).**—The middle sacral artery arises from the back of the aorta just above the bifurcation. From this point it proceeds downwards, over the last lumbar vertebra and along the middle of the sacrum, to the front of the coccyx, where it forms slender arches of anastomosis with the lateral sacral arteries, and is then continued as a small vessel through the median aponeurosis of the levatores ani muscles to terminate in the coccygeal gland (see Vol. I, p. 371).

From the front of the middle sacral artery small branches pass into the fold of the mesorectum, and ramify upon the posterior surface of the intestine, anastomosing with the hæmorrhoidal arteries; and on each side others spread out upon the sacrum, and anastomose with the lateral sacral arteries, occasionally sending small offsets into the anterior sacral foramina.

**Varieties.**—The middle sacral artery sometimes deviates a little to one side. It may arise in common with one or both of the fifth pair of lumbar arteries, or from the bifurcation of the aorta, or from one of the common iliac arteries, more frequently the left. It often gives off on each side a considerable branch (*lowest lumbar artery*), which passes backwards on the fifth lumbar vertebra (fig. 376, 9). The middle sacral artery has also been seen to furnish an accessory renal, or a middle hæmorrhoidal artery. This artery represents the caudal prolongation of the aorta of animals, and its lateral branches may be regarded as corresponding to the intercostal and lumbar arteries.

#### COMMON ILIAC ARTERIES.

The common iliac arteries (11-12 mm.), commencing at the bifurcation of the aorta, pass downwards and outwards, diverging from each other at an angle which is slightly greater in the female than in the male, and divide opposite the lumbosacral articulation into the internal and external iliac arteries.

<sup>1</sup> Brit. and For. Med. Chir. Rev., July, 1863.

The common iliac arteries measure generally about two inches in length. Both are covered by the peritoneum and the small intestine, and are crossed by the branches of the sympathetic nerve which pass from the aortic to the hypogastric plexus, as well as usually by the ureter near their point of division; the artery of the left side is crossed also by the superior hæmorrhoidal vessels. The left common iliac artery lies close to the inner border of the psoas muscle, and rests upon the bodies of the fourth and fifth lumbar vertebræ; the right artery is separated for the most part from these bones by the two common iliac veins, and touches the psoas muscle only at its lower end.

*Relation to veins.*—The *left common iliac vein* lies to the inner side of and below the left artery. On the right side there are three veins in proximity to the artery;

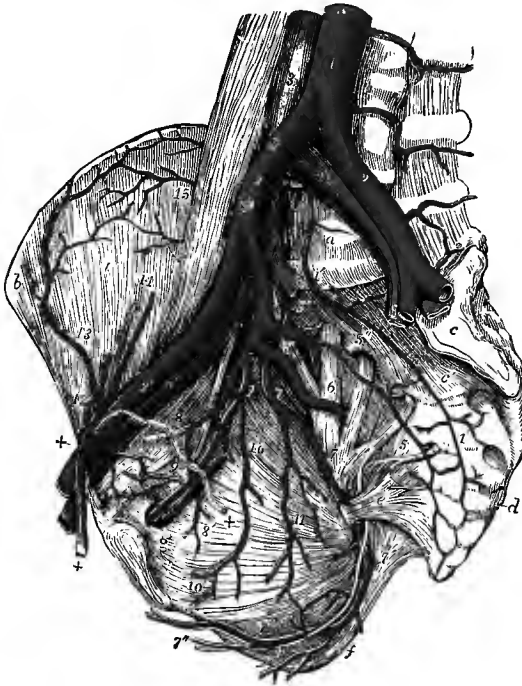


Fig. 377.—THE RIGHT SIDE OF A MALE PELVIS, SHOWING THE ILIAC ARTERIES AND THEIR BRANCHES. (Allen Thomson.)  $\frac{1}{2}$

The viscera of the pelvis have been removed, as well as the internal iliac veins; the larger nerves have been left: *a*, body of fifth lumbar vertebra; *b*, anterior superior spine of ilium; *c*, left auricular surface of sacrum; *c'*, third piece of sacrum; *d*, first piece of coccyx; *e*, small sacro-sciatic ligament; *f*, tuberosity of ischium, covered internally by the great sacro-sciatic ligament; *g*, obturator canal; *i*, iliacus muscle; 1, abdominal aorta; 1', middle sacral artery; 2, 2, common iliac arteries; 2', right external iliac; 3, inferior vena cava; 4, 4, common iliac veins; the number of the right points by a line to the right internal iliac artery; 4', right external iliac vein; 5, placed on the lumbo-sacral nervous trunk, points to the posterior division of the internal iliac artery continued into the gluteal; 5', ilio-lumbar artery; 5'', lateral sacral artery, with branches passing into the anterior sacral foramina; 6, placed on the anterior division of the first sacral nerve, points to the sciatic artery coming from the anterior division of the internal iliac; 7, pudic artery;

7', the same artery passing behind the spine of the ischium, and proceeding forwards on the inner side of the obturator internus muscle, accompanied by the pudic nerve, and giving off, near *f*, inferior hæmorrhoidal branches; 7'', superficial perineal artery and nerve; 8, obliterated hypogastric artery, cut short, and 8', superior vesical branches arising from it; 9, obturator artery with the corresponding nerve and vein; 9', pubic twigs which anastomose with the pubic branch of the epigastric artery; 10, inferior vesical; 11, middle hæmorrhoidal artery, arising in this instance from the pudic; 12, epigastric artery, winding to the inner side of +, +, the vas deferens and spermatic cord; 13, circumflex iliac artery; 14, spermatic artery and vein divided superiorly; 15, twigs of ilio-lumbar artery anastomosing with the circumflex iliac.

the *right common iliac vein* lying behind the lower part of the vessel, the *left common iliac vein* crossing behind it above its middle, and the *inferior vena cava*, resulting from the union of the two others, being on the right side of the artery at its upper end.

The common iliac artery usually does not furnish any named collateral branches. A few minute twigs are given to the psoas muscle, to the ureter, and to the neighbouring lymphatic glands.



**Varieties.**—The *place of division* of these arteries is subject to great variety. In two-thirds of a large number of cases it ranged between the middle of the last lumbar vertebra and the upper margin of the sacrum, in one case in eight it was above, and in one case in six it was below that space. Most frequently the left artery was found to divide lower than the right (R. Quain).

The *length* varies in most instances between an inch and a half and three inches, but it has been seen in some rare cases less than half an inch, and as long as four inches and a half. When longer than usual the artery is generally more or less tortuous. In two instances absence of one common iliac artery has been observed, the internal and external iliacs of that side springing directly from the end of the aorta (on the right side by Cruveilhier, on the left side by W. J. Walsham).

**Branches.**—The common iliac artery occasionally gives off the middle sacral, the ilio-lumbar, or the upper lateral sacral artery, more rarely a lumbar, an accessory renal, or a spermatic artery.

#### SURGICAL ANATOMY OF THE COMMON ILIAC ARTERY.

The common iliac artery may be reached in an operation by dividing the abdominal muscles in the lumbar region. A semilunar incision, having its convexity turned outwards, may be carried from a point an inch and a half to the inner side of the anterior superior iliac spine, upwards and somewhat outwards, to near the lower margin of the thorax. The external oblique, internal oblique, and transversalis muscles are successively divided, together with the thin transversalis fascia; the peritoneum, to which the ureter and spermatic vessels adhere closely, is next separated from the lateral abdominal wall and the surface of the psoas until the artery is reached; the areolar sheath is then scraped through and the ligature applied, the needle being passed on either side from right to left. It seldom happens that the common iliac artery is too short to allow of the application of a ligature, but if it were found to be less than an inch and a half in length, the external and internal iliac trunks might be secured close to the bifurcation.

**Collateral circulation.**—After ligature of the common iliac artery, blood is conveyed to the external iliac trunk through the anastomoses of the circumflex iliac with the lumbar arteries, and of the epigastric with the internal mammary; to the internal iliac through the anastomoses of the middle with the lateral sacral arteries, of the lumbar with the ilio-lumbar, of the superior with the middle and inferior hæmorrhoidal, and of the obturator and the arteries supplied to the pelvic viscera with the corresponding vessels of the opposite side.

#### INTERNAL ILIAC ARTERY (II).

The internal iliac artery (hypogastric) extends from the bifurcation of the common iliac artery downwards towards the great sacro-sciatic foramen, near the upper border of which it divides into branches. It is generally from an inch to an inch and a half in length, and is smaller than the external iliac in the adult, but the reverse in the foetus. At its origin, the artery lies near the inner border of the psoas muscle; lower down, it rests against the sacrum and lumbo-sacral nervous cord. It is covered by the layer of peritoneum constituting the posterior false ligament of the bladder, and beneath this the ureter crosses it on the inner side. The companion vein lies behind, and somewhat to its inner side, and the commencement of the artery crosses the upper end of the external iliac vein.

**BRANCHES.**—The branches of the internal iliac artery, though constant and regular in their general distribution, vary much in their mode of origin. They arise, in most instances, from two principal divisions of the parent trunk, of which one is anterior to the other. From the *anterior division* arise the superior vesical (connected with the pervious portion of the foetal hypogastric artery), the inferior vesical (vaginal in the female), middle hæmorrhoidal, obturator, internal pudic, and sciatic arteries, and also, in the female, the uterine artery. The *posterior division* gives off the ilio-lumbar and lateral sacral arteries, and is continued into the gluteal.

**Varieties.**—*Length.*—The internal iliac artery has been found as short as half an inch, and sometimes as long as three inches, but it is not often less than an inch in length. Three instances are recorded in which this vessel was absent on the left side, and its branches were derived from a loop of the external iliac artery dipping down into the pelvis (Ellis, Eckhard,

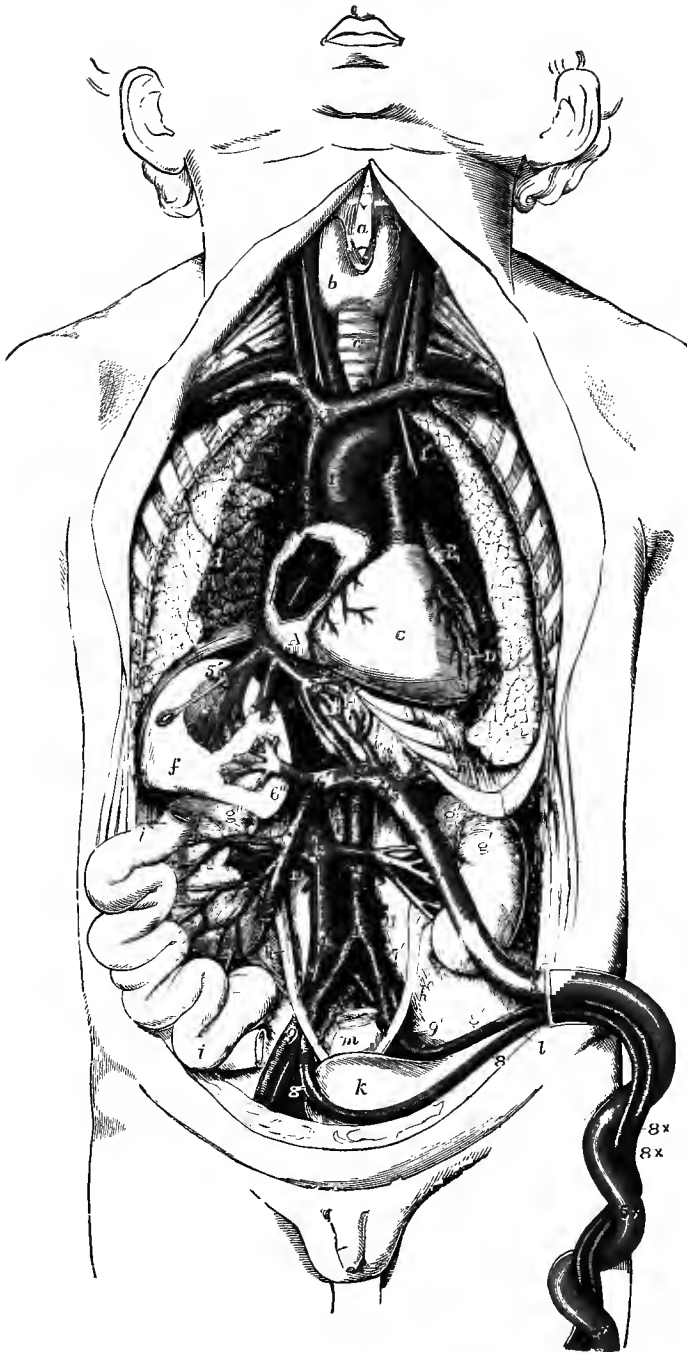


Fig. 378.—SEMIDIAGRAMMATIC VIEW OF THE HEART AND CHIEF BLOOD-VESSELS IN THE FŒTUS.

The vessels which convey mainly arterial blood are coloured red, and those conveying venous blood blue.

*a*, thyroid cartilage; *b*, thyroid body; *c*, trachea; *d*, right lung; *e*, diaphragm below the apex of the heart; *f*, right, and *f'*, left lobe of the liver, dissected to show the ramifications of the umbilical

and hepatic veins; *g*, right, *g'*, left kidney; *g''*, suprarenal bodies; *h*, right, *h'*, left ureter; *i*, portion of small intestine turned to the right side, to show the veins passing from it to the portal vein; *k*, urinary bladder; *l*, is placed below the umbilicus, which is drawn to the left, and points by a line to the urachus; *m*, rectum.

A, A, right auricle of heart, opened to show foramen ovale; a probe, introduced through a divided right hepatic vein and the inferior vena cava, is seen passing through the foramen ovale into the left auricle; at the lower part of the foramen is seen the Eustachian valve; B, left auricular appendix; C, right ventricle; D, placed on the inner surface of the left lung, points to the left ventricle.

1, ascending aorta; 1', back part of the arch, joined by the ductus arteriosus and crossed by the left vagus nerve; 1'', abdominal aorta; 2, pulmonary trunk; 2', the place of division into right and left pulmonary arteries and ductus arteriosus; 3, 3, superior vena cava; 3', right, 3'', left innominate vein; 4, inferior vena cava between the junction of the hepatic veins and the right auricle; 4', continuation of the inferior vena cava below; 5, umbilical vein within the body of the foetus, 5 ×, without the body, in the umbilical cord; 5'—5'', ductus venosus; 5'', 5'', hepatic veins; 6, 6', superior mesenteric vein becoming portal; 7, on the right common iliac vein, points to the common iliac artery; 7', left common iliac artery; 8, right, 8', left umbilical artery; 8 ×, 8 ×, umbilical arteries in the umbilical cord; 9, 9', external iliac arteries; 10, right renal vessels; 11, inferior mesenteric artery.

Ledwich). The lengths of the common and internal iliac arteries generally bear an inverse proportion to each other—the internal iliac being long when the common iliac is short, and *vice versâ*. Moreover, when the common iliac is short, the internal iliac (arising higher than usual) is placed for some distance above the brim of the pelvis, and descends by the side of the external iliac to reach that cavity.

The *place of division* of the internal iliac into its branches varies between the upper margin of the sacrum and the upper border of the sacro-sciatic foramen.

*Branches*.—Occasionally all the branches of the internal iliac artery arise without the previous separation of that vessel into two portions (3·8 per cent., Jastachinski, "Die typischen Verzweigungsformen der Arteria hypogastrica," Internat. Monatschr. f. Anat., viii, 1891).

In more than a fourth of R. Quain's cases a branch, most frequently the ilio-lumbar artery, arose from the internal iliac trunk before its subdivision.

**Hypogastric artery.**—In the foetus, the hypogastric artery, retaining almost the full size of the common iliac, curves forwards from that artery to the side of the urinary bladder, and ascends on the anterior wall of the abdomen to the umbilicus. At that point the artery takes the name of *umbilical*, and the vessels of the two sides, coming into contact with one another, and with the umbilical vein along with which they are spirally coiled, proceed in the umbilical cord to the placenta. After the cessation of the placental circulation at birth, the hypogastric arteries become impervious from the side of the bladder upwards to the umbilicus, and are converted into fibrous cords. These two cords, being shorter than the part of the peritoneum on which they rest, cause a fold of the serous membrane to project inwards; and thus are formed two fossæ at the fore part of the abdomen on each side of the middle line, in one or other of which the projection of an internal inguinal hernia takes place. The proximal part of the artery persists as the internal iliac, and the portion intervening between this and the side of the bladder remains pervious, although proportionally much reduced in size, and forms the trunk of the superior vesical artery.

#### BRANCHES OF THE INTERNAL ILIAC ARTERY.

1. The **superior vesical artery (v)** is, at its commencement, a part of the hypogastric artery of the foetus which remains pervious after the changes that take place subsequently to birth. It divides into numerous branches which supply the apex and body of the bladder, and anastomose with the corresponding vessels of the opposite side, as well as with the offsets of the inferior vesical artery. Anteriorly, small twigs ascend on the urachus to the abdominal wall, and posteriorly, others supply the lower end of the ureter. One or more of the hindmost branches of this artery are sometimes described separately under the name of *middle vesical*.

2. The **inferior vesical artery (v)** (vesico-prostatic), derived usually from the anterior division of the internal iliac, is directed downwards to the base of the bladder, where it ends in branches which are distributed to the lower part of that organ, to the prostate, and to the vesiculæ seminales. The branches to the prostate communicate more or less freely upon that body with the artery of the opposite side, and by small descending twigs also with the arteries of the perineum. It occa-

sionally happens that one of the latter offsets is much enlarged, and replaces one or more branches of a defective pudic artery, as will be more fully noticed in the description of that vessel.

One slender but constant branch, the *artery of the vas deferens* (vi), arising from either the superior or inferior vesical artery, sends one or more twigs downwards to the lower part of the vas deferens and the vesicula seminalis, and is then continued forwards along the vas deferens, in company with which it descends in the spermatic cord as far as the testicle, where it anastomoses with the spermatic artery. This branch may reinforce or even replace the last-mentioned vessel.

Besides the superior and inferior vesical arteries, other small offsets are frequently furnished to the bladder from the obturator, sciatic, or other branches of the internal iliac artery.

The **vaginal artery** (v) (vesico-vaginal) in the female corresponds to the inferior vesical artery in the male. Arising from the anterior division of the

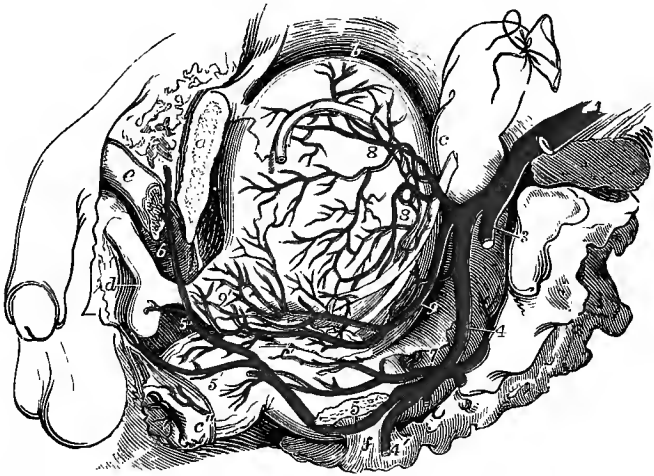


Fig. 379.—THE VISCERA OF THE MALE PELVIS FROM THE LEFT SIDE, SHOWING THE VESICAL AND PUDIC ARTERIES. (R. Quain.)  $\frac{1}{2}$

a, os pubis, divided a little to the left of the symphysis; b, the upper part of the bladder, upon which lies the vas deferens; c, the upper part of the rectum, near the left ureter; c', at the junction of the middle and lower parts of the rectum, points to the vesicula seminalis; c'', anus; d, bulb of the corpus spongiosum; e, crus penis divided; f, small sacro-sciatic ligament, attached to the spine of the ischium; 1, common iliac artery; 2, internal iliac artery; 3, gluteal artery, cut short; 4, common trunk of the sciatic and pudic arteries; 4', sciatic artery, cut as it is passing out of the great sacro-sciatic foramen; 5, on the divided surface of the ischial spine, points to the pudic artery as it is about to enter the perineum by the small sacro-sciatic foramen; 5', superficial perineal branch of pudic; 5'', pudic artery, giving off the artery of the bulb, and dividing at 6, into the artery of the corpus cavernosum and the dorsal artery of the penis; 7, on the middle part of the rectum, points to the superior hæmorrhoidal artery; 8, 8, ramifications of the superior vesical artery; 9, inferior vesical artery, of considerable size in this instance, giving branches to the bladder, the vesicula seminalis, the rectum (middle hæmorrhoidal), and 9', to the prostate gland.

internal iliac, or frequently from the uterine artery, it descends and ramifies upon the vagina, sending at the same time offsets to the lower part of the bladder, to the bulb of the vestibule, and to the contiguous part of the rectum. It anastomoses behind the vagina with the corresponding artery of the opposite side.

**3. The middle hæmorrhoidal artery** (v) is frequently derived from the inferior vesical or the internal pudic artery. It ramifies on the lower part of the rectum, and anastomoses with the other hæmorrhoidal and the inferior vesical arteries.

4. The **uterine artery** (*v*) is directed inwards from the anterior division of the internal iliac towards the neck of the uterus. Insinuating itself between the layers of the broad ligament, it passes upwards on the side of the uterus, pursuing an exceedingly tortuous course, and sends off numerous branches, which ramify on the anterior and posterior surfaces and in the substance of that organ. Near its termination it is joined by a branch of the ovarian artery, forming an arch from which offsets proceed to the Fallopian tube and the round ligament of the uterus. During pregnancy the uterine artery becomes much enlarged.

5. The **obturator artery** (*iv*), while it usually arises from the anterior division of the internal iliac, is not unfrequently derived from the posterior division of that vessel. It is directed downwards and forwards a little below the ilio-pectineal line, resting upon the obturator portion of the pelvic fascia, and covered by the peritoneum. The obturator nerve is a little way above, and the companion vein is

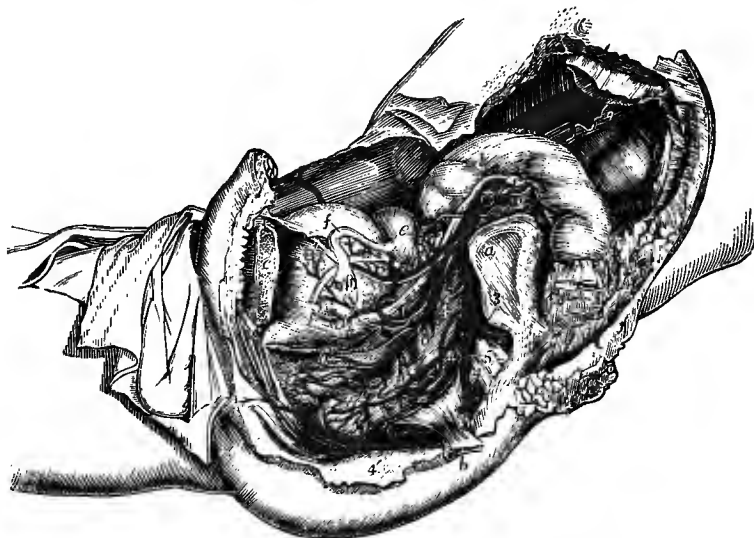


Fig. 380.—THE ARTERIES OF THE FEMALE PELVIS, AS SEEN ON THE REMOVAL OF THE LEFT HIP-BONE, &c. (R. Quain.) †

*a*, auricular surface of sacrum ; *b*, spine of ischium with the small sacro-sciatic ligament ; *c*, os pubis, divided a little to the left of the symphysis ; *d*, on the sigmoid part of the colon, and *d'*, on the lower part of the bladder, point to the ureter ; *e*, on the upper part of the body of the uterus, points to the ovary ; *f*, on the upper part of the bladder, points to the Fallopian tube ; *f'*, round ligament of uterus ; 1, external iliac artery, cut short ; 2, internal iliac artery ; 3, gluteal artery, cut short ; 4, 4, left pudic artery, from which a part has been removed ; 4', the same artery in the perineum, and 4'', its last part, dividing into the dorsal and deep arteries of the clitoris ; 5, on the sacral nerves, points to the sciatic artery ; 6, vaginal artery, giving off branches to the bladder 6', and to the rectum 6'' ; 7, uterine artery ; 8, superior vesical, and 8', obliterated hypogastric artery ; 9, 9, ovarian artery, descending from the aorta ; 10, superior hæmorrhoidal artery, spreading over the side of the rectum.

below the artery. Reaching the upper part of the thyroid foramen, it passes through a short canal formed by the obturator groove on the under surface of the superior ramus of the pubis and the arched border of the obturator fascia (p. 339), and divides immediately into internal and external terminal branches, which descend on the surface of the obturator membrane, beneath the obturator externus muscle.

*Branches.*—(*a*) Within the pelvis, besides other small muscular offsets, and sometimes a branch to the urinary bladder, the obturator artery furnishes an *iliac*

branch which ramifies in the iliac fossa, supplying the ilio-psoas muscle and anastomosing with the ilio-lumbar artery.

(b) One or two small *pubic* branches are given off by the artery as it is about to leave the pelvis: these vessels ramify on the back of the pubis, and communicate behind the bone and the attachments of the abdominal muscles with the pubic branch of the epigastric artery, and with the corresponding offsets of the opposite side.

(c) The *internal terminal* branch, turning downwards close to the inner margin of the thyroid foramen, furnishes offsets to the obturator muscles and to the upper

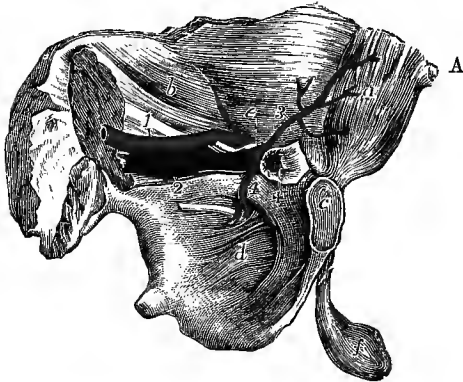
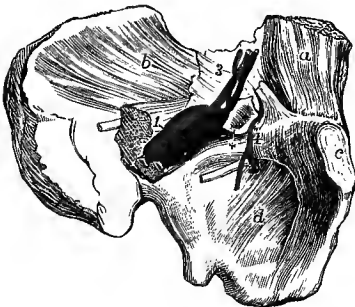


Fig. 381, A. and B.—VIEWS OF THE LEFT HIP-BONE, WITH THE ATTACHED ABDOMINAL MUSCLES, FROM THE INSIDE, SHOWING DIFFERENT POSITIONS OF THE ABERRANT OBTURATOR ARTERY. (R. Quain.) †

In A, the aberrant artery passes to the outer side of a femoral hernia; in B, it surrounds the neck of the sac.

*a*, rectus muscle; *b*, iliacus; *c*, symphysis pubis; *d*, obturator membrane; *e*, on the transversalis fascia, points to the vas deferens passing through the internal abdominal ring; *f*, testicle; +, neck of a femoral hernial sac; 1, external iliac artery; 2, external iliac vein; below 2, the obturator nerve; 3, epigastric artery, giving off 4, the aberrant obturator artery.



B

ends of the adductors, and anastomoses with branches of the internal circumflex artery.

(d) The *external terminal* branch descends near the outer margin of the thyroid foramen, sends a small offset inwards to anastomose with the lower part of the internal branch, and then, inclining outwards in the groove below the acetabulum, is distributed to the muscles arising from the ischial tuberosity and

anastomoses with branches of the sciatic artery. It also gives twigs to the obturator muscles; and one small branch, entering the hip-joint through the cotyloid notch, supplies the fat and synovial membrane at the bottom of the acetabulum, and is continued in the interarticular ligament to the head of the femur.

**Varieties.**—The obturator artery very frequently has its origin transferred to the commencement of the epigastric artery (nearly 30 per cent.), and occasionally to the external iliac near its termination (1·2 per cent.); or it may arise by two roots, one from the internal iliac and the other from the epigastric (3·6 per cent.).<sup>1</sup> Sometimes the obturator artery arises from the epigastric on both sides of the same body, but in the majority of instances the irregular origin exists only on one side. It may be said that in two out of every five subjects the obturator artery is arising from the epigastric on one or both sides. The epigastric origin is somewhat more common in the female than in the male; and the origin by two roots is

<sup>1</sup> W. Pfitzner, "Ueber die Ursprungsverhältnisse der Arteria obturatoria," *Anatom. Anzeiger*, iv, 1889; S. Jastschinski, "Die Abweichungen der Arteria obturatoria nebst Erklärung ihres Entstehens," *Internat. Monatschr. f. Anat. u. Phys.*, viii, 1891.

found to occur much more frequently in the embryo and young child than in the adult (Jastschinski).

When the obturator artery arises from the epigastric, it turns backwards into the pelvis to reach the canal at the upper part of the thyroid foramen; and in this course it is necessarily close to the femoral ring, the opening situated at the inner side of the external iliac vein, through which hernial protrusions descend from the abdomen into the thigh. In about six-tenths of such cases the artery turns backwards close to the external iliac vein, and therefore on the outer side of the femoral ring; in three-tenths it passes backwards across the ring; and in the remaining one-tenth it is directed at first inwards and then arches backwards on the inner side of the ring. Its relation to the femoral ring is in some measure dependent upon the spot at which it leaves the epigastric artery, for when it arises from the transverse part of that vessel it usually passes backwards at once to gain the obturator canal, but if it arises from the epigastric after the latter has turned upwards, the obturator artery descends forming an arch and occupies a more internal position (Jastschinski). The position on the inner side of the ring is more frequent in males than females.

The anastomosis which normally exists between the pubic branches of the obturator and epigastric arteries explains the nature of the change which takes place when the origin of the obturator artery is transferred from the one place to the other. In such cases one of the anastomosing vessels may be supposed to have become enlarged, and the posterior or proper root of the obturator artery to have remained undeveloped or to have become obliterated in a proportionate degree.

The obturator artery has also been seen to arise from the upper part of the femoral, either alone or in conjunction with the internal circumflex artery, in which case it arches backwards over the superior ramus of the pubis, and through the femoral ring, to reach the thyroid foramen.

In a few cases the obturator artery has been observed giving off the epigastric artery, an accessory pudic artery (within the pelvis), or the dorsal artery of the penis (in the thyroid foramen).

**6. The internal pudic artery (iv)**, one of the terminal branches of the anterior division of the internal iliac, is distributed to the perineum and the external organs of generation. The following description of the artery has reference to its arrangement in the male, and the differences which it presents in the female will be afterwards pointed out.

From its origin in front of the pyriformis muscle, the pudic artery descends along with the sciatic artery, and leaves the pelvis by the lower part of the great sacro-sciatic foramen. Then curving gradually forwards, it crosses over the ischial spine and passes through the small sacro-sciatic foramen into the posterior division of the perineal space, where it lies along the outer wall of the ischio-rectal fossa, being placed from an inch to an inch and a half above the lower margin of the ischial tuberosity. Continuing its course forwards, it gradually approaches the margin of the ischial ramus, penetrates the base of the triangular ligament, and runs between the layers of that structure to near the apex of the subpubic arch. Close to the inferior ramus of the pubis it ends under cover of the crus penis by dividing into the artery of the corpus cavernosum and the dorsal artery of the penis. The pudic artery is accompanied throughout its course by the veins of the same name.

Within the pelvis, the pudic artery rests against the rectum internally, and the sacral plexus of nerves intervenes between it and the pyriformis muscle. Over the ischial spine, the artery is covered by the gluteus maximus muscle, and the pudic nerve lies to its inner side. In the ischio-rectal fossa, the artery is contained in the substance of the obturator fascia, the dorsal nerve of the penis being above, and the perineal division of the pudic nerve below it; and between the layers of the triangular ligament, it is embedded in the tendinous origin of the constrictor urethræ muscle, the dorsal nerve of the penis taking a similar course, but being more deeply placed.

*Branches.*—From the part of the artery within the pelvis small offsets proceed to the obturator internus, pyriformis, and coccygeus muscles. As the artery crosses the ischial spine it gives off branches to the adjacent part of the gluteus maximus,

and other twigs which supply the external rotator muscles and anastomose with offsets of the sciatic artery. In the perineum the following larger branches arise :—

(a) The *inferior* or *external hæmorrhoidal artery*, often represented by two or three separate branches, arises from the pudic artery as it enters the perineal space. Directed inwards through the fat of the ischio-rectal fossa towards the anus, it divides into branches which supply the superficial structures of the posterior part of the perineum, the sphincter and levator ani muscles, and anastomose with the other hæmorrhoidal arteries as well as with the corresponding vessels of the opposite side. Small offsets also turn round the border of the gluteus maximus and supply the overlying integument, while others pass forwards and communicate with the superficial perineal artery.

(b) The *superficial perineal artery* (v) arises from the pudic at the fore part of the ischio-rectal fossa. Crossing over or under the transversus perinei muscle, it runs

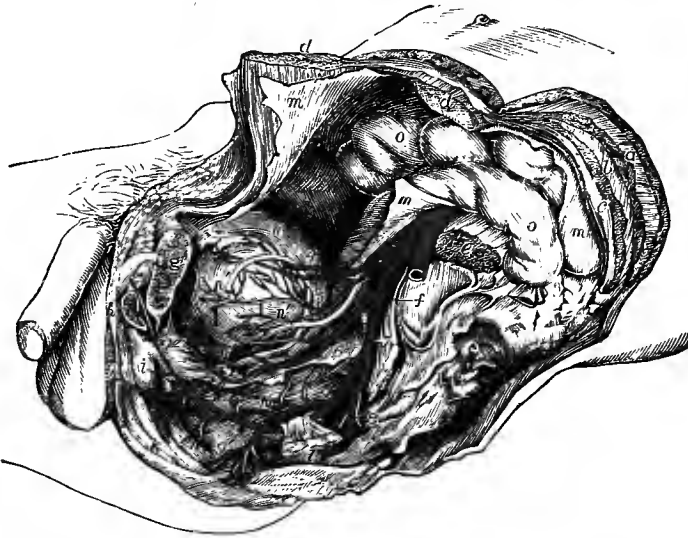


Fig. 382.—THE ARTERIES OF THE MALE PELVIS, AS SEEN ON THE REMOVAL OF THE LEFT HIP-BONE, &c. (R. Quain.)  $\frac{1}{2}$

*a*, external oblique muscle divided ; *b*, internal oblique ; *c*, transversalis ; *d, d*, the parts of the divided rectus ; *e*, psoas magnus divided ; *f*, on the auricular surface of the sacrum, points to the sacral plexus of nerves ; *g*, on the os pubis, sawn through a little to the left of the symphysis, points to the divided spermatic cord ; *h*, crus penis divided ; *i*, bulb of corpus spongiosum ; *k*, external sphincter muscle ; *l*, spine of ischium with the small sacro-sciatic ligament ; *m*, peritoneum ; *n*, upper part of urinary bladder ; *n', n'*, vas deferens ; *n'', n''*, ureter ; *o, o*, intestines ; *1*, common iliac artery ; *2*, external iliac ; *3*, internal iliac ; *4*, obliterated hypogastric and superior vesical arteries ; *5*, middle vesical ; *6*, inferior vesical artery ; *7*, placed on the sacral plexus, points to the common trunk of the pudic and sciatic arteries ; close above *7*, the gluteal artery is seen cut short ; *8*, sciatic artery, cut short ; *9*, on the rectum, the pudic artery as it is about to pass behind the spine of the ischium ; *9'*, on the lower part of the rectum, the inferior hæmorrhoidal branches ; *9''*, superficial perineal artery ; *9'''*, on the prostate gland, the pudic artery in the fore part of the perineum, giving off the artery of the bulb, and finally dividing into the artery of the corpus cavernosum and the dorsal artery of the penis ; *10*, on the middle part of the rectum, the superior hæmorrhoidal artery.

forwards beneath the superficial perineal fascia, in company with the nerves of the same name, gives offsets to the subjacent muscles, and divides into long slender branches which supply the back of the scrotum and anastomose with the external pudic branches of the femoral artery.



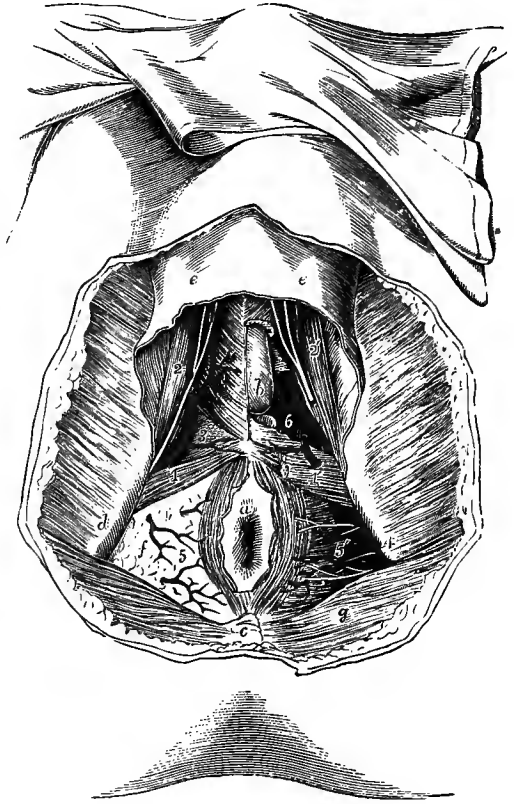
(c) The *transverse perineal artery* (vi) generally arises in common with the preceding, but it is sometimes a distinct branch of the pudic artery. Passing inwards towards the central point of the perineum, it supplies the parts between the anus and the bulb, and anastomoses with its fellow of the opposite side.

(d) The *artery of the bulb* (v) arises from the pudic near the point where that vessel enters between the layers of the triangular ligament. It runs inwards between the fibres of the constrictor urethræ muscle, being placed usually about half an inch from the base of the triangular ligament, and penetrates the bulb to be distributed to the erectile tissue of the corpus spongiosum. It gives branches to

Fig. 383.—DISSECTION OF THE PERINEUM IN THE MALE. (Allen Thomson.)  $\frac{1}{2}$

The right side shows a superficial, the left a deeper view.

a, anus, with a part of the integument surrounding it; b, left half of the bulb of the corpus spongiosum, exposed by the removal of the bulbo-cavernosus muscle; c, coccyx; d, right ischial tuberosity; e, e, superficial perineal fascia; f, fat occupying the right ischio-rectal fossa; g, gluteus maximus muscle; l, on the right transversus perinei muscle, points to the superficial perineal artery as it emerges in front (in this case) of the muscle; l', on the left side, on the surface of the triangular ligament, points to the superficial perineal artery cut short; 2, on the right ischio-cavernosus muscle, points to the superficial perineal artery and nerves passing forwards; 2', on the left side, the same vessel and nerves divided; 3, on the right half of the triangular ligament, points to the transverse perineal artery; 4, on the left ischial tuberosity, points to the pudic artery deep in the ischio-rectal fossa; 5, 5', inferior hæmorrhoidal branches of the pudic arteries and nerves; 6, on the left side, placed in a recess from which the inferior layer of the triangular ligament has been removed, in order to show the continuation of the pudic artery, its branch to the bulb, and Cowper's gland.



Cowper's gland, and to the membranous part of the urethra.

Another smaller branch to the corpus spongiosum is frequently given off by the pudic artery near its bifurcation, or by the artery of the corpus cavernosum.

(e) The *artery of the corpus cavernosum* (art. profunda penis) (v) is slightly the larger of the two terminal branches of the pudic trunk. It perforates the inferior layer of the triangular ligament and enters the inner side of the crus penis, whence it is continued forwards in the centre of the corpus cavernosum to the anterior extremity of that body, giving off in its course numerous offsets to the erectile tissue.

(f) The *dorsal artery of the penis* (v) ascends to the upper surface of that organ between the crus and the pubic symphysis. After piercing the suspensory ligament, the artery runs forwards, between the median dorsal vein and the corresponding nerve, to the neck of the penis, where it ends in offsets to the glans

and the prepuce. It supplies the integument of the penis, and several branches pass through the fibrous sheath of the corpus cavernosum to the spongy tissue in its interior, and anastomose with the offsets of the deep artery. The right and left dorsal arteries communicate freely together in the glans penis.

**Varieties.**—The pudic artery is sometimes small, and fails to supply one or two, or even three of its usual branches, which, in those circumstances, are furnished by a supplemental vessel, the *accessory pudic*. The defect most frequently met with is that in which the pudic ends as the artery of the bulb, while the arteries of the corpus cavernosum and dorsum of the penis are derived from the accessory pudic. But all the three arteries of the penis may be supplied by the accessory pudic, the pudic itself ending as the superficial perineal. A single accessory pudic has been found to supply both cavernous arteries, while the pudic of the right side gave both dorsal arteries (R. Quain). On the other hand, cases occur in which only a single branch is furnished by the accessory artery, either to take the place of an ordinary branch altogether wanting, or to supplement one of the branches which is diminutive in size.

The *accessory pudic artery* generally arises from the pudic itself, before the passage of that vessel through the sacro-sciatic foramen, and descends within the pelvis, along the lower part of the urinary bladder and across the side of the prostate gland, to reach the root of the penis by perforating the triangular ligament in front of the membranous part of the urethra. Less frequently the accessory pudic is derived from the inferior vesical (p. 474), or from some other branch of the internal iliac artery. It may also arise from the obturator artery within the pelvis, that vessel taking origin from either the internal iliac or the epigastric artery; and in a few cases it has been given off by the epigastric artery directly.

**Branches.**—The *artery of the bulb* is sometimes small, sometimes wanting on one side, and occasionally it is double. But a more important deviation from the common condition is one sometimes met with, in which the vessel, arising earlier, and crossing the perineum farther back than usual, reaches the bulb from behind. In such a case there is considerable risk of dividing the artery in performing the lateral operation for stone. On the other hand, when this vessel arises from an accessory pudic artery, it lies farther forwards than usual, and is out of danger in case of operation.

The *dorsal artery of the penis* has been observed to arise from the obturator artery in the thyroid foramen, from the lower end of the external iliac, from one of the external pudic branches of the femoral, or from the deep femoral artery. This branch is sometimes small on one side, the deficiency being supplied by the opposite artery. The two dorsal arteries are occasionally united by a cross branch, and they have been seen uniting into a common trunk on the dorsum of the penis.

**The pudic artery in the female.**—In the female this vessel is much smaller than in the male. It takes a similar course, but the following branches differ in their size and distribution from the corresponding arteries in the male.

The *superficial perineal artery* is larger than in the male, and is distributed to the labia pudendi.

The *artery of the bulb* is small, and supplies the bulb of the vestibule.

The two terminal branches are much smaller than in the male. The *artery of the corpus cavernosum* (art. profunda clitoridis) enters that body; and the *dorsal artery of the clitoris* passes forwards between the crura clitoridis and terminates in the glans and in the membranous fold corresponding to the prepuce of the male.

**7. The sciatic artery (iv)**, the larger of the two terminal branches of the anterior division of the internal iliac, is distributed chiefly to the muscles on the back of the pelvis. It descends on the anterior surface of the pyriformis muscle and the sacral plexus of nerves, and issues by the lower part of the great sacro-sciatic foramen, in company with the pudic artery and the sciatic nerves. Continuing its course downwards, under cover of the gluteus maximus and resting upon the obturator internus and gemelli muscles, it ends as a slender vessel which accompanies the small sciatic nerve along the back of the thigh, supplying the integument and anastomosing with superficial branches of the perforating arteries.

**Branches.**—(a) *Muscular* branches pass to the lower part of the gluteus maximus, anastomosing in the muscle with the gluteal artery; to the external rotator muscles, anastomosing with twigs of the pudic artery; and to the muscles arising from the ischial tuberosity, anastomosing with the obturator and internal circumflex arteries.

(b) The *coccygeal* branch, inclining inwards, pierces the great sacro-sciatic ligament, and is distributed mainly to the gluteus maximus, two or three offsets perforating that muscle and ramifying in the subcutaneous tissue over the sacrum and coccyx.

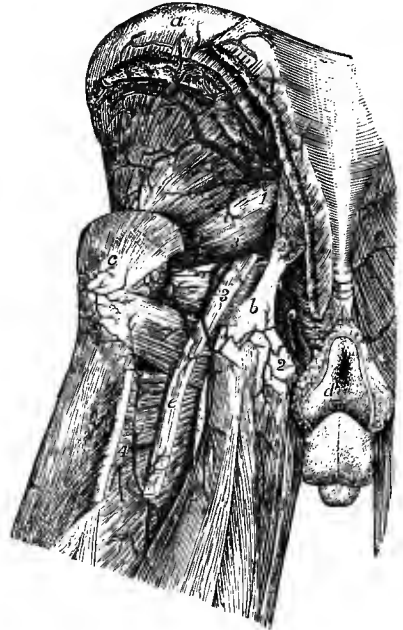(c) The *anastomotic* branch, directed outwards to the hollow on the inner side of the great trochanter, supplies the external rotator muscles and the hip-joint, and anastomoses with offsets of the gluteal artery, with the ascending branch of the internal circumflex artery, and with the first perforating artery.

(d) The *comes nervi ischiadici* (vi) enters the great sciatic nerve, which it supplies, and anastomoses with twigs of the perforating arteries.

(e) Several *cutaneous* branches pass to the integument at the lower border of the gluteus maximus, along with branches of the small sciatic nerve.

Fig. 384.—ARTERIES OF THE BACK OF THE PELVIS. (Tiedemann.)  $\frac{1}{2}$

*a*, iliac crest; *b*, ischial tuberosity; *c*, great trochanter; *d*, integument round the anus; *e*, great sciatic nerve; 1, trunk of the gluteal artery as it issues from the great sacro-sciatic foramen, the superficial part is cut short, the deep part is seen passing forwards on the surface of the gluteus minimus muscle; 2, on the great sacro-sciatic ligament, points to the pudic artery as it winds over the ischial spine; 2', the continuation of the artery in the perineum; 3, 3, sciatic artery; the upper figure points to the trunk of the vessel, from which the anastomotic branch is seen running outwards towards the great trochanter; the lower figure indicates the continuation of the artery along the back of the thigh; 4, first perforating artery.



**Varieties.**—The sciatic artery occasionally arises in common with the gluteal, leaving that vessel outside the pelvis, at the upper border of the pyriformis muscle. In a few cases this artery has been found much enlarged, and forming the main artery of the limb (see varieties of the femoral artery). The *comes nervi ischiadici* has been seen by Hyrtl of large size, and continued along the thigh to join the popliteal artery, a little above the knee-joint.

**8. The gluteal artery (iii)**, the largest branch of the internal iliac, is distributed to the muscles on the outer side of the pelvis. It passes backwards between the lumbo-sacral cord and the first sacral nerve, turns round the upper margin of the great sacro-sciatic foramen, and divides opposite the interval between the gluteus medius and pyriformis muscles into a superficial and a deep part. Before leaving the pelvis the gluteal artery gives some twigs to the pyriformis and obturator internus muscles, and one or two branches to the hip-bone.

(a) The *superficial* part, the smaller of the two divisions, passes backwards between the contiguous borders of the gluteus medius and pyriformis muscles, and divides into a number of branches, which are distributed to the gluteus maximus, and anastomose with the sciatic and the posterior branches of the lateral sacral arteries.

(b) The *deep* part divides again into two branches, which run forwards between the gluteus medius and minimus muscles. The *superior* branch courses along the upper border of the gluteus minimus towards the anterior superior iliac spine, and, after supplying the muscles between which it is placed, anastomoses with the

ascending branch of the external circumflex artery, as well as with the deep circumflex iliac by means of branches which perforate the origin of the gluteus medius, and ascend over the iliac crest. The *inferior* branch crosses the middle of the gluteus minimus, distributes offsets to the smaller gluteal muscles and the hip-joint, and anastomoses with the external circumflex and sciatic arteries.

**Variety.**—One instance is recorded in which the gluteal artery was replaced by a large branch arising from the femoral and passing outwards and backwards to reach the gluteal muscles (F. T. Roberts).

**9. The ilio-lumbar artery (v)** resembles in a great measure one of the lumbar arteries. It is a short vessel which passes outwards, between the obturator nerve and the lumbo-sacral cord, to the upper end of the ilio-pectineal line, where it divides, behind the inner margin of the psoas muscle, into lumbar and iliac branches.

The *lumbar* or *ascending* branch turns upwards under cover of the psoas, to which and to the quadratus lumborum it is mainly distributed, and anastomoses with the lower lumbar arteries. A *spinal* branch is sent inwards through the last intervertebral foramen, and is distributed like the spinal offsets of the lumbar arteries.

The *iliac* or *transverse* branch is directed outwards into the iliac fossa, and ramifies partly beneath, partly on the surface of the iliacus muscle, giving offsets to the bone, and forming anastomoses with the obturator, circumflex iliac, and lumbar arteries.

**Varieties.**—The ilio-lumbar artery frequently arises from the internal iliac above the division of that trunk, more rarely from the common iliac. The iliac and lumbar portions sometimes arise separately from the parent trunk.

**10. The lateral sacral arteries (v)** are usually two in number on each side, although occasionally they are united into one. They arise close together from the posterior division of the internal iliac. Both arteries incline somewhat inwards and descend on the front of the sacrum, internal to the anterior sacral foramina. The superior artery is confined to the upper part of the sacrum; the inferior passes downwards to the front of the coccyx, and terminates by anastomosing with offsets of the middle sacral artery.

From the lateral sacral arteries small offsets proceed outwards to the pyriformis and coccygens muscles, and to the sacral nerves, anastomosing with one another round the foramina. Others are directed inwards and anastomose with branches of the middle sacral artery. The largest branches pass backwards into the anterior sacral foramina, supply twigs to the sacral canal, and are continued through the posterior foramina to the muscles and integuments on the back of the sacrum, anastomosing with the gluteal and sciatic arteries.

#### EXTERNAL ILIAC ARTERY.

The external or anterior of the two arteries resulting from the division of the common iliac forms a large continuous trunk, which extends downwards in the limb as far as the lower border of the popliteus muscle, but, for convenience of description, it is named in successive parts of its course external iliac, femoral, and popliteal.

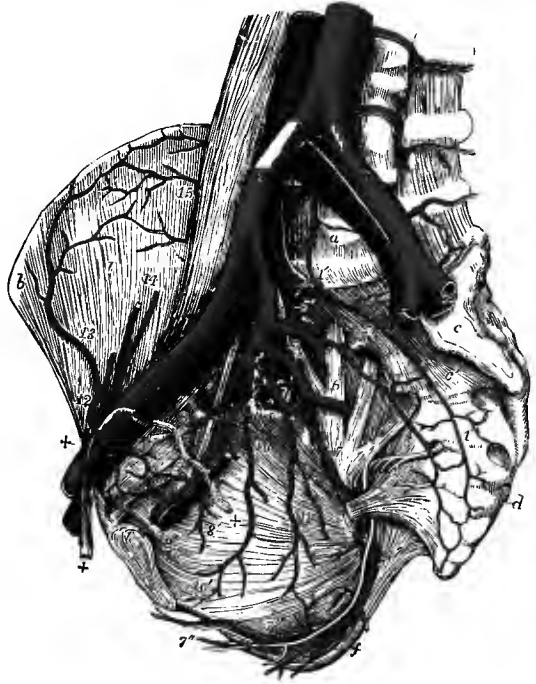
The external iliac artery (9-10 mm.) is placed within the abdomen, and extends from the bifurcation of the common iliac to the lower border of Poupart's ligament, where the vessel enters the thigh, and is named femoral. It is larger than the internal iliac, and measures usually from three and a half to four inches in length. Inclining obliquely outwards, its course, together with that of the common iliac

artery, may be marked by a line drawn on the surface of the abdomen from the place of division of the aorta, *i.e.*, a spot about a finger's breadth to the left of and below the umbilicus, to a point midway between the anterior superior spine of the ilium and the symphysis pubis. The upper third of this line would lie over the common iliac, the lower two-thirds over the external iliac artery.

In its course downwards and forwards, the external iliac artery is situated a little above the brim of the pelvis, and rests for the most part against the inner border of the psoas, but near Poupart's ligament it passes onto the front of that muscle. It is, however, separated from the muscle by the iliac fascia, to which it is bound, together with the companion vein, by the subperitoneal tissue. The artery is covered by peritoneum, and crossed on the left side by the sigmoid flexure of the

Fig. 385.—THE ILIAC ARTERIES OF THE RIGHT SIDE, IN THE MALE. (Allen Thomson.)  $\frac{1}{3}$

For the detailed description of this figure, see p. 470. 2', external iliac artery, accompanied by 4', the corresponding vein; 12, epigastric artery, winding to the inner side of +, +, the spermatic cord, and sending downwards its pubic branch to join 9', the pubic offsets of the obturator artery; the epigastric artery is cut short above; 13, circumflex iliac artery, anastomosing with 15, branches of the ilio-lumbar; 14, spermatic vessels, descending to join the spermatic cord; +, within the pelvis, the vas deferens descending from the cord.



colon, on the right by the termination of the ileum. The ureter, as it descends into the pelvis, sometimes passes over the upper end of the vessel.

*Relation to veins, &c.*—The external iliac vein lies at first behind the artery with an inclination to the inner side; but, as the vessels approach

Poupart's ligament at the fore part of the pelvis, the vein is on the same plane with the artery and quite to the inner side, being carried forwards by the bone. At a short distance from its lower end the artery is crossed by the *circumflex iliac vein*.

Large *lymphatic glands* are found resting upon the front and inner side of the artery; and the *spermatic* (or *ovarian*) *vessels*, together with the *genital branch of the genito-crural nerve*, descend over it near its termination.

**BRANCHES.**—The external iliac artery supplies small twigs to the psoas muscle and the neighbouring lymphatic glands, and, close to its termination, two branches of considerable size, *viz.*, the epigastric and the circumflex iliac, which are distributed to the walls of the abdomen.

**1. The deep epigastric artery (iv)** (inferior epigastric) arises from the inner and fore part of the external iliac, usually a few lines above Poupart's ligament. It is at first directed inwards for a short distance between Poupart's ligament and the internal abdominal ring, and then ascends on the inner side of that aperture, being covered by the transversalis fascia and resting on the peritoneum. As it turns round

the internal abdominal ring, the artery is crossed on its outer side, in the male by the vas deferens and the spermatic vessels, which here meet to form the spermatic cord, in the female by the round ligament of the uterus. Continuing its course upwards, the vessel perforates the transversalis fascia and passes over the semilunar fold of

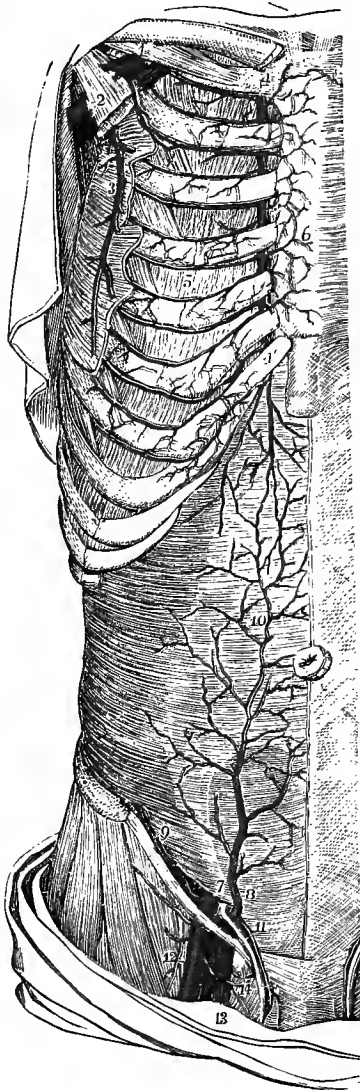


Fig. 386.—THE DISTRIBUTION AND ANASTOMOSES OF THE EPIGASTRIC AND INTERNAL MAMMARY ARTERIES. (Tiedemann.) †

For the detailed description of this figure, see p. 427. 7, on the transversalis muscle above the internal abdominal ring, points to the last part of the external iliac artery, at the place where it gives origin to 8, the epigastric, and 9, the circumflex iliac artery; 10, anastomoses of the epigastric with the abdominal branch of the internal mammary artery; 11, spermatic cord, receiving the cremasteric branch from the epigastric artery; 12, femoral artery; 13, femoral vein; 14, a lymphatic gland closing the femoral ring.

Douglas to enter the sheath of the rectus, becoming closely applied to the back of that muscle. It finally divides, somewhat above the level of the umbilicus, into a number of branches which supply the rectus, and anastomose freely in the muscle with the abdominal branch of the internal mammary artery.

The epigastric artery is usually accompanied by two veins, which unite into a single trunk before ending in the external iliac vein; but sometimes there is only one vein, lying on the inner side of the artery.

**BRANCHES.**—These are small but numerous.

(a) The *cremasteric artery* (vi) descends on the spermatic cord, and, besides supplying the cremaster muscle and other coverings of the cord, anastomoses with the spermatic and external pudic arteries.

(b) The *pubic branch* (vi) ramifies behind the pubis, and communicates with the corresponding artery of the opposite side, as well as with the pubic branch of the obturator artery.

(c) *Muscular branches*, which arise mainly from the outer side of the epigastric artery, ramify in the broad muscles of the abdomen,

and anastomose with branches of the circumflex iliac, lumbar, and lower intercostal arteries.

(d) *Superficial branches* perforate the rectus muscle, and anastomose beneath the skin with branches of the superficial epigastric artery.

**2. The deep circumflex iliac artery (v)** arises from the outer side of the external iliac, generally a little below the origin of the epigastric artery. It runs upwards and outwards behind Poupart's ligament, resting on the iliacus muscle, and being contained in a fibrous canal at the junction of the transversalis and iliac

fasciæ, as far as the anterior superior iliac spine. From this point the artery is continued backwards along the inner margin of the iliac crest, giving branches to the iliacus and lateral abdominal muscles, and ends by anastomosing with the iliac branch of the ilio-lumbar artery. Some small branches also pierce the muscles attached to the crest of the ilium and communicate with offsets of the gluteal artery.

From the first part of the circumflex iliac artery branches are given to the ilio-psoas, and to the upper ends of the sartorius and tensor vaginæ femoris muscles. One considerable branch, sometimes replaced however by two or three smaller ones, arises near the anterior superior iliac spine, and ascends between the internal oblique and transversalis muscles, supplying the abdominal wall, and anastomosing with the epigastric and lumbar arteries.

Two veins accompany the circumflex iliac artery; these unite below into a single vessel, which crosses the external iliac artery about three quarters of an inch above Poupart's ligament, and joins the external iliac vein.

**Varieties.**—*Size.*—In those rare cases in which the principal vessel of the lower limb is continued from the sciatic branch of the internal iliac artery, the external iliac is much diminished in size, and ends in the profunda artery of the thigh.

*Branches.*—The usual number of two principal branches of the external iliac artery may be increased by the separation of the circumflex iliac into two branches, or by the addition of a branch usually derived from another source, such as the internal circumflex artery of the thigh, or the obturator artery, or very rarely the deep femoral artery. In one case the dorsal artery of the penis was thus given off (Arthur Thomson, Journ. Anat., xix, 330).

The *deep epigastric artery* occasionally arises higher than usual, as at an inch and a half, or even two inches and a half, above Poupart's ligament; and it has been seen to arise below that ligament from the femoral, or from the deep femoral artery. The epigastric frequently furnishes the obturator artery as already described (p. 476); and a few examples are recorded in which the epigastric artery arose from an obturator furnished by the internal iliac artery. In a single instance the epigastric artery was represented by two branches, one arising from the external iliac, and the other from the internal iliac artery (Lauth). Some combinations of the epigastric with the internal circumflex, or with the circumflex iliac, or with both those vessels, have been noticed.

The *deep circumflex iliac artery* sometimes deviates from its ordinary position,—arising at a distance not exceeding an inch above Poupart's ligament. Deviations in the opposite direction are not so frequent, but it is occasionally found arising below the ligament, from the femoral artery.

#### SURGICAL ANATOMY OF THE EXTERNAL ILIAC ARTERY.

The external iliac artery is usually tied about midway between its commencement and the origin of the epigastric artery. It may be exposed by a curved incision, about four inches in length, commencing about an inch above and a little outside the middle of Poupart's ligament, and terminating about an inch above the anterior superior iliac spine. After dividing carefully the integument, the abdominal muscles, and the transversalis fascia, the peritoneum (to which the spermatic vessels adhere) is raised from the iliac fossa, and the artery is found at the margin of the pelvis, lying along the inner border of the psoas muscle. The vein is close to the artery, on its posterior and inner aspect; the genital branch of the genito-crural nerve lies on it rather to the outer side; and the circumflex iliac vein crosses it near Poupart's ligament. In order to introduce the ligature, it is necessary to divide the layer of subperitoneal tissue which binds the vessel down to the iliac fascia; and the needle should be passed from within outwards on both sides of the body.

*Collateral circulation.*—After ligature of the external iliac artery, blood is conveyed to the lower end of that vessel through the anastomoses of the epigastric with the internal mammary, intercostal, and lumbar arteries, and of the circumflex iliac with the lumbar and ilio-lumbar arteries; to the femoral trunk also by the anastomoses of the branches of the deep femoral artery with the branches of the internal iliac, viz., the internal circumflex with the obturator and sciatic arteries, the external circumflex with the gluteal, and the perforating arteries with the sciatic.

#### FEMORAL ARTERY.

The femoral artery is that portion of the artery of the lower limb which lies in the upper three-fourths of the thigh,—its limits being marked above by Poupart's

ligament, and below by the opening in the great adductor muscle, after passing through which the artery receives the name of popliteal.

At its commencement the femoral artery is of the same size as the external iliac

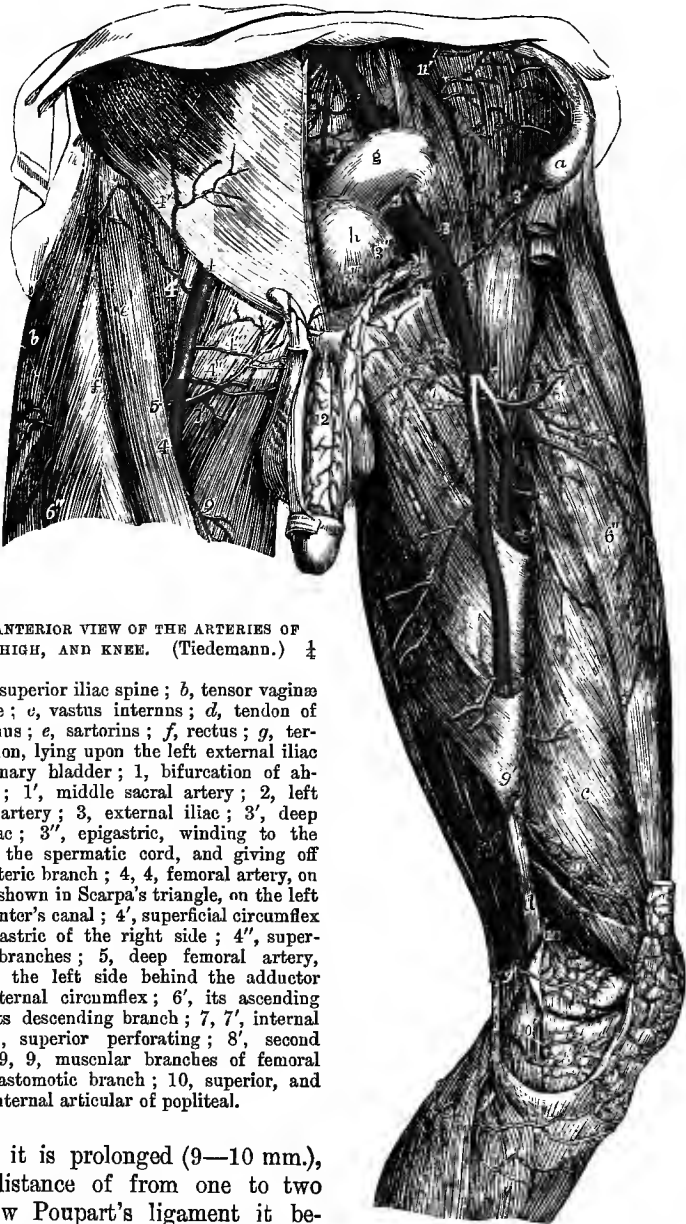


Fig. 387.—ANTERIOR VIEW OF THE ARTERIES OF THE PELVIS, THIGH, AND KNEE. (Tiedemann.)  $\frac{1}{2}$

*a*, anterior superior iliac spine; *b*, tensor vaginae femoris muscle; *c*, vastus internus; *d*, tendon of adductor magnus; *e*, sartorius; *f*, rectus; *g*, termination of colon, lying upon the left external iliac artery; *h*, urinary bladder; 1, bifurcation of abdominal aorta; 1', middle sacral artery; 2, left common iliac artery; 3, external iliac; 3', deep circumflex iliac; 3'', epigastric, winding to the inner side of the spermatic cord, and giving off 3''', its cremasteric branch; 4, femoral artery, on the right side shown in Scarpa's triangle, on the left exposed in Hunter's canal; 4', superficial circumflex iliac and epigastric of the right side; 4'', superficial pudic branches; 5, deep femoral artery, descending on the left side behind the adductor longus; 6, external circumflex; 6', its ascending branch; 6'', its descending branch; 7, 7', internal circumflex; 8, superior perforating; 8'', second perforating; 9, 9'', muscular branches of femoral artery; 9'', anastomotic branch; 10, superior, and 10', inferior internal articular of popliteal.

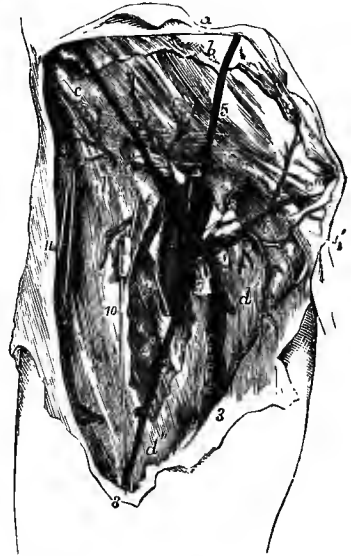from which it is prolonged (9—10 mm.), but at a distance of from one to two inches below Poupart's ligament it becomes suddenly smaller (i) in consequence of its giving off a large branch, the *deep femoral artery*, for the supply of the muscles of the thigh. The short portion of the vessel above the origin of its deep branch is frequently referred to as the *common femoral artery*, which is then described as dividing into the *superficial femoral* (the continuation of the trunk) and the *deep femoral arteries*.



A general indication of the direction of the femoral artery, over the fore part and inner side of the thigh, is given by a line reaching from a point midway between the anterior superior iliac spine and the symphysis pubis above to the prominent tuberosity on the inner condyle of the femur below, the hip-joint having been first slightly flexed, and the thigh abducted and rotated out. In the first part of its course the artery lies along the middle of the depression known as Scarpa's triangle, between the ilio-psoas muscle on the outer side, and the adductor muscles on the inner side of the limb. In this situation the beating of the artery may be felt, and the circulation through the vessel may be most easily controlled by pressure. At a distance of from three to four inches below Poupart's ligament, the sartorius muscle, which forms the outer boundary of Scarpa's triangle, inclining inwards, comes to lie over the artery, and conceals the vessel in the remainder of its extent. Beneath the sartorius the artery is contained, together with the femoral vein and the internal

Fig. 388.—DISSECTION OF THE RIGHT GROIN, SHOWING THE FEMORAL VESSELS AND THEIR SUPERFICIAL BRANCHES. (R. Quain.)  $\frac{1}{2}$

*a*, integument of abdomen; *b*, superficial abdominal fascia; *b'*, the part descending on the spermatic cord; *c*, *c*, aponeurosis of external oblique muscle; *c'* the same near the external abdominal ring; *c''*, inner pillar of the ring; *d*, iliac part of the fascia lata; *d'*, pubic part; *e*, *e*, femoral sheath laid open, the inner letter is immediately over the femoral canal; *e'*, sartorius muscle, partially exposed; 1, femoral artery, having 2, the femoral vein to its inner side; the septum of the sheath is shown between the two vessels; 3, internal saphenous vein; 3', its anterior branch; 4, superficial circumflex iliac vein; 5, superficial epigastric vein; 6, external pudic vessels; 7 to 8, some of the lower inguinal glands receiving twigs from the vessels; 9, internal, 10, middle, and 11, external cutaneous nerves.



saphenous nerve, in an elongated intermuscular space which is called Hunter's canal, and which is bounded externally by the vastus internus muscle, internally and posteriorly by the adductors.

While passing through Scarpa's space, the femoral artery is covered only by the integument and the iliac portion of the fascia lata, as well as, in its upper part, by the femoral sheath which invests both the artery and the vein. In the rest of its course it is covered by the sartorius muscle, and also by a dense fibrous membrane which stretches across from the tendons of the long and great adductors to the vastus internus muscle, and forms the anterior wall of Hunter's canal. The artery rests at first upon the psoas muscle, by which it is separated from the margin of the pelvis and the capsule of the hip-joint; next it is placed in front of the pectineus and adductor brevis muscles, the companion vein and deep femoral vessels being interposed; afterwards, it lies upon the long adductor muscle; and lastly, upon the tendon of the great adductor. In the lower half of its course, it has immediately on its outer side the vastus internus muscle, which intervenes between it and the internal surface of the femur.

At the groin, the artery, after having passed over the margin of the pelvis, is placed in front of the innermost part of the head of the femur; and at its lower end, the vessel lies close to the inner side of the shaft of the bone; but in the intervening space, in consequence of the projection of the neck and shaft of the femur

outwards, while the artery holds a straight course, it is separated from the bone by a considerable interval.

*Relation to veins.*—The *femoral vein* is very close to the artery, both being enclosed in the same sheath, and separated from each other only by a thin partition of fibrous membrane. At the groin, the vein lies on the same plane as the artery, and to its inner side; but gradually inclining backwards, the vein is placed behind the artery at the lower part of Scarpa's space, and afterwards gets somewhat to the outer

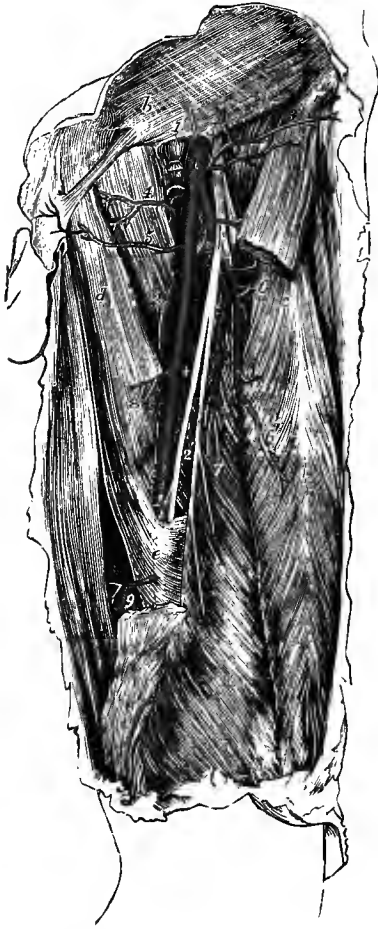

Fig. 389.—THE FEMORAL ARTERY AND ITS BRANCHES.  
(R. Quain.)  $\frac{1}{2}$

The sartorius muscle has been removed in part, so as to expose the artery in the middle third of the thigh; *a*, anterior superior iliac spine; *b*, aponeurosis of external oblique muscle near the external abdominal ring; *c*, rectus femoris; *d*, adductor longus; *e*, lower part of the aponeurosis covering the artery; 1, 1, femoral artery; 1' femoral vein, divided and tied close below Poupart's ligament; 2, 2, 2, deep femoral artery; 3, anterior crural nerve, the figure lies between two superficial epigastric branches of the artery; 3', superficial circumflex iliac artery; 4, 5, external pudic arteries, the deeper arising in this case from the internal circumflex; 6, external circumflex artery, with its ascending, transverse and descending branches separating from it; 6', branch to the rectus muscle; 7, branch to the vastus internus muscle; 8 and 9, some of the muscular branches of the femoral; +, origin of the second perforating artery.

side. The *deep femoral vein*, near its termination, crosses behind the femoral artery; and the *internal saphenous vein*, as it ascends on the fore part of the limb, lies to the inner side; but it not unfrequently happens that a superficial vein of considerable size ascends for some distance directly over the artery.

*Relation to nerves.*—At the groin, the *anterior crural nerve* lies a little to the outer side of the femoral artery (about a quarter of an inch), being separated from the vessel by some fibres of the psoas muscle and by the iliac fascia. Lower down in the thigh, the *internal saphenous nerve* accompanies the artery in Hunter's canal, lying along its anterior surface, until the vessel perforates the adductor magnus. The *internal cutaneous nerve* also crosses the upper part of the artery at the inner border of the sartorius.

**BRANCHES.**—The femoral artery gives off the following branches:—some small and superficial, which are distributed to the integument and glands of the groin and ramify on the lower part of the abdomen, viz., the external pudic (superior and inferior), the superficial epigastric, and the superficial circumflex iliac; the great nutrient artery of the muscles of the thigh, named the deep femoral or profunda; several muscular branches; and lastly, the anastomotic artery, which descends to the inner side of the knee.

1 and 2. The **external pudic arteries** arise either separately or by a common trunk from the inner side of the femoral artery. The *superior*, the more superficial branch, perforates the cribriform fascia in the saphenous opening, and courses up-

wards and inwards, passing in the male over the spermatic cord, to be distributed to the integument on the lower part of the abdomen and on the external organs of generation. The *inferior* branch, more deeply seated, runs inwards on the surface of the pectineus and adductor longus muscles (occasionally beneath the latter), to both of which it furnishes branches, and, piercing the fascia lata at the inner border of the thigh, is distributed to the scrotum in the male, to the labium in the female. The external pudic arteries anastomose with each other, with the superficial perineal artery, and with the cremasteric branch of the deep epigastric artery.

**3. The superficial epigastric artery**, arising from the femoral about half an inch below Poupart's ligament, passes forwards through the fascia lata (sometimes through the upper part of the saphenous opening) and runs upwards on the abdomen in the superficial fascia covering the external oblique muscle. Its branches, ascending nearly as high as the umbilicus, anastomose with superficial branches of the deep epigastric artery.

**4. The superficial circumflex iliac artery**, frequently arising in common with the superficial epigastric, runs outwards across the iliac muscle, in the direction of Poupart's ligament, towards the iliac crest. It gives small twigs to the iliacus and sartorius muscles, anastomosing with the deep circumflex iliac artery, and other branches which perforate the fascia lata and supply the integument of the hip.

All the preceding arteries give small branches to the lymphatic glands in the groin.

**5. The deep femoral or profunda artery (ii)**, the principal nutrient vessel of the thigh, usually arises from the outer and back part of the femoral, about an inch and a half below Poupart's ligament. It is directed at first somewhat outwards, in front of the iliacus muscle, so as to be visible for a short distance external to the continuation of the femoral trunk; then inclining inwards and slightly backwards, it descends behind that vessel, and between the adductor longus and magnus muscles near their femoral attachments. Giving off numerous branches on its way downwards, the profunda diminishes rapidly in size; and it terminates, at the junction of the middle and lower thirds of the thigh, as a small vessel which pierces the adductor magnus, and is known as the lowest perforating artery.

This artery lies successively in front of the iliacus, pectineus, adductor brevis, and adductor magnus muscles. The femoral and profunda veins and the adductor longus muscle are interposed between it and the superficial femoral trunk.

*Branches.*—The named branches of the deep femoral artery are the external and internal circumflex, and the perforating arteries. Other less regular offsets pass to the vastus internus, and to the adductor muscles.

**A. The external circumflex artery (iii-iv)**, the largest of the branches, arises from the outer side of the profunda near its commencement. Passing outwards for a short distance beneath the sartorius and rectus muscles, and between the divisions of the anterior crural nerve, it gives offsets to the neighbouring muscles, and ends by dividing into the three following branches:—

(a) The *ascending* branch runs upwards beneath the tensor vaginae femoris, supplies that muscle and the fore parts of the gluteus medius and minimus, and anastomoses with the terminal branches of the gluteal artery, as well as with offsets of the deep circumflex iliac. One branch passes up under cover of the rectus muscle, and is distributed to the hip-joint.

(b) The *transverse* branch, the smallest of the three, is directed outwards over the crureus, and divides into two or three branches which enter the vastus externus muscle on its deep surface, and anastomose with the upper perforating arteries.

(c) The *descending* branch, much larger than the others, sends its offsets downwards to the rectus, vastus externus and crureus muscles, anastomosing in the last with the inferior perforating arteries. One or two of the lowest branches reach

as far as the knee, and communicate with the upper external articular of the popliteal.

B. The **internal circumflex artery (iv)**, arising generally opposite the external from the inner and posterior part of the deep femoral artery, passes back-

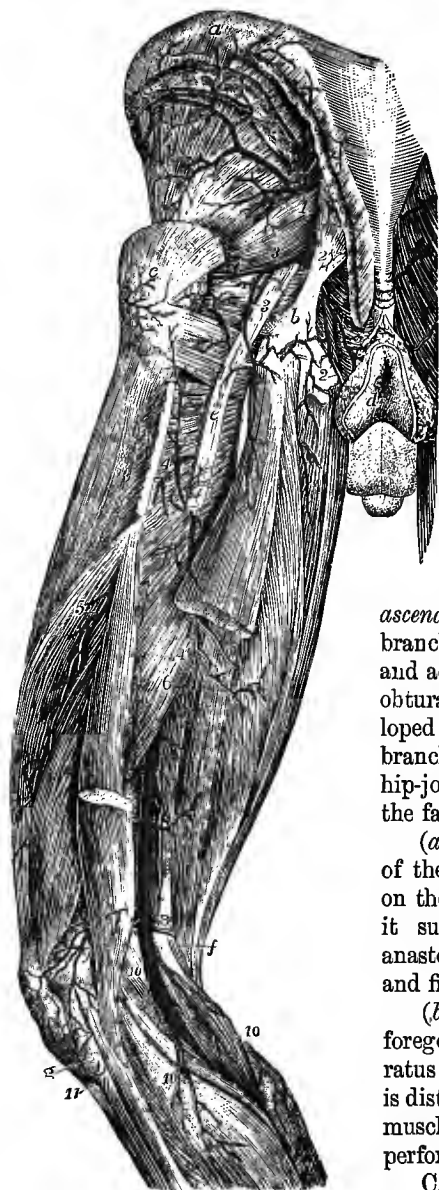

Fig. 390.—POSTERIOR VIEW OF THE ARTERIES OF THE PELVIS, THIGH, AND POPLITEAL SPACE. (Tiedemann.)  $\frac{1}{2}$

*a*, iliac crest; *b*, attachment of the great sacro-sciatic ligament to the tuberosity of the ischium; *c*, great trochanter; *d*, integument around the anus; *e*, great sciatic nerve; *f*, semitendinosus and semimembranosus muscles; *g*, head of fibula; 1, gluteal artery; 2, pudic; 3, sciatic; 4, first perforating artery; 4', its branch to the hamstring muscles; 5, 6, branches of the lower perforating arteries; 7, 7', popliteal artery, near the upper figure the origin of the superior muscular branches; 8, on the tendon of the adductor magnus, near the origin of the superior articular branches; 9, the anastomosis of the external superior articular with other branches; 10, 10', sural branches; 11, anterior tibial recurrent artery.

wards between the psoas and pectineus muscles, and over the upper border of the adductor brevis, towards the small trochanter of the femur, close to which it divides into two terminal branches, *ascending* and *transverse*. It furnishes *muscular* branches, which supply the obturator externus and adductor muscles and anastomose with the obturator artery, and an *articular* branch (developed in inverse proportion to the articular branch of the obturator artery), which enters the hip-joint through the cotyloid notch and supplies the fat and synovial membrane in the interior.

(*a*) The *ascending* branch follows the tendon of the obturator externus muscle to the hollow on the inner side of the great trochanter, where it supplies the external rotator muscles, and anastomoses with offsets of the gluteal, sciatic, and first perforating arteries.

(*b*) The *transverse* branch, larger than the foregoing, passes backwards between the quadratus femoris and adductor magnus muscles, and is distributed to the upper parts of the hamstring muscles, anastomosing with the sciatic and first perforating arteries.

C. The **perforating arteries** are subject to considerable variation in their arrangement, but they are generally four in number, including the terminal branch of the parent vessel. They pass backwards close to the femur, through small tendinous arches in the insertion of the adductor magnus muscle, and give considerable branches to the hamstring muscles, as well as small twigs to the great sciatic nerve, and a series of cutaneous branches, which issue along the back of the external inter-

muscular septum and supply the integument on the outer and posterior aspects of the thigh. All these offsets anastomose with one another, the upper ones also with the sciatic and internal circumflex arteries, and the lower ones with branches of the popliteal artery. Much diminished in size, the perforating arteries are continued outwards, winding round the back of the femur, the first passing through the insertion of the gluteus maximus and the others through the short head of the biceps and the external intermuscular septum, to terminate in the vastus externus and crureus muscles, where they anastomose with branches of the external circumflex artery.

(a) The *first perforating artery* passes backwards at the lower border of the pectineus muscle, through the fibres of the adductor brevis and adductor magnus, to both of which it furnishes branches, and is distributed mainly to the hamstring muscles and the lower end of the gluteus maximus. One branch ascends beneath the latter muscle on the back of the femur, and joins in the anastomosis in the hollow internal to the great trochanter with the gluteal, sciatic and internal circumflex arteries. Only a very small vessel is continued through the gluteus maximus into the vastus externus muscle.

(b) The *second perforating artery* is frequently united at its origin with the first, a little below which it pierces the adductor brevis and magnus muscles.

(c) The *third perforating artery* pierces the adductor magnus muscle below the insertion of the adductor brevis. The principal *medullary artery* of the femur is derived from either the second or third perforating artery.

(d) The *fourth perforating artery* supplies chiefly the short head of the biceps muscle. It frequently gives a second artery to the femur.

**6. Muscular branches.**—In Scarpa's triangle the femoral artery gives some small branches to the surrounding muscles. In Hunter's canal a variable number of larger branches is given off to the sartorius, vastus internus, and adductor muscles. A constant branch, of considerable size, arises from the femoral artery near its termination (sometimes from the beginning of the popliteal) and passes outwards close to the back of the femur, perforating the short head of the biceps and the external intermuscular septum, to end in the outer part of the crureus muscle.

**7. The anastomotic artery (iv)** arises from the femoral close to the opening in the adductor magnus muscle, and immediately divides into two branches, superficial and deep, which are, however, not unfrequently given off separately from the femoral trunk.

(a) The *superficial* branch accompanies the internal saphenous nerve to the inner side of the knee, giving offsets to the lower parts of the sartorius and gracilis muscles, and ends by supplying the skin of the upper and inner part of the leg. Small twigs anastomose over the inner tuberosity of the tibia with the lower internal articular artery of the popliteal.

(b) The *deep* branch descends, embedded in the fibres of the vastus internus muscle, along the front of the adductor magnus tendon to the inner condyle of the femur, where it anastomoses with the internal articular arteries. It supplies the vastus internus and crureus muscles, and sends small offsets outwards across the front of the femur, as well as one of larger size at the upper border of the patella, to join the superior external articular artery from the popliteal.

**Varieties of the femoral artery and its branches.**—In some rare cases the main artery of the lower limb has been found springing from the internal iliac trunk, being continued from a greatly enlarged sciatic artery, and descending with the great sciatic nerve along the back of the thigh to the popliteal space, where its connections and ending are similar to those of the vessel having the normal arrangement. The external iliac artery is then small, and

terminates in the profunda and other branches usually derived from the femoral artery. Ten examples of this deviation from the normal condition of the vessels are recorded.

In one instance met with by Tiedemann the external iliac artery divided near Poupart's ligament into two parts, which united again at the level of the small trochanter. A somewhat similar case is figured by Dubrueil, in which a "vas aberrans" is given off from the lower end of the external iliac artery, and descends on the inner side of the main trunk, to join the femoral about an inch below the origin of the profunda. Several instances are recorded of division of the femoral artery, below the origin of the profunda, into two vessels which reunite a variable distance above the opening in the adductor magnus, so as to form a single popliteal artery.

*Branches.*—The *deep femoral artery* is sometimes given off from the inner side of the parent trunk, and more rarely from the back part of the vessel. It has also been found in a few instances arising from the front of the femoral artery, and winding inwards over the femoral vein to gain its usual position below. Occasionally its origin is less than one inch, or more than two inches, below Poupart's ligament. It was found by R. Quain, in one instance arising above Poupart's ligament, and in another four inches below that band; but in the latter case the internal and external circumflex arteries did not arise from the profunda. As a very rare occurrence, absence of the profunda has been met with, the circumflex and perforating arteries arising separately from the femoral trunk (Hyrtl, A. H. Young).

The *external circumflex artery* sometimes arises directly from the femoral; or it may be represented by two branches, of which, in most cases, one proceeds from the femoral, the other from the profunda; both branches, however, occasionally arise from the profunda, much more rarely from the femoral artery.

The *internal circumflex artery* may be transferred to the femoral above the origin of the profunda. Examples have also been met with in which the internal circumflex arose from the epigastric, from the circumflex iliac, or from the external iliac artery.

In a large number of cases (578) the profunda failed to give the external circumflex in 15 per cent., the internal circumflex in 21 per cent., and both circumflex arteries in 4 per cent. (R. Quain; J. Srb).

Many occasional branches have been seen arising from the femoral, as the deep epigastric, circumflex iliac, or an aberrant obturator artery; more rarely the ilio-lumbar, or the dorsal artery of the penis. The *great saphenous artery* is a branch that has been occasionally met with. It arises either above or below the origin of the profunda, and running at first between the vastus internus and adductor magnus muscles, it issues from the lower end of Hunter's canal to reach the inner aspect of the knee, whence it accompanies the internal saphenous vein even as far as the internal malleolus. This vessel is normal in many mammals.

#### SURGICAL ANATOMY OF THE FEMORAL ARTERY.

Ligature of the *common femoral artery* is occasionally practised, and has been successful in several cases. The proximity of the epigastric and circumflex iliac branches of the external iliac artery, the presence of a number of small anastomosing branches springing from the trunk itself, and the possibility of the profunda, or one of the circumflex arteries, arising at a higher level than usual must, however, be borne in mind in considering the propriety of applying a ligature to this part of the vessel.

In performing the operation, the integument and the iliac portion of the fascia lata are divided either by a transverse incision one inch and a half long, with its centre placed over the artery, carried parallel to and half an inch below Poupart's ligament, or by a longitudinal incision of equal extent in the line of the vessel (p. 487), commencing close below Poupart's ligament. Any superficial arteries that have been cut being secured, the femoral sheath is then laid open, and the artery freed from its areolar investment. The vein is here to the inner side of the artery, and, being separated from that vessel by a septum in the femoral sheath, does not come into view. The needle should be passed from within outwards.

The *superficial femoral artery* may be tied either immediately below Scarpa's triangle, or in Hunter's canal. The former position is that usually preferred by surgeons, owing to the superficial position of the vessel, and its freedom from large branches. The hip having been slightly flexed, and the thigh everted, an incision about three and a half inches long, and so placed that its centre is about four and a half inches from Poupart's ligament, is made in the line of the artery. The integument and fascia lata are cut through at once, and the sartorius muscle exposed. The inner border of the sartorius is then raised and drawn well outwards, together with the internal cutaneous nerve which lies along this edge of the muscle (fig. 388), and the sheath of the artery is opened in the centre of the incision and separated from the vessel. The femoral vein is not seen, as it is placed behind the artery, only a very thin layer of connective tissue being interposed between the two. The needle is to be passed from within

outwards, its point being kept close to the artery. A considerable branch of the saphenous vein may be divided in making the first incision, and if so will require a ligature.

To reach the artery in Hunter's canal a longer incision is necessary, in consequence of the greater depth of the vessel, and it should be made a finger's breadth internal to the line of the artery, care being taken to avoid the internal saphenous vein. The superficial structures and the fascia lata having been cut through, the sartorius muscle is exposed and is recognized by its fibres running parallel to the line of the incision. The outer border of this muscle is then freed and drawn inwards, when the aponeurosis covering the femoral vessels is laid bare, and is to be carefully divided. The sheath of the artery is now opened, avoiding the internal saphenous nerve which lies on the surface of the vessel, and the needle is to be passed from without inwards, as the vein is placed behind and slightly to the outer side of the artery.

*Collateral circulation.*—When the common femoral artery has been tied, the circulation in the lower limb is carried on by means of the anastomoses of the internal pudic artery with the pudic branches of the femoral, of the obturator with the internal circumflex, of the circumflex iliac and gluteal with the external circumflex, and of the sciatic with the internal circumflex and upper perforating branches of the profunda. After ligature of the superficial femoral artery, blood reaches the distal portion of the limb through the anastomoses of the descending branch of the external circumflex artery with the articular arteries of the knee, and through the communications along the back of the thigh, between the sciatic artery, the terminal branches of the internal circumflex, the perforating arteries and the branches of the popliteal. In several instances in which the condition of the vessels has been examined after ligature of the femoral (or external iliac) artery, the *comes nervi ischiadici* has been found much enlarged, forming, with anastomotic branches from the perforating arteries, a vessel which accompanies the great sciatic nerve, and ends below in the popliteal artery or one of its branches.

#### POPLITEAL ARTERY (I—II).

The popliteal artery, continuous with the femoral, is placed at the back of the knee, and extends along the lower fourth of the thigh and the upper sixth of the leg. It reaches from the opening in the adductor magnus to the lower border of the popliteus muscle, where it divides into the anterior and posterior tibial arteries. Its termination is on a level with the lower part of the tubercle of the tibia.

In the first part of its course the popliteal artery inclines slightly from within outwards, over the inner portion of the popliteal surface of the femur, to reach a point behind the middle of the knee-joint, whence it descends vertically to its lower end. Being deeply situated in its whole extent, it is covered at its upper end by the semimembranosus muscle; for a short distance above the knee it is placed in the popliteal space; below this it is covered by the gastrocnemius muscle and is also crossed by the plantaris; and its termination is beneath the upper margin of the soleus muscle.

At its commencement the artery lies close to the inner side of the femur, but in descending it is separated by an interval from the somewhat hollowed popliteal surface of the bone; it then rests on the posterior ligament of the knee-joint, and lastly on the popliteus muscle.

*Relation to veins.*—The *popliteal vein* lies close to the artery throughout. At the upper end it is placed to the outer side and somewhat behind; it then gradually crosses over the artery, and below gains the inner side. The vein is frequently double along the lower part of the artery, and more rarely also at the upper part. The *short saphenous vein*, ascending to join the popliteal, is also placed over the artery in the lower part of the popliteal space.

*Relation to the nerve.*—The *internal popliteal nerve* lies at first to the outer side of, but much nearer to the surface than, the artery; it afterwards crosses gradually over the vessels, and is placed behind and to the inner side of them below the joint. The nerve is separated from the artery throughout its course by the vein.

**BRANCHES.**—The branches of the popliteal artery may be arranged in two sets, viz., the muscular and the articular.

A. The muscular branches are divided into a superior and an inferior group.

1. The **superior muscular** branches, three or four in number, are distributed to the lower parts of the adductor magnus and hamstring muscles, and anastomose with the perforating and upper articular arteries. Small offsets pass from these branches to the internal popliteal nerve and to the skin, and also communicate above with the branches of the perforating arteries.

2. The **inferior muscular** or **sural arteries**, generally two in number, and of considerable size, arise from the back of the popliteal artery, a little above the knee-joint, and enter, one the outer, and the other the inner head of the gastrocnemius muscle, which they supply, as well as the plantaris and the upper part of the soleus muscle.

Over the surface of the gastrocnemius, on each side and in the middle of the limb, are slender branches, which descend a considerable distance along the calf of

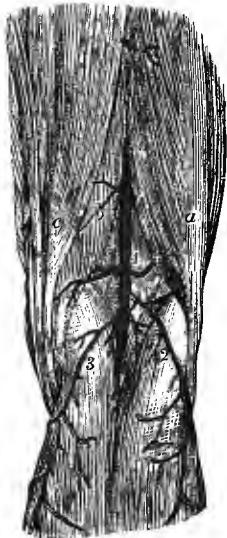


Fig. 391.—VIEW OF THE POPLITEAL ARTERY AND ITS BRANCHES IN THE RIGHT LEG. (Tiedemann.)  $\frac{1}{2}$

*a*, biceps muscle; *b*, semimembranosus; *c*, semitendinosus; 1, popliteal artery, 2, 3, superficial sural branches; 4, outer, 5, inner superior articular branch; 6, superior muscular; 7, median superficial artery.

the leg and supply the integument. These small vessels (*superficial sural*) may arise either from the popliteal trunk or from its sural branches.

B. The articular arteries are five in number. Two of these pass off nearly at right angles from the popliteal artery, one on each side, above the condyles of the femur; two others have a similar arrangement below the knee-joint; and the fifth passes directly forwards into the centre of the joint.

1. The **superior internal articular artery** is directed inwards just above the inner head of the gastrocnemius, and beneath the inner hamstring muscles, to all of which it furnishes small offsets. Winding round the inner side of the femur, between the bone and the tendon of the adductor magnus, it divides under cover of the vastus internus muscle into branches, which anastomose with the deep part of the anastomotic, the upper external articular, and the lower articular arteries. The size of this artery varies inversely with that of the deep part of the anastomotic branch of the femoral.

2. The **superior external articular artery** ( $\vee$ ), larger than the internal, runs outwards above the outer head of the gastrocnemius, under cover of the biceps, and, perforating the intermuscular septum, enters the lower part of the crureus muscle. Its branches anastomose above with the descending branch of the external circumflex artery, below with the lower external articular artery, and internally with the upper internal articular artery and the deep branch of the anastomotic, forming with the last a considerable arch at the upper border of the patella.

3. The **inferior internal articular artery** ( $\vee$ ), the larger of the two lower branches, inclines at first downwards and inwards along the upper margin of the popliteus muscle, to which it gives branches, and then passes forwards below the inner tuberosity of the tibia, between the internal lateral ligament and the bone. Its offsets ramify over the inner and fore part of the joint, as far as the patella and its ligament, and anastomose with the superficial branch of the anastomotic, the upper internal articular, and lower external articular arteries.



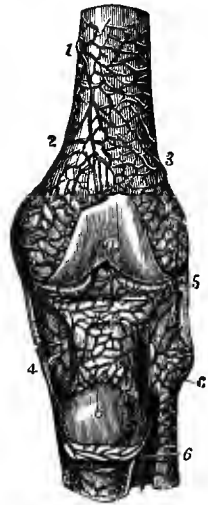
4. The **inferior external articular artery** takes its course outwards, at first under cover of the outer head of the gastrocnemius and over the tendon of the popliteus, afterwards beneath the external lateral ligament of the knee and the tendon of the biceps muscle, and resting against the margin of the external semilunar fibrocartilage. Having reached the fore part of the joint, it divides near the patella into branches, some of which communicate with the lower internal articular artery and with the recurrent branch from the anterior tibial, while others anastomose with the upper articular arteries.

5. The **middle or azygos articular artery** is a small branch which arises opposite the flexure of the joint, and pierces the posterior ligament to be distributed to the crucial ligaments and other structures within the articulation. Small twigs also pass forwards in the mucous ligament to the fat at the front of the joint, and communicate with the other articular arteries.

The upper and lower articular arteries of the popliteal, the anastomotic branch of the femoral, and the anterior tibial recurrent artery form, by their communica-

Fig. 392.—THE DEEP ANASTOMOSES OF THE FRONT OF THE KNEE.  
(Tiedemann.)  $\frac{1}{4}$

*a*, patellar surface of femur; *b*, posterior surface of the patella which, with the ligamentum patellae, has been turned down; *c*, head of fibula; 1 and 2, branches of the anastomotic and superior internal articular arteries, ramifying on the bone and anastomosing with the superior external articular branch 3, and with other arteries within and below the joint; 4, branches of the internal inferior articular; 5, external inferior articular; 6, anterior tibial recurrent artery.



tions over the front of the knee, a superficial wide-meshed network of fine vessels between the fascia and skin, and a deeper and closer network of larger vessels, in contact with the bones, from which numerous offsets proceed to the interior of the joint.

**Varieties.**—Deviations from the ordinary condition of the popliteal artery are not frequent. The principal departure from the ordinary arrangement consists in the high division of the vessel into its terminal branches. Such an early division has been found to take place opposite the knee-joint, or in the intercondylar fossa of the femur, but not higher. In one case, the artery was continued down to the middle of the leg before dividing (Portal).

Occasionally the popliteal artery divides into three terminal branches, viz., the anterior and posterior tibial and the peroneal arteries; or more rarely into anterior tibial and peroneal arteries, the posterior tibial being small or absent.

The popliteal artery has been seen dividing in the upper part of the popliteal space into two branches which reunited after a separate course of about two inches (A. Ward Collins, Journ. Anat., xx, 32); and in another instance a "vas aberrans" passed from the upper end of the popliteal artery to the beginning of the posterior tibial (J. Y. Mackay, "Memoirs and Memoranda in Anatomy," 1889, 176).

One instance is recorded in which the popliteal artery passed downwards internal to the origin of the inner head of the gastrocnemius muscle, and then turned outwards between that and the internal condyle of the femur, to gain the popliteal space (T. P. A. Stuart). In two or three cases the positions of the artery and vein have been found reversed. The artery is occasionally separated from the vein by an accessory slip of origin of the gastrocnemius muscle (p. 263).

The *azygos articular* branch often arises from one of the other articular arteries, especially the superior external branch. There are sometimes several small middle articular branches. Two examples of a *small saphenous artery*, formed by the enlargement of the median superficial sural branch, and descending with the short saphenous nerve and vein to the back of the external malleolus, have been met with.

## SURGICAL ANATOMY OF THE POPLITEAL ARTERY.

The popliteal artery is very rarely tied, since, in cases of aneurism of the arteries of the upper part of the leg, ligature of the superficial femoral artery is both an easier and a more successful operation. The artery might, however, if necessary, be secured either in its upper or its lower part, but in the middle portion of its extent, while contained within the popliteal space, the artery is closely covered by the vein and nerve, as well as by the sural branches of the vessels and the external saphenous vein; and moreover the principal branches are also arising here, so that a ligature cannot be safely applied to this part of the vessel. In its upper part the artery may be reached either by making an incision on the inner side of the thigh in its lower third, and then separating the sartorius and inner hamstring muscles from the tendon of the adductor magnus, or by dividing the integument in the middle line of the limb posteriorly, and then turning inwards the semimembranous muscle. In an operation upon the lower part of the artery, the incision would have to be carried between the heads of the gastrocnemius muscle, care being taken to avoid the external saphenous vein.

## POSTERIOR TIBIAL ARTERY (III).

The posterior tibial artery, the larger of the two vessels resulting from the bifurcation of the popliteal, lies along the back of the leg, between the superficial and deep muscles of this part, being closely bound down to the latter group by the fascia which covers them. It extends from the lower border of the popliteus muscle to the lower border of the internal annular ligament, where it divides, on a level with a line drawn from the point of the internal malleolus to the centre of the convexity of the heel, into the internal and external plantar arteries.

Situated at its origin opposite the interval between the tibia and fibula, the artery approaches the inner side of the leg as it descends, and lies behind the tibia; at its lower end it is placed midway between the inner malleolus and the prominence of the heel. Very deeply seated at the upper part, where it is covered by the fleshy portions of the gastrocnemius and soleus muscles, it becomes superficial in the lower third of the leg, being there covered only by the integument and two layers of fascia, and by the annular ligament behind the inner malleolus. At its termination the artery is placed beneath the origin of the abductor hallucis muscle. It lies successively upon the tibialis posticus, the flexor longus digitorum, and, at its lower end, directly on the tibia and the ankle-joint. Behind the ankle, the tendons of the tibialis posticus and flexor longus digitorum lie between the artery and the internal malleolus; while the tendon of the flexor longus hallucis is to its outer side.

*Relation to the veins and nerve.*—The posterior tibial artery is accompanied by two *venae comites*. The *posterior tibial nerve* is at first on the inner side of the artery, but as soon as the latter has given off its peroneal branch, the nerve crosses over the vessel and is continued down on its outer side. Beneath the internal annular ligament the artery is frequently placed between the *internal* and *external plantar* divisions of the posterior tibial nerve.

**BRANCHES.**—The posterior tibial artery gives off one large branch—the peroneal artery, and numerous small offsets which will be first described.

**1.** Several **muscular** branches are distributed to the deep-seated muscles, and one or two of considerable size to the inner part of the soleus muscle. A small offset from one of these perforates the tibial attachment of the soleus, and ascends over the popliteus muscle to anastomose with the lower internal articular artery.

**2.** The **medullary artery** of the tibia, the largest of its kind in the body, arises from the posterior tibial near its commencement, and, after giving small branches to the neighbouring muscles, enters the foramen in the bone. This vessel not unfrequently arises from the anterior tibial artery.

**3.** Two or three **cutaneous** branches, of small size, supply the skin of the inner side of the leg.

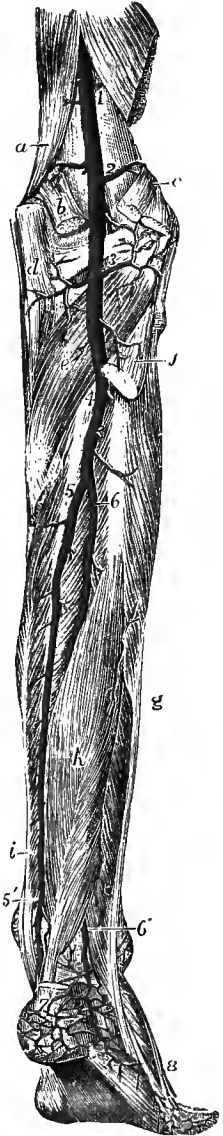
**4.** A **communicating** branch passes transversely, beneath the flexor longus

hallucis muscle, between the posterior tibial and peroneal arteries, about an inch above the ankle-joint. A second loop of communication between these vessels is sometimes present, lying in the fat beneath the tendo Achillis.

5. One or two small **internal malleolar** branches pass inwards beneath the flexor longus digitorum and tibialis posticus muscles, and ramify over the internal

Fig. 393.—DEEP VIEW OF THE ARTERIES OF THE BACK OF THE RIGHT LEG. (Tiedemann.)  $\frac{1}{4}$

*a*, lower part of adductor magnus muscle; *b*, origin of inner head of gastrocnemius; *c*, outer head and plantaris; *d*, tendon of semi-membranosus; *e*, popliteus; *f*, fibular origin of soleus; *g*, peroneus longus; *h*, flexor longus hallucis; *i*, flexor longus digitorum; 1, upper part of popliteal artery; 2, origin of its superior articular branches; 3, origin of its inferior articular branches; the middle or azygos branch is seen between these numbers; 4, division of popliteal into anterior and posterior tibial arteries; 5, 5', posterior tibial; at 5', the internal malleolar branches are seen passing inwards, and the communicating branch outwards; 6, peroneal artery; 6', its continuation as posterior peroneal; 7, calcaneal branches; 8, external branches of the metatarsal of the dorsal artery of the foot.



malleolus, where they anastomose with similar offsets from the anterior tibial artery.

6. The **peroneal artery (iv)** lies deeply along the back part of the leg, close to the fibula. Arising from the posterior tibial artery about an inch below the lower border of the popliteus muscle, it inclines at first slightly outwards towards the fibula, being covered by the soleus and the deep layer of fascia, and resting upon the tibialis posticus muscle; it then descends vertically along the inner border of the bone and under cover of the flexor longus hallucis, being contained in a fibrous canal between the origins of that muscle and the tibialis posticus. Opposite the lower end of the interosseous space it gives off the anterior peroneal branch, and is thence continued downwards, being much reduced in size and taking the name of *posterior peroneal artery*, over the lower tibio-fibular articulation and behind the external malleolus, to terminate in branches which ramify on the outer surface and back of the os calcis. The peroneal artery is accompanied by two *venae comites*, and, until it enters the flexor longus hallucis, by the branch of the posterior tibial nerve to that muscle.

*Branches.*—(*a*) *Muscular* branches pass from the peroneal artery to the soleus, tibialis posticus, flexor longus hallucis, and peronei muscles. Small branches also perforate the interosseous membrane, and are distributed to the extensor longus digitorum and peroneus tertius muscles.

(*b*) A *medullary artery* enters the fibula.

(*c*) The *communicating* branch, lying close behind the tibia about an inch from its lower end, is a branch of variable size, which connects the peroneal and posterior tibial arteries, and also sends small twigs beneath the muscles to ramify over the inner side of the lower part of the tibia. This branch is sometimes wanting.

(*d*) The *anterior peroneal artery* (*v*), arising from an inch to an inch and a half above the ankle-joint, passes forwards below the interosseous membrane, and descends in front of the articulation between the tibia and fibula to the outer side of the tarsus. It communicates with the external malleolar branch of the anterior tibial artery, and supplies offsets to the peroneus tertius muscle and the articulations of the ankle; its terminal branches anastomose with the posterior peroneal and tarsal arteries.

(*e*) The *terminal* branches of the posterior peroneal artery (*external calcaneal*) anastomose with the external malleolar and tarsal arteries on the outer side of the foot, and over the heel with the internal calcaneal branches of the external plantar artery.

**Varieties.**—The *posterior tibial artery*, as well as the anterior tibial, is lengthened in those instances in which the popliteal artery divides higher up than usual. Not unfrequently the posterior tibial artery is diminished in size, and is subsequently reinforced, either by a transverse branch from the peroneal in the lower part of the leg, or, more rarely, by two transverse vessels, one crossing close to the bone, and the other over the deep muscles. In other instances the posterior tibial may exist only as a short muscular trunk in the upper part of the leg, or may be entirely wanting, while an enlarged peroneal artery takes its place from above the ankle downwards into the foot. One or two *internal calcaneal* branches (*v. p.* 500) are frequently given off from the lower end of the posterior tibial artery.

The posterior tibial artery is occasionally covered in the lower third of the leg by muscle, which may be an accessory long flexor of the toes (*p.* 265), or a slip of the soleus (*p.* 264).

The *peroneal artery* has been found to arise lower down than usual, about three inches below the popliteus muscle; and, on the contrary, it sometimes arises higher up from the posterior tibial, or even from the end of the popliteal artery. In some cases of high division of the popliteal artery, the peroneal artery is transferred to the anterior tibial. It more frequently exceeds than falls short of the ordinary dimensions, being enlarged to reinforce the posterior tibial. In those rare instances in which it is lost before reaching the lower part of the leg, a branch of the posterior tibial takes its place. Absence of the peroneal artery has been recorded by Otto and W. Krause, but these cases are explained by Barkow, as being correctly suppression of the posterior tibial artery between the origin of the peroneal and the communicating branch. The *anterior peroneal* branch is sometimes enlarged to compensate for the small size of the anterior tibial artery in the lower part of the leg, or to supply the place of that artery on the dorsum of the foot; or it may be absent and be replaced by the external malleolar branch of the anterior tibial.

#### PLANTAR ARTERIES.

The internal and external plantar arteries are the branches into which the posterior tibial divides, immediately below the internal annular ligament, where it is covered by the origin of the abductor hallucis muscle.

The **internal plantar artery** (*v*), much smaller than the external, lies along the inner side of the foot. Placed at first under cover of the abductor hallucis, it passes forwards in the interval between that muscle and the short flexor of the toes, and on reaching the head of the first metatarsal bone, considerably diminished in size, it terminates by joining the digital artery to the inner side of the great toe.

**Branches.**—(*a*) Small branches of this artery accompany the digital branches of the internal plantar nerve, and join the digital arteries in the inner three clefts. It also gives (*b*) offsets to the surrounding muscles, and (*c*) cutaneous branches, which appear in the furrow between the middle and internal portions of the plantar fascia. (*d*) Other branches pass inwards and appear at the upper border of the abductor hallucis muscle, supplying the integument and anastomosing with offsets of the dorsal artery of the foot; and (*e*) from the outer side one or more branches run deeply into the foot, to supply the articulations and anastomose with branches of the plantar arch.

The **external plantar artery** (*iv*) at first inclines outwards and forwards, to

reach the base of the fifth metatarsal bone ; it then turns obliquely inwards across the sole, to gain the interval between the bases of the first and second metatarsal bones, where it joins the dorsal artery of the foot ; and thus is completed the *plantar arch*, the convexity of which is turned forwards. At first the artery is placed, together with the external plantar nerve, between the calcaneum and the abductor hallucis ; farther on it lies between the flexor digitorum and flexor accessorius. As it turns forwards it lies in the interval between the short flexor of the toes and the abductor of the little toe, being placed along the line separating the

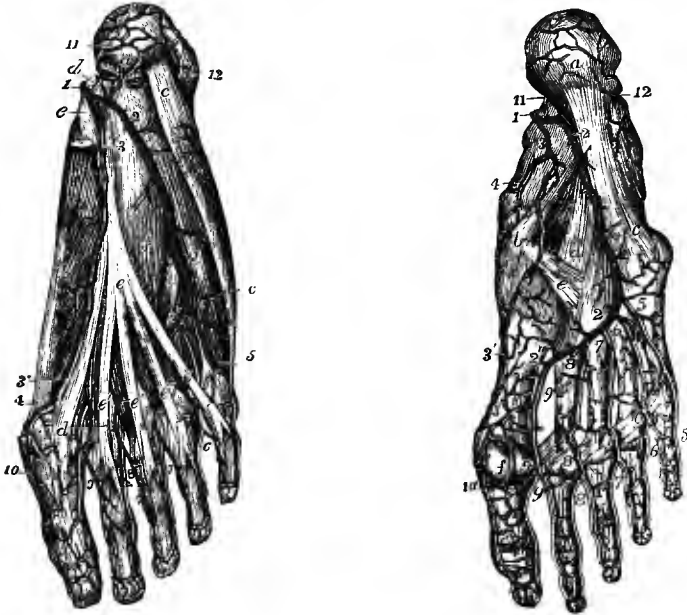


Fig. 394.—SUPERFICIAL VIEW OF THE ARTERIES IN THE SOLE OF THE RIGHT FOOT. (Tiedemann.)  $\frac{1}{2}$

*a*, tuberosity of the calcaneum close to the origins of the flexor brevis digitorum (cut short) and the abductor hallucis, of which a part is removed to show the plantar arteries ; *b*, abductor hallucis ; *c*, abductor minimi digiti ; *d*, tendon of the flexor longus hallucis ; *e*, tendon of the flexor longus digitorum ; *e'*, its four slips, close to the lumbricales muscles, passing on to perforate the tendons of the flexor brevis ; *f*, flexor accessorius ; *g*, flexor brevis minimi digiti ; 1, posterior tibial, dividing into the plantar arteries ; 2, 2', external plantar ; 3, internal plantar ; 3', the same passing forwards to communicate with 4, the digital branch for the great toe, derived from the dorsal artery of the foot ; 5, first digital branch of the fifth toe ; 6, placed in the angle of division of the second digital artery, between the fourth and fifth toes ; 7, third digital artery dividing similarly between the third and fourth toes ; 8, fourth digital artery dividing between the second and third toes ; 9, digital artery dividing between the first and second toes ; 10, internal digital artery of the great toe ; 11, calcaneal branches of the external plantar artery, anastomosing with 12, the calcaneal branches of the posterior peroneal artery.

Fig. 395.—DEEP VIEW OF THE ARTERIES IN THE SOLE OF THE RIGHT FOOT. (Tiedemann.)  $\frac{1}{2}$

All the muscles have been removed : *a*, calcaneal tuberosity ; *b*, internal cuneiform bone ; *a* to *c*, long, and *d*, short plantar ligament ; *e*, prolongation of the tibialis posticus tendon ; *f*, one of the sesamoid bones of the great toe ; 1, posterior tibial artery dividing into the plantar arteries ; 2, 2', external plantar artery ; 2', 2'', plantar arch ; 3, 3', internal plantar artery ; 3'', its communication with the internal digital artery of the great toe ; 4, branches of the internal plantar to the inner side of the foot ; 5, 5', first digital branch ; 6, second digital artery ; 6' its division between the fourth and fifth toes ; 7, third digital artery ; 7', its distribution to the third and fourth toes ; 8, fourth digital artery ; 8', its distribution to the second and third toes ; 9, fifth digital artery ; 9', its distribution to the first and second toes ; 10, internal digital branch of the great toe ; at the upper numbers, 6, 7, and 8, the posterior perforating branches are partially seen ; at 2'', the dorsal artery of the foot (in this instance of small size) is seen joining the plantar arch ; 11, and 12, calcaneal branches of the external plantar and posterior peroneal arteries.

middle from the external portion of the plantar fascia, and covered by that membrane. The remainder of the artery, which turns inwards and forms the plantar arch, is placed deeply against the interosseous muscles, and is covered by the flexors of the toes, the lumbricales muscles, and the adductor obliquus hallucis.

*Branches.*—A. *In its course to the fifth metatarsal bone*, the external plantar artery gives off (a) two or three *internal calcaneal* branches, which pierce the origin of the abductor hallucis muscle and ramify over the heel, anastomosing with the external calcaneal branches of the peroneal artery; (b) numerous *muscular* branches; (c) small offsets which ascend over the outer border of the foot and anastomose with the tarsal and metatarsal branches of the dorsal artery; and (d) *cutaneous* offsets, which appear in the groove between the middle and outer divisions of the plantar fascia.

B. *From the plantar arch* are given off the following branches:—

(a) From the concavity of the arch small offsets pass backwards to the articulations of the tarsus, and anastomose with the deep branches of the internal plantar artery.

(b) The *posterior perforating* branches, three in number, pass upwards through the back part of the three outer intermetatarsal spaces, between the heads of the dorsal interosseous muscles, and on reaching the dorsum of the foot inosculate with the interosseous branches of the metatarsal artery.

(c) The *digital* branches (v) are four in number. The *first* digital artery inclines outwards from the outermost part of the plantar arch, over the fifth metatarsal bone, and runs along the outer border of the little toe. The *second* digital artery passes forwards along the fourth intermetatarsal space, and near the cleft between the fourth and fifth toes divides into two collateral branches, which course along the contiguous borders of those toes. The *third* digital branch is similarly distributed to the fourth and third toes, and the *fourth* to the third and second toes.

The digital artery which supplies the opposed sides of the first and second toes, and that to the inner side of the great toe are derived from the ending of the dorsal artery of the foot.

Thus, as in the fingers, *collateral digital arteries* pass along the sides of the flexor aspect of each of the toes, and then inosculate across the last phalanx so as to form an arch, from the convexity of which minute vessels pass forwards to the extremity of the toe, and upwards to the matrix of the nail.

*Anterior perforating* branches, one in each space, are sent upwards by the digital arteries near their bifurcation, to communicate with the interosseous arteries on the dorsum of the foot. These branches are, however, often wanting in one or more of the outer spaces.

*Varieties.*—The arteries of the foot deviate from the normal arrangement much less frequently than those of the hand.

The *internal plantar artery* is sometimes smaller than usual, and has been seen terminating in the flexor brevis hallucis (Cruveilhier). On the other hand, it may be larger and supply alone the digital artery of the inner side of the great toe, or even the arteries of the contiguous sides of the great and second toes.

The *external plantar artery* occasionally varies in size, a diminution being accompanied by an enlargement of the dorsal artery of the foot, and *vice versa*. It has been observed very small, and not entering into the plantar arch, which was formed by the dorsal artery alone (Dubrueil, Cruveilhier).

The *posterior perforating* branches, which are usually very small vessels, are sometimes enlarged, and furnish the interosseous arteries on the back of the foot, the metatarsal branch of the dorsal artery, from which the dorsal interosseous arteries are usually derived, being in that case very small.

#### ANTERIOR TIBIAL ARTERY (IV).

The anterior tibial artery, the smaller of the two divisions of the popliteal trunk, extends from the lower border of the popliteus muscle to the bend of the ankle,

whence the vessel is afterwards prolonged to the hinder end of the interval between the first and second metatarsal bones, under the name of dorsal artery of the foot.

The anterior tibial artery is at first directed forwards between the attachments

Fig. 396.—ANTERIOR VIEW OF THE ARTERIES OF THE LEG AND FOOT. (Tiedemann.)  $\frac{1}{2}$

The tibialis anticus muscle is drawn inwards so as to bring the anterior tibial artery into view; the extensor proprius hallucis, the long extensor of the toes and the peroneus tertius muscles in their lower part, and the whole of the extensor brevis, have been removed. 1, superior external articular branch of the popliteal artery; 2, anterior tibial recurrent; 3, 3, anterior tibial, giving off muscular branches on each side; 4, dorsal artery of the foot; 5, external malleolar artery, anastomosing with the anterior peroneal which is seen descending upon the lower part of the fibula; the internal malleolar is represented proceeding from the inner side of the anterior tibial artery; 6, tarsal branch of the dorsal artery, in this instance larger than usual and reinforcing the next artery; 7, metatarsal branch, giving off the second dorsal interosseous artery; in the first interosseous space the dorsal artery of the foot is seen descending into the sole after having given off the first dorsal interosseous artery; between 8, and 8, the collateral dorsal digital arteries.



of the tibialis posticus muscle (p. 267), and through the aperture in the upper part of the interosseous membrane, lying here close to the inner side of the neck of the fibula, to the front of the leg. It then descends along the anterior surface of the interosseous membrane, gradually approaching the tibia, and in its lower part comes to lie over the front of that bone. The position of the artery may be indicated by a line drawn from a point midway between the head of the fibula and the external tuberosity of the tibia to the centre of the front of the ankle-joint.

In the upper two-thirds of the leg, while resting on the interosseous membrane, to which it is closely bound down by connective tissue, the artery is deeply placed between the tibialis anticus on its inner side and the extensor longus digitorum and extensor proprius hallucis muscles on its outer side. In the lower third, where the muscles become tendinous, the artery inclines forwards upon the tibia and is nearer to the surface, but is covered by the extensor proprius hallucis, which crosses it gradually from the outer to the inner side. Above the ankle it is placed also beneath the upper band of the anterior annular ligament.

*Relation to veins and nerves.*—The anterior tibial artery is accompanied by two *venae comites*. The *anterior tibial nerve*, coming from the outer side of the neck of the fibula, approaches the artery a short distance below the place where the vessel appears in front of the interosseous membrane. Lower down, the nerve for the most part lies in front of the artery, and at the ankle it is generally on the outer side of the vessel.

*BRANCHES.*—Before perforating the interosseous membrane the anterior tibial artery gives off the posterior tibial recurrent and the superior fibular branches. On the front of the leg it gives off the anterior tibial recurrent, numerous muscular branches, and the external and internal malleolar arteries.

1. The **posterior tibial recurrent artery** is a small branch which ascends beneath the popliteus muscle to the back of the knee-joint. It gives offsets to the popliteus and the upper tibio-fibular articulation, and anastomoses with the lower articular arteries from the popliteal. This branch is sometimes wanting.

2. The **superior fibular** branch, also of small size, arises most frequently from the anterior tibial artery, but it is sometimes derived from the posterior tibial, or from the lower end of the popliteal artery. It runs outwards across the neck of the fibula, perforating the attachment of the soleus, and is distributed to that muscle, to the peroneus longus, and to the integument.

3. The **anterior tibial recurrent artery** (v), larger than the posterior, arises from the trunk immediately after its passage through the aperture in the interosseous membrane. Ascending through the upper end of the tibialis anticus muscle, to which it furnishes offsets, this branch ramifies over the outer tuberosity of the tibia, and anastomoses with the lower articular arteries of the popliteal.

4. The **muscular** branches supply the muscles of the front of the leg, and send also three or four small twigs backwards through the interosseous membrane into the tibialis posticus, as well as other offsets forwards between the muscles to the skin.

5. The **external malleolar artery** (v-vi) arises near the ankle-joint, and is directed outwards beneath the extensor longus digitorum and peroneus tertius muscles, to ramify over the outer malleolus, forming anastomoses with the anterior peroneal and tarsal arteries. It furnishes twigs to the neighbouring articulations.

6. The **internal malleolar artery**, smaller than the foregoing, passes inwards beneath the tendon of the tibialis anticus, and ramifies over the internal malleolus, anastomosing with the corresponding branches from the posterior tibial artery.

#### DORSAL ARTERY OF THE FOOT (IV-V).

The dorsal artery of the foot, the continuation of the anterior tibial, extends from the bend of the ankle to the posterior end of the first intermetatarsal space. At this spot it turns downwards and passes between the heads of the first dorsal interosseous muscle into the sole, where it completes the plantar arch and supplies the inner side of the second and both sides of the great toes.

On the dorsum of the foot the artery lies in the interval between the tendons of the extensor proprius hallucis and extensor longus digitorum muscles, resting upon the tarsal bones, to which it is bound by an aponeurotic layer. It is covered by the integument and the dorsal fascia of the foot, at its upper end also by the lower band of the anterior annular ligament, and near its termination by the innermost slip of the extensor brevis digitorum muscle.

Two *venæ comites* accompany this artery, and the internal branch of the *anterior tibial nerve* lies usually on its outer side.

BRANCHES.—On the dorsum of the foot, the artery gives off two or three small internal branches, which ramify on the inner side of the tarsus, and anastomose with branches of the internal plantar artery, two external branches, which are of larger size, and are named tarsal and metatarsal arteries, and the first dorsal interosseous artery, which arises as the trunk bends downwards in the first space. As soon as it appears in the sole, the artery divides into two terminal offsets, an outer communicating branch which completes the plantar arch, and an inner digital artery to the great and second toes.

1. The **tarsal artery** (v) arises opposite the head of the astragalus, and inclines outwards beneath the extensor brevis digitorum muscle to the cuboid bone, where it divides into branches which anastomose with the external malleolar, the



peroneal, external plantar, and metatarsal arteries. It furnishes offsets to the extensor brevis digitorum, and to the tarsal articulations.

**2. The metatarsal artery**, arising near the bases of the metatarsal bones, is also directed outwards beneath the short extensor muscle, and terminates in branches which anastomose with offsets of the tarsal and external plantar arteries. It supplies small branches to the extensor brevis digitorum muscle and the articulations of the foot, and from the fore part of the arch formed by the vessel three dorsal interosseous arteries are given off.

The *dorsal interosseous arteries* (vi) pass forwards over the outer three intermetatarsal spaces, resting upon the dorsal interosseous muscles, to which they furnish small offsets. Opposite the metatarso-phalangeal articulations each artery divides into two *dorsal digital* branches, which run along the contiguous borders of the corresponding toes. These arteries communicate with the plantar arch at the back part of the interosseous spaces by means of the posterior perforating branches, and, less constantly, with the plantar digital arteries at the fore part of the spaces by the anterior perforating branches. From the outermost interosseous artery, or from the metatarsal artery itself, a small branch is given off to the outer border of the little toe.

**3. The first dorsal interosseous artery** (v), continuing the direction of the dorsal artery of the foot, runs forwards over the dorsal interosseous muscle of the first space, communicates with the corresponding plantar digital artery by an anterior perforating branch, and divides into *dorsal digital* branches for both sides of the great toe, and the inner side of the second toe. The branch to the inner side of the great toe is, however, frequently small or wanting.

**4. The plantar digital branch** passes forwards in the first interosseous space, sends inwards across the first metatarsal bone the artery for the inner side of the great toe, and terminates by dividing into collateral digital branches for the adjacent sides of the first and second toes.

**Varieties of the anterior tibial artery.**—*Origin.*—In instances of early division of the popliteal artery, the place of origin of the anterior tibial is necessarily higher than usual, and in these cases the commencement of the vessel may either descend by the side of the posterior tibial artery behind the popliteus, or it may pass in front of that muscle, resting against the outer tuberosity of the tibia, to reach the upper end of the interosseous space. The peroneal artery is occasionally found conjoined with the anterior tibial, that vessel having either a normal or a high origin.

*Course.*—The anterior tibial artery has been observed inclining outwards towards the fibula in the lower part of the leg, and then returning to its ordinary position on the dorsum of the foot. It has also been seen coming to the surface in the middle of the leg, and continued downwards from that point, covered only by the fascia and the integument (Pelletan, Velpeau). Velpeau also states that in one case the artery gained the front of the leg by passing with the musculo-cutaneous nerve round the outer side of the fibula.

*Size.*—This vessel is more frequently diminished than increased in size.

It may be defective in various degrees. Thus, the dorsal artery of the foot may fail to enter the sole, and the digital branches to the great and second toes are then derived from the external or the internal plantar division of the posterior tibial. In a farther degree of diminution, the anterior tibial ends at the ankle, or in the lower part of the leg; its place is then taken by the anterior peroneal artery, which forms the dorsal artery of the foot, the two vessels (anterior tibial and anterior peroneal) being either connected together or separate.

A few cases are recorded in which the anterior tibial artery was altogether wanting, its place in the leg being supplied by perforating branches from the posterior tibial artery, and on the dorsum of the foot by the anterior peroneal artery.

This artery is occasionally larger than usual, in that case compensating for a defective condition of the external plantar artery.

The *dorsal artery of the foot* is not unfrequently found curving outwards below the ankle-joint, and returning to its usual position at the back of the first interosseous space. It has also been seen passing through the second space into the sole.

The *metatarsal artery* varies greatly in its arrangement. It is sometimes given off higher than usual, and it occasionally arises in common with the tarsal artery. It may be smaller

than usual or absent, the deficiency being supplied by the tarsal artery, which furnishes one or more of the outer dorsal interosseous arteries (fig. 396). Occasionally there are two metatarsal arteries.

The *dorsal interosseous arteries* are sometimes derived mainly or solely from the plantar arch, by means of the posterior perforating branches.

#### SURGICAL ANATOMY OF THE ARTERIES OF THE LEG.

The *posterior tibial artery* may be tied at any spot in the lower two-thirds of the leg. To reach the artery in the middle third, an incision from three to four inches in length is made through the skin and fascia, parallel to, and about half an inch behind, the internal border of the tibia. The inner head of the gastrocnemius being drawn backwards, and the internal saphenous vein (if exposed) forwards, the fleshy fibres of the soleus are cut through until the deep aponeurosis of the latter muscle is reached. This is then divided for the whole length of the wound, and the deep layer of fascia, which is here thin, is exposed. On laying this open the artery is at once seen, being placed between the companion veins, and having the nerve to its outer side.

In the lower third of the leg, the artery is readily tied by means of an incision two inches long, placed midway between the inner border of the tibia and the edge of the tendo Achillis, and carried through the integument and the two layers of fascia.

The *peroneal artery* might, if necessary, be secured in the middle third of the leg. An incision, from three to four inches long, is made through the skin and fascia immediately over the outer border of the fibula, and the soleus drawn backwards. The fibres of the flexor longus hallucis are then to be raised from the posterior surface of the fibula, until the membranous wall of the canal containing the vessel is exposed, and on laying this open the artery will be found resting against the bone.

In order to apply a ligature to the *anterior tibial artery*, an incision is made along the front of the leg in the line of the vessel (see p. 501) for a distance of about three inches. In the upper part a longer incision is necessary than in the lower, in consequence of the greater depth of the artery, and a short transverse cut on each side through the dense fascia will facilitate the subsequent steps of the operation. The areolar interval between the tibialis anticus and the extensor longus digitorum is then opened up, and the muscles drawn well to the sides; in the lower part of the leg the extensor proprius hallucis must also be drawn outwards. The artery is then found lying upon the interosseous membrane, or upon the bone, according to the level at which it is exposed. The nerve is either superficial to, or on the outer side of the vessels. In the lower third of the leg, the outer border of the tendon of the tibialis anticus muscle is the best guide to the artery.

The *dorsal artery of the foot* is tied by means of an incision an inch and a half in length, placed midway between the tendons of the extensor proprius hallucis and extensor longus digitorum muscles, and terminating below at the posterior end of the first intermetatarsal space. On dividing the fascia, the artery is found passing beneath the innermost slip of the extensor brevis digitorum, and having the companion nerve generally to its outer side. The aponeurotic layer binding the vessels against the bone must also be cut through to bring them fully into view.

#### MORPHOLOGY OF THE ARTERIAL SYSTEM.

The first portions of the great arteries, viz., the pulmonary trunk and the ascending aorta, are to be regarded, so far as their development is concerned, as portions of the heart, being formed from the foetal aortic bulb. The latter gives origin on each side to a series of vascular arches, five, or it may be six, in number, which pass backwards in the wall of the foregut to join a longitudinal vessel—the primitive dorsal aorta. The relation of these arterial arches to the somatic and splanchnic arteries subsequently to be referred to is uncertain. The changes which the arches undergo in the course of farther development are fully explained in the section "Embryology" in Vol. I, and are indicated also in fig. 333, on p. 385 of this volume. They may be shortly stated as follows:—From the lowest arches are formed the pulmonary arteries, and on the left side also the ductus arteriosus. The fourth arch, with the common stem of this and the arches above, gives rise on the right side to the innominate artery and the beginning of the subclavian, and on the left side to the arch of the aorta. The elongated common stem of the upper three arches becomes the common carotid artery, the third arch forms the internal carotid artery, and the common stem of the first two arches furnishes the external carotid.

Of the branches of the external carotid artery, the superior thyroid is the artery of the median thyroid diverticulum, and therefore descends to the central part of the gland (the inferior thyroid artery from the subclavian being the vessel of the lateral thyroid diverticulum, and passing to the outer and lower part of the gland); the lingual passes into the

tongue developed in the concavity of the mandibular arch; and the facial and internal maxillary are respectively superficial and deep arteries extending into the foetal mandibular and maxillary processes. The posterior auricular artery, lying over the styloid process, is in the position of the second arch, and the occipital is probably an offset from the same; the origin of the occipital artery from the internal carotid, which is sometimes observed, may be explained as resulting from the persistence of the dorsal connection of the second arch.

The primitive dorsal aortæ become fused for the greater part of their extent into the single descending aorta, from which there are given off—1, a series of metameric somatic or parietal arteries on each side to the body-wall, 2, a smaller number of azygos splanchnic or visceral branches which pass forwards in the primitive mesentery to the alimentary canal, 3, a set of paired arteries to the suprarenal bodies, and the renal and genital glands, and 4, mediastinal and phrenic branches to the septa of the body-cavity.

1. *Somatic arteries.*—The typical arrangement of these vessels is seen in the upper aortic intercostal arteries, and less perfectly in the lower intercostals and the lumbar arteries. Each enters its body-segment with the corresponding spinal nerve, and like that divides on the side of the vertebra into a dorsal and a ventral branch. The *dorsal* branch passes backwards

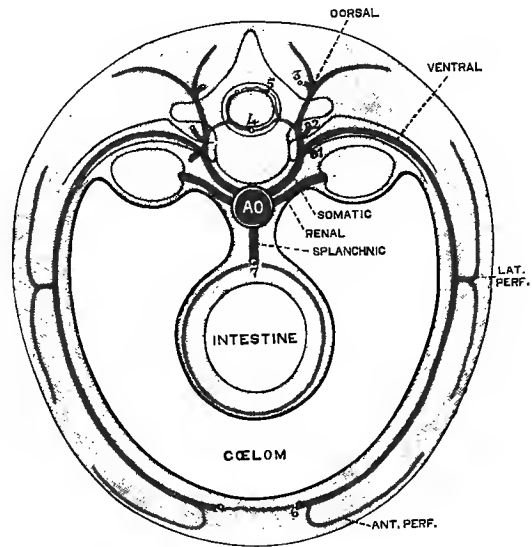
Fig. 397.—SCHEME OF THE TYPICAL ARRANGEMENT AND COMMUNICATIONS OF THE BRANCHES OF THE AORTA. (G. D. T.)

Longitudinal anastomoses: 1, pre-costal; 2, postcostal; 3, postvertebral; 4, anterior neural; 5, posterior neural; 6, ventral somatic; 7, dorsal splanchnic.

between the transverse processes of the vertebra, furnishes a *spinal* offset to the interior of the spinal canal, and is distributed to the dorsal muscles and integument. The *ventral* branch is continued in the intercostal space to the front of the body, and gives off in its course a *lateral perforating* offset with the lateral branch of the nerve: from such lateral branches the main arteries of the limbs are derived. At the fore part of the intercostal space an *anterior perforating* branch accompanies the termination of the nerve. The adjacent segmental arteries are

united by longitudinal anastomoses, which, although for the most part small, and not unfrequently wanting, in certain regions attain a greater development and give rise to trunks through which the blood-supply is furnished to the several structures of the part, the primitive origins being more or less completely obliterated. The chief of these are—1, the *precostal anastomosis* in front of the neck of the rib, 2, the *postcostal anastomosis* between the neck of the rib and the transverse process, 3, the *postvertebral anastomosis* between the dorsal branches behind the transverse process, 4 and 5, the single *anterior neural* and the paired *posterior neural anastomoses* formed by the spinal branches on the spinal cord, and 6, the *ventral somatic anastomosis* uniting the anterior ends of the ventral branches, and giving rise to the internal mammary and epigastric arteries.

In the neck, as a consequence of the withdrawal of the aortic trunk from this region with the descent of the heart and lower arches, the upper six segmental arteries, which were present in the early embryo, have disappeared, and the aortic connections of the last cervical and the upper two thoracic arteries are also obliterated. The seventh artery however persists, and its ventral division, becoming greatly developed, gives rise to the first part of the subclavian artery (with the exception of the small proximal portion of the artery of the right side formed from the fourth arch), the continuation of which, passing between the scaleni, is the lateral perforating branch, while the prolongation of the segmental vessel is represented by the portion of the internal mammary descending to the first rib-cartilage, where it passes into the ventral longitudinal anastomosis. The ascending cervical artery is formed from the precostal anastomoses of the suppressed arteries; and the vertebral trunk, which at its origin



is the dorsal branch of the seventh segmental artery, is thence to the transverse process of the atlas the series of postcostal anastomoses; the part of the last artery lying in the vertebral groove of the atlas is the spinal offset of the first segmental vessel, which enters the cranium, having first contributed its posterior spinal branch to the dorsal neural anastomosis, and joins its fellow in the basilar artery—a part of the ventral neural anastomosis. The ventral division of the eighth segmental artery is wanting, while its dorsal branch, continued by the postvertebral anastomoses, forms the deep cervical artery; and this together with the intercostal arteries of the first and second spaces arise from the subclavian (the seventh segmental artery) by means of the superior intercostal trunk, which is a precostal anastomosis.

The origin and morphological relations of the terminal branches of the aorta and of the arteries of the lower limbs are by no means clearly understood. The middle sacral artery (caudal aorta of the lower animals) being generally regarded as the continuation of the aortic trunk, the common and external iliac arteries would appear to be the ventral division of the artery of the fourth lumbar segment, of which the last lumbar artery is the dorsal branch only (Hochstetter). The femoral artery is the lateral perforating offset, and the continuation of the segmental vessel forms the first portion of the epigastric artery, which communicates through ventral anastomoses with the internal mammary and subclavian above, and the obturator below. The normal obturator artery may be looked upon as the ventral division of another segmental artery, and the gluteal and sciatic as lateral perforating branches, while the internal iliac is a precostal anastomosis by which they have acquired a secondary origin from the common iliac, and which is continued by the lateral sacral arteries. An obturator artery arising from the epigastric is a development of the ventral anastomosis.

An entirely different explanation is given by A. H. Young, who looks upon the common iliac and hypogastric arteries as the direct prolongations of the primitive aortæ, while the middle sacral is a new formation. From the primitive aorta the external iliac artery is given off as a segmental parietal vessel, while the internal iliac is a common stem for parietal and visceral arteries.

**Arteries of the limbs.**—It has already been seen that the segmental arteries of the body-wall follow closely in their course and branching the corresponding nerves, and the same is the case with the arteries of the limbs. As a rule the chief nerve-trunks are accompanied by an arterial canal, which may attain considerable development, so as to form a principal vessel, or may exist only as an anastomotic chain. Where there are differences in the nerves of the two limbs, therefore, correlated differences in the arteries may be expected. The large arteries may also be developed from different channels in the two cases, so that a main trunk in the one limb is only represented by a small vessel or an anastomotic connection in the other. In the neighbourhood of the large joints numerous anastomoses are formed between the different channels, and by the development of these it may happen that the chief arteries accompany different nerves in the several limb-segments. From these considerations it will be evident that the homologies of the arteries are mainly dependent upon the homologies that are recognized between the nerves of the limbs.

In comparing together the main arterial trunks of the two limbs, it will be observed that they show an important difference in their relation to the limb-girdle; the axillary artery enters the limb with the nervous trunks on the postaxial or caudal side of the shoulder-girdle, while the femoral artery runs on the preaxial or cephalic side of the hip-girdle in company with only a small part of the limb-nerves. From this it may be inferred that the two vessels are not strictly homologous. In the Sauropsida generally the main artery enters the hind limb on the caudal side of the pelvic girdle, in company with the sciatic nerve, and therefore corresponds more closely to the artery of the fore limb; and in the early mammalian embryo a similar condition exists, the sciatic artery being continued into the limb, while the femoral artery is small and does not extend beyond the thigh. Subsequently the latter artery grows more rapidly, and forming a connection with the primitive vessel near the knee becomes the main trunk, while the sciatic between the pelvis and the ham in great part disappears (Hochstetter). The rare cases in which the main artery of the limb is continued from the sciatic (p. 491) are instances of persistence of the primitive condition.

While the lower part of the brachial artery may therefore be regarded as represented in the popliteal, the place of division of the former corresponds to the point of origin of the lower internal articular branch of the latter, that branch being homologous to the radial recurrent artery, while the radial trunk itself is not farther represented in the leg. The remainder of the popliteal artery may accordingly be compared to the ulnar-interosseous trunk of the forearm, although from the difference in their relation to the pronator teres and popliteus muscles respectively it would appear that the correspondence of the two vessels is not complete.

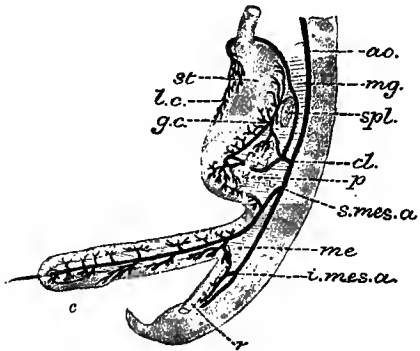
In the forearm the nerves of the ventral side of the limb form two trunks, the ulnar and median, each of which is accompanied by an artery—the ulnar proper and the *comes nervi mediani*, the latter being usually small, although in some cases it is enlarged and continued beneath the annular ligament into the palm. These two nerves are represented in the lower limb by one trunk—the posterior tibial, with which runs the artery of the same name. Inas-

much as the course of the posterior tibial nerve in the leg agrees closely with that of the median nerve in the forearm, it would seem probable that the posterior tibial and median arteries are homologous channels, and that the ulnar artery proper is not represented in the leg. When the posterior tibial nerve divides into the internal and external plantar, corresponding respectively to the median and ulnar nerves in the hand, the arterial channel also becomes double; the internal plantar artery then represents the occasional continuation of the median in the hand, while the external plantar artery with its arch reproduces the deep part of the ulnar artery and the deep palmar arch. The superficial palmar arch has no representative in the foot, and the digital arteries of the toes are furnished by branches homologous to the palmar interosseous arteries of the hand.

The peroneal artery is the obvious homologue of the anterior interosseous artery of the forearm, and the anterior tibial of the posterior interosseous. The continuation of the anterior tibial artery into the dorsal artery of the foot, the termination of which like that of the radial in the hand is an enlarged perforating artery of the first space, may be compared to a channel formed through the anastomotic network on the back of the wrist from the end of the posterior interosseous to the radial artery. The termination of the anterior interosseous artery and the anterior peroneal agree in entering the dorsal anastomosis; and the formation of two

Fig. 398.—THE ARTERIES OF THE STOMACH AND INTESTINE IN THE EMBRYO OF SIX WEEKS. (Toldt.)

*ao*, aorta; *cl*, coeliac axis, sending its branches forwards through *mg*, the mesogastrum to *st*, the stomach, where the splenic and hepatic arteries communicate along *gc*, the great curvature, and supply *spl*, the spleen, and *p*, the pancreas, while the coronary artery crosses to the right of the lower end of the oesophagus and then descends along *lc*, the small curvature; *s. mes. a.*, superior mesenteric artery passing through *me*, the mesentery to the primary intestinal loop; *i. mes. a.*, inferior mesenteric artery.



arches (tarsal and metatarsal) in the dorsal network of the foot in comparison with the single carpal arch at the wrist may be explained as resulting from the greater development of the tarsal region of the foot.

**2. Splanchnic arteries.**—It may be assumed that these were originally double in accordance with the primitive disposition of the aortic trunk from which they arise, and that the azygos stems have been formed either by the fusion of paired vessels, or more probably by the suppression of the arteries on one side. They comprise the small oesophageal branches of the aorta in the thorax, and the three large arteries, coeliac, superior mesenteric and inferior mesenteric, in the abdomen. In some of the lower vertebrates the arteries to the alimentary canal are more numerous, and the coeliac and mesenteric arteries may be regarded as trunks resulting from the union of several such branches. The primary offsets of these trunks, passing in the primitive mesentery towards the dorsal border of the alimentary canal, divide each into an ascending and a descending branch, which join the neighbouring branches in arches, thus giving rise to the *dorsal splanchnic anastomosis*. From the arches, of which there may be more than one series, offsets proceed to the wall of the canal on each side.

The coeliac axis is the artery of the abdominal portion of the foregut, and supplies also the glandular structures developed in connection therewith, viz., the liver, pancreas and spleen. Its three divisions probably represent as many primitive splanchnic arteries, all of which pass through the mesogastrum to the stomach, although their original disposition in relation to the peritoneum is much obscured by developmental modifications (see Vol. I, "Embryology, Development of the Alimentary Canal"). Of the three divisions, the highest and lowest, viz., the coronary and hepatic, agree closely in their type: they run to the extremities of the stomach, where they give off their ascending and descending branches, and are peculiar in then being prolonged over the original right side of the tube and through the small omentum (ventral mesogastrum) to the liver, forming at the same time along the small curvature of the stomach a *ventral splanchnic anastomosis*, which is not developed elsewhere on the canal. The ascending and descending portions of the coronary artery are respectively represented by the branches to the oesophagus and the fundus of the stomach; the hepatic branch is distinct in the fœtus, but is only occasionally well developed in the adult (p. 460); and the offset to the ventral anastomosis is so much enlarged as to form the continuation of the trunk. The primitive stem of the hepatic artery is the gastro-duodenal, which divides into its ascending, right gastro-epiploic, and descending, superior pancreatico-duodenal,

branches; the hepatic branch is greatly enlarged and usually furnishes almost the whole of the arterial supply to the liver; while its anastomotic or pyloric branch is but small. The splenic artery, which occupies an intermediate position, is also primitively gastric; its ascending division forms the *vasa brevia*, and its descending division the left gastro-epiploic artery, while the splenic and pancreatic branches are collateral offsets to the glands formed in the mesogastrium.

The superior mesenteric artery, developed from the embryonic vitelline or omphalo-mesenteric artery, is the artery of the midgut, and supplies the portion of the bowel formed from the primary intestinal loop. The inferior mesenteric artery is similarly the trunk for the supply of the hind gut. The dorsal anastomoses between the branches of these trunks are largely developed, and the number of successive arches that are formed is in direct relation to the length of the suspensory peritoneal fold and the consequent mobility of each region of the intestine.

3. The suprarenal, renal and spermatic arteries form a group intermediate in position between the parietal and visceral arteries, but more closely related to the former in accordance with the position in which the organs supplied by these vessels are developed. Originally more numerous, they have become reduced in number like the visceral arteries; and the occurrence of supernumerary renal arteries may be regarded as a reversion to the multiple, possibly a metameric condition. The uterine and vaginal arteries probably belong also to this group (Mackay).

4. The mediastinal and phrenic arteries are more closely allied to the splanchnic system of vessels, and the bronchial arteries may be referred to the same group.

(On this subject see W. J. Walsham, "Abnormal Origin and Distribution of the upper seven right Intercostal Arteries, with remarks," *Journ. Anat.*, xvi, 1882; W. His, "Anat. menschl. Embryonen," iii, 1885; A. Frozier, "Zur Entwicklungsgeschichte der Wirbelsäule," &c. (Segmental arteries of neck), *Arch. f. Anat.*, 1886; A. Macalister, "The Morphology of the Arterial System in Man," *Journ. Anat.*, xx, 1886; J. Yule Mackay, "The Arterial System of Vertebrates homologically considered," *Proc. Phil. Soc., Glasgow*, xviii, 1887, and in "Memoirs and Memoranda in Anatomy"; H. St. John Brooks, "Arterial Trunks indicating Archaic or Unusual Courses of Nerve-Trunks in the Limbs," *Roy. Acad. Med. Ireland*, Jan. 4, 1889; F. Hochstetter, "Ueber die ursprüngliche Hauptschlagader der hinteren Gliedmasse des Menschen und der Säugethiere, nebst Bemerkungen über die Entwicklung der Endäste der Aorta abdominalis," and "Ueber die Entwicklung der Art. vertebralis beim Kaninchen," &c., *Morph. Jahrb.*, xvi, 1890; A. H. Young, "On the Termination of the Mammalian Aorta, with observations on the Homologies of the Pelvic Arteries," in "Studies in Anatomy," the Owens College, 1891.)

## SYSTEMIC VEINS.

The systemic veins commence by small branches which receive the blood from the capillaries throughout the body, and unite to form larger vessels, which end at last by pouring their contents into the right auricle of the heart through two large venous trunks, the superior and inferior *venæ cavæ*. The blood from the walls of the heart itself is returned by the cardiac veins also to the right auricle.

The veins, however, which bring back the blood from the stomach, intestines, spleen, and pancreas, have an exceptional destination, not conveying the blood directly to the heart, but joining to form a single trunk—the portal vein, which again becomes ramified in the substance of the liver, and carries its blood to the capillaries of that organ. Thence the blood passes into the ultimate twigs of the hepatic veins, and is conveyed by these veins into the inferior vena cava. The veins thus passing to the liver constitute the *portal system*.

The anastomoses of veins are much larger and more numerous than those of arteries. The veins of the body generally consist of a subcutaneous and a deep set, which have very frequent communications with each other. In some parts of the body, chiefly in the limbs and at the surface, the veins are provided with valves, while in others no valves exist (see Vol. I, p. 368).

The systemic veins are naturally divisible into two groups: firstly, those from which the blood is carried to the heart by the superior vena cava, viz., the veins of the head and neck and upper limbs, together with those of the spine and a part of the walls of the thorax and abdomen, with which may be associated also the veins

of the heart ; and secondly, those from which the blood is carried to the heart by the inferior vena cava, viz., the veins of the lower limbs, the lower part of the trunk, and the abdominal viscera. (For a general representation of the venous system, see fig. 328, p. 376.)

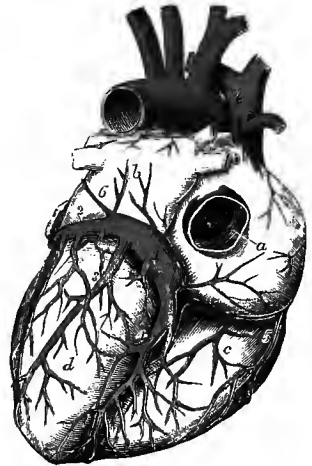
### VEINS OF THE HEART.

The greater number of the cardiac veins are collected into a large common trunk which pours its blood into the lower part of the right auricle, in the angle between the orifice of the inferior vena cava and the right auriculo-ventricular orifice. The terminal part of this trunk is somewhat dilated, and is named the coronary sinus. The veins leading into the sinus are named the left or great, the posterior, the middle, and the right or small cardiac veins. In addition to these, there are also the anterior and the smallest cardiac veins, which open separately into the right auricle. The veins of the heart are without valves, excepting at their terminations.

The **great cardiac** or **coronary vein** commences near the apex of the heart, and ascends, increasing gradually in size, along the anterior interventricular

Fig. 399.—THE HEART FROM BEHIND, TO SHOW THE CARDIAC VEINS. (Allen Thomson.)  $\frac{1}{2}$

*a*, placed on the right auricle, points to the Eustachian valve seen within the opening of the inferior vena cava ; *b*, left auricle ; *c*, right ventricle ; *d*, left ventricle ; *e*, superior vena cava ; *f*, arch of aorta ; 1, coronary sinus ; 2, great coronary vein, turning round the heart in the left auriculo-ventricular groove ; 3, posterior cardiac veins ; 4, middle cardiac vein ; the small coronary vein is seen joining the right end of the coronary sinus ; 5, one of the anterior cardiac veins passing directly into the right auricle ; 6, the oblique vein, proceeding downwards over the left auricle to join the coronary sinus.



groove, in company with the anterior branch of the left coronary artery. It then turns backwards, by the side of the posterior branch of the same artery, in the groove between the left auricle and ventricle, and, having gained the posterior surface of the heart, terminates in the left end of the coronary sinus. In the first part of its course it receives branches from the interventricular septum and from the anterior wall of both ventricles ; and as it passes backwards it is joined by descending branches from the left auricle, and by ascending branches from the ventricle, one of which, lying along the left margin of the heart, is of considerable size. A valve, generally of two segments, is placed over the opening of the vein in the coronary sinus.

The **posterior cardiac veins** are three or four in number, and ascend on the posterior surface of the left ventricle to open into the coronary sinus along its lower border. Sometimes one of these veins is much larger than the others.

The **middle cardiac vein**, of considerable size, commences at the apex of the heart, where it communicates with the radicles of the great coronary vein, and passes upwards in the posterior interventricular groove to join the right extremity of the coronary sinus. It receives branches from the interventricular septum, and from the posterior wall of both ventricles, but more particularly the right.

The **right** or **small coronary vein** collects blood from the hinder parts of the right auricular and ventricular walls, and passes transversely in the groove between the right auricle and ventricle to open into the right end of the coronary sinus. This small vein is often represented by two or three separate branches, and it is occasionally absent.

The **coronary sinus** is about an inch in length, and is placed at the back of the heart, in the groove between the left auricle and ventricle, where it is covered by the muscular fibres of the auricle. At its termination it opens into the right auricle, immediately in front of the inferior vena cava, and its orifice is covered by the Thebesian valve. The sinus is joined by the principal veins of the heart in the manner described above, and also at its left extremity by a small straight vein (*oblique vein* of Marshall) which runs downwards and inwards over the back of the left auricle. All the veins joining the sinus, except the small oblique vein which is often imperforate, are provided with more or less complete valves at their terminations.

The **anterior cardiac veins** are two or three small vessels running upwards on the front of the right ventricle, and one of larger size ascending along the right border of the heart, all of which open into the auricle immediately above the auriculo-ventricular groove. These veins have no valves.

The **smallest cardiac veins** (*venæ cordis minimæ*), very variable in number, are contained in the substance of the heart, and open into the right auricle, especially upon and in the neighbourhood of the interauricular septum, giving rise to some of the foramina Thebesii. Similar minute veins open into the left auricle, and according to L. Langer also into both ventricular cavities.

The coronary sinus, together with the small oblique vein, considered with reference to their foetal condition and certain abnormal conditions to which they are subject along with other neighbouring veins, may be looked upon rather as the persistent terminal parts of a typically distinct left superior vena cava (duct of Cuvier, with the left horn and transverse part of the sinus venosus), than as simply the main stem of the cardiac veins. The explanation of this will be found in the description of the development of these veins in Vol. I.

### SUPERIOR VENA CAVA.

The superior or descending vena cava conveys to the heart the blood which is returned from the head and neck, the upper limbs, and the walls of the thorax. It is formed by the union of the right and left innominate veins, behind the junction of the first costal cartilage of the right side with the sternum, and descends nearly vertically to the base of the heart, where it opens into the right auricle, opposite the third costal cartilage. It is about three inches long, and in its course it describes a slight curve, the convexity of which is directed to the right side. It has no valves.

At its commencement, the superior vena cava is placed on the right side of the innominate artery, and rests against the beginning of the right bronchus, being covered in front and externally by the pleura. The right phrenic nerve also lies along its outer side. About an inch and a half above its termination, it perforates the fibrous layer of the pericardium, the serous membrane being reflected over it and surrounding it except along its posterior surface. The lower part of the vein lies in front of the right division of the pulmonary artery and the upper right pulmonary vein, and the ascending aorta is to its inner side.

The superior vena cava receives small pericardial and mediastinal veins, and immediately above the place where it perforates the pericardium it is joined by the large azygos vein.

### INNOMINATE VEINS.

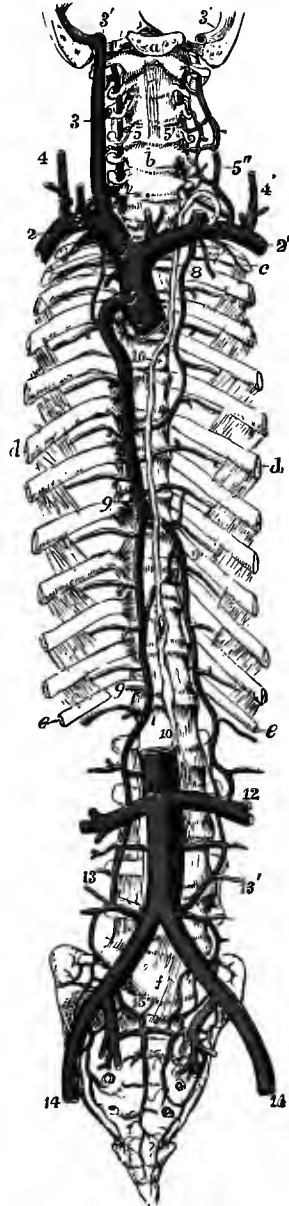
The innominate or brachio-cephalic veins, commencing on each side by the union of the subclavian and internal jugular veins behind the inner end of the clavicle, transmit the blood returning from the head and neck, the upper limbs, and a part of the thoracic wall. They end below by uniting to form the superior vena cava, beneath the junction of the first costal cartilage of the right side with the



sternum. The right vein is about an inch in length, and descends nearly vertically by the side of the commencement of the subclavian and the upper end of the innominate artery; externally it is covered by the right pleura and lung, the

FIG. 400.—SKETCH OF THE PRINCIPAL VENOUS TRUNKS, TOGETHER WITH THE THORACIC DUCT. (Allen Thomson.)  $\frac{1}{2}$

*a*, basilar process of occipital bone, through which and the temporal bones a transverse section has been made so as to lay open the jugular foramen on both sides; *b*, fifth cervical vertebra; *c*, first rib; *d*, the sixth; *e*, the twelfth; *f*, fifth lumbar vertebra; 1, superior vena cava divided at the place of its entrance into the right auricle; 2, right, 2', left subclavian vein; 3, right internal jugular vein; 3', 3', lower parts of the lateral sinuses of the dura mater; that of the right side shows at its junction with the jugular vein the bulb which lies in the jugular fossa of the temporal bone; 4, right, and 4', left external jugular vein; 5, right, and 5', left vertebral vein, being joined by 5'', the anterior vertebral vein, before entering (in this case) the subclavian vein; 6, placed on the left subclavian vein below the opening of the last, and of the thoracic duct; below *b*, the inferior thyroid veins; 7, 7', internal mammary veins; 8, the left superior intercostal vein, joining the left innominate, and anastomosing below with the left upper azygos vein; the right superior intercostal vein is seen joining the large azygos vein; 9, 9, 9, large azygos vein; 9', left lower azygos vein; 10, thoracic duct; 11, inferior vena cava, at the place of junction of the renal veins; 12, communication of the left lower azygos vein with the left renal vein; 13, 13', right and left ascending lumbar veins, continued upwards into the corresponding azygos veins; 14, 14', external iliac veins, which are joined higher up by the internal iliacs, to form the common iliac veins; 15, placed on the promontory of the sacrum, points on either side to the prolongation of the lower branches of the lumbar veins into the pelvis, and their union with sacral and other branches of the internal iliac veins.



phrenic nerve being interposed. The vein of the left side, nearly three times as long as the right, takes a course from left to right, at the same time inclining somewhat downwards: it crosses behind the upper part of the manubrium, being separated from the bone by the lower ends of the sternohyoid and sterno-thyroid muscles, and by the thymus gland or its remains; below it is the arch of the aorta, and behind it are the three large branches of the arch, as well as the left phrenic and pneumo-gastric nerves. The innominate veins have no valves.

**LATERAL TRIBUTARIES.**—Both innominate veins are joined by the vertebral, inferior thyroid and internal mammary veins; that of the left side also by the superior intercostal, and some small thymic, mediastinal and pericardial veins. There is also, opening into the angle of union of the internal jugular and subclavian veins, on the left side the thoracic duct, on the right side the right lymphatic duct.

The **vertebral vein** results from the union of a considerable offset from the intraspinal venous plexus, issuing above the neural arch of the atlas, with branches which proceed from the pericranium and the deep muscles lying behind the foramen magnum of the occipital, and which anastomose with the occipital,

with the commencement of the deep cervical, and with the posterior spinal veins. It passes downwards through the foramina in the transverse processes of the upper six cervical vertebræ, forming in this part of its course a close plexus around the artery of the same name ;<sup>1</sup> then inclining forwards, it descends under cover of the internal jugular vein, and across the subclavian artery, to open into the commencement of the innominate vein posteriorly, where its orifice is guarded by a single or double valve. The vertebral venous plexus receives branches from the neighbouring muscles, from the dorsal spinal veins of the neck, from the spinal canal through the intervertebral foramina, and from a plexus over the anterior surface of the cervical vertebræ ; and near its termination the trunk is joined by the anterior vertebral and deep cervical veins, as well as in many cases by a small vein from the first intercostal space, which accompanies the superior intercostal artery.

The *anterior vertebral vein* issues from the plexus over the cervical vertebræ, and passes downwards in company with the ascending cervical artery, receiving branches from the prevertebral and scaleni muscles, to join the lower end of the vertebral vein.

The *deep cervical vein* (posterior vertebral), a vessel of large size, commences in the suboccipital region, and descends between the complexus and semispinalis muscles to the lower part of the neck, where it turns forwards below the transverse process of the seventh cervical vertebra, to unite with the vertebral vein just before that enters the innominate trunk. It is joined by the occipital veins and by branches from the deep parts at the back of the neck, and it has numerous communications with the dorsal spinal veins.

**Varieties.**—The vertebral vein not unfrequently passes through the foramen in the transverse process of the seventh cervical vertebra, or sends a considerable offset through that foramen to join the deep cervical vein.

The **inferior thyroid veins** are of large size, and are formed by branches which emerge from the lateral lobes of the thyroid body, where they anastomose with the superior and middle thyroid veins. They form a plexus on the front of the trachea below the isthmus of the thyroid body, and then descend along that tube, under cover of the sterno-thyroid muscles, receiving on their way downwards œsophageal, inferior laryngeal and tracheal branches. The vein of the left side joins the left innominate trunk ; that of the right side either terminates in common with the foregoing, or it inclines somewhat outwards across the innominate artery, and opens into the angle of union of the two innominate veins, or less frequently into the lower end of the right innominate. There is also in some cases an additional median vein descending from the isthmus of the thyroid body.

The **internal mammary veins** are two in number on each side, and accompany the artery of the same name. They receive tributaries corresponding to the branches of the artery from the abdominal and thoracic walls and from the mediastinal space ; and at the upper part of the thorax the two veins join into a single trunk which terminates in the innominate vein, or on the right side frequently in the beginning of the superior vena cava.

The **superior intercostal vein** is a short vessel which receives the veins from two or three intercostal spaces below the first, and has a different termination on the two sides. The vein of the right side inclines down-

<sup>1</sup> C. Walther, "Recherches anatomiques sur les veines du rachis," Thèse, Paris, 1885 ; N. Rüdinger, "Ueber die Hirnslagadern und ihre Einschliessung in Knochencanälen," Arch. f. Anat., 1888 ; Trolard, "De l'appareil veineux des artères encéphaliques," Journ. de l'Anat., 1890. Trolard describes the vertebral vein as a single large vessel, which resembles a sinus of the dura mater, surrounding the artery except at its postero-internal third, and the lumen of which is to some extent irregularly divided into secondary channels and cellular spaces by septa and trabeculæ.

wards and enters the upper part of the large azygos vein; that of the left side usually passes forwards across the highest part of the arch of the aorta and joins the left innominate vein; it also communicates below with the commencement of the left upper azygos vein, and sometimes it passes entirely into this vessel.

**Varieties of the superior vena cava and innominate veins.**—A considerable number of instances are recorded in which the left innominate vein, being formed in the usual manner, does not cross the middle line to join the corresponding vessel of the right side, but is continued down in front of the arch of the aorta and the root of the left lung to the heart, where it receives the great cardiac vein and then inclines outwards in the usual position of the coronary sinus to open into the right auricle, thus giving rise to what has been termed a left superior vena cava. In some of these cases the right and left veins are connected by a cross branch of small size in the usual position of the left innominate vein. This condition is normal in many animals, and its occurrence in the human subject is due, as is fully explained in the description of the mode of development of the great veins, to the persistence of the communication between the left primitive jugular vein and duct of Cuvier in the foetus. A trace of this connection is frequently to be seen in the adult in the form of a small fibrous cord passing from the left superior intercostal vein as it crosses the aorta, within the vestigial fold of the pericardium, to the commencement of the oblique vein on the back of the left auricle (p. 353). In a few cases such a left superior vena cava has been found opening into the left auricle of the heart; and in two instances the coronary sinus has been observed terminating in a similar manner (Lindner, Jeffrey).

Five examples of a single left superior vena cava, without transposition of the viscera, have been met with, the right innominate vein crossing the middle line and joining the vessel of the left side to form a trunk which has a disposition similar to that of the left superior vena cava described above. In these cases the left duct of Cuvier has remained patent and undergone development, while the channel of the right side has become occluded.

Another form of persistence of the left duct of Cuvier has been met with by Gruber; in this the opening into the right auricle is occluded, and the principal veins of the heart terminate in a trunk which ascends to the left innominate vein (Virchow's Archiv, xcix).

#### VEINS OF THE HEAD AND NECK.

The blood returning from the head and neck flows on each side into two principal veins, the external and internal jugular. There are generally no valves in the veins of the head and neck, except at the lower ends of the external and internal jugular veins, near their junction with the subclavian, where valves are always present.

The superficial veins of the fore part of the head and the deep veins of the face converge and unite so as to form two principal trunks, the facial and temporo-maxillary veins. From the hinder part of the scalp the blood is collected by the posterior auricular and occipital veins.

The **facial vein** (anterior facial) lies obliquely along the side of the face, extending from the inner margin of the orbit downwards and outwards to the anterior border of the masseter muscle. Resting on the same plane as the facial artery, but being placed farther back, and taking a less tortuous course, it has very nearly the same relations to contiguous parts. It commences at the side of the nose by a vein termed angular, which collects blood from the forehead, the upper eyelid and the nose, and it is increased in size by the junction of numerous tributaries on its way downwards. Below the jaw it inclines backwards, covered by the cervical fascia and the platysma myoides, and unites below the digastric muscle with the anterior division of the temporo-maxillary vein to form a short trunk (*common facial vein*), which opens into the internal jugular about the level of the hyoid bone. From the facial vein near its ending a communicating branch generally runs downwards along the anterior border of the sterno-mastoid muscle to join the lower part of the anterior jugular vein.

**Tributaries.**—(a) The *frontal vein* is formed by branches which pass obliquely downwards and inwards from the roof of the skull and the forehead, maintaining

communications in their course with the anterior branches of the temporal vein. It descends vertically along the lower and inner part of the forehead, running parallel with the corresponding vessel of the opposite side, and beneath the inner end of the eyebrow it terminates in the angular vein. The right and left frontal veins communicate together by cross branches, and sometimes the two vessels are united for a short distance in a common trunk, which divides again below.

(b) The *supraorbital vein*, much smaller than the frontal, receives branches from the lower part of the forehead, from the eyebrow, and from the upper eyelid, and inclines inwards to join the termination of the frontal vein. It communicates externally with the temporal, and posteriorly with the ophthalmic vein.

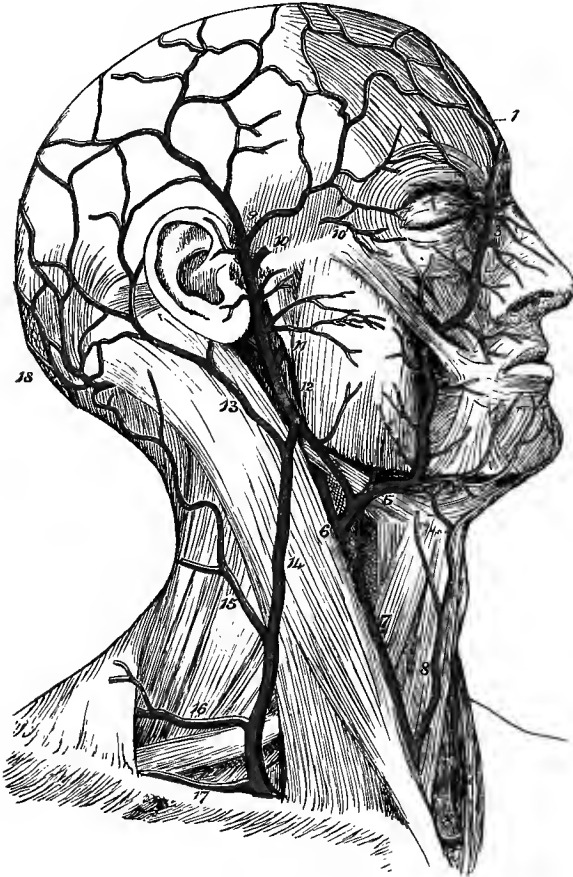

Fig. 401.—SUPERFICIAL VEINS OF THE HEAD AND NECK. (G. D. T.)  $\frac{1}{2}$

1, frontal vein ; 2, supra-orbital ; 3, angular vein, receiving superior palpebral and nasal branches ; 4, 4, facial vein on the face, receiving inferior palpebral, superior labial, parotid and masseteric branches ; + indicates the spot where it is joined by the deep facial vein ; 5, facial vein in the neck, being joined by submental, with inferior labial, glandular and inferior palatine branches ; 6, common facial vein, joining the internal jugular ; 7, communicating branch to 8, the anterior jugular ; 8', transverse branch connecting the two anterior jugular veins ; 9, superficial temporal, and 10, middle temporal, uniting to form the common temporal vein, which is receiving anterior auricular and transverse facial branches ; 10', orbital branch of middle temporal ; 11, internal maxillary vein ; 12, temporo-maxillary vein, the anterior division of which unites with the facial, while the posterior joins 13, the posterior auricular vein, to form 14, the external jugular ; 15, posterior external jugular ; 16, transverse cervical ; 17, suprascapular vein ; 18, occipital veins.

(c) The *angular vein*, formed by the junction

of the supraorbital and frontal veins, is perceptible beneath the skin as it runs obliquely downwards and outwards near the inner margin of the orbit, resting against the side of the nose at its root. It receives on its outer side one or two small *superior palpebral veins* from the upper eyelid, and anteriorly the *nasal veins*, which pass upwards to join it from the side and dorsum of the nose ; behind, it communicates freely with the commencement of the superior ophthalmic vein ; and internally, it is united to its fellow by the *transverse nasal vein*, which forms an arch over the bridge of the nose. On a level with the lower margin of the orbit it becomes continuous with the facial vein.

(d) Two or three *inferior palpebral veins* pass inwards and downwards from the lower eyelid and adjacent part of the cheek to join the facial vein below the orbit. A communication is formed between these branches and the infraorbital vein.

(e) The *superior labial vein* forms a close plexus in the substance of the orbicularis muscle in the upper lip and ascends to open into the facial vein on a level with the ala of the nose. From a similar plexus in the lower lip two or three vessels descend over the base of the inferior maxilla, and join the submental branch of the facial or the commencement of the anterior jugular vein.

(f) The *deep facial* or *anterior internal maxillary vein* is a vessel of considerable size, which passes from the pterygoid plexus downwards and forwards over the zygomatic surface of the superior maxilla to open into the facial vein below the malar bone.

(g) Small *buccal*, *masseteric*, and *parotid* branches also join the facial vein on its outer side.

(h) The *submental vein* commences below the chin, where it communicates with the anterior jugular vein, and passes backwards under cover of the base of the lower jaw, receiving branches from the muscles and the submaxillary gland, to join the facial vein.

(i) *Submaxillary* branches from the gland of that name join the facial vein either separately or in common with the submental vein.

(j) The *inferior palatine vein* returns the blood from a plexus surrounding the tonsil and from the soft palate; it passes downwards, being deeply seated by the side of the pharynx, to join one of the preceding, or terminate separately in the facial vein.

The **temporo-maxillary vein** (posterior facial) is a short trunk, often presenting a plexiform disposition, which is formed by the union of the temporal and internal maxillary veins opposite the neck of the lower jaw. It descends, embedded in the substance of the parotid gland, on the outer surface of the external carotid artery to near the angle of the jaw, where it divides into two parts, the one of which inclines forwards, passing either over or under the stylo-hyoid and digastric muscles, to join the facial vein, while the other is directed backwards across the border of the sterno-mastoid muscle to form with the posterior auricular the commencement of the external jugular vein.

The **temporal vein** is formed close to the zygoma by the union of two vessels which are known as the superficial and middle temporal veins. The *superficial temporal vein* takes its origin in branches which spread over the top and side of the head, communicating with one another, with the corresponding vessels of the opposite side, with the frontal vein anteriorly, and with the occipital and posterior auricular veins behind, so as to form a wide-meshed plexus in the subcutaneous tissue. Descending over the temporal fascia, the branches are collected into two vessels corresponding to, although not closely accompanying, the divisions of the artery, superficial to which they are placed; and these, joining in front of the ear, give rise to the superficial trunk. The *middle temporal vein* is derived from a plexus in the temporal fossa, from which the deep temporal veins (passing to the pterygoid plexus) also issue, and piercing the temporal fascia near the zygoma unites with the superficial vein. The middle temporal vein is joined by a considerable *orbital* branch, which, after receiving some *external palpebral veins* from the eyelids, and communicating with the supraorbital and facial veins, passes backwards with the artery of the same name between the layers of the temporal fascia. The *common temporal vein* descends over the base of the zygoma, and sinks beneath the parotid gland to form by its junction with the internal maxillary vein the temporo-maxillary trunk. Other tributaries of the temporal vein are the *anterior auricular veins* from the external ear; branches from a plexus which surrounds the articulation of the

lower jaw, and into which one or two small veins issuing from the tympanum by the fissure of Glaser pour their contents; *parotid* branches from the gland; and one or two *transverse facial veins* from the surface of the masseter muscle.

The **internal maxillary vein** is a short vessel, often double, which passes backwards from the pterygoid plexus in the zygomatic fossa, in company with the first part of the internal maxillary artery, and joins the temporal vein behind the ramus of the jaw. The **pterygoid plexus**, corresponding to the second and third parts of the internal maxillary artery, is a network of large veins covering both surfaces of the external pterygoid muscle, and extending also over the inner surface of

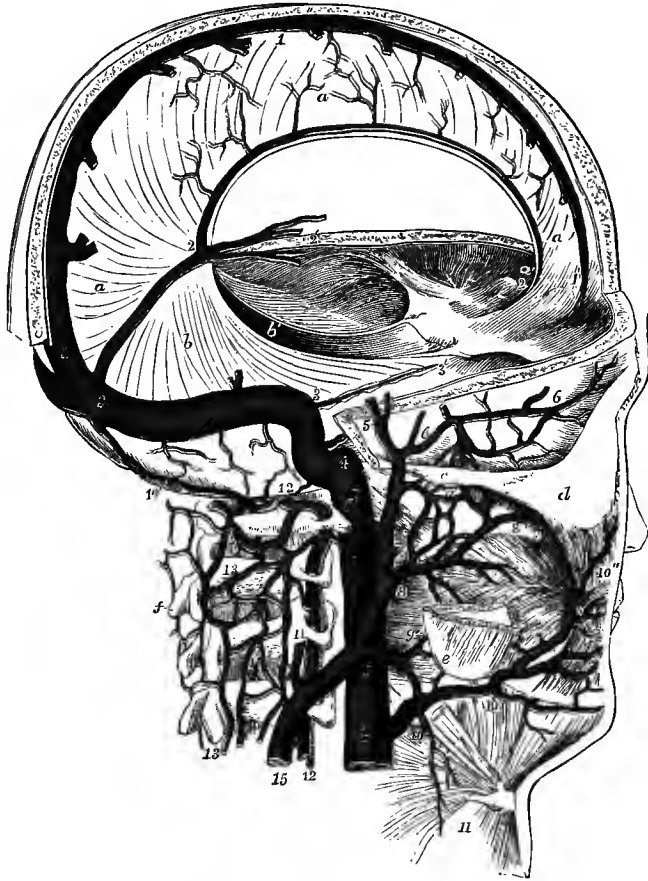


Fig. 402.—DIAGRAMMATIC VIEW OF THE SINUSES OF THE DURA MATER AND SOME OF THE DEEP VEINS OF THE HEAD AND NECK. (Allen Thomson.)  $\frac{1}{2}$

The greater part of the calvaria has been removed, but an arched strip has been left in the region of the superior longitudinal sinus. The occipital portion of the skull has been entirely removed so as to expose the lateral sinus and its termination in the internal jugular vein. *a, a*, falx cerebri; *b, b'*, tentorium cerebelli; *c*, zygoma; *d*, malar bone; *e*, angle of jaw; *f*, spinous process of axis; 1, superior longitudinal sinus; 2, inferior longitudinal sinus; 2, to 3, straight sinus; 2', veins of Galen; 3, lateral sinus, descending to 4, the commencement of the internal jugular vein; 3', superior petrosal sinus; 4, 4, internal jugular vein; 5, superficial temporal vein; 6, middle temporal; 8, internal maxillary joining the common temporal vein to form the temporo-maxillary trunk; 8', pterygoid plexus receiving the deep temporal veins; 9, anterior division of the temporo-maxillary trunk, joining the facial vein; 9', inferior palatine vein; 10, common facial; 10', submental; 10'', upper part of facial; 11, posterior auricular; 12, 12, vertebral; 13, 13, dorsal spinal veins; 14, occipital sinus communicating above the atlas with the posterior spinal plexus; 15, external jugular vein.

the internal pterygoid. It receives tributaries which are mostly companion veins of the branches of the internal maxillary artery. Thus, three or four *deep temporal veins* descend from the temporal muscle, and other branches come from the pterygoid and masseter muscles; a *posterior dental* or *alveolar* branch ascends from the surface of the upper jaw, and another of larger size, *inferior dental*, from the canal in the lower jaw; two *middle meningeal veins* accompany the artery of the same name; and lastly, *superior palatine*, *infraorbital*, and *spheno-palatine veins*, as well as a communicating branch from the inferior ophthalmic vein, also enter the plexus. The blood is conveyed from the plexus by the deep facial vein (p. 515) anteriorly, and posteriorly by the single or double internal maxillary vein.

The **posterior auricular vein**, of large size in comparison with the artery of the same name, collects the blood from the hinder part of the side of the head and from the cranial surface of the auricle; it descends over the mastoid process and the upper end of the sterno-mastoid muscle, to terminate in the external jugular vein.

The **occipital veins**, generally two or three in number, issue from the hindmost part of the venous network of the scalp, the most external being also connected in most cases with the lateral sinus within the skull by means of the emissary vein occupying the mastoid foramen (this vein sometimes joins a branch of the posterior auricular); descending over the occipital bone, they pass deeply between the muscles of the back of the neck, and empty themselves into the commencement of the deep cervical vein.

**External jugular vein.**—This vein commences near the angle of the jaw by the union of the posterior auricular and the posterior division of the temporo-maxillary veins. It descends with a nearly vertical course between the platysma myoides and the fascia, crossing the sterno-mastoid obliquely and gaining the posterior border of that muscle below. Near the clavicle it perforates the fascia, the margin of the opening being closely united to the wall of the vessel, and then inclines slightly inwards to terminate most frequently in the subclavian vein at the outer border or in front of the anterior scalenus muscle, but sometimes in the lower end of the internal jugular, or in the angle between the two large veins. It is joined below the middle of the neck by a considerable vein (*posterior external jugular*), which descends from the occipital region, collecting branches from the integument and the superficial muscles of the back of the neck, and near its termination by the *transverse cervical* and *suprascapular veins* from the shoulder, corresponding to the arteries of the same name, as well as usually by the anterior jugular vein from the fore part of the neck.

The external jugular vein has an imperfect valve close to its termination, and another, which however is generally sufficient to prevent regurgitation, about an inch and a half above the clavicle. There are also valves in the transverse cervical and suprascapular veins, either at or a short distance from their orifices.

The **anterior jugular vein** takes its origin in the submaxillary region by the union of branches, some of which proceed from the superficial structures of this part and form communications with the submental vein, while others descend from the lower lip and chin. The vessel runs down the front of the neck, being placed a variable distance from the middle line, and frequently being connected by one or more cross branches with the external jugular vein; near the inner end of the clavicle it perforates the fascia, and, after being joined in most cases by a communicating branch from the facial vein, is then directed outwards behind the origin of the sterno-mastoid muscle to open into the lower end of the external jugular vein, or sometimes directly into the subclavian vein. The lower parts of the two anterior jugular veins are generally united by a transverse branch contained in the interfascial space at the upper border of the sternum (p. 297).

**Varieties of the superficial veins of the head and neck.**—These veins are subject to many deviations from the arrangement above described. Thus, the relative size of the two divisions of the *temporo-maxillary vein* varies greatly, and it not unfrequently happens that one is very small or even absent, so that the trunk is continued mainly or wholly in one set of cases into the external jugular vein, in another set into the internal jugular through the common facial vein. The *facial vein* occasionally passes backwards over the sterno-mastoid muscle and joins the external jugular vein; or it may be continued downwards, by means of an enlargement of the normal communicating branch, into the anterior jugular vein. In those instances in which the temporo-maxillary vein passes entirely into the internal jugular, the *external jugular vein* is very small, being formed solely by the posterior auricular vein; and in such cases the posterior auricular vein may also join the temporo-maxillary trunk, so that the external jugular vein is then altogether wanting in the greater part of the neck. The lower part of the external jugular vein is occasionally connected with the cephalic vein of the arm by means of a branch passing downwards over the clavicle, and in rare cases the whole vein has been seen taking this course and dipping into the infraclavicular fossa to join the cephalic, or to open into the subclavian vein above the subclavius muscle. The *transverse cervical* and *suprascapular veins* not unfrequently open independently into the subclavian vein. The *anterior jugular vein* varies greatly in size, and the right and left veins are sometimes united into a single median vessel for a part of their length. As a rare occurrence the anterior jugular vein passes outwards in front of the sterno-mastoid muscle.

**Internal jugular vein.**—This vein, receiving the blood from the cranial cavity, is continuous at its upper extremity with the lateral sinus within the skull, and terminates inferiorly in the innominate vein. It commences in the large posterior compartment of the jugular foramen by a more or less marked dilatation which is termed the *sinus* or *bulb* of the internal jugular vein,<sup>1</sup> and then makes its appearance below the base of the skull, where it rests against the rectus capitis lateralis muscle, being placed close behind the internal carotid artery. Inclining gradually to the outer side of that vessel, it descends with a nearly straight course in the neck, and becoming considerably increased in size about the level of the hyoid bone by the junction of the common facial, as well as of several deep veins, it thence accompanies the common carotid artery to the back of the clavicle, under cover of which it unites at a right angle with the subclavian vein. The internal jugular vein lies on the outer side of, and frequently overlaps somewhat, the common carotid artery, and the two vessels, together with the pneumo-gastric nerve, are contained in the same sheath of the deep cervical fascia. Close to, or within an inch of, the lower end of the vein is placed a single or double valve, which is however generally insufficient to completely prevent regurgitation, especially on the left side, where it is not unfrequently absent.

*Lateral tributaries.*—(a) The *inferior petrosal sinus* leaves the skull by the anterior compartment of the jugular foramen, and opens immediately into the internal jugular vein.

(b) *Pharyngeal veins.*—These veins form a plexus which covers the outer surface of the pharynx, communicating above on the inner side of the internal pterygoid muscle with the pterygoid plexus, and collecting branches also from the soft palate, the Eustachian tube, and the prevertebral muscles. From this plexus two or three vessels descend, and open into the internal jugular or the common facial vein, either separately or in union with the lingual or superior thyroid veins.

(c) *Lingual veins.*—The blood conveyed to the tongue by the lingual artery is returned by means of—1, the *ranine vein*, the largest of the lingual veins, which commences below the tip of the tongue, and passes backwards at first beneath the mucous membrane, and afterwards across the outer surface of the hyo-glossus muscle, in company with the hypoglossal nerve, receiving branches from the substance of

<sup>1</sup> According to Langer the so-called *bulb* does not belong to the internal jugular vein, but is simply the convexity of a sharp bend formed by the lateral sinus just before it terminates in that vein ("Ueber den Ursprung der inneren Jugularvene," Wiener Sitzungsberichte, 1884).



the tongue, the surrounding muscles, the sublingual gland, and the mucous membrane of the floor of the mouth; 2, two *venæ comites* of small size which accompany the lingual artery; and 3, the *dorsal veins of the tongue*, which proceed from a plexus beneath the mucous membrane on the posterior third of that organ. These vessels are sometimes united in a short common trunk, but more frequently they open separately into the internal jugular or common facial vein.

(d) The *common facial vein* has already been described.

(e) The *superior thyroid vein* leaves the upper part of the thyroid body, after communicating freely with the other thyroid veins, and ascends to join the internal jugular or frequently the common facial vein. It receives branches from the surrounding muscles, and the *superior laryngeal* and *crico-thyroid veins*.

(f) The *middle thyroid vein* issues from the lateral lobe of the thyroid body, and crosses the common carotid artery to join the internal jugular vein on a level with, or a little below, the cricoid cartilage.

#### VENOUS CIRCULATION WITHIN THE CRANIUM.

The part of the venous system contained within the skull consists of veins properly so called, and of certain channels named *sinuses*, which receive the blood from those veins, and conduct it to the internal jugular veins. The sinuses alluded to are spaces left between the layers of the dura mater, the fibrous covering of the brain.

#### VEINS OF THE BRAIN.

The **veins of the cerebrum** are more numerous than, and for the most part run independently of, the arteries. They have very thin walls, and communicate freely together. They are divided into superficial, which ramify upon the surface of the hemispheres, and deep, which are placed within its ventricles and emerge by the transverse fissure. The former are again subdivided into superior and inferior.

The *superior cerebral veins*, ten to twelve on each side, run inwards over the upper surface of the large brain to the margin of the longitudinal fissure, where they are joined by branches which ascend on the mesial surface of the hemisphere, and then open into the superior longitudinal sinus. The anterior veins are small, and are directed transversely inwards; the middle and posterior are larger, pass obliquely forwards, and finally are embedded for a short distance in the wall of the sinus before opening into its cavity.

The *inferior cerebral veins* pass from the outer and lower surfaces of the hemisphere to the cavernous, superior petrosal and lateral sinuses. One of these vessels, known as the *middle cerebral* or *superficial Sylvian vein*, is of large size, and courses superficially along the fissure of Sylvius to end in the cavernous sinus: it collects branches from the frontal, parietal and temporal lobes. The *great anastomotic vein* of Trolard is formed by one of its tributaries on the surface of the parietal lobe, becoming continuous with a superior cerebral vein ascending to the superior longitudinal sinus. A similar *posterior anastomotic vein* extends from the middle cerebral downwards and backwards across the temporal lobe to the lateral sinus (Labbé).

The *deep cerebral veins* are collected into two trunks, which are known as the *veins of Galen*. These vessels begin close to the foramen of Monro, being formed on each side by the union of the *choroid vein*, which ascends tortuously along the margin of the velum interpositum from the inferior cornu of the lateral ventricle, returning the blood from the choroid plexus of that cavity, and the *vein of the corpus striatum*, which passes forwards in the groove between the corpus striatum and optic thalamus, being joined in its course by branches from both these bodies, and near its termination by veins from the septum lucidum and the anterior cornu of the ventricle. The

right and left veins of Galen run backwards, lying close together between the layers of the velum interpositum; and beneath the splenium of the corpus callosum they join into a short common trunk (*vena magna Galeni*), which ascends to reach the anterior extremity of the straight sinus, where it opens. They receive on their way branches from the inner side of the optic thalamus, from the choroid plexuses of the third ventricle, and from the corpus callosum, the large basilar vein, and small vessels from the corpora quadrigemina and pineal body, as well as a branch from the posterior cornu of the lateral ventricle. The common trunk is also joined by veins from the inner and lower surfaces of the occipital lobe, and from the hinder part of the callosal convolution of each hemisphere, and by some small veins from the upper surface of the cerebellum.

The *basilar vein* is formed opposite the anterior perforated space at the base of the cerebrum by the union of—1, a small *anterior cerebral vein*, which accompanies the artery of the same name below the genu of the corpus callosum, and communi-

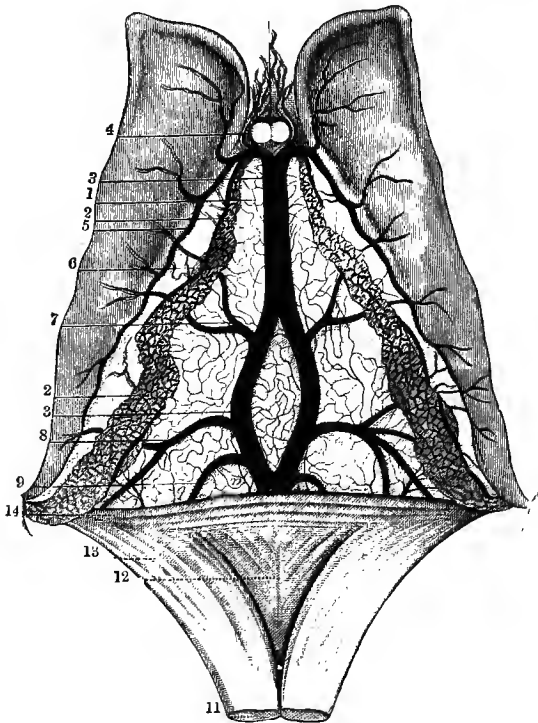


Fig. 403.—UPPER SURFACE OF THE VELUM INTERPOSITUM, WITH THE CHOROID PLEXUSES OF THE LATERAL VENTRICLES AND THE VEINS OF GALEN. (From Sappey after Vicq-d'Azyr.)

1, fore part of velum interpositum; 2, choroid plexus; 3, 3, left vein of Galen; 4, veins from the corpus callosum and septum lucidum; 5, vein of corpus striatum; 6, choroid vein; 7, vein from optic thalamus; 8, vein from the inferior cornu, and 9, vein from the posterior cornu of the lateral ventricle; 11, 12, 13, fornix, divided anteriorly and turned backwards; 14, splenium of corpus callosum.

cates with the vein of the opposite side; 2, the *deep Sylvian vein*, which lies in the lower part of the fissure of Sylvius, communicating freely with the middle cerebral vein, and collecting branches from the insula and adjacent parts of the frontal and temporal lobes; and 3, the *inferior striate veins*, which descend from

the corpus striatum through the anterior perforated space. It passes backwards round the crus cerebri, receiving in its course branches from the parts in the interpeduncular space, from the midbrain, from the uncinatè convolution, and from the inferior cornu of the lateral ventricle; and it ends by opening into the vein of Galen just before that vessel unites with its fellow.

The **veins of the cerebellum** are disposed in two sets. The *superior cerebellar veins* are directed partly upwards and inwards to the straight sinus and the *vena magna Galeni*, partly outwards to the superior petrosal and lateral sinuses. The *inferior cerebellar veins*, together with the veins from the medulla oblongata and pons, enter the inferior petrosal, lateral and occipital sinuses.

**Varieties.**—The veins of the cerebrum are very variable in their arrangement, a condition which may be explained by the number and size of their communications. The *middle cerebral vein* may open into the sphenoparietal or superior petrosal sinus, or into the beginning of the basilar vein. The *veins of Galen* often terminate independently in the straight sinus, without uniting into a "vena magna." In one instance they ascended, one on the inner surface of each cerebral hemisphere, to the superior longitudinal sinus (Testut). The *anterior cerebral vein* is sometimes wanting. The *basilar vein* may enter the vena magna Galeni or the straight sinus.

(Trolard, "Recherches sur l'anatomie du système veineux de l'encéphale et du crâne," Thèse, 1868, and in Arch. gén. de Méd., 1870; C. Labbé, "Note sur la circulation veineuse du cerveau," &c., Arch. de Physiol., 1879; J. Symington, "On the Valvular Arrangements in connection with the Cranial Venous Circulation," Brit. Med. Journ., 1882; Browning, "The Veins of the Brain and its Envelopes," Brooklyn, 1884; G. Sperino, "Circolazione venosa del capo," Torino, 1884; E. Hédon, "Étude anatomique sur la circulation veineuse de l'encéphale," Thèse, 1888, and in Internat. Monatschr. f. Anat., 1889.)

#### VENOUS SINUSES OF THE CRANIUM.

The sinuses are channels contained within the substance of the dura mater, and lined by a delicate membrane which is continuous with the internal coat of the veins. They admit of a division into two groups, viz., a supero-posterior group, lodged almost entirely in the processes of the dura mater, and an infero-anterior group, situated in the base of the skull. To the former belong the superior longitudinal, the inferior longitudinal, the straight, the lateral, and the occipital sinuses: the latter includes the cavernous, the circular, the superior and inferior petrosal, and the basilar sinuses.

The **superior longitudinal sinus** (fig. 402, 1) commences at the crista galli, where it sometimes (constantly in the child) has a communication with the veins of the nasal cavity through the foramen cæcum, and extends backwards in the upper border of the falx cerebri, occupying the median groove on the inner surface of the calvaria, and increasing gradually in size as it proceeds. In form it is three-sided, and its cavity is bridged across by several fibrous bands, the *chordæ Willisii*. Connected with the sinus on each side is a series of irregular cavities in the dura mater, the *lacunæ laterales* of Key and Retzius, into which the Pacchionian bodies of the arachnoid project from below, while their thin upper wall lines the corresponding depressions of the calvaria. Internally they are continued into the sinus by comparatively narrow apertures or canals, and externally each usually receives a branch of the meningeal veins. They vary in number and size, and increase in extent with advancing years: the largest are found in the region of the vertex, where they may be more than an inch in length. The sinus receives the superior cerebral veins, which often communicate with the lacunæ as they traverse the dura mater. It also communicates in many cases with the veins of the scalp, by means of an emissary vein which passes through the parietal foramen. As it descends on the occipital bone the superior longitudinal sinus usually deviates a little from the middle line, and inclines to one side (more frequently the right) of the internal occipital protuberance, where it becomes somewhat enlarged and bends sharply round at a right angle to be continued into the corresponding lateral sinus. This dilatation is lodged in a well-marked depression on the occipital bone, and constitutes what is termed the *torcular Herophili* or the *confluence of the sinuses*. From it a cross branch of variable size proceeds over the front of the occipital protuberance to a similar bend formed by the straight sinus passing into the lateral sinus of the opposite side.

The **inferior longitudinal sinus** (fig. 402, 2) is very small, and has so much of a cylindrical form that it is sometimes named *inferior longitudinal vein*. It passes backwards in the posterior half or more of the lower border of the falx cerebri, and

opens into the straight sinus on reaching the anterior margin of the tentorium. It receives branches from the falx, and sometimes from the mesial surface of the hemispheres.

The **straight sinus** (s. tentorii) (fig. 402, 2—3), continuous with the foregoing, is also joined at its commencement by the vena magna Galeni from the interior of the cerebrum. It runs backwards and downwards, along the junction of the falx cerebri and the tentorium, to the internal occipital protuberance, where it is connected by a cross branch, generally of small size, with the torcular Herophili, but is mainly continued into the lateral sinus of the opposite side to that into which the superior longitudinal sinus is prolonged. The straight sinus receives in its course some superior cerebellar veins, and small branches from the tentorium.

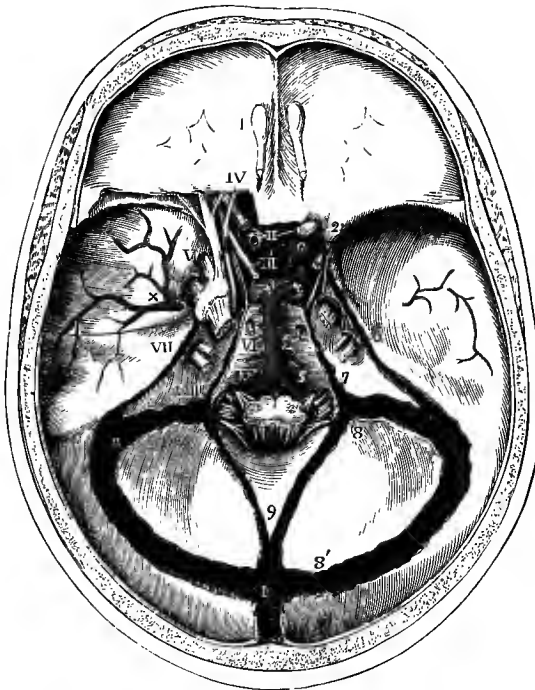


Fig. 404. — INTERNAL VIEW OF THE BASE OF THE SKULL, SHOWING THE SINUSES OF THE DURA MATER, &c. (Allen Thomson.)  $\frac{1}{2}$

The tentorium has been removed, and also a small portion of the roof of the orbit posteriorly on the left side, so as to bring into view the sinuses, which are laid open, the arteries at the base of the skull, and the trunks of the cranial nerves.

I, olfactory bulb; II, optic nerves; III, third nerve; IV, trochlear nerve; V, placed opposite to the middle of the three divisions of the fifth nerve; VI, sixth nerve; VII, facial and auditory nerves; VIII, placed opposite to the glosso-pharyngeal, pneumo-gastric and spinal accessory nerves; IX, hypoglossal nerve; 1, right internal carotid artery as it makes its turn within the cavernous sinus in the groove of the sphenoid bone; 2, its ophthalmic branch; 3, right and left posterior cerebral arteries, from the former of which the posterior communicating artery is seen passing forwards to the internal carotid; 4, basilar artery; 5, vertebral arteries giving off the anterior spinal; x, middle menin-

geal artery spreading upwards from the foramen spinosum; 6, superior petrosal sinus; 7, inferior petrosal sinus; 8, termination of the lateral sinus at the jugular foramen; 8', commencement of the lateral sinus; 9, occipital sinus, in this case of large size; 10, torcular Herophili, and below that number in the figure, the superior longitudinal sinus.

The **lateral sinuses** commence at the internal occipital protuberance, and terminate on each side at the jugular foramen in the bulb of the internal jugular vein. The sinuses of the two sides generally differ in size, the one into which the superior longitudinal sinus is prolonged being much larger than that of the opposite side, which is formed by a continuation of the straight sinus. Each sinus passes outwards in the corresponding lateral groove of the occipital bone, forming an arch with its convexity upwards,<sup>1</sup> and being lodged in the attached margin of the tentorium, to the posterior inferior angle of the parietal bone, then curves downwards in the groove of the mastoid portion of the temporal bone, and finally turns

<sup>1</sup> A. E. Birmingham, Dublin Journal of Medical Science, February, 1891.

forwards over the jugular process of the occipital bone to the posterior compartment of the jugular foramen. It is joined by veins from the posterior part of the cerebrum, from both surfaces of the cerebellum, and from the diploe, as well as, at the point where it turns downwards from the tentorium, by the superior petrosal sinus. Emissary veins passing through the mastoid and posterior condylar foramina connect the lateral sinus with the veins of the exterior of the head.

The **occipital sinus** is a small vessel, generally single, but sometimes double, which is contained in the falx cerebelli. Above, it opens into the torcular Herophili; below, it communicates with the posterior spinal veins, and is usually continued forwards on one or both sides of the foramen magnum to join the lower end of the lateral sinus. It receives one or two small veins from the cerebellum.

The **cavernous sinuses**, placed one on each side of the body of the sphenoid bone, and extending from the inner end of the sphenoidal fissure to the apex of the petrous part of the temporal bone, are of considerable size and of very irregular form. Their cavity is traversed by numerous interlacing filaments, which give rise to a structure resembling that of cavernous tissue, and from this circumstance they derive their name. Enclosed in the outer wall of each are the third, the fourth and the ophthalmic and superior maxillary divisions of the fifth nerves as they pass forwards to the sphenoidal fissure and foramen rotundum; and in the cavity of the sinus, covered only by its thin lining membrane, are the internal carotid artery, the sixth nerve and a plexus of the sympathetic. Each sinus receives the ophthalmic veins anteriorly, and communicates internally by means of the intercavernous sinuses with the corresponding vessel of the opposite side, while posteriorly it discharges its blood into the petrosal sinuses. It is also joined by some inferior cerebral veins, and by a small vessel named the *spheno-parietal sinus* (Breschet), which, after receiving a branch from the dura mater and communicating with the middle meningeal veins, runs inwards on the under surface of the small wing of the sphenoid bone.

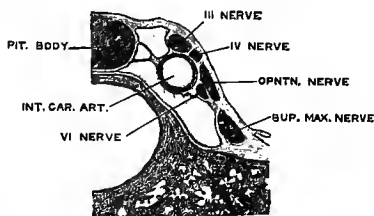


Fig. 405—TRANSVERSE SECTION OF THE CAVERNOUS SINUS. (Langer.)

The **circular sinus** is the name given to a venous ring surrounding the pituitary body in the sella turcica, and formed by two transverse vessels (*anterior and posterior intercavernous sinuses*) which connect together the right and left cavernous sinuses. Either of these transverse branches may however be wanting, but the anterior, which is usually the larger, is the more constant. On the other hand, there is often an additional vessel passing across below the pituitary body.

The **superior petrosal sinus** is a narrow canal running in the groove along the upper margin of the petrous part of the temporal bone. Commencing at the back part of the cavernous sinus, it is directed outwards and backwards in the attached margin of the tentorium cerebelli, and ends in the lateral sinus as this turns downwards in the groove on the mastoid part of the temporal bone. It is joined by some inferior cerebral and superior cerebellar veins, as well as by small branches from the tympanum, which issue by the petro-squamous fissure.

The **inferior petrosal sinus**, much shorter and wider than the superior, passes from the cavernous sinus downwards and outwards in the groove between the lower margin of the petrous bone and the basilar process of the occipital bone. It passes through the anterior compartment of the jugular foramen and opens immediately into the upper end of the internal jugular vein. The inferior petrosal sinus receives some inferior cerebellar veins, and the *auditory veins* from the internal ear.

The **transverse or basilar sinus**, or **basilar plexus**, is a venous network

excavated in the dura mater over the basilar process of the occipital bone, opening into the inferior petrosal sinus on each side, and into the anterior spinal veins below.

**Varieties of the sinuses.**—The disposition of the sinuses around the *torcular Herophili* is subject to considerable variation. It occasionally happens that the lower part of the superior longitudinal sinus is placed in the middle line, and then the straight sinus opens into the front, while the lateral sinuses spring from the sides, of the torcular, so that a true confluence of the sinuses is formed. In other instances the connecting branch between the torcular and the straight sinus is of large size, and conveys blood from the superior longitudinal sinus, which then empties itself equally into both lateral sinuses. In either of the foregoing arrangements, the right and left lateral sinuses are of equal size, a condition, however, which is of comparatively unfrequent occurrence. A great diminution, or even absence, of one lateral sinus has been met with, the vessel of the opposite side being much enlarged.

The *inferior longitudinal sinus* is very inconstant, and according to some anatomists is only exceptionally present.

The *occipital sinus* is sometimes wanting; or it may be of large size and form a groove on the occipital bone, by the side of the foramen magnum, as it passes forwards to the jugular foramen (fig. 404).

The *cavernous sinus* is represented in the child by a venous plexus in the dura mater, which, by enlargement and fusion of its channels, is converted into the sinus of the adult with its characteristic structure. In old age the trabeculæ diminish, and the cavity becomes simpler. The *basilar plexus* shows similar variations with age. (Langer, "Der Sinus cavernosus der harten Hirnhaut," Wiener Sitzungsberichte, 1885.)

The *spheno-parietal sinus* is often wanting. On the other hand it may be of large size and receive the termination of the middle cerebral vein. It sometimes joins the ophthalmic vein at the sphenoidal fissure.

An additional *petro-squamous sinus* is sometimes present, lying in a small groove along the junction of the petrous and squamous portions of the temporal bone, and opening behind into the lateral sinus. In rare cases the petro-squamous sinus is found passing through an aperture (*foramen jugulare spurium*) in the squamous part of the temporal bone, between the orifice of the external auditory meatus and the glenoid cavity, and then joining the temporal vein, thus resembling the arrangement in the dog and many other animals, in which a similar vessel forms the principal outlet for the intracranial blood. In the human subject also, at an early period of foetal life, the lateral sinus is continued forwards in this course, and opens into the primitive (afterwards the external) jugular vein, and the occurrence of a petro-squamous sinus is due to the persistence of this channel, which usually becomes obliterated after the development of the internal jugular vein. (On the varieties of the sinuses, see J. F. Knott, Journ. Anat., xvi, 27; C. Labbé, Arch. de Physiol., 1883; G. Sperino, *op. cit.*, p. 521.)

#### OPHTHALMIC VEINS.

The ophthalmic veins are two in number, and collect the blood from the parts within the orbit. They are of relatively large size, have a markedly flexuous course, and their branches form numerous plexiform communications.

The **superior ophthalmic vein**, much the larger, commences near the root of the nose by a wide communication with the angular vein, and is also joined, usually near its origin, by another communicating branch from the supraorbital vein. It passes backwards in company with the ophthalmic artery, crossing the optic nerve from within outwards, and gains the inner end of the sphenoidal fissure, where it opens into the fore part of the cavernous sinus. It is joined in its course by *anterior* and *posterior ethmoidal*, *muscular* and *lacrimal* branches, and near its termination by the *central vein of the retina*, all of which correspond generally to the arteries of the same name. The veins from the eyeball are called anterior and posterior ciliary. The *anterior ciliary veins* are small and accompany the corresponding arteries; perforating the sclerotic coat close to the cornea, they join the muscular branches of the ophthalmic veins. The *posterior ciliary veins*, of larger size, are four or five in number, emerge from the eyeball about midway between the cornea and the entrance of the optic nerve, and end partly in the superior, partly in the inferior ophthalmic vein.

The **inferior ophthalmic vein** is formed by the union of the lower posterior

ciliary veins with some branches from the muscles, and passes backwards near the floor of the orbit to open also into the cavernous sinus, either separately or, more frequently, in common with the superior ophthalmic vein. It sends a communicating branch downwards through the sphenomaxillary fissure to the pterygoid plexus, and sometimes this offset forms the chief or sole termination of the vein.

(M. Gurwitsch, "Ueber die Anastomosen zwischen den Gesichts- und Orbitalvenen," Arch. f. Ophthalmol., xxix, 1883; A. F. Festal, "Recherches anatomiques sur les veines de l'orbite," &c., Thèse, Paris, 1887.)

## VEINS OF THE DIPLOE.

The veins of the diploe of the cranial bones are only to be seen after the pericranium is detached, and the external table of the skull carefully removed by means of a file. Lodged in canals hollowed in the substance of the bones, their branches form an irregular network,

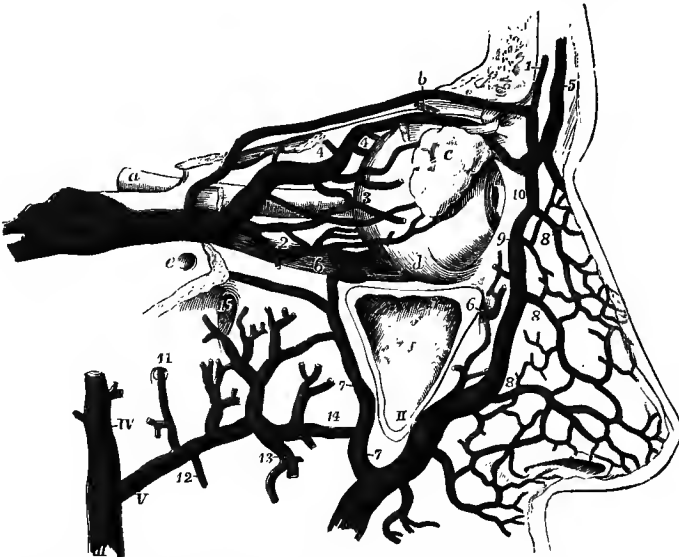

Fig. 406.—SKETCH OF THE OPHTHALMIC VEINS, SHOWING THEIR DISTRIBUTION AND COMMUNICATIONS WITH OTHER VEINS (altered from Hirschfeld and Levcillé). (Allen Thomson.)

The orbit is opened from the outer side and the dissection is similar to that for displaying the ophthalmic artery (fig. 345, p. 410): *a*, optic nerve; *b*, superior oblique muscle, divided a little way behind its pulley; *c*, lachrymal gland lying upon the eyeball; *d*, inferior oblique muscle; *e*, foramen rotundum; *f*, maxillary antrum, opened externally: I, cavernous sinus, being joined by the common trunk of the ophthalmic veins; 1, supraorbital vein, joining the angular below and communicating behind (in this case by a long branch) with the superior ophthalmic vein; 2, inferior ophthalmic vein; 3, posterior ciliary veins; 4, 4, anterior and posterior ethmoidal branches, joining the superior ophthalmic vein; 5, frontal vein; 6, in front of the antrum, infraorbital vein; 6, in the orbit, communication of the inferior ophthalmic vein with the pterygoid plexus; 11, facial vein; 7, deep facial from the pterygoid plexus; 8, 8, 8, nasal branches; 9, 10, angular vein; III, temporo-maxillary trunk, formed by the union of IV, the temporal and V, the internal maxillary veins; 11, meningeal branch; 12, inferior dental; 13, 14, muscular, alveolar and communicating branches; 15, placed in the sphenomaxillary fossa above the sphenopalatine vein; only a few branches of the pterygoid plexus are represented.

from which a few larger vessels issue. These are directed downwards at different parts of the cranium, and terminate, partly in the veins on the outer surface of the bones, and partly in the sinuses of the interior of the skull. They are very variable in their arrangement. According to Breschet there are four such veins in each half of the cranium, viz., a frontal, two temporal, and an occipital.

The *frontal* is small, and issues by an aperture at the supraorbital notch to join the supraorbital vein. There is often only one frontal vein present.

The *temporal* are distinguished as anterior and posterior. The *anterior* is contained chiefly in the frontal bone, but may extend also into the parietal; it opens externally into a deep temporal vein, through an aperture in the great wing of the sphenoid, and internally into one of the meningeal veins or the sphenoparietal sinus. The *posterior* ramifies in the parietal bone, and passes through an aperture at the lower and hinder angle of that bone, or through the mastoid foramen, to the lateral sinus.

The *occipital* is the largest of all, and opens either externally into the occipital vein, or internally into the torcular Herophili or the lateral sinus. Its ramifications are confined especially to the occipital bone.

In the young subject these veins are very small, and they become much larger in old age.

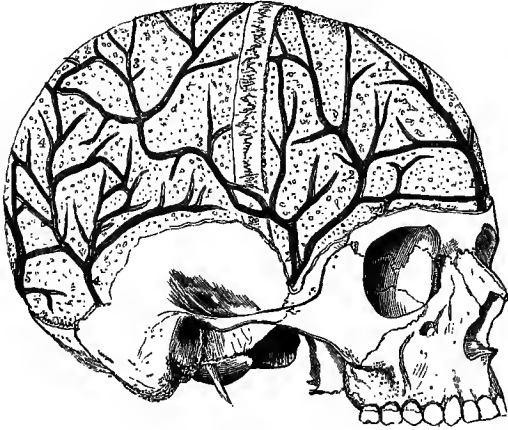


Fig. 407.—VEINS OF THE DIPLOE OF THE CRANIAL BONES. (Breschet.)  $\frac{1}{3}$

The external table has been removed from the greater part of the calvaria so as to expose the diploë and the veins, which have been injected: 1, a single frontal vein; 2, 3, anterior temporal vein; 4, posterior temporal; 5, occipital vein of the diploë.

#### EMISSARY VEINS.

The emissary veins are vessels which pass through apertures in the wall of the cranium and establish communications between the sinuses and the veins of the exterior of the skull. They vary much in size in different individuals, and some of them are not

always present. The following vessels may be included in this group, viz. :—

(a) The *mastoid emissary* is the largest and most constant of these veins; it passes through the mastoid foramen between the lateral sinus and the outermost occipital, or less frequently the posterior auricular vein.

(b) The *parietal emissary*, occupying the parietal foramen and connecting the superior longitudinal sinus with the veins of the scalp, is usually of small size, and is frequently wanting on one or both sides.

(c) The *condylar emissary* is also inconstant; it passes from the lateral sinus through the posterior condylar foramen to the beginning of the vertebral vein.

(d) A minute *occipital emissary* is sometimes present, passing from the torcular Herophili, through a foramen which opens on the external occipital protuberance, to one of the occipital veins.

(e) One or two considerable veins descend from the cavernous sinus through the foramen ovale, as well as small ones through the fibrous tissue in the foramen lacerum, to the pterygoid and pharyngeal plexuses. There is frequently another vein passing through a foramen of Vesalius (p. 47).

(f) A small *carotid plexus*, prolonged from the cavernous sinus, accompanies the internal carotid artery in the carotid canal, and opens below into the internal jugular vein.

(g) A venous ring surrounds the hypoglossal nerve in the anterior condylar foramen, and communicates internally with the occipital sinus and intraspinal veins, externally with the vertebral vein and the plexus on the front of the spine.

#### VEINS OF THE UPPER LIMB.

The veins of the upper limb are divisible into two sets, the superficial, which are placed between the fascia and the skin, and the deep, which accompany the arteries. The superficial veins are much larger than the deep, and take a greater share in returning the blood, especially from the distal portion of the limb. Both sets are provided with valves, and these are more numerous in the deep than in the subcutaneous veins. Valves are constantly present at the entrance of branches into the main vessels.



## SUPERFICIAL VEINS OF THE UPPER LIMB.

The two principal cutaneous veins of the forearm, the radial and the posterior ulnar, commence on the dorsum of the hand by a plexus into which the branches from both surfaces of the fingers empty themselves. Two smaller veins, the median

Fig. 408.—THE SUPERFICIAL VEINS OF THE UPPER LIMB, FROM BEFORE (the arrangement of the veins of the hand after Braune.) (G. D. T.)  $\frac{1}{4}$

1, cephalic vein; 2, basilic; 3, radial; 4, median-cephalic; 5, median, receiving a large branch from the outer side of the wrist, and being joined near its division by the deep median vein; 6, median-basilic; 7, anterior ulnar; 8, posterior ulnar vein.

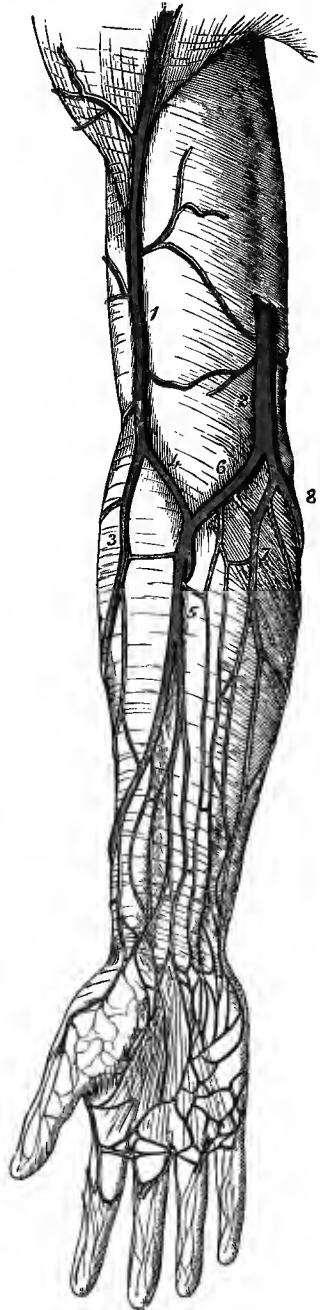
and the anterior ulnar, ascend on the front of the forearm; and at the bend of the elbow all these vessels become connected so as to give rise to two trunks, the basilic and cephalic veins, which are continued up the arm.

The **radial vein** takes origin from the outer part of the plexus on the back of the hand, and is also joined at the upper end of the first interosseous space by a communicating branch of considerable size from the venæ comites of the deep palmar arch. It ascends along the outer border of the forearm, receiving numerous branches in its course, and at the bend of the elbow, in the hollow on the outer side of the biceps muscle, it unites with the median-cephalic division of the median vein to form the cephalic vein.

The **posterior ulnar vein** commences in the inner part of the dorsal plexus of the hand, and also receives a communicating branch issuing behind the abductor minimi digiti muscle from the deep veins of the palm. It proceeds along the posterior aspect of the ulnar border of the limb, lying on the surface of the flexor carpi ulnaris muscle, and just below (occasionally above) the internal condyle of the humerus turns forwards to join the median-basilic division of the median vein, thus giving rise to the basilic vein.

The **anterior ulnar vein**, much smaller than the posterior, ascends along the inner part of the front of the forearm, and at the bend of the elbow either joins the posterior ulnar or opens separately into the median-basilic vein.

The **median vein** is generally of small size, and results from the union of two or three vessels which pass upwards from a fine plexus in the palm of the hand, receiving other branches in the forearm and communicating freely on



either side with the radial and ulnar veins; but not unfrequently it is large and forms the principal outlet of the dorsal plexus of the hand on the outer side, in which case the radial vein is proportionally reduced in size. It ascends to the hollow in front of the elbow, and there terminates by dividing into the median-basilic and median-cephalic veins, which diverge upwards from each other, lying one on each side of the prominent tendon of the biceps muscle. Close to its bifurcation this vessel receives a short wide branch, the *deep median vein*, which pierces the fascia, and forms a communication between it and the deep veins accompanying the arteries.

The **median-basilic vein**, usually the larger of the two divisions of the median, is directed inwards to join the commencement of the basilic vein. It passes in front of the brachial artery, from which it is separated by the semilunar fascia of the

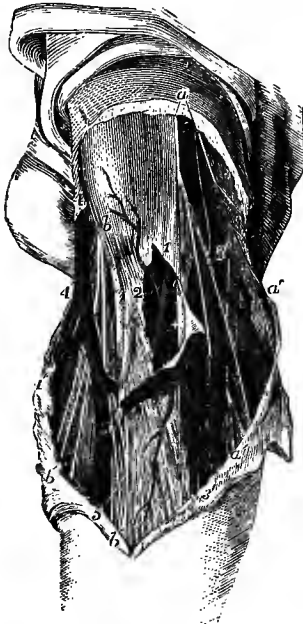

Fig. 409.—THE SUPERFICIAL VEINS AT THE BEND OF THE ELBOW. (R. Quain.)  $\frac{1}{2}$

The full description of this figure will be found at p. 437. At 1, the fascia is opened in front of the brachial artery and its accompanying veins; the inner vena comes has been divided, the outer, marked 2, is entire; +, median nerve; 3, basilic vein; 3', 3', ulnar veins; 4, cephalic vein; 4', radial vein; 5, 5, median vein; 5 to 4', median-cephalic; 5 to 3', median-basilic.

biceps, and it is crossed by branches of the internal cutaneous nerve.

The **median-cephalic vein** inclines outwards in the hollow between the biceps and the supinator longus muscles, passing in front of the musculocutaneous nerve, and joins the radial to form the cephalic vein.

The **basilic vein**, the largest of the veins of the arm, ascends in the groove on the inner side of the biceps muscle, lying internal to the situation of the brachial artery; it perforates the fascia somewhat below the middle of the arm, and is continued upwards into the axillary vein.

The **cephalic vein** is directed upwards in the groove along the outer border of the biceps muscle, and then between the pectoralis major and the deltoid; finally dipping in between the last two muscles, it crosses the first part of the axillary artery, and opens into the axillary vein between the pectoralis minor and subclavius muscles.

**Varieties.**—The superficial veins of the forearm are subject to great variation, both in the disposition and size of their trunks, and in their arrangement at the bend of the elbow. The *radial vein* may be very small or even absent, and in such cases the *cephalic vein* may also be wanting, the branches from the outer side of the forearm being collected into the median vein, which is continued directly into the median-basilic. It occasionally happens that the *anterior ulnar vein* is larger than the posterior. The *median-basilic vein* is not unfrequently double.

The *cephalic vein* sometimes passes up over the clavicle and terminates in the external jugular vein; or these two vessels may be united by a communicating branch (*jugulo-cephalic*) in this situation. In two cases this communicating branch has been seen to perforate the bone (Allen Thomson). The cephalic vein is occasionally found passing backwards between the subclavius muscle and the clavicle to join the lower end of the subclavian vein.

## DEEP VEINS OF THE UPPER LIMB.

The brachial artery and its various branches in the arm, forearm and hand, are each accompanied by two veins, named *venæ comites*. These companion veins lie one on each side of the corresponding artery, and are connected with each other at intervals by short cross branches, which in some places closely surround the artery. Their distribution so nearly corresponds with that of the arteries, that they need not be more particularly described.

The **brachial veins**, or *venæ comites* of the brachial artery, terminate near the lower margin of the subscapularis muscle by joining the axillary vein; not unfrequently, however, the inner one unites with the basilic vein soon after that vessel passes beneath the fascia.

Between the several veins of the upper limb numerous communications exist in their whole course. Thus, those which lie beneath the integument are freely

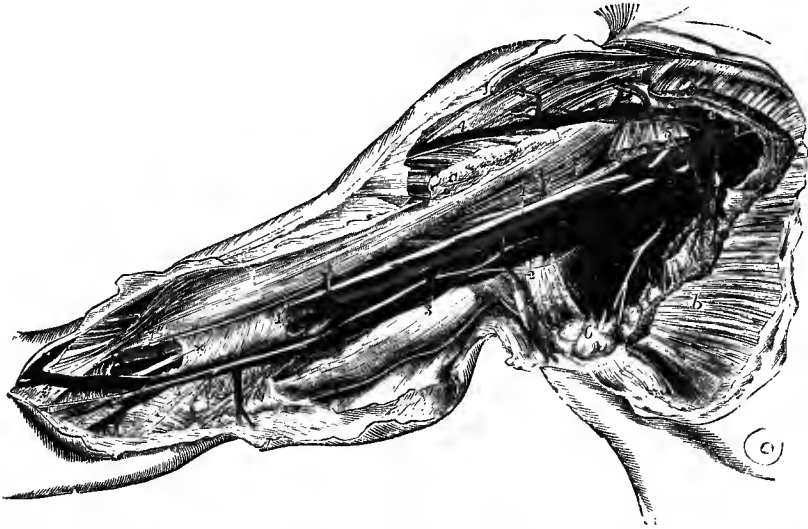


Fig. 410.—THE BLOOD-VESSELS OF THE AXILLA AND ARM FROM THE INNER SIDE. (R. Quain.)  $\frac{1}{2}$

The detailed description of this figure will be found at p. 436. The following numbers indicate the principal veins:—2, 2, axillary vein; 3, 3, basilic vein; 3', median-basilic; 4, 4', cephalic vein; 6, alar thoracic and subscapular; 7, one of the brachial veins.

connected to each other by cross branches in the hand and forearm. Not only are the veins in each pair of *venæ comites* united by short transverse vessels crossing the artery which they accompany, but also those accompanying different arteries have frequent connections with each other. Lastly, the subcutaneous and the deep veins communicate freely, especially in the neighbourhood of the joints. This general anastomosis ensures the continuance of the circulation during muscular action in the frequent and varied motions of the limb.

The **axillary vein** is of large size and collects all the blood returning from the upper limb. It is formed by the continuation upwards of the basilic vein of the arm, and extends, like the corresponding artery, from the lower border of the *teres major* muscle to the outer margin of the first rib. It is placed on the inner side of the axillary artery and has similar relations to the surrounding muscles.

*Lateral tributaries.*—The axillary vein receives in its course the several veins corresponding to the branches of the axillary artery, viz., the two *circumflexæ*, *sub-*

*scapular, long thoracic, alar thoracic, acromio-thoracic* (opening in common with the cephalic vein) and the *superior thoracic veins*; at the lower border of the subscapularis muscle it is joined by one or both of the brachial venæ comites, and near its termination by the cephalic vein.

The **subclavian vein** is the continuation of the axillary, and extends from the outer margin of the first rib to the inner border of the anterior scalenus muscle, where it terminates by uniting with the internal jugular to form the innominate vein. It crosses over the first rib and behind the clavicle, being placed at a lower level and therefore pursuing a less arched course than the artery, from which it is separated by the anterior scalenus muscle and the phrenic nerve. The subclavian vein is joined, usually close to the outer border of the anterior scalenus, by the external jugular vein, and it has constantly a pair of valves placed immediately outside the entrance of the latter vessel.

The wall of the subclavian vein adheres closely to the fascial sheath by which it is invested, and this being intimately connected in front with the costo-coracoid membrane and the back of the clavicle (p. 208), the vessel becomes expanded when the shoulder is carried forwards. Hence care should be taken in operations about the root of the neck or the shoulder in order to avoid the danger of air being drawn into the circulation by movements of the limb.

**Varieties.**—The subclavian vein is occasionally placed at a higher level than usual as it curves inwards, rising above the clavicle into the neck, and overlapping the subclavian artery. It has also been seen in rare cases passing between the subclavius muscle and the clavicle (Luschka), lying with the artery behind the anterior scalenus, changing places with the artery, or, lastly, dividing into two parts, which were placed, one in front of, the other behind, the anterior scalenus (Luschka). It often receives separately the anterior jugular, the supra-scapular, or the transverse cervical vein; occasionally the cephalic vein. Other unusual tributaries that have been met with are the brachial venæ comites (W. Krause), and on the left side a bronchial vein (M. J. Weber).

#### AZYGOS VEINS.

The azygos veins are longitudinal vessels resting against the thoracic portion of the spinal column, and formed by the union of the veins corresponding to the arteries of the intercostal spaces. In the lower part of the thorax the two veins of opposite sides are disposed symmetrically, but higher up the blood gathered from most of the veins of the left side is poured into the trunk on the right, which becomes enlarged and unsymmetrical, and has on that account received the name of large or right azygos, while the united vessels from the corresponding parts on the left side constitute the small or left azygos veins.

The **right or large azygos vein** (vena azygos major) commences in the abdomen, generally by an anastomotic vessel (*ascending lumbar vein*) which connects together the several lumbar veins, and establishes a communication below, either directly or indirectly, with the common iliac vein. It is also joined in many cases by a branch which opens distally into the inferior vena cava, or into the renal vein; and occasionally it takes its origin solely in this way. Passing from the abdomen into the thorax through the aortic opening in the diaphragm, or to the outer side of that opening through the fibres of the right crus, the azygos vein ascends on the bodies of the dorsal vertebræ to the level of the fifth rib, where it arches forwards over the root of the right lung, and then opens into the superior vena cava, immediately above the point at which that vessel perforates the pericardium. When passing through the opening in the diaphragm, this vein is accompanied by the thoracic duct, both being situated on the right side of the aorta. In the thorax, maintaining the same position with respect to the duct and the aorta, it passes in front of the intercostal arteries, and is covered by the pleura. It receives the intercostal veins of the right

side, with the exception of that from the first space, the upper two or three of these vessels being united into a short common trunk which is known as the *superior intercostal vein* (p. 512), and which opens into the commencement of the arch of the

Fig. 411.—SKETCH OF THE PRINCIPAL SYSTEMIC VENOUS TRUNKS, SHOWING THE AZYGOS VEINS. (Allen Thomson.)  $\frac{1}{2}$

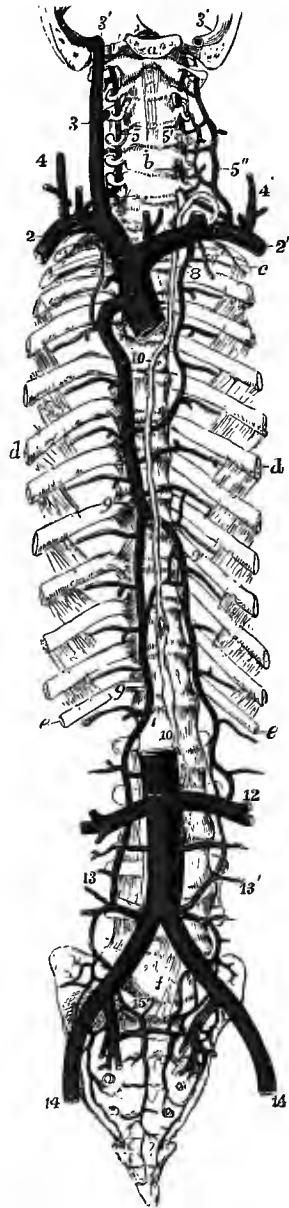
For the detailed description of this figure see p. 511. The following indications relate to the accompanying part of the text: 8, left superior intercostal vein, continued below into the left upper azygos vein; the superior intercostal vein of the right side is seen passing downwards into the large azygos vein; 9, 9, 9, large azygos vein; 9', left lower azygos vein; 10, thoracic duct; 11, inferior vena cava; 12, union of a branch of the left lower azygos with the left renal vein; 13, 13', right and left ascending lumbar veins, continued upwards into the corresponding azygos veins; 15, union of lumbar, ilio-lumbar, and sacral veins.

azygos vein. It is also joined by the left azygos veins, by the right bronchial vein, and by several small cesophageal, pericardial, and posterior mediastinal veins.

The **left lower or small azygos vein** (v. hemiazygos) commences as the ascending lumbar vein of the left side, and in most cases has also a communication with the corresponding renal vein,<sup>1</sup> seldom with the suprarenal or spermatic. It enters the thorax through the left crus of the diaphragm and ascends upon the spine, in front of the lower intercostal arteries, to the level (most frequently) of the ninth dorsal vertebra, where it crosses to the right behind the aorta and opens into the large azygos vein. It receives the intercostal veins from the lower three or four spaces of the left side, and some small branches from the mediastinum.

The **left upper azygos vein** (v. hemiazygos accessoria) is formed by the union of the veins from four or five intercostal spaces, generally from the fourth to the seventh or eighth inclusive, and it receives also some mediastinal branches and the left bronchial vein. It communicates above with the superior intercostal vein, and below it opens into the large azygos vein, either separately or in common with the left lower azygos vein.

The *intercostal veins* are single vessels lying in the intercostal spaces above the arteries, which they follow closely in their ramifications. They are joined by large posterior branches, collecting blood from the muscles of the back, the dorsal spinal plexus and the spinal canal, and by small twigs from the bodies of the vertebræ, before terminating in the superior intercostal or azygos veins. The vein from the



<sup>1</sup> Lejars found the left azygos vein communicating with the renal in 88 per cent. ("Les voies de sûreté de la veine rénale," Bull. Soc. Anat., Paris, 1888).

first space passes forwards in company with the superior intercostal artery, and opens into the innominate vein or one of its branches, most frequently the vertebral.

The *bronchial veins* are of small size and return only a portion of the blood conveyed to the lungs by the bronchial arteries. They are formed by the union of branches from the larger bronchial tubes, as well as from the other structures of the lung, and issue at the hilum of that organ, where they receive other twigs from the lower part of the trachea and from a fine plexus in the posterior mediastinum. The vein of the right side opens into the large azygos vein near its termination; that of the opposite side ends in the left upper azygos vein. The minute veins from the smaller bronchial tubes, and some of those from the larger ones, terminate in the pulmonary veins, as do also several branches from the mediastinal plexus (Zucker-kandl).

As the azygos veins communicate below with the inferior vena cava or some of the branches of that vessel, while they terminate above in the superior cava, they form a supplementary channel by which blood can be conveyed from the lower part of the body to the heart in cases of obstruction of the inferior trunk. There is generally a valve, most frequently consisting of two segments, in the arch or at the upper end of the ascending portion of the large azygos vein, but in the majority of cases it is not sufficient to close the vessel completely. In rare instances only is a valve present in the left lower azygos vein at or near its termination. The intercostal veins have valves near their openings into the azygos veins.<sup>1</sup>

**Varieties.**—The azygos veins of the left side present many varieties both in the number of intercostal veins which each receives, and in the manner in which they are connected with the large azygos vein. Two or three of the middle intercostal veins of the left side frequently unite into a short intermediate trunk, which passes directly into the large azygos vein; or the left upper azygos vein may be absent, the intercostal veins which usually form that vessel being continued across the spine and opening independently into the main stem. The left superior intercostal and upper azygos veins are sometimes represented by a single vessel, which may join either the corresponding innominate vein above, or the large azygos vein below. Occasionally all the intercostal veins of the left side are collected into a longitudinal trunk which terminates in the left innominate vein, the arrangement corresponding to that on the right side; and, on the other hand, instances are sometimes met with in which there is only a single azygos vein ascending on the front of the spine and receiving the intercostal veins of both sides. Transposition of the azygos veins is recorded by Gruber, the larger vessel being placed on the left side, receiving the smaller right veins, and then arching forwards over the root of the left lung to open into the left end of the coronary sinus of the heart, thus resembling the condition which is normal in the sheep and some other animals. The foregoing varieties are readily explained by reference to the mode of development of these vessels (see Vol. I).

In several cases the inferior vena cava has been seen continued into the azygos vein, which is then of course extremely large (see varieties of the inferior cava); and the spermatic vein or, on the left side, the renal and suprarenal veins have also been observed terminating in the same manner.

#### VEINS OF THE SPINE.

The veins of the spine form plexuses extending along the whole length of the column, and may be divided into the following sets: 1, the dorsal, placed deeply in the vertebral grooves; 2, the veins of the bodies of the vertebræ; 3, the anterior longitudinal, lying within the canal at the back of the bodies of the vertebræ; 4, the posterior longitudinal, also situated within the canal, along the fore part of the arches of the vertebræ; and 5, the veins of the spinal cord. There are likewise branches of communication, some of which unite the several sets with one another, while others bring them into connection with the general venous system. The veins of the spine have no valves.

The **dorsal spinal veins** are derived from the muscles and integument of the

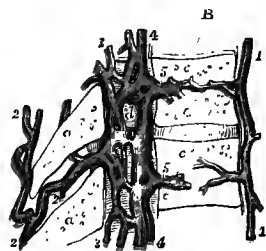
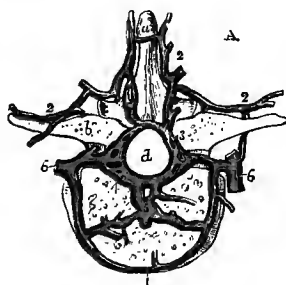
<sup>1</sup> W. Braune, "Ueber die Intercostalvenen des menschl. Körpers," Ber. d. kgl. sächs. Gesellsch., 1883.

back, and form a plexus over the arches of the vertebræ. The largest tributaries pass forwards by the side of the interspinous ligaments, proceeding in many cases from a median longitudinal vessel placed over the spinous processes of several vertebræ. Offsets from the plexus perforate the ligamenta subflava to join the posterior longitudinal veins within the spinal canal; and at the outer part of the vertebral groove other veins are given off, which pass forwards between the transverse processes and open into the posterior branches of the intercostal and lumbar veins, or in the neck, where the plexus is most developed, into the vertebral vein.

The **veins of the bodies of the vertebræ** are comparatively large vessels contained in the canals within these bones, the arteries which accompany them being very small. They anastomose on the front of the vertebræ with the veins in that situation; and the trunk of each, having reached the spinal canal through the single or double foramen on the posterior surface of the body of the vertebra, opens into the corresponding transverse branch uniting the anterior longitudinal veins.

Fig. 412, A and B.—HORIZONTAL AND SAGITTAL SECTIONS OF LOWER DORSAL VERTEBRÆ, SHOWING THE EXTERNAL AND INTERNAL VEINS OF THE SPINE. (Breschet.)  $\frac{2}{3}$

*a*, spinous process; *b*, transverse process; *c*, body; *d*, spinal canal; 1, external veins of the body; 2, dorsal spinal veins, communicating with the internal and forming a plexus over the laminae and processes; 3, posterior, and 4, anterior internal plexus of veins of the spinal canal; 5, internal veins of the body joining the anterior spinal veins; 6, posterior branches of the intercostal veins.



The **anterior longitudinal spinal veins** are two large plexiform vessels which extend the whole length of the spinal canal, lying behind the bodies of the vertebræ, one along each edge of the posterior common ligament. These vessels are dilated opposite the bodies of the vertebræ, where the right and left veins are connected by large transverse branches placed between the posterior common ligament and the bones, and constricted over each intervertebral disc, at which point an offset is sent outwards through the corresponding intervertebral foramen. Superiorly, the anterior spinal veins, having given off a large offset above the atlas to form the beginning of the vertebral vein, communicate with the basilar sinus through the foramen magnum, and form, with the posterior spinal veins and the lower end of the occipital sinus, a venous ring in the substance of the dura mater round that opening.

The **posterior longitudinal spinal veins**, also two in number, are contained in the loose tissue between the dura mater and the posterior wall of the spinal canal. They are often much broken up in parts of their course, and they communicate with one another by numerous cross branches on the anterior surface of the arches of the vertebræ, with the dorsal spinal veins by branches perforating the ligamenta subflava, and with the occipital sinus by branches which ascend through the foramen magnum. From the plexus thus formed offsets pass outwards to the intervertebral foramina, where they join the similar branches given off by the anterior longitudinal veins, and form a plexus around the issuing nerve.<sup>1</sup>

The **veins of the spinal cord** are of small size and run with a tortuous course in the substance of the pia mater, where they form a network with elongated

<sup>1</sup> C. Walther, *op. cit.* on p. 512.

meshes. They are larger below than above, and on the posterior than on the anterior surface of the cord. One considerable trunk lies beneath the anterior spinal artery over the anterior median fissure of the cord, and another more or less regular vessel, or anastomotic chain, is found on each side immediately behind the anterior nerve-roots. On the posterior surface there is also a median longitudinal vein, which is largest and most constant in the cervical and lumbo-sacral regions. These vessels communicate with the veins of the spinal canal by means of branches which are more numerous than the medullary arteries, and which accompany the nerve-roots to the intervertebral foramina; and at the upper end they are prolonged to the bulb, where they join the veins of the pons and cerebellum, and give offsets to the sinuses around the foramen magnum.<sup>1</sup>

From a consideration of the connection and arrangement of the different parts of these complex veins, it would appear that the main currents of the blood flow through them horizontally in the rings that are formed by the transverse branches between the longitudinal veins, and the offsets proceeding from the latter to the intervertebral foramina. The veins issuing from the spinal canal open, according to the region in which they are placed, into the vertebral veins, into the posterior branches of the intercostal and lumbar veins, and into the lateral sacral veins.

#### INFERIOR VENA CAVA.

The inferior or ascending vena cava returns the blood from the lower limbs and abdomen. It begins at the junction of the two common iliac veins in front of the right half of the fifth lumbar vertebra, and thence ascends along the right side of the aorta, being covered by the duodenum, pancreas, and lower end of the portal vein, to the posterior surface of the liver; there it becomes embedded in a deep groove, not unfrequently a canal, in that organ, and inclines forwards to reach its opening in the tendon of the diaphragm, to the margin of which the wall of the vessel is firmly united. After perforating the diaphragm, it is enclosed for a very short distance in a fold of the serous layer of the pericardium, and then terminates by entering the right auricle of the heart, about the level of the disc between the eighth and ninth dorsal vertebræ. A semilunar valve, known as the *valve of Eustachius*, is situated over its entrance into the auricle, but this, as explained in the description of the heart, is only the vestige of a fœtal structure, variable in size, and without influence in preventing reflux of the blood.

TRIBUTARIES.—Besides the common iliac veins, the inferior vena cava receives the following:—

1. The **lumbar veins** (fig. 411, p. 531) correspond in number with the arteries of the same name. They are formed by the junction of *anterior* branches from the wall of the abdomen, where they communicate with the epigastric and other neighbouring veins, and *posterior* branches, of larger size, which receive tributaries from the muscles of the back, the dorsal spinal plexus, and the spinal canal. Passing forwards upon the bodies of the vertebræ, beneath the psoas muscle, and on the left side also behind the aorta, they terminate by opening into the back of the inferior vena cava. Two of the vessels, either of the same or of opposite sides, may join together into a single trunk before their termination. The lumbar veins of each side communicate with one another by means of branches which cross in front of the transverse processes, and in this way a longitudinal vessel is formed, called the *ascending lumbar vein*, which connects together more or less completely the lateral sacral, ilio-lumbar, common iliac, and lumbar veins, and is continued upwards into the corresponding azygos vein.

<sup>1</sup> See A. Adamkiewicz and H. Kadyi, *opp. cit.* on p. 421.



2. The **spermatic veins** (in the male) proceed upwards from the testicle and epididymis, and form in the spermatic cord a thick plexus of convoluted vessels known as the *spermatic* or *pampiniform plexus*. Passing through the inguinal canal into the abdomen, in company with the spermatic artery, the branches from this plexus join into two or three veins, and these again unite into a single vessel which ascends beneath the peritoneum, on the surface of the psoas muscle, and opens on the right side into the vena cava, on the left into the renal vein. The spermatic veins sometimes bifurcate before their termination, and in this case one branch may enter the vena cava, the other the renal vein.

The spermatic veins receive small branches from the ureter and the abdominal wall; and the left, which is usually larger than the right, is joined also by one or two *colico-spermatic veins* from the descending colon.<sup>1</sup>

In the female the **ovarian veins** have the same general course as the ovarian arteries; they form a plexus near the ovary (*ovarian* or *pampiniform plexus*) in the broad ligament, and communicate freely with the uterine plexus.

Valves are often present in the spermatic veins, especially in the pampiniform plexus; and in exceptional cases they have been seen in the ovarian veins. There is also in most cases a valve at the termination of each spermatic or ovarian vein; but this is not unfrequently absent on the left side, and then a valve will generally be found in the renal vein not more than a quarter of an inch from the entrance of the former vessel (Rivington).

3. The **renal or emulgent veins** are short but wide vessels which issue from the hilum of the kidney, and pass inwards in front of the corresponding arteries to join the vena cava nearly at a right angle, the left usually a little higher up than the right. The vein of the left side is also longer than the right, and passes in front of (rarely behind) the aorta. The renal veins receive small branches from the suprarenal bodies, and the left is joined also by the spermatic and capsular veins of the same side. Valves are occasionally present in the renal veins or in some of their branches.

4. The **capsular or suprarenal veins** are, relatively to the organs from which they arise, of considerable size. On the right side the vein ends in the vena cava, on the left in the renal vein.

5. The **hepatic veins** return the blood conveyed to the liver by the portal vein and the hepatic artery. They converge to the groove in which the inferior vena cava lies, and are collected mainly into two or three large trunks which open obliquely into that vessel. There is also a variable number of smaller branches which collect the blood from the adjacent portions of the gland and pass directly into the vena cava. The hepatic veins have no valves; but, owing to their oblique entrance into the vena cava, a semilunar fold is formed at the lower border of the orifice of each vein.

6. The **inferior phrenic veins** are two in number on each side, and follow the course of the arteries of the same name. On the left side these veins often join the suprarenal vein.

**Varieties.**—It occasionally happens that the left common iliac vein is continued upwards on the left side of the aorta, after having given off, in most of these cases, a connecting branch of variable size to the right vein at the usual place of junction. About the level of the second lumbar vertebra it receives the left renal vein, and then crosses in front of (very rarely behind) the aorta to join the right common iliac vein, which passes up in the usual place of the inferior vena cava. The vein on the left of the aorta in these cases is probably a persistent lower portion of the left cardinal vein of the fetus. In rarer cases the inferior vena cava is placed in the lower part of its course on the left side of the aorta, and crosses over the latter vessel to gain its usual situation, after having been joined by the left renal

<sup>1</sup> W. H. Bennett, "On Varicocele," 1891. This work may be consulted for additional details as to the disposition of the spermatic veins.

vein. It is obvious that this condition would result from the foregoing variety if the vein of the right side were obliterated. (J. Walter, "Ueber die partielle Verdoppelung der Vena cava inferior," in "Beiträge zur Morphologie," &c., Stuttgart, 1884; A. Robinson, "Abnormalities of the Venous System and their Relation to the Development of the Veins," in "Studies in Anatomy," the Owens College, 1891.)

In cases of transposition of the viscera, without other abnormality (p. 386), the inferior vena cava is of course on the left side of the aorta throughout.

In a few instances the inferior vena cava, instead of ending in the right auricle of the heart, has been seen following the course of the right, or even of the left, azygos vein, passing through the diaphragm by the side of the aorta, and ascending through the posterior mediastinum, to join the superior vena cava, which therefore returns the blood from nearly the whole of the body. In these cases the hepatic veins do not join the inferior cava, but form a trunk which opens into the right auricle at the usual place of termination of that vessel. In this variety it may be supposed that the normal inferior cava has not been developed, and that the blood is returned from the lower part of the body by a persistent cardinal vein.

Supernumerary *renal veins* are occasionally met with, but not so frequently as supernumerary arteries; and one of these vessels on the left side may open into the corresponding azygos vein, as may also the *spermatic* or *suprarenal vein*. In rare cases a left renal vein has been observed entering the common iliac vein; this may also be explained as the persistence of a portion of the left cardinal vein distal to the junction of the renal vein.

The *hepatic veins* have been seen opening independently by one or two trunks into the right auricle; and a single hepatic vein has been found to end in this way, or in the left auricle (Breschet), or in the right ventricle of the heart, where its orifice was guarded by a valve (Rothe).

#### COMMON ILIAC VEINS.

The common iliac veins are formed on each side by the confluence of the external and internal iliac veins. Extending from the base of the sacrum upwards to near the junction of the fifth with the fourth lumbar vertebra, at a point a little to the right of the middle line, the two common iliac veins unite to form the inferior vena cava. The right vein is shorter than the left, and is nearly vertical in its direction. The right vein is placed behind, and then to the outer side of its artery; while the left vein is to the inner side of the left common iliac artery, and then passes behind the right. These veins are usually destitute of valves, but in a few instances one has been met with (Friedreich).

**LATERAL TRIBUTARIES.**—The **ilio-lumbar vein** collects branches from the hinder part of the abdominal wall, from the muscles of the back, and from the spinal canal, and emerges from beneath the psoas muscle to enter the lower part of the common iliac vein. It communicates above with the lumbar, and below with the lateral sacral veins.

The **middle sacral veins**, two in number, ascend on the front of the sacrum with the middle sacral artery, and join above into a single vessel which opens into the left common iliac, or occasionally into the angle of union of the two large veins. They anastomose freely with the lateral sacral veins, and by smaller branches with the veins of the rectum.

**Varieties.**—The common iliac vein is sometimes divided into two vessels for a portion of its extent. Absence of the common iliac vein of one or both sides has been met with, the left external and internal iliac veins being continued upwards to enter the commencement of the inferior cava, or (in one case) the two internal iliac veins being joined into a common trunk which unites with the right and left external iliac veins to form the vena cava (Gruber).

#### VEINS OF THE LOWER LIMB AND PELVIS.

The veins of the lower limb are divisible into two sets, those of the one being deeply seated, those of the other running in the superficial fascia. All the veins of the lower limb are provided with valves, and these are more numerous than in the veins of the upper limb. The deep veins have more valves than the subcutaneous set.

## SUPERFICIAL VEINS OF THE LOWER LIMB.

The superficial veins of the sole are numerous, but small, and form a plexus with close meshes immediately beneath the skin. In the furrow crossing the roots of the toes they give rise to a transverse arch which receives anteriorly the sub-

Fig. 413.—THE INTERNAL SAPHEOUS VEIN.

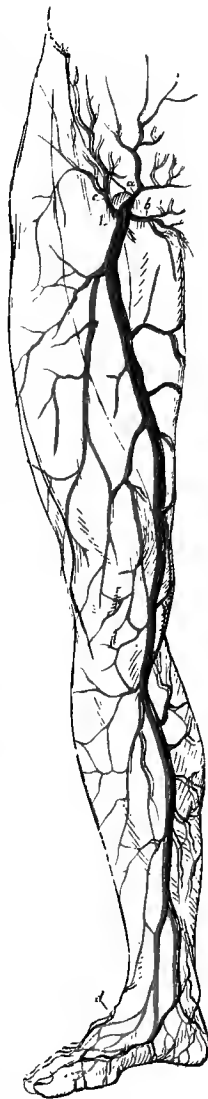
1, saphenous opening in the fascia lata; a, superficial epigastric vein; b, external pudic; c, superficial circumflex iliac; d, external or short saphenous beginning on the dorsum of the foot.

cutaneous veins of the toes, and posteriorly efferent vessels from the fore part of the plantar network, and from which trunks ascend in the interdigital spaces to join the dorsal veins. Other vessels pass from the plexus on each side, upwards round the margin of the foot, where they are joined by communicating offsets from the deep veins, and open into the beginning of the corresponding saphenous vein. All these veins are provided with numerous valves, which direct the flow of blood towards the dorsum of the foot.<sup>1</sup>

Immediately beneath the integument on the dorsum of the foot there is a network of veins, receiving the dorsal branches from the toes as well as the interdigital offsets from the sole, and forming a more or less regular arch, from which issue two principal trunks, named the internal or long, and the external or short saphenous veins.

The **internal or long saphenous vein** extends from the ankle to within an inch and a half of Poupart's ligament. Taking rise from the inner part of the plexus on the dorsum of the foot, it passes upwards in front of the inner ankle, and then behind the inner border of the tibia, accompanied by the internal saphenous nerve. It inclines a little backwards as it passes the inner condyle of the femur, and ascending along the inner and fore part of the thigh, following the course of the sartorius muscle, it passes through the saphenous opening in the fascia lata to terminate in the femoral vein.

The internal saphenous vein communicates below the internal malleolus with the deep plantar veins, in the leg with the veins accompanying the anterior and posterior tibial arteries, and in the thigh one or more branches pass between it and the femoral vein. It is joined at its commencement by superficial branches from the inner part of the sole and the heel; in its course upwards by numerous cutaneous branches from the leg and thigh; and close to its termination by the *superficial circumflex iliac*, *superficial epigastric*, and *external pudic veins*, corresponding severally to the arteries of the same name, as well as in many cases by a large *anterior* branch which ascends in the thigh over the position of the femoral artery. There is also very frequently a *posterior* branch of considerable size, collecting blood from the



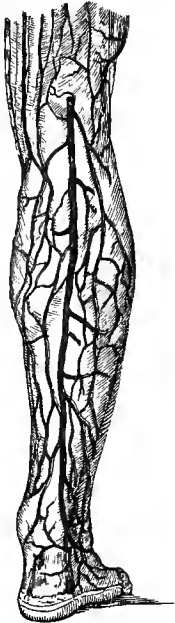
<sup>1</sup> W. Braune and P. Müller, "Die Venen des Fusses und Unterschenkels," 1889; Lejars, "Les veines de la plante du pied chez l'homme et les grands animaux." Archives de Physiologie, 1890.

inner and back parts of the thigh, and opening into the saphenous vein a little below its aperture in the fascia lata.

The valves of the internal saphenous vein vary greatly in number (from 7 to 20), position, and development. Two are often found near the termination of the vein, one just before, and the other after it perforates the cribriform fascia in the saphenous opening; but either or both of these may be imperfect or absent. The proportion of competent valves diminishes with age. (K. Klotz, "Untersuchungen über die Vena saphena magna beim Menschen, besonders rücksichtlich ihrer Klappenverhältnisse," Arch. f. Anat., 1887; W. H. Bennett, "On Varicose Veins of the Lower Extremities," 1889.)

The **external or short saphenous vein**, smaller than the internal, proceeds from the outer end of the arch on the dorsum of the foot. It passes behind the outer ankle, and ascends in the leg along the outer border of the tendo Achillis, in

Fig. 414.—THE EXTERNAL SAPHENOUS VEIN.



The vein, commencing on the dorsum and outer side of the foot, is seen to pass up behind the outer ankle and to dip beneath the fascia in the popliteal space.

company with the external saphenous nerve, and then over the interval between the heads of the gastrocnemius to the lower part of the popliteal space, where it perforates the deep fascia to end in the popliteal vein. Opposite the ankle and along the leg it communicates with the deep veins; and it receives superficial branches from the outer part of the foot and heel, and the back of the leg, as well as one which descends on the posterior surface of the thigh. A communicating branch usually passes from this vessel near its termination upwards and forwards to the internal saphenous vein; and sometimes the trunk itself follows this course, having no connection, or only a very small one, with the popliteal vein.

The number of valves in the external saphenous vein varies from nine to thirteen (Houzé).

**Varieties.**—The external saphenous vein, or a communicating branch, is occasionally continued upwards behind the adductor magnus to open into one of the perforating veins of the profunda. It has also been seen ascending, wholly or in part, along the back of the thigh to join the sciatic vein (Hyrtl, Hochstetter). According to Braune the ending of the external saphenous vein is always double.

#### DEEP VEINS OF THE LOWER LIMB.

The deep veins accompany the arteries and their branches, following exactly their distribution. Those below the knee, being for the most part disposed in pairs, and presenting the disposition described in the corresponding veins of the upper limb, are named the *venæ comites* of the vessels with which they are associated. The *venæ comites* of the arteries of the leg, namely, the **anterior** and **posterior tibial veins** (the latter having previously received the **peroneal**), unite near the lower border of the popliteus muscle, and form by their junction the popliteal vein.<sup>1</sup>

The **popliteal vein**, thus formed, receives smaller branches corresponding to the articular and muscular arteries, and the larger branch named the external saphenous vein. In its course upwards the vein is placed superficially to the popliteal artery, and it crosses that vessel gradually from the inner to the outer side. It passes with

<sup>1</sup> On the origin, communications, and valvular arrangements of these veins, see Braune and Müller, *op. cit. supra*.

the artery through the opening in the adductor magnus, and becomes continuous with the femoral vein. The popliteal vein has two or three valves.

In addition to the large popliteal trunk, there are two smaller veins accompanying the artery, one on each side, formed respectively by the continuation upwards of the internal and external lower articular veins, which are joined by some muscular branches.

**Varieties.**—The union of the veins which form the popliteal is often farther up than usual, and the lower part of the artery is then accompanied by two large veins. This arrangement in some rare cases extends to the entire length of the artery.

The **femoral vein** extends, like the artery which it accompanies, through the upper three-fourths of the thigh, and terminates at Poupart's ligament in the external iliac vein. Placed behind and at first somewhat to the outer side of the artery, it gradually inclines inwards, and on reaching Poupart's ligament lies on the inner side, on the same plane with the artery, from which it is separated only by a slight partition of the membranous sheath investing both vessels. In the lower part of its course, the vein receives the branches which accompany the offsets of the superficial femoral artery; in the upper part, the *deep femoral (profunda) vein* opens into it, having first received the venæ comites of the branches derived from the deep femoral artery; and near its termination it is joined by the internal saphenous vein. The femoral vein contains three or four valves, one of which is usually placed immediately above the entrance of the profunda vein. In most cases there is another valve (the *ilio-femoral valve* of Bennett) near Poupart's ligament, either in the upper end of the femoral vein, or in the lower part of the external iliac.

The femoral artery is also accompanied in Hunter's canal by two or three small veins, which adhere closely to it, and often receive some of the muscular branches: they open into the main trunk before the junction of the profunda vein.

**Varieties.**—The femoral vein occasionally pursues a course different from that of the artery along the thigh. Extending upwards from the popliteal space, the vein in such cases perforates the adductor magnus above the ordinary position, and, joining with the deep femoral vein, first approaches the femoral artery at the groin. The same vein is sometimes double in a small part, or more rarely in almost its whole length, a condition which may be explained as resulting from the enlargement of one of the small companion veins.

The **external iliac vein** is the continuation of the femoral vein from Poupart's ligament to the junction of the internal iliac vein, in the neighbourhood of the lumbo-sacral articulation. It is at first internal to the artery, but as it ascends it gradually inclines to the back of that vessel. It frequently contains one valve, rarely two.

Near its commencement at Poupart's ligament, the external iliac vein receives the *deep circumflex iliac* and *epigastric veins* (v. p. 484), corresponding to the arteries of the same name, and also a *pubic vein*, which ascends from the obturator vein in the thyroid foramen, and frequently constitutes the principal termination of the latter vessel.

#### VEINS OF THE PELVIS.

The **internal iliac vein** is formed by the union of branches which accompany most of the branches of the internal iliac artery. The umbilical vein of the fœtus, however, which in the cord accompanies the corresponding arteries, diverges from these arteries within the body, and passes upwards to the liver. The internal iliac vein lies behind and somewhat to the inner side of the artery, and, after a short course upwards to the margin of the pelvis, joins with the external iliac vein, to form the common iliac. No valves are found in the trunk of the internal iliac vein, but they exist in its branches.

**Tributaries.**—The tributaries of the internal iliac vein correspond in general to the various branches of the internal iliac artery, with the exception that the internal

pubic veins do not receive the main supply of blood from the dorsal vein of the penis, and that the ilio-lumbar veins open into the common iliac trunks. The visceral veins are remarkable for their size and frequent anastomoses, and form a series of plexuses, named *prostatic*, *vesical*, *hæmorrhoidal*, *vaginal*, and *uterine*.

The *gluteal*, *sciatic* and *obturator veins* agree closely with the arteries of the same name.

The *lateral sacral veins* form, by their communications with one another and with the middle sacral veins, a plexus over the anterior surface of the sacrum. They receive branches from the sacral canal through the anterior sacral foramina, and open at two or three points into the internal iliac vein.

The *internal pudic veins*, for the most part two in number, accompany the artery, around which they form frequent communications, and unite into a single trunk

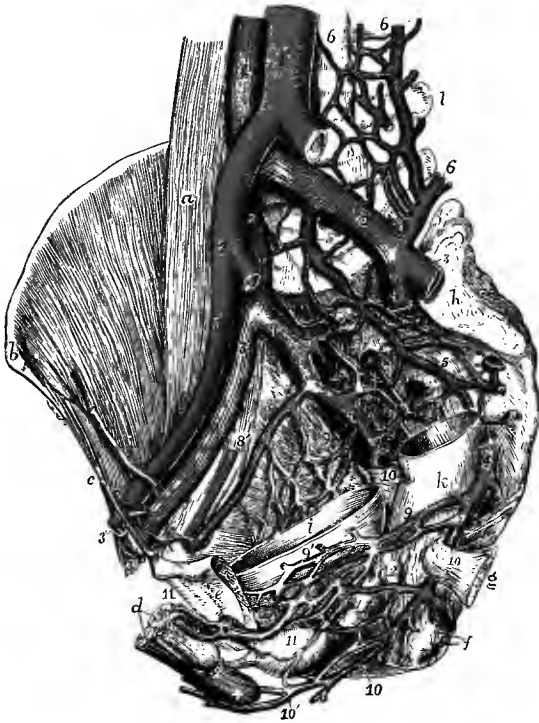


Fig. 415.—INTERNAL VIEW OF THE MALE PELVIS FROM THE LEFT SIDE, TO SHOW THE PRINCIPAL VEINS. (Allen Thomson.)  $\frac{1}{2}$

The greater part of the pelvic wall of the left side, and the upper parts of the rectum and urinary bladder have been removed; the left common iliac and the right internal iliac arteries, and the left external and internal iliac veins have been cut short: *a*, right psoas magnus muscle; *b*, anterior superior iliac spine; *c*, Poupart's ligament; *d*, cavernous and spongy bodies of the penis divided near the root; +, bulb of spongy body, above which is the membranous part of the urethra; *e*, left os pubis, sawn through close to the symphysis; *f*, anus; *g*, spine of ischium with small sacro-sciatic ligament; *h*, auricular surface of sacrum; *i*, bladder; *l*, rectum; *l*, transverse process of fourth lumbar vertebra; 1, inferior vena cava; 1', abdominal aorta; 2, 2, common iliac veins; 2', right common iliac artery; 3, 3, external iliac veins; 3', external iliac artery; 4, 4, internal iliac veins; 5, 5, middle sacral vein; 6, 6, ilio-lumbar and lumbar veins; 7, right gluteal and upper lateral sacral veins; 8, 8', obturator vein and artery of right side; 9, veins ascending from vesical plexus on right side; 9', lower part of vesical plexus on left side; 10, on the small sacro-

sciatic ligament, indicates on the right side the junction of the pudic and sciatic veins, on the left side the trunk of the pudic vein; 10', perineal veins; 11, on the prostate, the left division of the dorsal vein of the penis joining the prostatic plexus, which is continued into the lower part of the vesical plexus; 12, on the lower part of the rectum, may indicate the position of the hæmorrhoidal plexus.

before entering the pelvis. They receive the veins of the corpus cavernosum and of the bulb, the transverse and superficial perineal, and the inferior hæmorrhoidal veins.

The *dorsal vein of the penis* commences by branches which issue from the glans penis and prepuce and form in the first instance two veins, one on each side of the middle line. These speedily unite and give rise to a single vessel which runs backwards between the two dorsal arteries, in the median groove on the upper surface of the penis, receiving on its way branches from the corpus spongiosum, and others

from the corpora cavernosa and the skin of the organ. At the root of the penis the dorsal vein passes through the aperture below the subpubic ligament (p. 338), forming a communication on each side with the commencement of the pudic vein, and then divides into two branches which enter the right and left portions of the prostatic plexus. Each of these divisions is also connected with the obturator vein of the same side by a considerable branch which ascends on the back of the pubis towards the thyroid foramen.

The *prostatic plexus* is formed mainly by the breaking up of the divisions of the dorsal vein of the penis, but it receives also smaller branches from the gland and the neighbouring muscles. It surrounds the base of the prostate, most thickly on its anterior and lateral aspects, and communicates below with the tributaries of the pudic vein, while above it is continuous with the vesical plexus. In old persons these veins are generally much enlarged, and their valves become imperfect or disappear.

In the female, a similar plexus surrounds the upper part of the urethra and receives the *dorsal vein of the clitoris*.

The *vesical plexus* consists of vessels which ramify over the whole of the bladder external to its muscular coat, being particularly large and numerous towards the base of the organ, where they receive branches from the ureters, the vasa deferentia and the vesiculæ seminales, and are closely connected with the prostatic and hæmorrhoidal plexuses in the male, or with the vaginal plexus in the female.<sup>1</sup>

The *hæmorrhoidal plexus* consists of large and copiously anastomosing veins in the wall of the lower part of the rectum, immediately underneath the mucous membrane. From it proceed *superior, middle, and inferior hæmorrhoidal veins* corresponding generally to the arteries of the same name, and it communicates freely with the plexuses in front of it. The superior hæmorrhoidal vein being a branch belonging to the portal system, the hæmorrhoidal plexus forms a very free communication between the portal and general venous systems.

The *vaginal plexus*, surrounding the vagina principally in its lower part, communicates freely with the hæmorrhoidal and vesical plexuses.

The *uterine plexus* pours its blood in greatest part into the ovarian veins, and is not considerable except during pregnancy.

### THE PORTAL SYSTEM OF VEINS.

The portal vein differs from other veins of the body in being subdivided into branches at both its extremities. The branches of origin, by the union of which it may be said to be formed, are the veins of the chylipoietic viscera (stomach, intestine and pancreas) and of the spleen; they run as single companion vessels with the corresponding arteries and their offsets. The other branches, or those of distribution, undergoing ramification in the substance of the liver, convey to the capillaries of that organ the blood collected in the main trunk. This blood, together with that of the hepatic artery, after having served for the secretion of the bile and the nourishment of the liver, is withdrawn from that organ by the hepatic veins, and carried by them into the inferior vena cava.

The **portal vein** or **vena portæ** is about three inches in length. Commencing behind the head of the pancreas, and just to the left of the inferior vena cava at the level of the first lumbar vertebra, by the junction of the splenic and superior mesenteric veins, it passes upwards and a little to the right, behind the first part of the

<sup>1</sup> On the arrangement of the vesical veins and their valves, see E. Hurry Fenwick, Journ. Anat., xix, 1885.

duodenum and then between the layers of the small omentum, to the transverse fissure of the liver. In the omentum it is placed close behind the hepatic artery on the left and the bile duct on the right, and is accompanied by filaments of the hepatic plexus of nerves, as well as by numerous lymphatics, all these being surrounded by the loose connective tissue constituting the capsule of Glisson.

Near the right end of the transverse fissure, the vena portæ becomes somewhat enlarged (*sinus of the portal vein*), and immediately divides into two branches. That

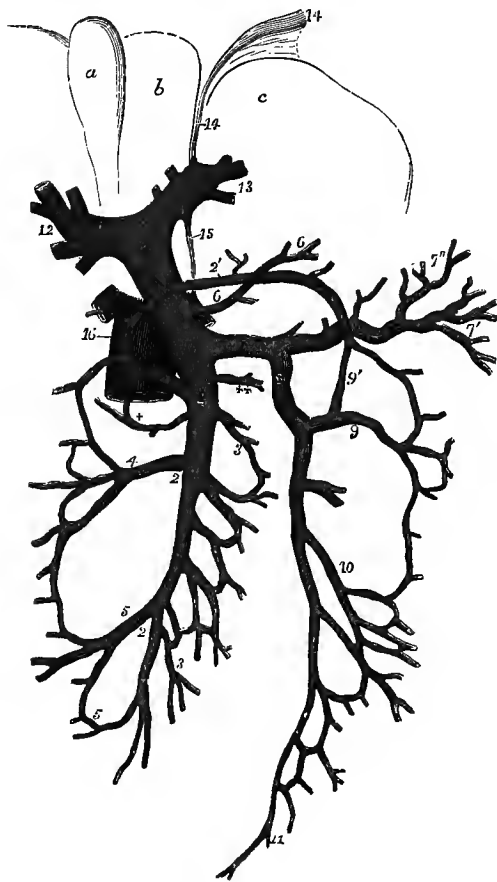


Fig. 416.—DIAGRAMMATIC SKETCH OF THE PORTAL VEIN AND ITS TRIBUTARIES. (Allen Thomson.)  $\frac{1}{2}$

The liver is turned upwards, so as to present a portion of its under surface: *a*, gall-bladder; *b*, quadrate lobe; *c*, left lobe; 1, 1, portal vein; 2, 2, superior mesenteric vein; 2', its middle colic branch, forming loops with the right and left colic veins; 3, 3, intestinal branches; +, pancreatico-duodenal branch; 4, right colic branch; 5, ileo-colic; 6, 6, coronary vein of stomach; ++, right gastro-epiploic; 7, splenic vein; 7', its branches from the spleen; 7'', its branches from the stomach; 8, inferior mesenteric vein; 9, left colic branch; 9', its communication with the middle colic; 10, sigmoid; 11, superior hæmorrhoidal; 12, right, and 13, left division of portal vein in the transverse fissure of the liver; 14, 14, obliterated cord of umbilical vein (round ligament of liver); 15, obliterated cord of ductus venosus; 16, part of inferior vena cava.

of the *right* side enters directly the substance of the corresponding lobe of the liver, and spreads out into branches, each of which is accompanied by an offset of the hepatic artery and of the hepatic duct. The *left* branch, which is smaller but necessarily longer, passes across to gain the left end of the transverse fissure, where it ramifies like the preceding branch. Opposite the fore part of the longitudinal fissure, the left

branch of the portal vein is joined anteriorly by the so-called round ligament of the liver, the remains of the umbilical vein of the fœtus; and a little to the right of this, from its posterior aspect, another fibrous cord, the obliterated ductus venosus, passes backwards to join the inferior vena cava.

*Tributaries.*—The principal branches which by their union contribute to form the portal vein are the superior and inferior mesenteric, and the splenic veins. It is also joined by the pyloric and coronary veins from the stomach, and sometimes by the cystic vein from the gall-bladder; but the latter vessel more frequently enters its right branch.

The **superior mesenteric vein** lies to the right side and somewhat in front of the artery of the same name. The distribution of its branches corresponds with that of the superior mesenteric artery, and it returns the blood from the several parts



supplied by that vessel, viz., from the small intestine, and from the ascending and transverse parts of the colon. The trunk, formed by the union of its several branches, inclines upwards and to the right side, passing in front of the third part of the duodenum and behind the pancreas, where it joins with the splenic vein to form the *vena portæ*. The superior mesenteric vein is also joined, close to its termination, by the *right gastro-epiploic vein* from the great curvature of the stomach.

The branches of the **inferior mesenteric vein** correspond with the ramifications of the artery of the same name. They commence at the lower part of the rectum in the hæmorrhoidal plexus, and unite into a single vessel near the sigmoid flexure of the colon. From this point the vein proceeds upwards beneath the peritoneum, lying to the left of the aorta, and then passing behind the pancreas, it inclines to the right to terminate in the angle formed by the junction of the splenic and superior mesenteric veins, or in the adjacent part of either of these vessels.

The **splenic vein**, a vessel of large size, commences by five or six branches which issue separately from the hilum of the spleen, and soon unite to form a single trunk. It is directed from left to right beneath the pancreas, in company with the splenic artery, below which it is placed. After crossing in front of the aorta it joins the superior mesenteric vein, nearly at a right angle. It receives *gastric* branches (*vasa brevia*) from the left portion of the stomach, the *left gastro-epiploic vein*, some *pancreatic* branches, and frequently the inferior mesenteric and coronary veins.

The **pyloric vein** is a small vessel which accompanies the pyloric branch of the hepatic artery on the small curvature of the stomach, and opens into the portal vein at a variable level.

The **coronary vein of the stomach** is of considerable size, and runs with the artery of the same name along the small curvature of the stomach to the cardiac orifice, where it receives branches from the œsophagus, and then, turning to the right, passes across the front of the spine to open into either the lower end of the portal vein or the adjoining part of the splenic vein.

There are no valves in the portal vein or in its larger tributaries, although such are known to exist in some animals. Valves are however present in the child in the veins of the stomach and of the wall of the intestine; but according to Hochstetter and Bryant they early become insufficient, and in the adult to a great extent disappear. (F. Hochstetter, "Ueber das normale Vorkommen von Klappen in den Magenverzweigungen der Pfortader," Arch. f. Anat., 1887; W. S. Bryant, "Valves in the Veins of the Human Intestines," Boston Med. and Surg. Journ., 1888; H. Koeppel, "Muskeln und Klappen in den Wurzeln der Pfortader," Arch. f. Physiol., 1890.)

**Varieties.**—The *coronary vein* is sometimes very small, or absent, when the *pyloric vein* is proportionately enlarged. The *pyloric vein* may either descend to the superior mesenteric vein, or ascend independently to the liver: it is often represented by two or three smaller branches. The *coronary vein* has been seen passing up through the small omentum to join the left division of the portal vein. (On the different modes of termination of the coronary and inferior mesenteric veins, and their relative frequency, see W. J. Walsham, "Observations on the Coronary Veins of the Stomach," Journ. of Anat., xiv, 1880; C. M. Fürst, "Venæ coronariæ ventriculi," Hygiea, 1881; F. Treves, "The Anatomy of the Intestinal Canal and Peritoneum in Man," 1885; F. Hochstetter, Arch. f. Anat., 1886; Report of Committee of Collective Investigation of Anat. Soc., Journ. Anat. xxv, 1890.)

**Accessory portal veins.**—This name has been given by Sappey to a number of small vessels which collect blood from the areolar tissue and peritoneal folds around the liver, and partly open into branches of the portal vein, partly penetrate directly into the substance of the liver; through anastomoses formed by the radicles of these vessels the portal vein is put into direct communication with the phrenic and azygos veins. There are also constantly one or more small veins which descend from the left division of the portal vein along the round ligament of the liver towards the umbilicus. According to Baumgarten the chief of these is a vestige of the umbilical vein, the lumen of which is as a rule not completely obliterated, but for a considerable part of its extent persists in the adult as a fine canal occupying the centre of the round ligament, and receiving minute branches from the abdominal wall. Other small veins on the surface of the ligament are called *parumbilical*, and open either into the remains of the umbilical vein or directly into branches of the portal vein. These vessels form connections

with the epigastric veins and the superficial veins of the abdominal wall; and they sometimes become much enlarged, setting up a more or less complete collateral circulation, in certain diseased conditions when the branches of the portal vein within the liver are obstructed. (Sappey, "Mémoire sur les veines portes accessoires," Journ. de l'Anat., 1883; W. Braune and E. H. Fenwick, "Die Venen der vorderen Rumpfwand des Menschen," 1884; E. Wertheimer, "Recherches sur la veine ombilicale," Journ. de l'Anat., 1886; P. Baumgarten, "Ueber die Nabelvene des Menschen," &c., "Arbeiten aus dem pathol. anatom. Institut zu Tübingen, i, 1891.)

Other communications between the portal and the general systemic veins are established by means of anastomoses formed by the veins of the pancreas, duodenum, colon and rectum with the parietal veins of the abdomen; and also through the oesophageal veins and the hæmorrhoidal plexus.

#### MORPHOLOGY OF THE VENOUS SYSTEM.

The arrangement of the primitive venous trunks of the body is different from that of the arteries, and where in the definitive state there appears to be a correspondence between the two (e.g. the superior vena cava and innominate veins to the ascending aorta and the branches of the arch, and the inferior vena cava to the abdominal aorta) the condition is secondary, resulting from developmental modifications of the original type. The first venous stems of the body are two vessels on each side, the *primitive jugular vein* descending from the head, and the *cardinal vein* ascending by the side of the aorta through the greater part of the trunk; the two unite to form the *duct of Cuvier*, which opens into the corresponding side of the sinus venosus of the heart. To these must be added the *vitelline* or *omphalo-mesenteric veins*, which are the earliest of the veins to be formed, and which are converted into the superior mesenteric, portal and hepatic veins (see Vol. I, p. 151), and the *umbilical veins*, of which the right soon disappears within the body, while the left is largely developed, and remains in function until the time of birth, when it also becomes obliterated, forming the round ligament of the liver.

The primitive jugular vein being joined by the subclavian vein when the upper limb makes its appearance, a brachio-cephalic or innominate trunk is formed; and the cardinal vein, undergoing reduction in the thoracic portion of its extent when in consequence of the development of the inferior vena cava (see below) it no longer returns the blood from the lower part of the body, becomes the azygos vein; while the duct of Cuvier forms a prolongation of the brachio-cephalic trunk. This symmetrical arrangement is destroyed by the occlusion of the greater part of the left brachio-cephalic trunk, following upon the development of the *transverse jugular vein*, which forms the greater part of the definitive left innominate, so that the blood from both sides of the upper part of the body is collected by the trunk of the right side or superior vena cava. The portion of the left trunk below the transverse jugular vein is represented by a part of the left superior intercostal vein and the fibrous band in the vestigial fold of the pericardium (p. 353), while the left part of the sinus venosus becomes the oblique vein and coronary sinus (p. 510). At the same time the upper end of the left cardinal (azygos) vein becomes obliterated, and the diminished trunk empties itself into the vein of the right side through transverse prevertebral communications which are formed between the two. Numerous varieties in the arrangement of the superior vena cava, innominate and azygos veins are readily explicable as the result of irregularities affecting the extent and manner of the occlusion of the primitive trunks (see pp. 513, 532).

In the abdomen, the cardinal vein of each side is joined in the pelvic region, where it becomes the internal iliac vein, by the primitive vein of the lower limb (sciatic), and receives as it ascends branches from the Wolffian body and the abdominal wall (lumbar veins). At a later period the secondary femoral vein (external iliac) and, on the development of the definitive kidney, the renal vein become its principal tributaries. A shorter passage to the heart is then formed by the development of a new vessel from the proximal end of the ductus venosus at the back of the liver, at the spot where that canal joins the omphalo-mesenteric (hepatic) veins; this grows downwards in front of the aorta as far as the origin of the superior mesenteric artery, and there bifurcates, its divisions forming a union on each side with the cardinal vein where that receives the renal vein. The short trunk thus formed is the hepatic portion of the inferior cava; and as it enlarges rapidly, the continuation of the cardinal vein shrinks and either disappears entirely, or remains as a communication between the azygos vein and the vena cava or the renal vein (p. 530).<sup>1</sup> The change from this symmetrical to the definitive asymmetrical condition takes place, as in the formation of the

<sup>1</sup> The ascending lumbar vein, which usually forms the beginning of the azygos vein, is a secondary trunk resulting from the formation of communications between the segmental veins, and may be compared to the precostal anastomoses of the segmental arteries (p. 505).

superior vena cava, by the development of a cross communication (*transverse iliac vein*) on the proximal side of the entrance of the vein from the limb, and the occlusion of the left primitive trunk between this and the renal vein. Thus the right common iliac vein and the portion of the inferior vena cava below the renal vein are parts of the right cardinal vein, and the greater part of the left common iliac is the transverse iliac vein. The different endings of the suprarenal and spermatic veins of the two sides thus find an explanation, and also the occasional occurrence of a channel on the left side of the aorta between the common

Fig. 417.—SCHEME OF THE DEVELOPMENT OF THE CHIEF VEINS OF THE BODY. (G. D. T.)

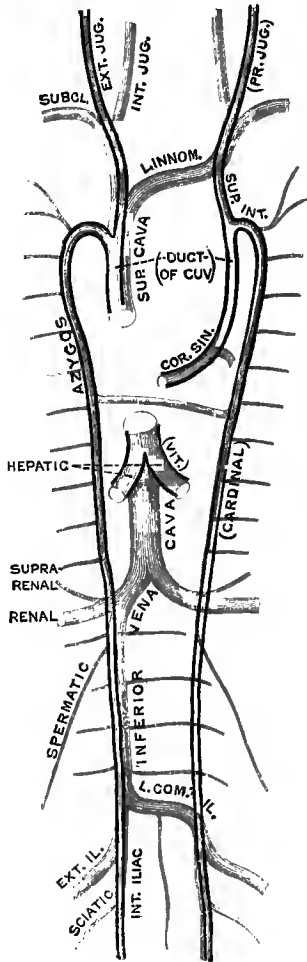
The primitive venous trunks are indicated by black outlines, and their names are enclosed within parentheses. The definitive veins are represented blue.

iliac and renal veins (p. 535). The upper end of the left spermatic vein, as suggested by Gegenbaur, probably includes a remnant of the left cardinal vein.<sup>1</sup>

The tributaries of these trunks are divided into superficial and deep.

The superficial veins course for the most part independently of the arteries, and although generally smaller than the deep trunks, they are to be regarded as constituting the primary system in the head and neck and in the limbs, since they are developed from, or in connection with, the original afferent vessels which return the blood from those parts in the embryo, while the deep veins are formed at a later period. Thus the primitive jugular vein becomes the external jugular, which at first receives the blood from the interior of the cranium through an aperture in front of the ear. This outlet is permanent in many animals, but in man it usually disappears (*cf.* p. 524), being supplanted by the greatly developed internal jugular vein, which extends from the lower part of the primitive trunk through the jugular foramen to join the lateral sinus. The facial, temporal and posterior auricular veins also are not properly companion veins to the arteries after which they are named, but belong to the superficial set.

In the rudimentary limbs, before the digits begin to appear, the blood is collected by a *marginal vein* which forms an arch at the distal edge of the extremity, and is continued up along the postaxial (ulnar or fibular) border thereof to join the veins of the trunk. In the lower vertebrates there is a similar upward prolongation of the marginal vein along the preaxial border of the limb, but in the mammal this part either is not developed or early disappears. As the digits grow out the arch becomes interrupted opposite the point of each, while the portions remaining in the intervals are converted into the collateral digital and interdigital veins, which become variably united on the dorsum of the appendage. In the upper limb the postaxial vein gives rise to the posterior ulnar, basilic, axillary and subclavian veins, thus forming the main trunk of the limb, into which the other veins empty themselves. A secondary trunk is developed on the preaxial border of the limb, receiving some of



<sup>1</sup> The sketch here given of the mode of formation of the inferior vena cava is based upon the recent observations of Hochstetter ("Ueber die Bildung der hinteren Hohlvene bei den Säugetieren," &c., *Anatom. Anzeiger*, 1887 and 1888), and differs materially from the earlier description of Rathke, which has hitherto been generally adopted by embryologists, and is followed in Volume I. of this work. (See also C. B. Lockwood, "The Early Development of the Pericardium, Diaphragm, and Great Veins," *Phil. Trans.*, 1888.)

the outer digital veins, and furnishes the radial and cephalic veins: the latter opens originally into the primitive (external) jugular vein, and later forms a connection between the muscles with the axillary vein. The occasional entrance of the cephalic vein into the external jugular, as is common among the lower animals, or the occurrence of a jugulo-cephalic vein (p. 528), which is normal in many apes,<sup>1</sup> is therefore a retention of the primitive ending. The two trunks, basilic and cephalic, form connections at the front of the elbow, which are joined also by the superficial and deep median veins, and through these a large part, or even the whole, of the blood from the radial side of the limb may be conveyed to the basilic vein, the cephalic vein then being correspondingly reduced or even disappearing.

In the lower limb the postaxial marginal vein is also at first the main trunk, but when the deep veins are developed it forms a connection with them at the knee, thus giving rise to the external saphenous vein, which therefore corresponds to the posterior ulnar vein of the forearm, and its femoral portion disappears more or less completely: the rare form of variety in which the external saphenous vein is continued to the sciatic (p. 538) is probably a persistence of the primitive trunk. Here also a secondary trunk, the internal saphenous, is developed on the preaxial border of the limb, but its homology with the preaxial trunk of the upper limb is doubtful. The internal saphenous vein opens into the femoral vein, which, in association with the change that has taken place in the great arterial trunk, has become the main vein of the limb. (F. Hochstetter, "Ueber die Entwicklung der Extremitätsvenen bei den Amnioten," *Morph. Jahrb.*, xvii, 1891.)

The deep veins, which as stated above are generally of secondary formation, are as a rule companion vessels to the arteries, although there are many exceptions, for example most of the larger veins of the brain and spinal cord. They differ from the arteries which they accompany more or less closely in—1, being more numerous; 2, having a greater capacity, the calibre of the single vein or the sum of the venæ comites always exceeding that of the corresponding artery; and 3, the greater number and size of their communications, which often lead to the formation of considerable plexuses, especially in regions where there is much movement between adjacent organs, or about parts which, although subject to rapid or considerable alterations in form or bulk, are surrounded by resistant structures, such as arteries in osseous canals, the viscera of the pelvis, the upper end of the pharynx, and the muscles in the zygomatic fossa. In these situations the venous plexuses form a soft packing which can readily adapt itself to the variations in shape and pressure of neighbouring parts.

### 3.—ABSORBENT VESSELS.

The absorbent vessels are divisible physiologically into two sets: the *lacteals*, which convey the chyle from the intestinal canal to the thoracic duct; and the *lymphatics*, which take up the lymph from all the other parts of the body, and return it into the venous system. Anatomically considered, however, the lacteals are not different from the lymphatics, and may be regarded as the absorbents of the mucous membrane of the intestine. The larger lacteals and lymphatics are provided with numerous valves, which give them, when distended, a somewhat moniliform appearance; and both are connected in their course with *lacteal* or *lymphatic* glands.

The general anatomy of the absorbents being elsewhere detailed (Vol. I, p. 376) only their course and position remain to be here described. They are gathered into a right and a left trunk, which open into the angles of union of the subclavian and internal jugular veins. The large vessel of the left side traversing the thorax is named the *thoracic duct*: it receives not only the lymphatics of its own side of the head and arm, and most of those of the trunk, but likewise the lymphatics of both lower limbs, and the whole of the lacteals. The short vessel of the right side is named the *right lymphatic duct*, and receives the lymphatics only of that side of the head and neck and upper part of the trunk, and of the right upper limb.

(On the distribution of the lymphatic vessels and glands generally, see Mascagni, "Vasorum lymphaticorum corporis humani historia et ichnographia," 1787; Cruikshank, "The Anatomy of the Absorbing Vessels of the Human Body," 2nd ed., 1790; Teichmann, "Das Saugadersystem vom anatomischen Standpunkte bearbeitet," 1861; and Sappey, "Description et iconographie des vaisseaux lymphatiques," 1874—85.)

<sup>1</sup> E. Ficalbi, "Di una particolare disposizione di alcuni vasi venosi del collo nelle scimmie," &c., *Atti d. Soc. Toscana d. Sci. Nat.*, iv; see also *Biologisches Centralblatt*, v, 1835.

## THORACIC DUCT.

The thoracic duct is the common trunk which receives the absorbents from both the lower limbs, from the abdominal viscera (except part of the upper surface of the

Fig. 418.—SKETCH OF THE THORACIC DUCT WITH THE PRINCIPAL SYSTEMIC VEINS. (Allen Thomson.)  $\frac{1}{2}$

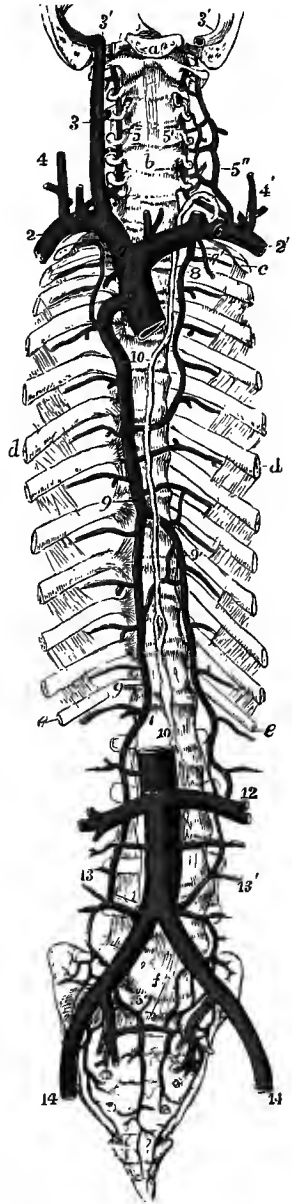
The full description of this figure will be found at p. 511.

10, 10, thoracic duct; the lower number is close to the receptaculum chyli; 6, on the left subclavian vein, marks the termination of the duct in the angle of union of the subclavian and internal jugular veins; 5, on the right subclavian vein, indicates the similar termination of the right lymphatic duct.

liver), and from the walls of the abdomen, from the left side of the thorax, left lung, left side of the heart, and left upper limb, and from the left side of the head and neck. It is from fifteen to eighteen inches long in the adult, and extends usually from the second lumbar vertebra to the root of the neck. Its commencement, however, is often as low as the third lumbar vertebra; and in some cases as high as the first lumbar, or even the last dorsal vertebra. Here there is usually a dilatation of the duct, of variable size, which is called *receptaculum chyli* (Pecquet), and is the common place of junction of the lymphatics from the lower limb with the trunks of the lacteal vessels.

The lower part of the thoracic duct is generally wider than the rest, being from 6 to 8 mm. in diameter; it lies at its commencement to the right side of or behind the aorta, and then ascends between that vessel and the right crus of the diaphragm to the thorax, where it is placed at first upon the front of the dorsal vertebrae, between the aorta and the large azygos vein. The duct runs upwards, gradually inclining to the left, and at the same time diminishing slightly in size, until it reaches the fourth dorsal vertebra, where, passing behind the arch of the aorta, it becomes applied to the left side of the oesophagus, lying between that tube and the left subclavian artery. Continuing its course into the neck to the level of the seventh cervical vertebra, it changes its direction and turns outwards, at the same time arching downwards and forwards so as to describe a curve over the apex of the pleura, and then terminates on the outer side of the internal jugular vein, in the angle formed by the union of that vein with the subclavian. The diminution in the size of the duct as it ascends is such that at the fifth dorsal vertebra it is often only 3 or 4 mm. in diameter, but above this point it again enlarges. The duct is generally waving and tortuous in its course, and is often alternately contracted and enlarged at irregular intervals.

The thoracic duct has valves at intervals throughout its course, the constrictions



at their attachments giving a nodulated appearance to the vessel. They are more numerous in the upper part of the duct. At the termination of the duct in the veins there is a valve of two segments, so placed as to allow the contents of the duct freely to pass into the veins, but effectually preventing the reflux of either chyle or blood into the duct.

**Varieties.**—The thoracic duct is not always a single trunk throughout its whole extent; it is frequently divided for some distance into two vessels which afterwards unite, especially in the lower part of its course (normal according to Teichmann); sometimes it separates into three divisions, or even presents a plexiform arrangement, for a short distance. In very rare cases the duct is double throughout, the two canals opening into the right and left innominate veins; or it is represented by two vessels, which are placed one on each side of the aorta, and unite at the root of the neck into a single trunk (Nuhn, Turner). Cruikshank, in one case, found the duct "triple or nearly so." In the neck, the thoracic duct often divides into two or three branches, which in some instances terminate separately in the great veins, but in other cases unite first into a common trunk; less frequently one of the branches passes across to the veins of the right side of the neck. It is stated by Teichmann that the termination of the thoracic duct, as well as of the right lymphatic duct, is regularly multiple; the number of terminal branches may be as many as eight on the left side, and five on the right. In the lower animals the termination of the thoracic duct in the veins of the right side as well as of the left is not uncommon. As a rare occurrence the trunk has been found passing upwards through the posterior mediastinum on the left side of the aorta. In cases of persistence of the right aortic root, either as a part of a right aortic arch or as a dorsal origin of the right subclavian or vertebral artery, the thoracic duct generally terminates in the veins of the right side: a similar termination has also been observed with a normal arrangement of the great arteries (Morrison Watson). In two instances the thoracic duct has been seen entering the large azygos vein (Wutzer, Arnold). (Teichmann, "Ueber die Ausmündung der Lymphgefäße in die Venen beim Menschen," Krakauer Akad. d. Wissensch., 1887; Arthur Thomson, "Variations of the Thoracic Duct associated with Abnormal Arterial Distribution," Journ. Anat., xvii, 1884; J. Szawlowski, "Ueber das Verhalten des Ductus thoracicus bei Persistenz der rechten absteigenden Aortenwurzel," Anatom. Anzeiger, 1888.)

#### RIGHT LYMPHATIC DUCT.

The right lymphatic duct is a short vessel, about 2 mm. or a little more in diameter, and from a quarter to half an inch in length, which receives the lymph from the absorbents of the right upper limb, the right side of the head and neck, part of the right side of the chest, the right lung and the right half of the heart, and part of the upper surface of the liver. It enters obliquely into the receding angle formed by the union of the right subclavian and internal jugular veins, where its orifice is guarded by a double valve. The vessels which usually unite to form this trunk, however, frequently terminate independently in the large veins.

#### LYMPHATICS OF THE LOWER LIMB.

The lymphatics of the lower limb are arranged in a superficial and a deep series. Those of the superficial series, together with the superficial lymphatics of the lower part of the trunk, converge to the superficial inguinal glands, with the exception of a few which dip into the popliteal space. Those of the deep series enter the deep inguinal glands.

The **popliteal lymphatic glands**, usually very small, and four or five in number, surround the popliteal vessels, and are embedded in a quantity of loose fat. They receive from below the deep lymphatics of the leg, and a few superficial ones which accompany the short saphenous vein; their efferent vessels ascend with the femoral vein to the groin.

The **superficial inguinal glands** vary much in number, but are generally between ten and fifteen: they are divisible into a superior or oblique and an inferior or vertical set. The *superior glands* lie in the line of Poupart's ligament,

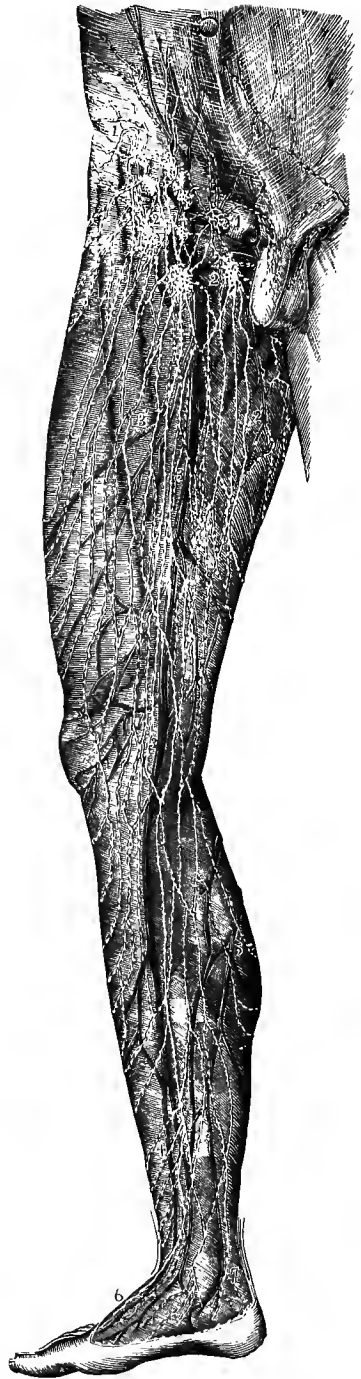Fig. 419. — THE SUPERFICIAL LYMPHATIC VESSELS AND GLANDS OF THE LOWER LIMB, FROM THE FRONT AND INNER SIDE (founded on Mascagni and others). (Allen Thomson.)  $\frac{1}{2}$

1, 1, upper inguinal glands receiving the lower abdominal, the inguinal, penile, and scrotal lymphatic vessels; 2, 2, femoral or lower inguinal glands, receiving the anterior, internal, and external femoral lymphatic vessels; 2', the internal lymphatic vessels; 3, 3, lymphatic vessels in the course of the internal saphenous vein; 4, the same in the leg; 5, inner lymphatics of the calf; 6, lymphatic vessels of the dorsum of the foot; 7, those of the heel and inner ankle.

and receive lymphatics from the integument of the trunk, gluteal region, perineum, and genital organs; the *inferior* or *femoral glands* surround the upper end of the long saphenous vein, and receive the superficial lymphatics of the limb. The efferent vessels of the superficial inguinal glands perforate the fascia, a large number passing through the saphenous opening, and some enter the deep inguinal glands, while others are continued upwards with the deep vessels into the abdomen, and join the lymphatic glands which lie along the external iliac artery.

The **deep-seated inguinal glands**, two or three in number, lie on the inner side of the femoral vein, the largest being placed in the femoral ring. They receive the deep lymphatics of the limb and some of the efferent vessels of the superficial inguinal glands. The efferent vessels of the deep glands proceed upwards through the femoral ring, and terminate in the external iliac lymphatic glands.

The **superficial lymphatics of the lower limb** arise in two sets, one from the inner part of the dorsum and sole of the foot, the other from the outer. The *inner* vessels, the more numerous, follow a similar course to that of the internal saphenous vein: passing partly in front of and partly behind the inner ankle, they ascend along the inner side of the knee and front of the thigh, and terminate in the inferior superficial inguinal glands. The *outer* vessels, ascending from the outer side of the foot, pass in great part in front of the external malleolus; some of these reach the internal set by crossing in front of the tibia; and others, ascending along the postero-external part of the leg and knee, incline forwards round the outer side of the thigh to join also the internal set. Two or three considerable vessels, arising in the neighbourhood of the heel, accompany the external saphenous vein behind the malleolus and along the back of the leg to the ham, where they dip down between the heads of the gastrocnemius



muscle and end in the popliteal glands. From the middle line of the back of the thigh lymphatics pass round on both sides to reach the inguinal glands.

The **deep-seated lymphatics of the lower limb** are associated in their whole course with the deep blood-vessels. In the leg they consist of three divisions, namely, anterior tibial, posterior tibial, and peroneal. Neither these nor the superficial absorbents pass through any lymphatic gland in the leg, unless it be those lymphatics which accompany the anterior tibial artery, near which a small *anterior tibial gland* is sometimes found on the front of the interosseous membrane above the middle of the leg. The several sets of deep lymphatics in the leg enter the lymphatic glands situated in the popliteal space. The efferent vessels from those glands are joined by other lymphatics in contact with the branches of the femoral artery, and enter the deep inguinal glands. Other deep lymphatics derived from the muscles of the gluteal region, and many proceeding from the adductor muscles of the thigh, enter the cavity of the pelvis in company with the gluteal, sciatic, and obturator arteries, and terminate in a series of glands placed along the internal iliac vessels. The deep lymphatics of the buttock are sometimes interrupted by two or three small glands, situated in the neighbourhood of the great sacro-sciatic foramen; and the obturator set usually traverse a gland placed against the wall of the pelvis about an inch behind the inner opening of the obturator canal.

The **superficial lymphatics of the lower part of the trunk** converge to the superficial inguinal glands, the direction of some of them being indicated by the superficial circumflex iliac and epigastric, and the external pudic arteries. Externally they converge to the groin from the gluteal region and from the lumbo-sacral area of the back, those from the latter part communicating with others which pass upwards to the axillary glands. Anteriorly they descend from the lower part of the surface of the abdomen, mingling about the level of the umbilicus with vessels which ascend towards the axillary glands.

The **superficial lymphatics of the perineum** are joined by vessels proceeding from the mesial part of the buttock, and course round the inner side of the thigh to enter the innermost glands of the superior inguinal group. The *deep lymphatics of the perineum* run with the pudic vessels to the internal iliac glands.

The **superficial lymphatics of the penis** usually form one large median dorsal trunk, and a variable number (commonly four or five) of smaller vessels on each side. The latter pass from the prepuce and the skin of the organ, and terminate in the internal glands of the superior inguinal set. The median trunk is formed at the cervix penis by the union of right and left vessels which collect the lymphatics from the skin of the glans and the mucous lining of the urethra, and form a plexus on each side of the frænum; in front of the suspensory ligament the trunk bifurcates, and its two divisions pass with the lateral vessels to the superior inguinal glands.<sup>1</sup> The *deep-seated lymphatics of the penis* pass with the pudic vessels under the pubic arch, and end in the glands on the internal iliac artery.

The **lymphatics of the scrotum** are very numerous, and pass to the superficial inguinal glands along the course of the external pudic arteries.

The lymphatics of the external generative organs in the female present a disposition similar to that existing in the male.

#### LYMPHATICS OF THE PELVIS AND ABDOMEN.

The **external iliac lymphatic glands**, from three to five, lie along the external iliac vessels, two or three of large size being placed immediately above

<sup>1</sup> Sappey, *op. cit.*; G. Marchant, "Recherches sur les lymphatiques des téguments des organes génitaux chez l'homme," Bull. Soc. Anat. Paris, 1889.



Poupart's ligament, and one or two smaller ones at a higher level. They receive the efferent vessels from the inguinal glands, as well as deep lymphatics from the abdominal wall, accompanying the epigastric and circumflex iliac vessels; and their efferent vessels pass upwards to the lumbar glands.

The **internal iliac lymphatic glands**, a numerous series placed along the internal iliac vessels, and the **sacral glands**, placed in the hollow of the sacrum, receive the lymphatics from the pelvic viscera and parietes.

The **lymphatics of the bladder** are few and small, and their course and termination are not sufficiently known. From a plexus over the base and the adjoining part of the abdominal surface of the organ a trunk passes on each side to enter a gland below the external iliac vein (Mascagni, Sappey); and other vessels derived from the pubic surface form a small trunk which traverses a gland lying against the obliterated hypogastric artery on its way to the internal iliac glands (Mascagni). The *lymphatics of the prostate* also ascend to glands below the external iliac vessels. The *lymphatics of the vesicula seminalis and of the ampullary portion of the vas deferens* are numerous, and enter one or two glands placed near the base of the former body (Sappey).

The **lymphatics of the uterus** are numerous, and become much enlarged during gestation. Those from the lower part of the organ converge on each side of the cervix to two or three large vessels, which are joined by lymphatics from the upper end of the vagina, and then pass backwards to enter the glands upon the internal iliac artery, thus following the course of the principal uterine blood-vessels. Others, proceeding from the upper end of the uterus, run outwards in the folds of peritoneum which constitute the broad ligaments, and, joining the lymphatics derived from the ovaries and Fallopian tubes, ascend with the ovarian vessels to the glands placed on the aorta and vena cava. There are also in some cases one or two small lymphatic vessels passing from the uterus forwards along the round ligament to one of the superficial inguinal glands. The *lymphatics from the greater part of the vagina* enter the lowest of the internal iliac glands; but those from the lower end join the vessels of the external generative organs passing to the superficial inguinal glands.<sup>1</sup>

The **lymphatics of the rectum** are frequently of considerable size; immediately after leaving the intestine, some of them pass through small glands which lie contiguous to it, and finally, they enter the lymphatic glands situated in the hollow of the sacrum. At the anus, their capillary network is continuous with that of the cutaneous lymphatics.

The **lumbar lymphatic glands** are very numerous and are disposed in three groups, a median and two lateral. The glands of the *median* group are of large size, and lie along the common iliac vessels, the aorta and the vena cava; they receive the efferent vessels of the external and internal iliac, and of the sacral glands, the lymphatics from the kidneys, suprarenal bodies and testicles (or ovaries with a part of the uterus), some of the efferent vessels of the lateral lumbar glands, and the lymphatics of the vertebral portion of the diaphragm. The glands of the *lateral* group are much smaller; they lie behind the psoas muscle, in the intervals between the transverse processes of the vertebræ, and receive the deep lymphatics of the hinder part of the abdominal wall. The greater number of the efferent vessels of the lumbar glands are generally united on each side into a short stem, the *lumbar lymphatic trunk*, which, with several smaller vessels, opens into the commencement of the thoracic duct.

The **lymphatics of the kidney** consist of a deep and a superficial set. Those placed upon the surface of the organ are comparatively small; they unite at the

<sup>1</sup> P. Poirier "Lymphatiques des organes génitaux de la femme," Paris, 1890.

hilum of the kidney with the lymphatics from the interior of the gland, and then pass inwards to a group of the median lumbar glands lying over the renal blood-vessels. The *lymphatics of the suprarenal capsules* unite with those of the kidney.

The **lymphatics of the testicle** commence in the substance, and upon the surface of the gland. Collected into several large trunks, they ascend with the other constituents of the spermatic cord, pass through the inguinal canal, and accompany

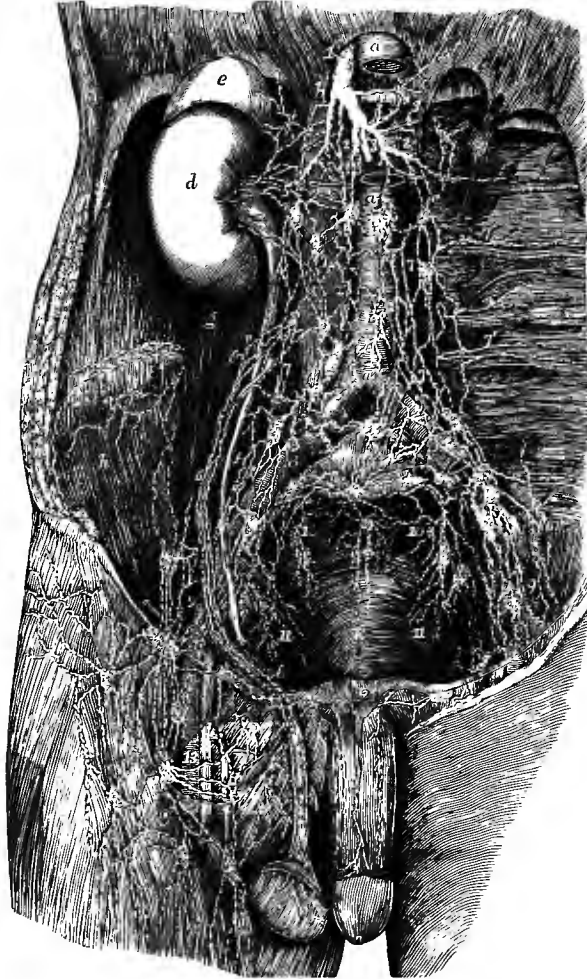

Fig. 420.—PRINCIPAL LYMPHATIC VESSELS AND GLANDS OF THE ABDOMEN AND PELVIS (modified from Mascagni). (Allen Thomson.)  $\frac{1}{2}$

*a*, abdominal aorta, the upper part of which has been removed to show the formation of the thoracic duct; *a'*, inferior vena cava; *b*, right, *c*, left crus of diaphragm; *d*, right kidney; *e*, suprarenal body; *f*, ureter; *g*, psoas muscle; *h*, iliacus; *k*, lower part of sacrum; 1, commencement of thoracic duct; 2, 2, lumbar lymphatic trunks; 3, intestinal lymphatic trunk; 4, suprarenal lymphatics; 5, renal; 6, 6, spermatic; 7, 7, lumbar lymphatic vessels and glands; 7', 7', some of the lymphatics of the loins; 8, those surrounding the common iliac vessels, and proceeding from the lymphatics of the pelvis and lower limb; 8', some lymphatics of the abdominal wall; 8, 9, external iliac glands; 10, 10, lateral sacral glands; above *k*, lymphatics of the rectum joining the median sacral glands; 11, internal iliac glands; 12, lymphatics of the dorsum of the penis passing to the glands of the groin; 13, inguinal glands.

the spermatic vessels in the abdomen to enter some of the lumbar lymphatic glands below the renal vessels.

The **deep lymphatics of the abdominal wall** in part pass along the circumflex iliac and epigastric arteries to the external iliac glands, the circumflex iliac set often traversing one or two small glands at the fore part of the iliac crest; others accompany the ilio-lumbar and lumbar arteries, and, after being joined by lymphatics from the muscles of the back and the spinal canal, enter the lateral lumbar glands. The lymphatics from the upper part of the anterior wall ascend with the internal mammary vessels, and enter the sternal glands in the thorax.

The **mesenteric glands** vary in number from a hundred and thirty to a hundred and fifty or more; and in the healthy state they are seldom larger than an almond. The largest are placed around the trunk of the superior mesenteric artery, but the greater number lie within the loops formed by the blood-vessels, between the layers of the mesentery, becoming smaller and increasing in number as they are nearer to the intestine. They are most numerous in that part of the mesentery which corresponds to the jejunum; and, except at the lower part of the ileum, they are seldom found closer to the intestine than an inch and a half or two inches. A considerable cluster of *ileo-colic glands* lies in the angle between the ileum and ascending colon. Small *mesocolic glands* in limited numbers are also disseminated irregularly between the layers of the peritoneal folds connected with the large intestine.

The **lacteals** take their origin in the wall of the intestines, where they form two chief plexuses, one beneath the mucous membrane, and the other between the layers of the muscular coat (see the anatomy of the intestinal canal, in Vol. III). They leave the intestine at its attached border, and ascend through the mesenteric glands, gradually diminishing in number and increasing in size, to near the root of the superior mesenteric artery, where they are joined by the efferent vessels of the cœliac glands, and terminate sometimes in a single *intestinal lymphatic trunk*, sometimes in three or four vessels, which open into the lower end of the thoracic duct. The lymphatics from the descending colon and the sigmoid flexure usually join some of the lumbar lymphatics, or turn upwards and open by a separate trunk into the thoracic duct.

The **cœliac glands**, from sixteen to twenty in number, and of large size, surround the cœliac axis, and cover the aorta above the superior mesenteric artery. They receive the lymphatic vessels derived from the stomach, spleen, pancreas, and the greater part of the liver; and their efferent vessels pass with the trunks of the lacteals to the thoracic duct.

The **lymphatics of the stomach** commence in the wall of that organ, and pass upwards and downwards over its surface to the small and great curvatures respectively, where they traverse a few small *gastric glands* lying along the attached border of the corresponding omenta. The lymphatics of the small curvature accompany the coronary vessels to the cardiac orifice, and then turn downwards behind the pancreas to enter the cœliac glands; those of the great curvature are directed towards the pylorus, along with the right gastro-epiploic artery, and, after being joined by the lymphatics from the upper part of the duodenum, also open into the cœliac glands. A third series of lymphatic vessels proceed from the left end of the stomach, and, following the course of the gastric branches of the splenic artery, unite with the lymphatics of the spleen.

The **lymphatics of the spleen** leave the organ at the hilum with the blood-vessels, and, accompanying these, pass through a series of small *splenic glands* lying against the tail of the pancreas, to terminate in the cœliac glands.

The **lymphatics of the pancreas** emerge therefrom at different points, and enter the cœliac glands at its upper border.

The **lymphatics of the liver** are divided into superficial, which run beneath the peritoneum on the upper and lower surfaces of the organ, and deep, which accompany the blood-vessels within its substance.

On the *upper surface of the liver*, the lymphatic vessels are disposed in the following groups, which differ in their course and termination, viz:—1. Those from the mesial portions of both lobes ascend in the falciform ligament, and pass through the diaphragm behind the ensiform process to enter the glands of the anterior mediastinum. 2. The lateral lymphatics of each lobe are directed backwards to the corresponding lateral ligament, and descend to the cœliac glands. 3. The lymphatics from the hinder part of this surface converge to the coronary ligament, perforate the diaphragm, and terminate in a small group of glands surrounding the upper end of the inferior vena cava. 4. At the fore part of the liver a few vessels turn downwards and join those of the inferior surface, while a larger number penetrate the liver-substance and unite with the lymphatics accompanying the portal vein.

The greater number of the lymphatics of the *under surface of the liver* converge to the transverse fissure, and descend with the deep lymphatics issuing at that part in the small omentum; but some pass deeply to join the portal lymphatics, while a few at the back of the right lobe enter the glands on the inferior cava.

The *deep lymphatics of the liver* accompany the branches of both the portal and hepatic veins. The vessels running in the portal canals issue by the transverse fissure and, being joined by most of the lymphatics of the under surface of the organ, pass downwards in the small omentum, where they traverse some small *hepatic glands*, to end in the cœliac glands. The lymphatics accompanying the hepatic veins form five or six trunks which pass through the diaphragm with the inferior vena cava, and enter the glands placed around that vessel, in union with the posterior lymphatics of the surface of the liver. The efferent vessels from these glands descend on the upper aspect of the vertebral portion of the diaphragm, and open into the lower end of the thoracic duct (Sappey).

#### LYMPHATICS OF THE THORAX.

The lymphatic glands of the thorax form the following groups, viz:—

1. Along the course of the internal mammary blood-vessels there are placed from six to ten small **sternal glands**, which receive lymphatics from the anterior thoracic and abdominal walls, from a portion of the diaphragm, and from the inner part of the mamma. The efferent vessels of the lower glands run partly to the upper glands of the same group and partly to the anterior mediastinal glands; those of the upper glands ascend to join the lymphatic trunks at the root of the neck.

2. On each side of the spine in the line of the heads of the ribs, and sometimes extending outwards between the intercostal muscles, is a set of small **intercostal glands**, from one to three in each space, which receive lymphatics from the thoracic parietes and the costal pleura. Their efferent vessels terminate mostly in the thoracic duct, those from the lower three or four spaces on each side uniting into a trunk which descends through the aortic opening of the diaphragm to enter the receptaculum chyli; but some of the upper ones on the right side generally ascend to the right lymphatic duct.

3. The **anterior mediastinal glands** are three or four in number, and lie behind the lower part of the body of the sternum, between that and the pericardium; they receive, besides some of the efferent vessels of the lower sternal glands, lymphatics from the mesial part of the upper surface of the liver, and others from the fore part of the diaphragm. Their efferent ducts pass upwards with those of the sternal glands to the right and left lymphatic trunks.

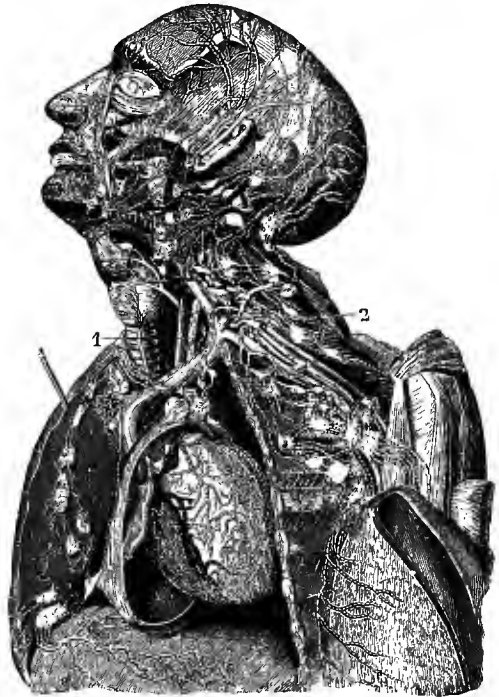
4. The **superior mediastinal** or **cardiac glands**, a large and numerous group, are placed in the upper part of the interpleural space, in connection with the innominate veins and the arch of the aorta, and more deeply between the latter and the lower end of the trachea; they receive the lymphatics of the heart, of the greater part of the pericardium, and of the thymus gland. Their efferent ducts form two or three vessels on each side, which ascend along the trachea to the thoracic and right lymphatic ducts respectively.

5. The **bronchial glands** are also numerous, and are continuous above with the foregoing group; the largest occupy the interval between the bronchi at their divergence, and others of smaller size accompany the primary divisions of each of

Fig. 421.—THE LYMPHATICS OF THE HEAD AND NECK AND OF THE UPPER PART OF THE TRUNK. (Mascagni.)  $\frac{1}{2}$

The chest and pericardium have been opened on the left side, and the left mamma detached and thrown outwards over the left arm, so as to expose a great part of its deep surface.

The principal lymphatic vessels and glands are shown on the side of the head and face, and in the neck, axilla, and mediastinum. Between the left internal jugular vein and common carotid artery, the upper ascending part of the thoracic duct is seen marked 1, and above this, and descending to 2, the arch and last part of the duct. The termination of the upper lymphatics of the diaphragm in the mediastinal glands, as well as the cardiac and the sternal glands, are also shown.



those tubes in the hilum of the lung. They receive the lymphatics of the lung; and their efferent vessels, forming two or three considerable trunks, ascend on the trachea with those of the cardiac glands to join the great lymphatic ducts. In early infancy the colour of the bronchial glands is pale red; towards puberty they become greyish and studded with dark spots; at a more advanced age they are frequently very dark or almost black.

6. The **posterior mediastinal glands**, eight to twelve, lie along the descending thoracic aorta and œsophagus, receiving lymphatics from the latter and from the hinder parts of the pericardium and the diaphragm; their efferent vessels join mainly the thoracic duct, but some pass also to the bronchial glands.

The **deep lymphatics of the thoracic wall** are divided into two sets, anterior and posterior. The *anterior lymphatics* pass forwards in the intercostal spaces and enter the sternal glands. The *posterior* or *intercostal lymphatics* run backwards with the intercostal vessels, receive opposite the intervals between the transverse processes accessions from the muscles of the back and the spinal canal, and terminate in the intercostal glands.

The **lymphatics of the heart** form a rich plexus on the surface of the ventricles, the chief vessels following the coronary arteries in the interventricular and auriculo-ventricular furrows. At the base of the heart anteriorly they are collected into two

trunks, which pass backwards, one on each side of the pulmonary artery, to the concavity of the arch of the aorta, and there terminate in the glands at the bifurcation of the trachea (Sappey).

The **lymphatics of the lung**, like those of the viscera generally, form two sets, one being superficial, the other deep-seated. Those at the surface are numerous and form a network beneath the pleura. The deep lymphatics run with the pulmonary blood-vessels and the bronchial tubes. The vessels of both sets converge to the root of the lung and terminate in the bronchial glands.

The **lymphatics of the œsophagus** form only a single plexus between the muscular and mucous coats. The trunks emerging from this plexus perforate the muscular wall and terminate in the inferior cervical and posterior mediastinal glands.

The **lymphatics of the thymus gland** are numerous and large. They enter the glands of the superior mediastinum, and, according to Astley Cooper, two large vessels proceed, one from each lateral lobe, to open by one or more orifices into the internal jugular veins.

#### LYMPHATICS OF THE UPPER LIMB.

In the upper limb, as in the lower, the lymphatics are arranged in a deep and a superficial set. These two sets of vessels, together with the superficial lymphatics of the greater part of the back and of the chest, converge to the axillary glands.

The lymphatic glands found in the upper limb below the axilla are neither large nor numerous; a few, however, are found in the course of the brachial artery, and occasionally even of the arteries of the forearm; two or more small glands are sometimes found in connection with the superficial lymphatics at the bend of the elbow, and one or two, more constantly, near the commencement of the basilic vein, a little above and in front of the inner condyle of the humerus.

The **axillary glands** are generally twelve or more; they vary much, however, in their number, as well as in their size, in different individuals. From four to six are placed along the axillary vessels, and receive the lymphatics which ascend from the limb; four or five small *pectoral glands* lie farther forwards on the serratus magnus near the long thoracic artery, at the lower border of the pectoral muscles, and receive the lymphatics from the mamma and front of the chest; while three or four *subscapular glands* are situated at the back of the axilla, along the subscapular vessels, and are joined by the lymphatics from the back. One or two small *infra-clavicular glands* are also found immediately below the clavicle in the hollow between the pectoralis major and deltoid muscles; they receive some lymphatics from the outer side of the arm and the shoulder, and are connected above with the inferior cervical glands, below with the axillary glands.

The efferent vessels of the axillary glands ascend with the subclavian vein, and form by their union in some cases a single trunk (*axillary lymphatic trunk*), in others two or three large vessels, which terminate on the left side in the thoracic duct, on the right side in the right lymphatic duct. Sometimes they open separately into the subclavian vein near its termination.

The **superficial lymphatics of the upper limb** begin in cutaneous networks, which are closest and most developed on the fingers and in the palm of the hand. The digital plexuses are finer and denser on the palmar than on the dorsal aspect, and empty themselves on each side of the fingers into two or three collateral trunks, which ascend to the back of the hand. From the network in the palm vessels converge below to the interdigital spaces, where they turn backwards to pass with the digital trunks to the dorsum of the hand, and others ascend over the front of the wrist to the forearm. The numerous lymphatics passing up the forearm tend to form three groups accompanying the radial, median and ulnar veins, the outer and inner

Fig. 422.—SUPERFICIAL LYMPHATICS OF THE BREAST, SHOULDER, AND UPPER LIMB, FROM BEFORE (after Mascagni and Sappey).  $\frac{1}{2}$

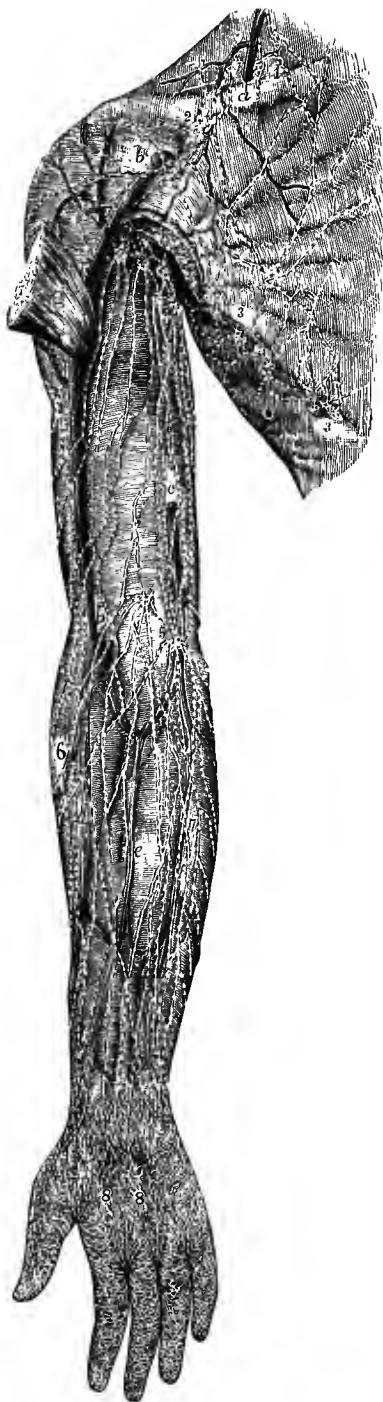
The lymphatics are represented as lying upon the deep fascia.

*a*, placed on the clavicle, points to the external jugular vein; *b*, cephalic vein; *c*, basilic vein; *d*, radial; *e*, median; *f*, ulnar vein; *g*, great pectoral muscle, cut and turned outwards; 1, superficial lymphatic vessels and glands above the clavicle; 2, infraclavicular glands; 3, 3, pectoral glands; 4, 4, axillary glands; 5, two small glands placed near the bend of the arm; 6, radial lymphatic vessels; 7, ulnar lymphatic vessels; 8, 8, palmar lymphatics.

sets being joined at intervals by tributaries derived from the posterior surface of the limb. The inner set, after being connected with the glands above the internal condyle, ascend in a straight direction along the arm, following the basilic vein, while the middle and the greater number of the outer vessels incline gradually inwards over the biceps muscle, and finally all enter the axillary glands. One or two vessels on the outer side accompany the cephalic vein to the glands in the infraclavicular fossa, and these are joined by others which pass forwards from the shoulder.

The **deep lymphatics of the upper limb** correspond with the deep blood-vessels. In the forearm they consist, therefore, of three sets, associated respectively with the radial, ulnar, and interosseous arteries and veins. In their progress upwards, they communicate near the wrist with the superficial lymphatics, and some of them enter the glands which lie by the side of the brachial artery near the bend of the elbow. They all terminate in the glands of the axilla.

The **superficial lymphatics of the chest** include the vessels running under cover of, and collecting lymph from, the pectoral muscles, the cutaneous lymphatics of this region, and the greater number of the lymphatics of the mamma. They are directed outwards and traverse the pectoral glands on their way to join the principal axillary glands. Associated with these vessels are the *superficial lymphatics of the upper part of the abdominal wall*, which commence about the level of the umbilicus, where they mingle with others passing downwards to the superficial inguinal glands, and then ascend to the pectoral and axillary glands. Some of the inner-



most of these vessels, however, pass with the deep lymphatics of this region to the sternal glands; they may traverse a small and inconstant *epigastric gland* near the linea alba (Mascagni).

The **superficial lymphatics of the back** converge to the axillary glands from its various regions; from the lower part of the neck over the surface of the trapezius muscle, from the hinder part of the deltoid, and from the whole thoracic region; the branches communicate inferiorly with vessels leading to the inguinal glands, and likewise across the middle line with branches of the opposite side.

### LYMPHATICS OF THE HEAD AND NECK.

The lymphatic glands of the head are comparatively few and small; those of the neck are, on the contrary, large and numerous. The following groups of glands, with their associated vessels, are distinguished:—

**1.** One or two **suboccipital glands** are placed beneath the skin, over the upper end of the complexus muscle, and receive the lymphatics from the hindmost part of the scalp; their efferent vessels join the superficial cervical glands.

**2.** The **mastoid glands** are two or three in number, and lie over the insertion of the sterno-mastoid muscle; they receive lymphatics which descend from the scalp behind the ear, and their efferent vessels enter the superficial cervical glands.

**3.** The **parotid lymphatic glands**, three or four of small size, lie beneath the parotid fascia, and are frequently more or less embedded in the substance of the parotid gland; one, larger than the others, is situated immediately in front of the tragus of the ear. They receive the superficial lymphatics descending from the temporal region, and their efferent vessels pass to the submaxillary and superficial cervical glands.

**4.** The **internal maxillary glands** are placed deeply beneath the ramus of the lower jaw, one or two with the internal maxillary artery, others on the hinder part of the buccinator muscle and the side wall of the pharynx. Their afferent vessels are derived from the temporal, zygomatic and orbital fossæ, as well as the roof of the mouth and the soft palate; their efferent vessels enter the superior deep cervical glands.

**5.** The **submaxillary lymphatic glands**, from eight to ten or more in number, lie beneath the base of the inferior maxilla, and receive the superficial lymphatics of the face, the lymphatics of the floor of the mouth, and of the submaxillary and sublingual salivary glands, as well as most of the vessels emerging from the parotid lymphatic glands. Their efferent vessels pass to both superficial and deep cervical glands. There are frequently also one or two small *suprahyoid glands* (Sappey) placed in the centre of the neck between the anterior bellies of the two digastric muscles, and connected with the lymphatics descending from the lower lip.

**6.** The **superficial cervical glands**, from four to six, lie along the external jugular vein, between the platysma myoides and the deep fascia. They are joined by the lymphatics of the external ear, and of the integument of the neck, by the vessels issuing from the suboccipital and mastoid glands, and by some of those from the parotid and submaxillary lymphatic glands. Their efferent ducts enter the inferior deep cervical glands. One or two small glands are sometimes found near the middle line of the front of the neck between the hyoid bone and the sternum, less frequently at the back of the neck over the trapezius muscle.

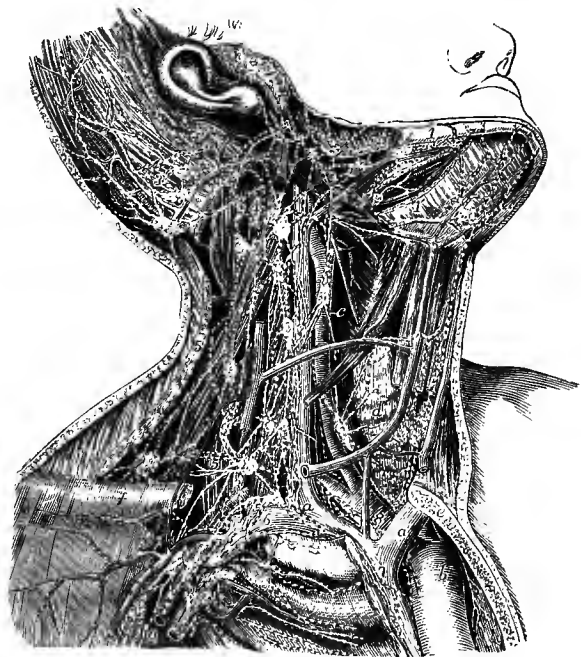
**7.** The **deep cervical glands** are very numerous (twenty to thirty), and are subdivided into superior and inferior. The *superior* extend from the bifurcation of the common carotid artery to the base of the skull, lying for the most part along the internal jugular vein. They receive the efferent vessels of the internal maxillary



and some of the submaxillary glands, the lymphatics of the cranial cavity, the tongue, larynx, and lower part of the pharynx, some of those of the thyroid body and the deep muscles of the neck. Their efferent vessels descend to the following glands. The *inferior deep cervical glands* are grouped around the lower part of the internal jugular vein, and extend outwards into the supraclavicular fossa, becoming continuous below with the glands of the superior mediastinum internally, and those of the axilla externally. They receive the efferent vessels of the other cervical glands, both superficial and deep, and the lymphatics from the lower part of the neck. Their efferent ducts unite to form a single vessel (*jugular lymphatic trunk*) which terminates in the thoracic (or right lymphatic) duct, or sometimes separately in one of the large veins.

The **lymphatics of the scalp** descend partly over the occiput and behind the

Fig. 423. — PRINCIPAL LYMPHATIC VESSELS AND GLANDS OF THE HEAD AND NECK ON THE RIGHT SIDE (after Bourguery in part). (Allen Thomson.)



The inner half of the clavicle and part of the sternum have been removed so as to expose the arch of the aorta, and the innominate artery and veins; the posterior belly of the omohyoid muscle is removed; and the sterno-mastoid, sterno-hyoid, and sterno-thyroid muscles, and the external jugular vein have been divided so as to expose the deeper parts.

*a*, right innominate vein at the place where it is joined by the principal lymphatic trunk; *a'*, the left vein; *b*, arch of aorta; *c*, common carotid artery; *d*, thyroid body crossed by the anterior jugular vein; *e*, cut surface of sternum; *f*, outer part of clavicle; 1, submaxillary lymphatic glands; 1', lingual; 2, parotid; 3, 3, suboccipital and mastoid; 4, superior deep cervical; 5, 5, inferior deep cervical glands; 6, 6, axillary glands; 7, on the superior vena cava, some of the anterior mediastinal vessels; 8, on the innominate artery, some of the superior mediastinal; to these last are seen descending some of the lymphatics from the thyroid body and lower part of the neck.

ear to the suboccipital and mastoid glands, and partly in front of the ear to the parotid lymphatic glands. From the mesial part of the forehead other vessels pass downwards and join the lymphatics of the face.

The **superficial lymphatics of the face** are directed for the most part obliquely downwards in the course of the facial vein, and enter the submaxillary glands, but those springing from the outer parts of the eyelids and cheek pass backwards to the parotid glands. The *deep lymphatics of the face*, including those of the orbit, nasal cavity in part, roof of the mouth, and interior of the cheek, terminate in the internal maxillary glands.

The **lymphatics of the cranial cavity** take their origin in networks contained in the pia mater on the surface of the brain and in the choroid plexuses of the ven-

tricles. At the base of the brain they are collected into larger vessels which descend along the internal carotid and vertebral arteries and the internal jugular vein to the deep cervical glands. The lymphatics springing from the choroid plexuses of the lateral and third ventricles run backwards and unite into a considerable trunk which accompanies the veins of Galen between the layers of the velum interpositum.

The **lymphatics of the tongue** are mainly directed backwards in company with the ranine vein, and traverse two or three small *lingual glands*, lying on the outer surface of the hyo-glossus muscle, on their way to join the deep cervical glands in the neighbourhood of the bifurcation of the common carotid artery. From the fore part of the tongue also, one or two vessels pass downwards together with the lymphatics of the floor of the mouth and, after perforating the mylo-hyoid muscle, enter the submaxillary glands.

The **lymphatics of the larynx** form two groups, superior and inferior. The *superior* are from four to six trunks which pierce the thyro-hyoid membrane and pass to the glands about the bifurcation of the common carotid artery. The *inferior* vessels, from three to five, arise from the infraglottic portion of the larynx, and emerge through the crico-thyroid membrane; they either enter a small *prelaryngeal gland* lying on the surface of that membrane, or pass directly to some *inferior laryngeal glands* at the lower and lateral part of the larynx.<sup>1</sup>

The **lymphatics of the pharynx** are abundant. Those from the upper part of the cavity are joined by lymphatic vessels from the nose and superior surface of the soft palate, and pass backwards to a gland near the skull, between the pharynx and the prevertebral muscles. The lymphatics from the lower part of the pharynx pass out with the superior laryngeal lymphatic vessels and enter the same glands.

<sup>1</sup> P. Poirier, "Vaisseaux lymphatiques du larynx," &c. Bull. Soc. Anat., Paris, 1887.

# INDEX AND GLOSSARY TO VOLUME II.<sup>1</sup>

- ABDOMEN** (fat belly of swine, perhaps from *adeps*, fat, as if for *adipomen*, perhaps from *abdo*, hide), fascia of, lining, 336  
     superficial, 327  
     lymphatics of, 550  
     muscles of, 327  
**Abdominal aorta**, 380, 456  
     artery (internal mammary), 428  
         (lumbar), 467  
     respiration, 325  
     ring, external or superficial, 328  
         internal or deep, 336  
**Abduction**, 151  
**Abductor**. See **MUSCLES**.  
*Aberrant arteries*, 419, 440, 451, 492, 495  
**Absorbent vessels**, 546  
**Accessoryus ad ilio-costalem**, 314  
*Accessoryus tricipitis muscle*, 221  
**Accessory artery**, pudic, 480  
     ligaments of atlas, 155  
     occipito-atlantal ligament, 157  
     palatine canals, 54  
     process of lumbar vertebræ, 11, 23  
**Acetabulum** (a vessel for holding vinegar), 110, 115, 136  
**Acrocephaly** (*ἄκρον*, summit; *κεφαλή*, head), 86  
**Acromial angle**, 90  
     artery, 432  
**Acromio-clavicular articulation**, 165  
**Acromion** (*ἄκρον*; *ἄμος*, shoulder), 90, 106  
**Acromio-scapular notch**, 90  
**Acromio-thoracic artery**, 432  
     vein, 530  
**Adduction**, 151  
**Adductor**. See **MUSCLES**.  
**Adductor tubercle**, 121  
**Adminiculum** (support) *lineæ albæ*, 335  
**Agger** (mound) *nasi*, 52  
**Air-sinuses in bones of head**, 71  
**Alæ** (*ala*, wing) of sacrum, 15  
     of vomer, 55  
**Alar ligaments**, of knee, 187  
     odontoid, 156  
     processes of ethmoid, 48  
**Alar** (*alaris*, contraction of *axillaris*) thoracic artery, 432  
     vein, 530  
**Alisphenoid**, 75, 80  
**Alveolar artery**, 406  
     index, 85  
     point, 83  
     process, 50, 52, 58  
     vein, 517  
**Alveoli** (*alveolus*, small hollow vessel), of lower jaw, 58  
     of upper jaw, 52  
**Amphiarthrosis** (*ἀμφί*, on both sides, intermediate; *ἄρθρον*, joint), 148  
*Amygdalo-glossus* (*amygdala*, tonsil) muscle, 307  
**Anal fascia**, 339  
     muscles, 341, 346  
**Anapophysis** (*ἀνά*, upon; *apophysis*), 11, 23  
**Anastomoses** (arterial) on alimentary canal, 465  
     of visceral and parietal branches of abdominal aorta, 469  
**Anastomosis** (*ἀναστόμιωσις*, outlet), nenral, 505  
     postcostal, 505  
     postvertebral, 505  
     precostal, 505  
     splanchnic, 507  
     ventral somatic, 505  
**Anastomotic arteries**. See **ARTERIES**.  
     veins of cerebrum, 519  
**Anatomy** (*ἀνά*, apart; *τέμνω*, cut), descriptive, 1  
     systematic and topographical, 1  
**Anconens** (*ἄγκων*, elbow), 221  
**Angiology** (*ἀγγεῖον*, vessel; *λόγος*, discourse), 351  
**Angle**, acromial, 90  
     of lower jaw, 59, 61  
     of pubis, 113  
     of rib, 26  
     subcostal, 29  
     of torsion, of femur, 123  
     of humerus, 94  
     of tibia, 127  
**Angular artery**, 398  
     movement, 151  
     processes of frontal bone, 37  
     vein, 514  
**Ankle-joint**, ligaments of, 190  
     movements of, 191  
**Annular** (*annulus*, ring), ligaments. See **LIGAMENT**.  
     fibres of auricles of heart, 368  
**Annulus ovalis**, 358  
**Antibrachial index**, 99  
**Antibrachium** (*ἀντί*, opposite; *brachium*), 86  
**Antrum** (cavern), 4  
     of Highmore, 50, 53, 72, 77  
     mastoid, 75

<sup>1</sup> Names printed in italics denote varieties. For additional information as to the meaning and derivation of anatomical terms the reader is referred to the works of Hyrtl, especially "Onomatologia anatomica," Wien, 1880.



ARTERIES OF ARTERY—*continued.*

central, of retina, 408  
of brain, 413, 415  
cerebellar, anterior, 423  
inferior, 421  
superior, 423  
cerebral, anterior, 411, 413  
middle, 411, 413  
*middle anterior*, 412  
posterior, 415, 423  
cervical, ascending, 424, 505  
deep, 429, 506  
of occipital, 399  
superficial, 425  
transverse, 425  
choroid, anterior, 411  
posterior, 415  
ciliary, 408  
circumflex, of arm, anterior, 435  
posterior, 434  
iliac, deep, 484  
superficial, 489  
of thigh, external, 489  
internal, 490  
clavicular, 432  
of clitoris, profunda, 480  
dorsal, 480  
coccygeal, 481  
cœliac, 458, 507  
colic, left, 463  
middle, 463  
right, 463  
communicating, of brain, anterior, 411  
posterior, 411  
coronary of heart, 382  
of lips, 398  
of stomach, 458, 507  
of corpus callosum, 413  
of corpus cavernosum, 479  
cortical of brain, 413, 415  
cremasteric, 484  
crico-thyroid, 395  
cystic, 460  
dental, anterior, 406  
inferior, 404  
posterior, 406  
digital, of foot, 500, 503  
of hand, 446, 450  
dorsal, of clitoris, 480  
of foot, 502, 507  
of fore finger, 450  
of intercostal, 456  
of lumbar, 467  
of penis, 479  
scapular, 434  
of thumb, 450  
of tongue, 395  
emulgent, 465  
epigastric, deep or inferior, 483, 505, 506  
superficial, 489  
superior, 428  
ethmoidal, 409  
facial, 396, 505  
transverse, 403  
femoral, 485, 506  
common, 486  
deep, 486, 489  
superficial, 486  
fibular, superior, 502  
frontal, of cerebral, anterior internal, 413  
ascending, 413  
inferior external, 413

ARTERIES OF ARTERY—*continued.*

frontal, of cerebral, inferior internal, 413  
middle internal, 413  
posterior internal, 413  
of ophthalmic, 411  
gastric, short, 461  
gastro-duodenal, 460, 507  
gastro-epiploic, left, 461, 508  
right, 460, 507  
gluteal, 481, 506  
hæmorrhoidal, inferior or external, 478  
middle, 474  
superior, 463, 465  
of hand, varieties of, 452  
hepatic, 460, 507  
humeral, 436  
of acromio-thoracic, 432  
transverse, 425  
hyoid (lingual), 395  
(thyroid), 394  
hypogastric, 471, 473  
ileo-colic, 463  
iliac, common, 469, 506  
external, 482, 506  
of ilio-lumbar, 482  
internal, 471, 506  
in fœtus, 473  
of obturator, 475  
ilio-lumbar, 482  
of index finger, dorsal, 450  
radial, 450  
infraorbital, 406  
innominate, 388, 504  
intercostal, aortic, 455, 505  
anterior of internal mammary, 428  
superior, 429, 506  
interosseous, of forearm, common, 443  
anterior, 443, 507  
posterior, 444, 507  
of foot, 503  
of hand, dorsal, 445, 450  
palmar, 452  
intestinal, 462  
labial, inferior, 398  
lachrymal, 409  
laryngeal, of inferior thyroid, 424  
of superior thyroid, 394  
*lateral of internal mammary*, 429  
lenticular, 413  
lenticulo-optic, 413  
lenticulo-striate, 413  
lingual, 395, 504  
lumbar, 467, 505  
*lowest lumbar*, 469  
of ilio-lumbar, 482  
malleolar, of anterior tibial, 502  
of posterior tibial, 497  
mammary, external, 432, 435  
internal, 427, 505  
masseteric, 405  
mastoid, of occipital, 399  
of posterior auricular, 401  
maxillary, external, 396  
internal, 403, 505  
median, 441, 443, 446, 506  
mediastinal, 428, 455, 508  
mcdullary, of clavicle, 425  
femur, 491  
fibula, 497  
humerus, 438  
radius, 443  
tibia, 496

ARTERIES OF ARTERY—*continued.*

medullary, of ulna, 443  
 meningeal, anterior, 410  
   of ascending pharyngeal, 402  
   middle or great, 404  
   of occipital, 400  
   posterior, 421  
   small, 404  
 mental, 405  
 mesenteric, inferior, 463, 507, 508  
   *middle*, 465  
   superior, 461, 507, 508  
 metacarpal, 444  
 metatarsal, 503  
 musculo-phrenic, 428  
 mylo-hyoid, 404  
 nasal, anterior, 410  
   of internal maxillary, 406  
   lateral, 398  
   of ophthalmic, 410, 411  
 naso-palatine, 406  
 obturator, 475, 506  
 occipital, of external carotid, 399, 401, 505  
   of cerebral, 415  
 cesophageal, of aorta, 454, 507  
   of coronary artery, 459  
   of inferior phrenic, 467  
   of inferior thyroid, 424  
 ophthalmic, 408  
 orbital, of meningeal, 404  
   of temporal, 403  
 ovarian, 466  
 palatine, inferior or ascending, 397  
   superior or descending, 406  
   of pharyngeal, 402  
 palmar, superficial, 446  
   deep, 451  
 palpebral, 409, 410  
 pancreatic, 461, 508  
 pancreatico-duodenal, inferior, 462  
   superior, 460, 507  
 parietal, ascending, of cerebral, 413  
   of occipital, 401  
 parieto-temporal, 414  
 of penis, dorsal, 479  
   profunda, 479  
 perforating, of foot, 500  
   of hand, 450, 452  
   of thigh, 490  
   of thorax, 428, 505  
 pericardial, 428, 454  
 perineal, superficial, 478, 480  
   transverse, 479  
 peroneal, 497, 507  
   anterior, 498  
 petrosal, 404  
 pharyngeal, ascending, 401  
 phrenic, inferior, 467, 508  
   superior, 428, 508  
 plantar, internal, 498, 507  
   external, 498, 507  
 popliteal, 493, 506  
 prevertebral, of ascending pharyngeal, 402  
 profunda, of arm, inferior, 438, 441  
   superior, 437, 441  
   of clitoris, 480  
   of penis, 479  
   of thigh, 489  
 pterygoid, 405  
 pterygo-palatine, 406  
 pubic, of epigastric, 484

ARTERIES OF ARTERY—*continued.*

pubic, of obturator, 476  
 pudic, *accessory*, 480  
   external, 488  
   internal, 477  
     in female, 480  
 pulmonary, 358, 378, 504  
   varieties of, 384  
 pyloric, 460, 508  
 radial, 447, 506  
   of index-finger, 450  
 raune, 395, 396  
 recurrent, of deep palmar arch, 451  
   interosseous, posterior, 444  
   of ophthalmic, 409  
   radial, 448, 506  
   tibial, 502  
   ulnar, 442  
 renal, 465, 508  
 sacral, middle, 469, 506  
   lateral, 482, 506  
*saphenous*, *great*, 492  
   *small*, 495  
 scapular, dorsal, 434  
   posterior, 426  
 sciatic, 480, 506  
 of septum narium, 398  
 of septum nasi, 406  
 sigmoid, 464  
 spermatic, 466, 508  
 spheno-palatine, 406  
 of spinal canal, 422  
 spinal, anterior, 421  
   of ascending cervical, 424  
   of deep cervical, 429  
   of ilio-lumbar, 482  
   of intercostals, 456  
   of lumbar, 469  
   posterior, 421  
   of vertebral, 420, 421  
 splenic, 460, 508  
 sternal, 428  
 sterno-mastoid (occipital), 399  
   (superior thyroid), 394  
 stylo-mastoid, 401  
 subclavian, 384, 386, 415, 504, 505  
 sublingual, 396  
 submental, 398  
 subscapular, 434  
   of suprascapular, 425  
 supraacromial, 425  
 supraorbital, 409  
 suprarenal, middle, 465, 508  
   inferior, 465, 508  
   superior, 467, 508  
 suprascapular, 425  
 supraspinous, 426  
 suprasternal, 425  
 sural, 494  
 systemic, 380  
 tarsal, 502  
 temporal, superficial, 402  
   anterior, 403  
   of cerebral, 415  
   deep, 405  
   middle, 403  
   posterior, 403  
 thoracic, acromial, 432  
   alar, 432  
   long, 432  
   short or superior, 432  
 of thumb, dorsal, 450

ARTERIES OF ARTERY—*continued.*

- of thumb, large, 450
  - thyroid axis, 423
  - thyroid, inferior, 424, 504
    - lowest, 388, 425
    - superior, 394, 504
  - tibial, anterior, 500, 503, 507
    - posterior, 496, 506
  - tonsillar, 398
  - tracheal, 424
  - transverse, of basilar, 423
    - cervical, 425
    - facial, 403
    - humeral or scapular, 425
    - perineal, 479
  - tympanic, 402, 404, 408
  - ulnar, 442, 447, 506
  - umbilical, 473
  - uterine, 475, 508
  - vaginal, 474, 508
  - of vas deferens, 474
  - vertebral, 419, 505
  - vesical, inferior, 473
    - middle, 473
    - superior, 473
  - vesico-prostatic, 473
  - vesico-vaginal, 474
  - Vidian, 406
  - volar, superficial, 449
- Arthrodia (*ἄρθρωδια*, a joint with shallow socket—Galen), 149
- Arthrology (*ἄρθρον*, joint; *λόγος*), 147
- Articular (*articulus*) arteries of hip, 476, 490
  - of knee, 494, 506
  - eminence of temporal bone, 41, 75
  - processes of vertebræ, 5, 6, 7, 8, 9, 11
    - homology of, 21
    - joints of, 153
  - surfaces, 150
- ARTICULATIONS (*articulus*, joint; diminutive of *artus*, limb), 147
- acromio-clavicular, 165
- of ankle, 190
- of astragalus, 192
- of atlas and axis, 155
- calcaneo-cuboid, 193
- of calcaneum, 192
- carpal, 173
- carpo-metacarpal, 175
- chondro-sternal, 159
- classification of, 147
- of coccyx, 178
- coraco-clavicular*, 165
- of costal cartilages, 29, 160
- costo-central, 158
- costo-clavicular*, 155
- costo-transverse, 159
- cubo-cuneiform, 195
- development of, 150
- of elbow, 170
- of foot, 192
- of forearm, 169
- of hand, 173
- of hip, 181
- intercarpal, 173
- interchondral, 29, 160
- intermetacarpal, 175
- intermetatarsal, 196
- interphalangeal of hand, 176
  - of foot, 197
- of knee, 183
- of lower limb, 181

ARTICULATIONS—*continued.*

- lumbo-sacral, 177
  - metacarpo-phalangeal, 176
  - metatarso-phalangeal, 197
  - modes of, 147
  - movements of, 151
  - of navicular bone, 192, 193, 194, 195
  - naviculo-cuboid, 194
  - naviculo-cuneiform, 195
  - of occipital bone, 155
  - of pelvis, 177
  - of pisiform bone, 174
  - pubic, 180
  - radio-carpal, 172
  - radio-ulnar, 169
  - of ribs, 158
  - sacro-coccygeal, 178
  - sacro-iliac, 178
  - sacro-vertebral, 177
  - scapulo-clavicular, 164
  - of shoulder, 166
  - sternal, 161
  - sterno-clavicular, 164
  - tarsal, 192
  - tarsometatarsal, 195
  - temporo-maxillary, 162
  - of thorax, 158
  - tibio-fibular, 189
  - transverse carpal, 173
    - tarsal, 194
  - of trunk and head, 151
  - of upper limb, 164
  - of vertebral column, 151
  - of wrist, 172
- Ascending aorta, 380, 381, 504
- Asterion (*ἀστήρ*, star), 84
- Asternal (*ἀ*, neg.; *στέρον*, breast) ribs, 25
- Astragalo-calcaneal ligaments, 192
- Astragalo-navicular ligament, 193
- Astragalus (*ἀστράγαλος*, ankle-bone, or die, the astragali of the sheep having been used as dice by the ancients), 130
- articulations of, 192
  - homology of, 144
  - ossification of, 138
- Atlanto-axial ligaments, 157, 158
- Atlanto-mastoid muscle*, 319
- Atlas, 7
  - homology of, 21
  - ligaments of, 155
  - movements of, 158
  - ossification of, 19
  - varieties of, 8
- Atrium (hall) of left auricle, 360
- of right auricle, 356
- Attollens (*attollo*, raise up) auriculum muscle, 280, 350
- Attrahens (*ad*, to; *traho*, draw) auriculum muscle, 281, 350
- Auditory artery, 423
  - meatus, external, 41, 64, 75
  - internal, 42, 43, 71
  - veins, 523
  - process, external, 41
- Auricles (*auricula*, outer ear, dim. of *auris*) or heart, 354
  - arrangement of fibres of, 368
  - left, 360
  - nerves of, 372
  - position in relation to wall of thorax, 365
  - relative capacity of, 374

Auricles—*continued*.  
 right, 356  
 septum of, 357  
 Auricular appendix, 356, 360  
 arteries, 401, 403, 404, 505  
 muscles, 280, 349, 350  
 point, 84  
 surface of ilium, 112, 178  
 surface of sacrum, 14, 178  
 veins, 515, 517  
 Auricularis. *See* MUSCLES.  
 Auriculo-bregmatic line, 84  
 Auriculo-ventricular apertures, 358, 360, 367.  
 375  
   fibrous or tendinous rings of, 368  
   furrow, 355  
   valves, 359  
 Axial skeleton, 4  
   relation of limbs to, 140  
 Axillary arches, 205, 274  
 Axillary artery, 431, 506  
   fascia, 208  
   lymphatic glands, 556  
   sheath, 298  
   vein, 529, 545  
 Axis (vertebra), 8  
   homology of, 21  
   ligaments of, 155  
   ossification of, 20  
   coeliac, 458  
   of pelvis, 117  
   thoracic, 435  
   thyroid, 423  
 Azygos (ἄζυγος, single, from α, without; ζυγόν,  
 yoke) artery, 495  
 veins, 530, 531, 544  
*See also* MUSCLES.

BACK, fasciæ and muscles of, 311  
 lymphatics of, 550, 556, 558  
 Ball and socket joint, 149  
 Basilar (*basis*, base) artery, 423, 506  
   groove, 34  
   plexus, 523  
   process of occipital bone, 31, 34, 67  
   sinus, 523  
   vein, 520  
 Basilic (from Arabic *al-basilik* in Avicenna, the  
 inner [vein]—Hyrtl) vein, 528, 545  
 Basihyal, 80  
 Basisoccipital, 73, 79  
 Basion (*Basis*, base), 84  
 Basisphenoid, 75, 80  
 Beak of olecranon, 95  
 Bertin, bones of, 44  
 Biceps (*bis*, twice; *caput*, head). *See* MUSCLES.  
 Bicipital artery, 437, 441  
   groove of humerus, 93  
   tuberosity of radius, 98  
 Bienspid (*bis*; *cuspid*, point) valve, 362  
 Biventer (*bis*; *venter*, belly) cervicis muscle,  
 317  
 Bladder, urinary, ligaments of, true, 339  
   lymphatics of, 551  
 BLOOD-VESSELS, description of, 377  
   *See also* ARTERIES and VEINS.

BONES, Descriptive Anatomy of, 3  
 astragalus, 130, 138, 144  
 atlas, 7, 19, 21  
 axis, 8, 20, 21  
 of Bertin, 44

BONES—*continued*.  
 calcaneum, or os calcis, 129, 138, 144  
 carpal, 100, 108, 143  
 clavicle, 86, 106, 140  
 coceyx, 5, 16, 21  
 cuboid, 132, 138, 143  
 cuneiform, of carpus, 101  
   of tarsus, 131, 138, 144  
*epipteric*, 62, 84  
 ethmoid, 47, 76, 80  
 femur, 118, 137, 142  
 fibula, 127, 138, 142  
 frontal, 36, 74, 80  
 of head, 31  
   homologies of, 79  
   ossification of, 73  
 hip, 110, 136, 140  
 humerus, 91, 107, 142  
 hyoid, 61, 78, 80  
 ilium, 110, 136, 140  
 innominate, 110, 136, 140  
*interparietal*, 34, 73, 79, 80, 84  
 ischium, 113, 136, 140  
 lachrymal, 57, 77, 80  
 of limbs, homological comparison of, 140  
   morphology of, 140  
 of lower limb, 110  
   ossification of, 136  
 lunar, 101, 108, 143, 144  
 magnum, 102, 108, 144  
 malar, 55, 78, 80  
 maxillary, inferior, 58, 78, 80  
   superior, 50, 77, 80  
 metacarpal, 103, 109  
 metatarsal, 133, 138  
 nasal, 56, 77, 80  
 navicular of tarsus, 131, 138, 144  
 number of, 4  
 occipital, 31, 73, 79  
 palate, 53, 77, 80  
 parietal, 35, 74, 80  
 patella, 124, 138, 144  
 phalangeal, of hand, 105, 109  
   of foot, 135, 139  
 pisiform, 101, 108, 144  
 pubic, 113, 136, 140  
 pyramidal, 101, 108, 143  
 radius, 97, 107, 142  
 ribs, 25, 31  
 sacrum, 5, 13, 20  
 scaphoid, of carpus, 101, 108, 143  
   of tarsus, 131, 138, 144  
 scapula, 87, 106, 140  
 semilunar, 101, 108, 143, 144  
 sesamoid, in hand, 105, 176, 236, 237  
   in foot, 135, 197, 261, 267, 271  
 sphenoid, 43, 75, 80  
 spongy. *See* turbinate.  
 sternum, 23, 30  
*suprasternal*, 25  
 tarsal, 129, 138, 143, 144  
 temporal, 39, 74, 80  
 tibia, 124, 138, 142, 144  
 trapezium, 102, 108, 144  
 trapezoid, 102, 108, 144  
 triquetral, 62  
 turbinate, inferior, 58, 78, 80  
   middle, 49, 72, 80  
   superior, 49, 72, 80  
 turbinate, sphenoidal, 44, 76, 80  
 ulna, 95, 108, 142  
 unciform, 103, 108, 143



BONES—*continued.*

- of upper limb, 86
  - ossification of, 106
- vertebræ. *See* VERTEBRÆ.
- vomer, 55, 77, 80
- Wormian, 62, 74
- Brachial artery. *See* ARTERY.
- ligament, internal, 218, 219
- muscles, 218
- veins, 529
- Brachialis anticus muscle, 220, 222
- Brachio-cephalic (*βραχιών*, arm; *κεφαλή*, head) artery, 388
  - vein, 510, 544
- Brachio-radialis muscle, 229
- Brachium (*βραχιών*, arm), 86
- Brachycephalic (*βραχύς*, short; *κεφαλή*, head) skulls, 84
- Brain, veins of, 519
- Branchial (*βράγχια*, gills) arches, 81
- Breast-bone, 23
- Bregma (*βρέγμα*, upper part of head), 83
- Brim of true pelvis, 115
- Bronchial (*βρόγχος*, windpipe) arteries, 454, 508
  - lymphatic glands, 555
  - veins, 532
- Buccal (*bucca*, mouth) artery, 405
  - fat-pad, 293
  - veins, 515
- Buccinator (*buccina*, trumpet) muscle, 286, 288, 350
- Bucco-pharyngeal fascia, 307
- Bulb, of jugular vein, 518
  - of urethra, artery of, 479
- Bulbar arteries, 421
- Bulbo-cavernosus muscle, 345
- Bursæ, synovial, or bursæ mucosæ, 202

- CALCAR (spur) femorale, 123
- Calcaneo-cuboid articulation, 193
- Calcaneo-navicular ligaments, 192
- Calcaneal arteries, 498
- Calcaneum (belonging to the heel, from *calca*, heel). *See* Os Calcis.
- Calvaria (skull-cap), 68
- Canal, of bone, 4
  - carotid, 42, 68, 70
  - crural or femoral, 243
  - dental, anterior, 51
    - inferior, 59
    - middle, 51
    - posterior, 50, 65
  - Eustachian, 42
  - Hunter's, 254, 256, 487
  - incisor, 52
  - infraorbital, 51, 63, 77
  - malar, 56, 63, 64
  - neural, 6
  - orbital, internal, 38, 49, 64, 69
  - palatine accessory, 54, 67
    - anterior, 52
    - posterior, 51, 54, 67
  - palato-maxillary, 51, 54, 67
  - pterygoid, 47
  - pterygo-palatine, 47, 54, 65
  - sacral, 15
  - spinal, 6
  - temporal, of malar bone, 56, 64
  - Vidian, 47, 65, 70
- Canaliculus innominatus*, 47
- Canine fossa, 50, 63

- Caninus muscle, 286
- Capitellum or capitulum (dim. of *caput*, head), 4
  - of humerus, 94
  - of rib, 26
- Capitular processes of dorsal vertebræ, 23
- Capsular arteries, 465
  - ligament of hip, 182
  - of knee, 187
  - of shoulder, 166
  - vein, 535
- Capsule of Tenon, 292
- Caput (head) of bone, 4
- Cardiac (*καρδία*, heart) lymphatic glands, 555
  - See also* HEART.
- Cardinal vein, 544
- Carotico-clinoid foramen*, 47
- Carotid (*καρωτίδες ἀρτηρίαι*, from *κάρω*, cause sleep; also said to be from *κάρω*, head; *ὄδς*, ear) artery, common, 388, 504
  - external, 390, 393, 504
  - internal, 390, 407, 504
- canal, 42, 68, 70
- foramen, 42
- gland, 391
- plexus of veins, 526
- sheath, 298, 391
- triangle, 391
- Carpal (*καρπός*) arches, arterial, 445, 449, 450, 507
  - arteries, 444, 449, 450
  - articulations, 173
- Carpalia, 143
- Carpo-metacarpal articulations, 175
- Carpus (*καρπός*, wrist), bones of, 100
  - homologies of, 143
  - ossification of, 108
  - compared with tarsus, 143
  - ligaments of, 173
- Cartilage (*cartilago*) of ribs, 28
  - connections of, 160
  - varieties of, 29
- See* Fibro-cartilage.
- Cava. *See* Vena cava.
- Cavernous sinus, 523
- Cavity, cotyloid, 4, 115
  - cranial, 68
  - glenoid, 4, 90
  - nasal, 71
  - sigmoid of radius, 99
  - of ulna, 95
- Cells, ethmoidal, 48, 72
- Central artery of retina, 408
  - point of perineum, 342
  - system of cerebral arteries, 413, 415
  - tendon of diaphragm, 324
  - vein of retina, 524
- Centrale*, 103, 143
- Centrum of vertebræ, 5, 21
- Cephalic (*κεφαλή*, head) index, 84
- Cephalic (from Arabic *al-kifal* in Avicenna-Hyrtl) vein, 528, 546
- Ceratohyals (*κέρας*, horn; *hyoid*), 80
- Cerebellum, arteries of, 421, 423
  - veins of, 520
- Cerebral arteries, 411, 412, 413, 423
  - veins, 519, 520
- Cervical (*cervix*, neck) arteries. *See* ARTERIES.
  - fascia, 296
  - lymphatic glands, 558
  - veins. *See* VEINS.
- Cervical vertebræ, 6
- Cervicalis ascendens muscle, 314

- Cervix (neck) of bone, 4  
 Check ligaments, 156  
 Chest. *See* THORAX.  
 Child, characters of skeleton in, 145  
*Chondro-epitrochlearis muscle*, 209  
 Chondro-glossus (χόνδρος, cartilage; γλῶσσα, tongue) muscle, 304  
 Chondro-sternal articulations, 159  
 Chordæ (χορδή, cord) tendineæ, 359, 360, 362  
 Willisii, 521  
 Choroid arteries, 411, 415, 421  
 vein, 519  
 Ciliary (*cilium*, originally eyelid, transf. to eyelash, and then as adj. *ciliaris* to ciliary body and processes of eye and other structures connected more or less closely therewith) arteries, 408, 409  
 bundle, 281  
 veins, 524  
 Circle of Willis, 412  
 Circular sinus, 523  
 Circumduction, 151  
 Circumflex arteries. *See* ARTERIES.  
 veins. *See* VEINS.  
 Circumflexus palati muscle, 308  
 Clavicle (*clavicula*, dim. of *clavis*, key; probably transl. from κλεῖς, key or bolt, collar-bone), 86  
 homology of, 140  
 ligaments of, 164  
 ossification of, 106  
 Clavicular artery, 432  
 notches of sternum, 25  
 Claviculo-humeral muscle, 275  
*Cleido-hyoid muscle*, 299  
 Cleido-mastoid (κλεῖς, key, or bolt, collar-bone; mastoid) muscle, 298  
 Cleido-occipitalis muscle, 299  
 Clinoid (κλίση, bed; εἶδος, shape) processes, 44, 45, 47  
 Clitoris (κλειτορίς, perhaps from κλείω, enclose), arteries of, 480  
 dorsal vein of, 541  
 Coaptation (*con*, together; *axto*, fit), 151  
 Coccygeal artery, 481  
 Coccygeus muscle, 344  
 Coccyx (κόκυξ, cuckoo), 5, 16  
 articulations of, 178  
 ossification of, 21  
 Cochlea, aqueduct of, 42  
 Cochleariform (*cochlearis*, spoon; *forma*, shape) process, 42  
 Cœliac (κοιλία, belly, from κοῖλος, hollow) artery or axis, 458, 507  
 lymphatic glands, 553  
 Colic (καλόν, colon or large intestine) arteries, 463  
 Colico-spermatie veins, 535  
 Collar-bone, 86  
 Collateral circulation. *See* SURGICAL ANATOMY.  
 intercostal arteries, 456  
 Colles, fascia of, 337  
 Columnæ carneæ, 359, 362  
 Comes nervi ischiadici, 481  
 nervi mediani, 441, 443, 446, 506  
 nervi phrenici, 428  
 Communicating arteries. *See* ARTERIES.  
 Complexus muscle, 316, 319, 347  
 Compressor. *See* MUSCLES  
 Condylar emissary vein, 526  
 foramina, anterior, 33, 68, 71  
 posterior, 33, 71  
 Condylar—*continued*.  
 fossa, posterior, 33  
 portions of occipital bone, 31, 33  
 surfaces of tibia, 124  
 Condylarthrosis (κόνδυλος; ἄρθρον), 149  
 Condyle (κόνδυλος, knuckle), 4  
 Condyles of femur, 121  
 of humerus, 94  
 of lower jaw, 59, 64  
 of occipital bone, 31, 33, 68  
 Condylloid joint, 149  
 Confluence of sinuses, 521  
 Congruent articular surfaces, 150  
 Conjoined tendon, 330  
 Conjugal ligament of ribs, 159  
 Conoid (κωνός, cone; εἶδος, shape) tubercle, 87  
 ligament, 165  
 Constrictor. *See* MUSCLES.  
 Continuous articulation, 147  
 Conus arteriosus, 358  
 Coraco-acromial ligament, 166  
 Coraco-brachialis muscle, 218, 222, 275  
*Coraco-clavicular articulation*, 165  
 Coraco-clavicular ligament, 165  
*Coraco-glenoid ligament*, 167  
 Coraco-humeral ligament, 167  
 muscles, 275  
 Coraco-scapular ligament, 166  
 notch, 90  
 Coracoid (κόραξ, raven; εἶδος, shape) process of scapula, 90, 106, 140  
 Cordiform (*cor*, heart; *forma*, shape) tendon of diaphragm, 324  
 Cornicula (*corniculum*, dim. of *cornu*, horn) of hyoid bone, 61  
 Cornua of coccyx, 16  
 of hyoid bone, 61  
 sacral, 14  
 of saphenous opening, 242  
 sphenoidal, 44  
 Coronary (*corona*, crown) suture, 61  
 Coronary (*corona*, crown) artery of heart, 382  
 of lips, 398  
 of stomach, 458, 507  
 plexuses, 372  
 sinus, 358, 510, 544  
 veins of heart, 509  
 of stomach, 543  
 Coronoid (κοράνη, anything hooked, e.g., the tip of a bow) fossa of humerus, 94  
 process of lower jaw, 60, 64, 78  
 of ulna, 95  
 Corpus Arantii, 364  
 Corpus striatum, veins of, 519, 520  
 Corpus callosum, artery of, 413  
 Corpus cavernosum, artery of, 479  
 Corrugator supercilii muscle, 283, 350  
 Cortical system of cerebral arteries, 413, 415  
 Costæ or ribs, 25, 30  
 Costal cartilages, 25, 28  
 respiration, 325  
 Costo-central articulation, 158  
*Costo-clavicular articulation*, 165  
 Costo-clavicular ligament, 164  
 Costo-coracoid membrane and ligament, 208  
*Costo-coracoid muscle*, 205, 209  
*Costo-fascialis muscle*, 299  
 Costo-transverse articulation, 159  
 Costo-xiphoid ligament, 160  
 Cotyloid (κοτύλη, cup; εἶδος, shape) cavity, 4  
 of hip-bone, 115  
 ligament, 181

- Cotyloid notch, 115  
 Cranial capacity, 82, 83  
     cavity, 68  
     venous sinuses, 521  
 Cranio-facial axis, bones forming, 81  
 Craniometry (*κρανίον*; *μέτρον*, measure), 82  
 Cranium (*κρανίον*, skull), 31. *See* SKULL.  
     lymphatics of, 559  
     venous circulation in, 519  
 Cremaster (*κρεμάω*, suspend), 332  
 Cremasteric artery, 484  
     fascia, 332  
 Crest of bone, 4  
     ethmoidal, 54  
     frontal, 38  
     of ilium, 110  
     incisor, 52  
     infratemporal, 46  
     lachrymal, 57  
     nasal, 52, 53  
     obturator, 113  
     occipital, external and internal, 32, 33  
     pubic, 113  
     sphenoidal, 44  
     supranastoid, 40, 64  
     temporal, 37  
     of tibia, 126  
     turbinate, inferior, 51, 53  
         superior, 54  
 Cribriform (*cribrum*, sieve; *forma*, shape)  
     fascia, 241  
     plate of ethmoid bone, 48, 49, 69, 82  
         of temporal bone, 42, 43  
 Crico-thyroid artery, 395  
     vein, 519  
 Crista talariformis, 43  
     galli (cock's comb), 48, 69  
     terminalis of His, 357  
 Crucial (*crux*, cross) ligaments, 184  
 Cruciform ligament, 155  
 Crura of diaphragm, 323  
 Crural (*crus*, leg) arch, deep, 336  
     canal, 243  
     ring, 336  
     sheath, 243  
 Crureus muscle, 254  
 Cubo-cuneiform articulation, 195  
 Cuboid (*κύβος*, cube; *εἶδος*, shape) bone, 132  
     homology of, 143, 144  
     ligaments of, 193, 194, 195  
     ossification of, 138  
 Cucullaris (*cucullus*, hood) muscle, 203  
 Cuneiform (*cuneus*, wedge; *forma*, shape) bones  
     of foot, 131  
         homology of, 144  
         ligaments of, 195  
         ossification of, 138  
     of hand, 101  
*Curvator coccygis muscle*, 344  
 Curved lines of occipital bone, 32  
 Cutaneous ligaments of phalanges, 235  
 Cuvier, duct of, 353, 510, 513, 544  
 Cylindrical bones, 4  
 Cystic (*κύστις*, bladder) artery, 460  
     vein, 542  
  
 DARTOS (*δαρτός*, skin of scrotum; *δέρω*, flay), 327  
 Deltoid (*δέλτα*, the letter Δ, or delta; *εἶδος*,  
     shape) eminence, 93  
     ligament, 190  
     muscle, 214, 218  
  
*Deltoid tubercle*, 87  
 Dental arteries. *See* ARTERIES.  
     canal, anterior, 51  
         of lower jaw, 58, 59  
         middle, 51  
         posterior, 50, 65  
     foramen, 59  
     veins, 517  
 Dentary nucleus of lower jaw, 78  
 Dentated suture, 147  
 Depressor. *See* MUSCLES.  
 Dermal (*δέρμα*, skin) skeleton, 3  
 Descending thoracic aorta, 380, 454  
 Development of articulations, 150  
*Dextrocardia* (*dexter*, right: more correctly  
     *dextrocardia*, from *δεξιός*, right; *καρδιά*,  
     heart), 386  
 Diaphragm (*διάφραγμα*, partition: from *διά*,  
     across; *φράσσω*, fence in), 322, 347, 349  
     action of, 326  
     pelvic, 344  
 Diaphragma oris, 302  
 Diaphragmatic arteries, 428, 467  
     respiration, 325  
     veins, 535  
 Diaphysis (*διά*, between; *φύω*, grow), 3  
 Diapophysis (*διά*, apart; *apophysis*), 23  
 Diarthrosis (*διάρθρωσις*, moveable articulation,  
     from *διά*, between; *ἄρθρον*, joint), 148  
 Digastric (*δύς*, twice; *γαστήρ*, belly) fossa, 41, 68  
     muscle, 301, 303, 349  
 Digital arteries of foot, 500, 503  
     of hand, 446, 450  
     fossa of femur, 119  
     phalanges, 105, 135  
*Digitus postminimus*, 144  
 Dilator naris, 284  
 Diploe (*διπλός*, double), 68  
     veins of, 525  
 Disc, interpubic, 180  
     intervertebral, 151  
 Discontinuous articulation, 148  
 Dolichocephalic (*δολιχός*, long; *κεφαλή*, head)  
     skulls, 84  
 Dolichopellic (*δολιχός*; *πέλλα*, bowl) pelvis, 118  
 Dorsal arteries. *See* ARTERIES.  
     muscles and fasciæ, 311  
     veins. *See* VEINS.  
     vertebræ, 9  
 Dorso-lateral muscle, 201, 347  
*Dorso-epitrochlearis muscle*, 206, 221  
 Dorsum sellæ (back of saddle), 44, 70  
 Douglas, semilunar fold of, 331  
 Duct, of Cuvier, 353, 510, 513, 544  
     nasal, 51, 57, 72  
     right lymphatic, 546, 548  
     thoracic, 546, 547  
 Ductus arteriosus, 379, 386, 504  
     venosus, 542, 544  
  
 EAR, muscles of, 280  
 Ejaculator urinæ muscle, 345  
 Elbow, veins at bend of, 528  
 Elbow-joint, 170  
 Eminences of bones, 4  
 Eminence, articular, of temporal bone, 41 75  
     deltoid, 93  
     frontal, 37, 82  
     hypothenar, 237  
     ilio-pectineal, 112  
     olivary, 43, 70

- Eminence—*continued*.  
 parietal, 35, 82  
 thenar, 236
- Emissary veins, 526
- Emulgent (*emulgeo*, milk or drain out) arteries, 465  
 veins, 535
- Enarthrosis (*ἐν*, in; *ἄρθρον*, joint), 149
- Endocardium (*ἐνδον*, within; *καρδία*, heart), 367, 373
- Endoskeleton (*ἐνδον*; *skeleton*), 3
- Ensiform (*ensis*, sword; *forma*, shape) process of sternum, 23, 25
- Epaxial (*ἐπί*, on; *axis*) muscles, 201
- Epicardium (*ἐπί*; *καρδία*, heart), 367, 372
- Epicondyle (*ἐπί*, on; *condyle*), 94
- Epicranial (*ἐπί*; *cranium* aponeurosis, 280 muscles, 279, 349
- Epigastric (*ἐπί*; *γαστήρ*, stomach) artery. *See* ARTERY.  
 lymphatic gland, 558  
 veins, 537, 539
- Epiphyal (*ἐπί*; *hyoid* bone) bones, 80, 163
- Epimysium (*ἐπί*; *μῦς*, muscle), 200
- Epiotic (*ἐπί*; *ὄτος*, gen. *ὠτός*, ear) centre, 75
- Epiphysis (*ἐπί*; *φύω*, grow), 4
- Epipterie* (*ἐπί*; *pteron*) bone, 62, 84
- Epirochlea (*ἐπί*; *trochlea*), 94
- Epirochleo-anconeus* muscle, 225
- Erect attitude, adaptation of skeleton to, 145  
 maintenance of, 183, 189, 192
- Erector. *See* MUSCLES.
- Ethmoid (*ἠθμος*, sieve; *εἶδος*, shape) bone, 47, 80  
 ossification of, 76
- Ethmoidal arteries, 409  
 cells or sinuses, 48, 72, 77  
 crest, 54  
 notch, 36  
 process, of inferior turbinate bone, 58  
 spine, 44  
 veins, 524
- Ethmoturbinals, 49, 80
- Eustachian canal, 42  
 tube, groove for, 46, 68  
 valve, 358, 534
- Eversion, of foot, 198  
 of ribs, 161
- Exoccipitals, 73, 79
- Exoskeleton (*ἐξω*, without; *skeleton*), 3
- Expiration, mechanism of, 326
- Extension, 151
- Extensor. *See* MUSCLES.
- Extrinsic muscles of limbs, 201  
 of tongue, 303
- Eyeball, movements of, 291  
 muscles of, 289
- Eyelids and eyebrows, muscles of, 281
- FACE, bones of, 31  
 lymphatics of, 559  
 muscles of, 281, 283, 285, 349
- Facial artery, 396, 403, 505  
 veins. *See* VEINS.
- Falciform (*falc*, sickle or scythe; *forma*, shape)  
 border of saphenous opening, 242  
 crest, 43  
 process of great sacro-sciatic ligament, 179
- Fallopian, aqueduct of, 42  
 hiatus of, 42, 70
- False ribs, 25  
 vertebræ, 5
- FASCIA (band), 202  
 abdominal, 327, 336  
 anal, 339  
 of arm, 218  
 axillary, 208  
 of back, 203  
 bucco-pharyngeal, 307  
 cervical, deep, 296  
 of Colles, 337  
 cremasteric, 332  
 cribriform, 241  
 deep, 202  
 dorsal, of foot, 268  
 of trunk, 313  
 endothoracic, 320  
 of forearm, 222  
 of hand, 222, 235  
 of head and neck, 278, 296  
 of hip and thigh, 241  
 iliac, 337, 347  
 of fascia lata, 242  
 infundibuliform, 337  
 intercolumnar, 329  
 lata (broad fascia), 241  
 of leg, 257  
 lumbar, 203, 313, 333, 337, 347  
 masseteric, 293  
 of neck, 296  
 obturator, 339  
 of orbit, 292  
 of palm, 235  
 parotid, 293, 296  
 pectineal, 242  
 of pectoral region, 208  
 pelvic, 339  
 perineal, 337  
 deep, 338  
 plantar, 268  
 prevertebral, 298  
 pubic of fascia lata, 242  
 of pyriformis, 339  
 recto-vesical, 339, 347  
 of Scarpa, 242, 327  
 semilunar, 219  
 of shoulder, 214  
 of sole, 268  
 spermatic, 329  
 subpubic, 338  
 superficial or subcutaneous, 202  
 temporal, 64, 293  
 of Tenon, 292  
 of thigh, 241  
 transversalis, 336, 347  
 triangular, 329  
 of trunk, anterior, 208  
 posterior, 203  
 morphology of, 347  
 of upper limb, 203
- Fat, subpericardial, 353, 373
- Fat-pad, buccal, 293
- Fauces (throat), isthmus of, 307  
 pillars of, 307
- Femoral (*femur*, thigh) artery. *See* ARTERY.  
 canal, 243  
 glands, 549  
 ligament, 242  
 muscles, anterior, 251  
 internal, 255  
 posterior, 250  
 sheath, 243  
 vein, 539
- Femoro-tibial index, 127

- Femur**, 118  
artery of, 491  
compared with humerus, 142, 144  
ossification of, 137
- Fibro-cartilage**, of heart, 367  
interarticular, acromio-clavicular, 165  
of knee, 185, 186  
of lower jaw, 163  
radio-ulnar or triangular, 169  
scapulo-clavicular, 165  
sterno-clavicular, 164
- Fibro-plate**, 150
- Fibrous pericardium**, 352  
rings of cardiac orifices, 368
- Fibula** (brace, clasp), 127, 142  
artery of, 497  
ossification of, 138
- Fibular artery**, superior, 502
- Fibulare**, 143
- Fingers**, bones of, 105  
movements of, 176  
transverse ligament of, 235
- Fissura sterni**, 25
- Fissure of bone**, 4  
of Glaser, 41, 42, 43  
incisor, 77  
petro-basilar, 68  
petro-sphenoidal, 68  
petro-squamous, 42  
pterygo-maxillary, 65  
sphenoidal, 47, 63, 70  
spheno-maxillary, 63, 65
- Flat bones**, 4
- Flexion**, 151
- Flexor**. See **MUSCLES**.
- Floating ribs**, 25
- Floccular fossa**, 75
- Flower**, homologous parts of scapula and ilium, 141, 145  
ossification of temporal bone, 75
- Fold**, vestigial, of Marshall, 353
- Fontanelles** (*fons*, fountain), 74, 82
- Foot**, arteries of, dorsal, 502, 507  
plantar, 498, 507  
articulations of, 192  
bones of, 110, 129  
compared with hand, 143  
in infant, 140  
ossification of, 138  
fascia of, 268  
muscles of, 268
- Foramen** (*foro*, pierce) of bone, 4  
cæcum of frontal bone, 38, 69  
*carotico-clinoid*, 47  
carotid, 42, 68  
centrale cochleæ, 43  
dental, inferior, 59  
incisor, 52, 72  
infraorbital, 50, 63  
*intercondylar*, 95  
*interventricular*, 365  
jugular, 68, 71  
*jugulare spurium*, 524  
lacrimum anterius, 70  
medium, 68, 70  
orbitale, 63  
posterius, 71  
magnum, 31, 68, 71, 82  
mastoid, 41, 71  
mental, 58, 63  
obturator, 110, 115  
occipital, 31, 68, 71
- Foramen**—*continued*.  
optic, 47, 63, 70  
ovale of hip-bone, 115  
of sphenoid, 47, 65, 70  
parietal, 35, 68  
quadratum, 324  
rotundum, 47, 65, 70  
sacro-sciatic, great and small, 179, 180  
singulare, 43  
spheno-palatine, 55, 67, 72  
spinal, 6, 7, 10, 12  
spinosum, 47, 65, 70  
*sternal*, 25, 31  
stylo-mastoid, 42, 68  
supraorbital, 37, 63, 64  
*supratrochlear*, 95  
thyroid, 115  
of a vertebra, 6  
vertebrarterial, 6, 23  
of *Vesalius*, 47, 526
- Foramina**, condylar, anterior, 33, 68, 71  
posterior, 33, 71  
of diaphragm, 324  
of ethmoid bone, 49, 69  
intervertebral, 5  
sacral, anterior, 14  
posterior, 14  
of Scarpa, 52  
of Stensen, 52  
of Thebesius, 358
- Forearm**, aponeurosis of, 222  
arteries of, 442, 447  
bones of, 95  
articulations of, 169  
compared with leg, 142  
ossification of, 107  
muscles and fasciæ of, 222  
veins of, 527
- Fossa acetabuli**, 115  
anterior palatine, 52, 67  
of bone, 4  
canine, 50, 63  
coronoid, 94  
digastric, 41, 68  
digital, 119  
glenoid of temporal bone, 40, 64, 75  
guttural, 67  
*hypotrochanterica*, 123  
iliac, 111  
incisor of lower jaw, 58  
of upper jaw, 50, 62  
infraclavicular, 87  
infraspinous, 88  
infratemporal, 64  
intercondylar, 121  
jugular, 42  
lacrimal, 37, 64  
myrtiform, 50, 62  
navicular, 47  
olecranon, 94  
ovalis, of heart, 357  
parietal, 35  
pituitary, 43  
posterior condylar, 33  
pterygoid, 46, 68  
radial, 94  
scaphoid, 47  
spheno-maxillary, 65  
subscapular, 88  
supraclavicular, 87  
supraspinous, 88  
temporal, 64

- Fossa.—*continued.*  
 trochanteric, 119  
 trochlear, 37  
 zygomatic, 64, 68
- Fossæ, nasal, 71, 82  
 occipital, superior and inferior, 33  
 Pacchionian, 36, 68  
 of skull, internal, 68.
- Fovea ovalis, 357  
*Foveola coccygea*, 178
- Frontal (*frons*, forehead) artery. *See* ARTERY.  
 bone, 36, 80  
 ossification of, 74  
 crest, 38  
 emiunence, 37, 82  
 process of malar bone, 56  
 sinus, 38, 72, 73, 74, 82  
 sulcus, 38  
 suture, 39, 74  
 vein, 513  
 of diploe, 525
- Frontalis muscle, 280
- Fronto-parietal suture, 61  
*Fronto-temporal suture*, 84
- Fundiform (*funda*, sling) ligament, 258
- Furrow, auriculo-ventricular, 355  
 of bone, 4  
 interventricular, 356  
 spinal, 18
- GALEN, veins of, 519
- Ganglia of cardiac nerves, 372
- Gasserian ganglion, depression for, 42
- Gastric (*γαστήρ*, stomach) arteries, 461  
 lymphatic glands, 553  
 veins, 543
- Gastrocnemius (*γαστήρ*, belly; *κνήμη*, leg)  
 muscle, 262, 267, 273
- Gastro-duodenal artery, 460, 507
- Gastro-epiploic (*γαστήρ*; *ἐπίπλοον*, omentum)  
 arteries, 460, 461, 507, 508  
 veins, 543
- Gemelli (twin) muscles, 248, 275
- Genio-glossus, or Genio-hyo-glossus (*γένειον*,  
 chin; *υοειδής*, hyoid bone; *γλώσσα*,  
 tongue) muscle, 303, 348
- Genio-hyoid muscle, 302, 348
- Genito-urinary muscles, 344
- Gimbernat's ligament, 329
- Ginglymus (*γίγγλυμος*, hinge), 149
- Girdles, shoulder and pelvic, comparison of, 140
- Glabella (dim. of *glabra*, fem. of *glaber*, smooth),  
 37
- Gladiolus (dim. of *gladius*, sword), 25
- Gland, carotid, 391  
 Haversian, 181
- Glands, lymphatic. *See* Lymphatic Glands.
- Glaser, fissure of, 41, 42, 43
- Gleno-humeral ligaments, 167
- Glenoid (*γλήνη*, shallow pit of bone; *εἶδος*,  
 shape) cavity, 4  
 of scapula, 90  
 fossa of temporal bone, 40, 64, 75  
 ligament, 167
- Gliding movement, 151
- Gliding joint, 149
- Gluteal artery, 481, 506  
 lines, 110  
 ridge, 121
- Gluteal veins, 540
- Glutei (*γλουτέες*, buttock) muscles. *See* MUSCLES.
- Gnathic (*γνάθος*, jaw) index, 85
- Gracilis (slender) muscle, 255, 257, 274, 348
- Great sinus of aorta, 381
- Groove, bicipital, 93  
 of bone, 4  
 carotid, 44, 71  
 for Eustachian tube, 46, 68  
 infraorbital, 51, 63  
 lachrymal, 51, 52, 57, 64  
 mylo-hyoid, 59  
 obturator, 113  
 occipital, 41, 68  
 olfactory, 49, 69  
 optic, 43  
 palatine, 67  
 sacral, 14  
 spiral, 93  
 sternal, 25  
 subcostal, 26  
 vertebral, of spinal column, 18  
 of atlas, 8
- Grooved suture, 148
- Grooves for sinuses, 71
- Guttural (*guttur*, throat) fossa, 67
- HÆMAL (*αἷμα*, blood) septum, 347
- Hæmorrhoidal (*αἷμα*; *ρέω*, flow) arteries. *See*  
 ARTERY.  
 plexus of veins, 541  
 veins, 541
- Hamstring muscles, 250
- Hamular (*hamulus*, dim. of *hamus*, hook) pro-  
 cess, of sphenoid bone, 47  
 of lachrymal bone, 57
- Hand, arteries of, 446, 450, 451, 452  
 articulations of, 172  
 bones of, 86, 100  
 ossification of, 108  
 compared with foot, 143  
 movements of, 176  
 muscles and fasciæ of, 235, 240, 276
- Harmonia (*ἁρμονία*—Galen, from *ἁρμόζω*, fit  
 together), 148
- Haunch, 110
- Haversian gland, 181
- Head, bones of, 31  
 homologies of, 79  
 morphology of, 78  
 ossification of, 73  
 typical component parts of, 79
- Head of a bone, 4
- Head and neck, fasciæ and muscles of, 278  
 lymphatics of, 558  
 veins of, 513
- HEART, 351, 354  
 apex of, 354, 367  
 arteries of, 382  
 atria of, 356, 360  
 auricular appendices of, 356, 360  
 auricles of, left, 360  
 right, 356  
 blood vessels of, 371  
 bone of, 368  
 cavities of, 356  
 dimensions and weight of, 374  
 endocardium, 373  
 epicardium, 372  
 fibro-cartilage of, 367  
 fibrous rings of, 368  
 form of, 354

HEART—*continued.*

ganglia of, 372  
 lining membrane of, 373  
 literature of, 375  
 lymphatics of, 371, 372, 373, 555  
 muscular fasciculi of, 368  
 myocardium, 368  
 nerves of, 372  
 openings of, aortic, 362, 364, 367, 375  
     auriculo-ventricular, left, 360, 375  
     right, 358, 375  
     of cardiac veins, 358  
     of coronary sinus, 358  
     of pulmonary artery, 358, 375  
     veins, 360  
     relations of, to wall of thorax, 367  
     tendinous rings of, 368  
 position of, 354, 365  
 serous coat of, 353, 372  
 sinus venosus of, 356, 360  
 size of, 374  
 structure of, 367  
 valves of, aortic, 364  
     auriculo-ventricular, 359, 362, 371  
     bicuspid or mitral, 362, 371  
     Eustachian, 358, 534  
     pulmonary, 360  
     sigmoid or semilunar, 360, 364  
     Thebesian, 358  
     tricuspid, 359, 360, 371  
 veins of, 358, 509  
 ventricles of, left, 361  
     right, 358  
 Hepatic (*ἥπαρ*, liver) artery, 460, 507  
     lymphatic glands, 554  
     veins, 535, 544  
 Hernia (*ἕρως*, branch), lumbar, 329  
 Hiatus (opening, from *hio*, open) aorticus,  
     324  
     Fallopian, 42, 70  
     interossens, 170  
 Highmore, antrum of, 50, 53, 72, 77  
 Hinge-joint, 149  
 Hip-bone, 110, 136, 140  
 Hip-joint, 181  
     ligaments of, 181  
     movements of, 183  
 Hip, muscles of, 243  
 Hip and thigh, fascia of, 241  
 Homologies, Homology (*ὁμός*, same; *λόγος*, pro-  
     portion) of bones of head, 79  
     of carpus and tarsus, 143, 144  
     of hand and foot, 143  
     of muscles, 201  
     of muscles of limbs, 277  
     of scapula and ilium, 140, 145  
     of shoulder and pelvic girdles, 140  
     of upper and lower limbs, 140  
     of vertebrae, 21  
 Humeral artery, 435  
     of acromio-thoracic, 432  
     transverse, 425  
     transverse, ligament, 167  
 Humero-radial index, 99  
 Humerus (shoulder), 91  
     arteries of, 438  
     compared with femur, 142, 143  
     ossification of, 107  
 Hunter's canal, 254, 256, 487  
 Hyo-glossus (*ὑοειδής*, *hyoid* bone; *γλωσσα*,  
     tongue) muscle, 303  
 Hyoid arteries, 394, 395

Hyoid (*υ*, the letter *upsilon*; *εἶδος*, shape) bone,  
     61, 80  
     ossification of, 78  
 Hypapophysis (*ὑπό*, under; *apophysis*), 21, 23  
 Hypaxial (*ὑπό*; *axia*) muscles, 201, 347  
 Hypogastric (*ὑπό*; *γαστήρ*, stomach) artery,  
     471, 473, 506  
 Hypothcnar (*ὑπό*; *θέναρ*, palm) eminence, 237  
 ILEO-COLIC artery, 463  
     lymphatic glands, 553  
 Iliac arteries. *See* ARTERIES.  
     fascia, 337, 347  
     fossa, 111  
     lymphatic glands, 550, 551  
     portion of fascia lata, 242  
     veins. *See* VEINS.  
 Iliacus. *See* MUSCLES.  
 Ilio-aponeurotic muscle, 247  
*Ilio-capsularis* muscle, 245  
 Ilio-costalis muscle, 314  
 Ilio-femoral ligament, 182  
     muscles, 275  
     valve, 539  
 Ilio-lumbar artery, 482  
     ligament, 178  
     vein, 536  
 Ilio-pectineal eminence, 112  
     line, 112, 113  
 Ilio-psoas muscle, 243, 249  
 Ilio-sciatic notch, 110, 114  
 Ilio-tibial band, 242  
 Ilio-trochanteric ligament, 182  
 Ilium (*ἰλία*, flanks), 110  
     homology of, 140, 141, 145  
     ossification of, 136  
 Incisor crest, 52  
     foramen, or canal, 52, 72  
     fissure, 77  
     fossa, lower jaw, 58  
     upper jaw, 50, 62  
     process, of upper jaw, 77  
 Incisura (notch), 4  
     semilunaris, of sternum, 25  
 Incongruent articular surfaces, 150  
 Incus (anvil), 80  
 Index, alveolar, 85  
     antibrachial, 99  
     of breadth of cranium, 84  
     cephalic, 84  
     femoro-tibial, 127  
     gnathic, 85  
     of height of cranium, 84  
     humero-radial, 99  
     nasal, 85  
     orbital, 85  
     pelvic, 118  
     sacral, 15  
     scapular, 91  
 Indicator muscle, 234  
 Infraclavicular fossa, 87  
     lymphatic glands, 556  
 Infrahyoid muscles, 299, 348  
 Infraorbital artery, 406  
     canal, 51, 63, 77  
     foramen, 50, 63  
     groove, 51, 63  
     vein, 517  
 Infrapatellar tendon, 184  
 Infraspinous fossa, 88  
 Infraspinus muscle, 215, 218, 275

- Infrasternal depression or fossa, 25  
 Infratemporal crest, 46, 64  
     fossa, 64  
 Infundibuliform fascia, 337  
 Infundibulum (funnel) of ethmoid bone, 48, 72  
     of right ventricle of heart, 358  
 Inguinal (*inguen*, groin) aperture, external, 328  
     internal, 336  
     lymphatic glands, 548  
 Inion (*ivion*, nape of neck), 84  
 Inlet of true pelvis, 115  
 Innominate artery, 388, 504  
     bone. *See* HIP-BONE.  
     veins, 510, 513, 544  
 Inscriptio tendinæ, 334  
 Insertion of muscles, 200  
 Inspiration, mechanism of, 325  
 Interaccessorii muscles, 318  
 Interarticular fibro-cartilages and ligaments.  
     *See* the various joints.  
     plate, 150  
 Intercavernous sinuses, 523  
 Intercondral articulations, 29, 160  
 Interclavicular notch, 25  
     ligament, 164  
     muscle, 212  
*Interclinoïd ligaments*, 47  
 Intercolumnar fascia and fibres, 329  
 Intercondylar fossa, 121  
     foramen, 95  
 Intercostal aponeurosis, 320  
     arteries, 428, 429, 455, 505, 506  
     lymphatics, 554-555  
     muscles, 319, 349  
     actions of, 325  
     spaces, 30  
     veins, 512, 531  
 Intermaxillary bone, 80  
 Intermedium, 143  
 Intermetacarpal articulations, 175  
 Intermetatarsal articulations, 196  
 Intermuscular septa. *See* Septa.  
 Internodia (*inter*, between; *nodus*, knot), 105  
 Interosseous arteries. *See* ARTERIES.  
     ligaments. *See* LIGAMENTS.  
     muscles, of hand, 238, 240, 276  
     of foot, 272, 274, 276  
     ridge of fibula, 128  
     of tibia, 126  
*Interparietal bone*, 34, 73, 79, 80, 84  
 Interparietal suture, 61  
 Interphalangeal articulations, hand, 176  
     toes, 197  
 Interpubic disc, 180  
 Interspinales muscles, 318, 347  
 Interspinous ligaments, 153, 347  
 Intertransversales muscles, 318, 347, 349  
 Intertransverse ligaments, 154  
 Introchanteric lines, 120  
     ridge, 120  
 Interventricular furrows, 356  
     septum, 365  
 Intervertebral discs, 151  
     foramina, 5  
 Intestinal arteries, 462  
*Intrajugular process*, 34, 71  
 Intrinsic muscles of limbs, 201 275  
 Inversion of foot, 198  
 Irregular or mixed bones, 4  
*Ischio-aponeuroticus muscle*, 25  
 Ischio-capsular ligament, 182  
 Ischio-cavernosus muscle, 344, 346, 349  
 Ischio-femoral muscles, 275  
 Ischium (*ischion*, hip), 113  
     homology of, 140, 144  
     ossification of, 136  
 Isthmus of aorta, 384  
     of fauces, 307  
     Vieussensii, 358  
 JACOBSON'S nerve, foramen for, 43  
 Jaw, lower, 58, 80  
     articulation of, 162  
     changes in, with age, 61, 78, 82  
     movements of, 163  
     muscles of, 293  
     ossification of, 78  
     upper, 50, 80  
     ossification of, 77  
 Joint. *See* ARTICULATION.  
 Joints, movements of bones in, 151  
     various forms of, 147  
 Jugal (*jugum*, yoke) bones, 80  
 Jugular facet of temporal bone, 42  
     foramen, 68, 71  
     fossa, 42  
     lymphatic trunk, 559  
     notch, 34  
     process, 34, 68  
     veins. *See* VEIN.  
*Jugulo-cephalic vein*, 528, 546  
 KIDNEY, lymphatics of, 551  
 Knee-joint, 183  
     movements of, 188  
 Knee-pan, 124  
 LABIAL (*labium*, lip) artery, inferior, 398  
     veins, 515  
 Labyrinth of ethmoid, 48  
 Lachrymal artery, 409  
     bone, 57, 80  
     ossification of, 77  
     crest, 57  
     fossa, 37, 64  
     groove, 51, 52, 57, 64  
     notch, 51  
     process of inferior turbinate bone, 58  
     vein, 524  
 Lacteals (*lac*, milk), 546, 553  
 Lacunæ laterales, 521  
 Lambda (the letter  $\Lambda$ ), 83  
 Lambdoid suture, 61  
 Lamina cribrosa of temporal bone, 42, 43  
 Laminae, or plates of vertebrae, 5, 6, 8, 9, 11, 12  
 Laryngeal arteries, 394, 424  
     lymphatics, 560  
     veins, 519  
*Lateral branch of internal mammary artery*, 429  
 Lateral mass of atlas, 7  
     of ethmoid, 48, 49, 76, 80  
     of sacrum, 14  
     sinus, 522  
     groove of, 33, 34, 41, 71  
 Latissimus dorsi muscle, 205, 208, 213, 274  
 Leg, aponeurosis of, 257  
     bones of, 110, 124, 127, 138, 142  
     muscles of, anterior, 259  
     external, 260  
     posterior, 261  
 Length of long bones of limbs, 94



Lenticular arteries, 413  
 Lenticulo-optic arteries, 413  
 Lenticulo-striate arteries, 413  
 Leptorhine (*λεπτός*, narrow; *ῥίς*, *ῥινός*, nose)  
 skulls, 85  
 Levator. *See* MUSCLES.  
 Ligamenta arcuata, 323  
   subflava, 153  
 LIGAMENTS (*ligo*, bind), accessory, of atlas, 155  
   occipito-atlantal, 157  
   acromio-clavicular, 165  
   alar, 187  
   alar odontoid, 156  
   of ankle, 190  
   annular, 202  
     of ankle, anterior, 258  
       external, 258  
       internal, 258  
     of radius, 169  
     of wrist, anterior, 174, 222  
       posterior, 175, 223  
   arched, of diaphragm, 323  
   astragalo-calcaneal, 192  
   astragalo-navicular, 193  
   atlanto-axial, 157, 158  
   of atlas, transverse, 155  
   of Bigslo, 182  
   of bladder, true, 339  
   brachial, internal, 218, 219  
   calcaneo-cuboid, 194  
   calcaneo-navicular, 192  
   carpal, 173  
   carpo-metacarpal, 175  
   check, 156  
   chondro-sternal, 160  
   of coccyx, 178  
   conjugal, 159  
   conoid, 165  
   coraco-acromial, 166  
   coraco-clavicular, 165  
   coraco-humeral, 167  
   *coraco-glenoid*, 167  
   coraco-scapular, 166  
   costo-central, 158  
   costo-clavicular, 164  
   costo-coracoid, 208  
   costo-transverse, 159  
   costo-xiphoid, 160  
   cotyloid, 181  
   crucial, 184  
   cruciform, 155  
   cubo-cuneiform, 195  
   of cuboid bone, 193, 194, 195  
   of cuneiform bones, 195  
   cutaneous of phalanges, 235  
   deltoid, 190  
   of elbow, 170  
   femoral, 242  
   of foot, 192  
   of forearm, 169  
   fundiform, 258  
   Gimbernat's, 329  
   glenoid, 167  
   gleno-humeral, 167  
   of hand, 173  
   of hip-joint, 181  
   ilio-femoral, 182  
   ilio-lumbar, 178  
   ilio-trochanteric, 182  
   interarticular, chondro-sternal, 160  
     costo-central, 159  
     of hip, 182

LIGAMENTS—*continued*.  
 intercarpal, 173  
 interclavicular, 164  
 interclinoid, 47  
 interosseous, of forearm, 169  
   of leg, 189  
     inferior, 190  
 interspinous, 153, 347  
 intertransverse, 154  
 ischio-capsular, 182  
 of knee-joint, 183  
 lateral lumbo-sacral, 177  
 metacarpal, 175  
   of thumb, 175  
 metacarpo-phalangeal, 176  
 metatarsal, 196  
   transverse, 197  
 metatarso-phalangeal, 197  
 morphology of, 150  
 mucous, 187  
 naviculo-cuboid, 194  
 naviculo-cuneiform, 195  
 oblique, 170  
 obturator, 180  
 occipito-atlantal, 157  
 occipito-axial, 157  
 odontoid, alar, 156  
   middle, 156  
 orbicular, 169  
 palmar, 174, 176  
 palpebral, 281  
 of patella, 184  
   lateral, 187  
 of pelvis, 177  
 petro-sphenoidal, 43, 47  
 of phalanges, fingers, 176  
   cutaneous, 235  
   toes, 197  
 pisi-metacarpal, 174  
 pisi-uncinate, 174  
 plantar, 194  
 Poupart's, 328  
 pterygo-maxillary, 286  
 pterygo-spinous, 47  
 pubic, 180  
 pubo-femoral, 182  
 pubo-prostatic, 339  
 radio-carpal, 172  
 radio-ulnar, 169  
 of rectum, 340  
 rhomboid, 164  
 of ribs, 158  
 round of hip, 182  
 sacro-coccygeal, 178  
 sacro-iliac, 178  
 sacro-sciatic, 179  
 of scapula, 166  
 scapulo-clavicular, 164  
 of shoulder-joint, 166  
 spino-glenoid, 166  
 stellate, 158  
 of sternum, 160  
 sterno-clavicular, 164  
 sterno-pericardial, 352  
 stylo-hyoid, 61, 78, 80, 163  
 stylo-maxillary, 163, 293, 295  
 subpubic, 180  
 suprascapular, 166  
 supraspinous, 154, 347  
 suspensory of axis, 156  
   of eye, 292  
   of penis, 327

LIGAMENTS—*continued.*

- tarsal, 192  
 of eyelids, 281, 283  
 tarso-metatarsal, 195  
 temporo-maxillary, 162  
 tibio-fibular, 189  
 transverse of atlas, 155  
 of acetabulum, 182  
 of fingers, 235  
 humeral, 167  
 of knee, 186  
 metacarpal, 175  
 metatarsal, 197  
 of pelvis, 338  
 of toes, 269  
 trapezoid, 165  
 triangular, of urethra, 338  
 of upper limb, 164  
 vaginal, 228  
 vertebral, 152  
 of wrist, 172
- Ligamentum arcuatum externum, 323  
 arcuatum internum, 323  
 arteriosum, 379  
 breve (of fingers), 228  
 conjugale costarum, 159  
 colli costæ, 159  
 longum (of fingers), 228  
 nuchæ, 154, 347  
 patellæ, 184  
 teres of hip-joint, 182
- Limb, lower, articulations of, 181  
 bones of, 110  
 ossification of, 136  
 fasciæ of, 241  
 lymphatics of, 548  
 muscles of, 241  
 veins of, 536  
 upper, articulations of, 164  
 bones of, 86  
 ossification of, 106  
 fasciæ of, 203  
 lymphatics of, 556  
 muscles of, 203, 274  
 veins of, 526
- Limbs, distinctive characters of, in man, 146  
 homological comparison of, 140  
 homologous bones, tables of, 144  
 homology of muscles of, 277  
 morphology of bones of, 140  
 of muscles of, 274  
 relation to axial skeleton, 140
- Line, of bone, 4  
 curved, of ilium, 110  
 of occipital bone, 31  
 gluteal, 110  
 ilio-pectineal, 112, 113  
 intertrochanteric, 120  
 oblique of lower jaw, external, 58  
 internal, 59  
 of radius, 98  
 of tibia, 126  
 popliteal, 126  
 spiral, of femur, 120, 121  
 supracondylar, of femur, 121  
 of humerus, 93  
 temporal, 35, 64  
 trapezoid, 87  
 white, of pelvic fascia, 340
- Linea alba, 327, 335, 347  
 aspera, 120  
 quadrati, 121
- Linea semilunaris, 335  
 Lineæ transversæ, 335  
 Lingual (*lingua*, tongue) artery, 395, 504  
 lymphatic glands, 560  
 veins, 518  
 Lingula, of lower jaw, 59, 78  
 sphenoidalis, 44, 70, 76  
 Lips, muscles of, 285  
 Liver, lymphatics of, 554  
 Long or cylindrical bones, 4  
 Longissimus dorsi muscle, 314  
 Longus colli muscle, 311, 347  
 Longitudinal sinuses, superior and inferior, 521  
 Lower, tubercle of, 358  
 Lumbar aponeurosis or fascia, 203, 313, 333, 337  
 arteries, 467, 469, 482, 505  
 lymphatic glands, 551  
 veins, 534, 544  
 vertebræ, 11
- Lumbo-sacral ligaments, 177  
 Lumbricales (*lumbrius*, earthworm). *See*  
 MUSCLES.
- Lunar bone, 101  
 homologies of, 143, 144  
 ossification of, 108
- Lungs, lymphatics of, 556  
 Lunula (dim. of *luna*, moon), 364  
 Lymphatic duct, right, 546, 548  
 glands, 546  
 anterior tibial, 550  
 axillary, 556  
 bronchial, 555  
 cardiac, 555  
 cervical, 558  
 cœliac, 553  
 epigastric, 558  
 femoral, 549  
 gastric, 553  
 hepatic, 554  
 ileo-colic, 553  
 iliac, 550, 551  
 inguinal, 548  
 intercostal, 554  
 infraclavicular, 556  
 internal maxillary, 558  
 laryngeal, inferior, 560  
 lingual, 560  
 lumbar, 551  
 mastoid, 558  
 mediastinal, anterior, 554  
 posterior, 555  
 superior, 555  
 mesenteric, 553  
 mesocolic, 553  
 parotid, 558  
 pectoral, 556  
 popliteal, 548  
 prelaryngeal, 560  
 sacral, 551  
 splenic, 553  
 sternal, 554  
 submaxillary, 558  
 suboccipital, 558  
 subscapular, 556  
 suprahyoid, 558  
 of thorax, 554  
 trunk, axillary, 556  
 intestinal, 553  
 jugular, 559  
 lumbar, 551
- LYMPHATICS (*lymphæ*, clear water), Descriptive  
 Anatomy of, 546

LYMPHATICS—*continued.*

of abdominal wall, 550, 551, 553, 557  
 back, 550, 556, 558  
 bladder, 551  
 cranial cavity, 559  
 face, 559  
 head and neck, 558  
 heart, 371, 372, 373, 555  
 intercostal, 555  
 of kidney, 551  
 larynx, 560  
 limb, lower, 548  
     upper, 556  
 liver, 554  
 lungs, 556  
 mamma, 554, 556, 557  
 œsophagus, 556  
 pancreas, 553  
 penis, 550  
 perineum, 550  
 pharynx, 560  
 pia mater, 559  
 prostate, 551  
 rectum, 551  
 scalp, 559  
 serotum, 550  
 spleen, 553  
 stomach, 553  
 suprarenal capsules, 552  
 testicle, 552  
 thorax, 554, 557  
 thymus gland, 556  
 tongue, 560  
 trunk, lower part, 550  
     upper part, 557  
 uterus, 551  
 vagina, 551  
 vas deferens, 551  
 vesicula seminalis, 551  
 vulva, 550

**MALAR** (*mala*, cheek) bone, 55, 80  
 ossification of, 78  
 canal, 56, 63  
 process, 50, 52  
 tuberosity, 55

**Malaris** muscle, 281

**Malleolar** (*malleolus*, ankle; dim. of *malleus*, hammer) arteries, 497, 502

**Malleolus**, external, 127, 138  
 internal, 127, 138

**Malleus** (hammer), 80

**Mamillary** (*mamilla*, nipple) processes of vertebrae, 12

**Mamma** (breast), lymphatics of, 554, 556, 557

**Mammary** artery, external, 432, 435  
 internal, 427, 505  
 vein, internal, 512

**Mandible** (*mandibula* or *mandibulum*, jaw, from *mando*, chew), 58, 78, 80

**Mauubrium** (handle) of sternum, 23, 24, 30

**Manus** (hand), 86

*Marginal process of malar bone*, 56

**Marginal** vein, of limb, 545

**Marrow** of bone, 3

**Marshall**, oblique vein of, 358, 510  
 vestigial fold of, 353

**Masseter** (*μασσάομαι*, chew) muscle, 293, 295, 349

**Masseteric** artery, 405  
 fascia, 293  
 veins, 515

**Mastication**, muscles of, 293

**Mastoid** (*μαστός*, nipple; *είδος*, form) antrum, 75  
 arteries, 399, 401  
 cells, 75  
 emissary vein, 526  
 foramen, 41, 71  
 lymphatic glands, 558  
 portion of temporal bone, 39, 41, 75  
 process, 41, 64, 68, 75, 82

**Maxilla** (jaw), inferior, 58, 78, 80  
 superior, 50, 77, 80

**Maxillary** artery, external, 396  
 internal, 403, 505  
 bone. *See* Maxilla.  
 lymphatic glands, internal, 558  
 process, of palate bone, 54  
     of inferior turbinate bone, 58  
 sinus, 50, 53, 72, 77  
 vein, anterior internal, 515  
 internal, 516

**Maxilloturbinal** bone, 80

**Meatus** (*meo*, pass), 4  
 external auditory, 41, 64, 75  
 internal auditory, 42, 43, 71  
 of nose, 48, 49, 72

**Mechanism** of foot, 197  
 of pelvis, 180

**Meckel's** cartilage, 78

**Median** artery, 441, 443, 446, 506  
 basilic vein, 528  
 cephalic vein, 528  
 line and plane, 1

**Median** (probably from Arabic *al-madjan* = vein of Madjan—Hyrtil) veins, superficial and deep, 527, 528

**Mediastinal** arterial plexus, 428  
 arteries, 428, 455, 508  
 lymphatic glands, 554, 555

**Medulla** (marrow) of bones, 3

**Medullary** arteries. *See* ARTERIES.

**Megacephalic** (*μέγας*, great; *κεφαλή*, head) skulls, 83

**Megaseme** (*μέγας*; *σῆμα*, index) index, 85

**Membrane** bones of head, 80  
 costo-coracoid, 208  
 interosseous, of forearm, 169  
     of leg, 189  
 obturator, 180

**Meningeal** arteries. *See* ARTERIES.  
 grooves, 35, 40, 68, 71  
 veins, middle, 517

**Meniscus** (*μηρίσκος* = lunula, dim. of *μήνη*, moon), 150

**Mental** (*mentum*, chin) artery, 405  
 foramen, 58, 63  
 protuberance, 58  
 spines, 59  
 tubercle, 58

*Mento-hyoid muscle*, 301

**Mesaticephalic** (*μεσαίτατος*, middlemost; *κεφαλή*, head) skulls, 84

**Mesatipellic** (*μεσαίτατος*; *πέλλα*, bowl) pelvis, 118

**Mesenteric** (*μέσος*, middle; *έντερον*, intestine) arteries. *See* ARTERIES.  
 glands, 553  
 veins, 542, 543, 544

**Mesethmoid** (*μέσος*, middle; *ἦθμος*, sieve), 80

**Mesocephalic** (*μέσος*; *κεφαλή*, head) skulls, 83

**Mesocolic** (*μέσος*; *κόλον*, colon) lymphatic glands, 553

**Mesognathous** (*μέσος*; *γάθος*, jaw) skulls, 85

Mesorhine (μέσος; ρίς, ρινός, nose) skulls, 85  
 Mesoscapula, 91  
 Mesoseme (μέσος, middle; σήμα, index) orbital index, 85  
 Mesosternum (μέσος; στέρνον, chest), 25  
 Metacarpal arteries, 444  
 Metacarpo-phalangeal articulations, 176  
 Metacarpus (μετά, beyond; καρπός, wrist), 103  
 articulations of, 175  
 ossification of, 109  
 Metapophysis (μετά; αποφυσις), 12, 23  
 Metasternum (μετά; στέρνον, chest), 25  
 Metatarsal artery, 503  
 Metatarso-phalangeal articulations, 197  
 Metatarsus (μετά; ταρός, instep), 133  
 articulations of, 196  
 ossification of, 138  
 Metopic (μέτωπον, forehead) suture, 39  
 Metopism, 39  
 Microcephalic (μικρός, small; κεφαλή, head) skulls, 83  
 Microseme (μικρός; σήμα, index) orbital index, 85  
 Midriff (Sax. midd, middle; hrif, belly), 322  
 Mitral (from resemblance to a bishop's mitre) valve, 362  
 Mixed bones, 4  
 Moderator band, 360  
 Morphology (μορφή, form; λόγος, discourse), of  
 arterial system, 504  
 of bones of head, 78  
 of limbs, 140  
 of fasciæ of trunk and head, 347  
 of ligaments, 150  
 of muscles, 201  
 of limbs, 274  
 of trunk and head, 347  
 of venous system, 544  
 Mouth, muscles of, 285  
 Movement, various kinds of, 151  
 Movements of ankle-joint, 191  
 of clavicle, 165  
 elbow, 172  
 foot and toes, 197  
 hip, 183  
 knee, 188  
 lower jaw, 163  
 occipito-vertebral, 158  
 of patella on femur, 188  
 pelvis, 180  
 radius on ulna, 170  
 respiration, 325  
 ribs, 161  
 scapula, 165  
 shoulder, 169  
 vertebral column, 154  
 wrist and fingers, 176, 240  
 Mucous ligament, 187  
 Multifidus (multus, many; findo, cleave) spine muscle, 317  
 MUSCLES, Descriptive Anatomy of, 200  
 abductor hallucis, 270, 276  
 indicis, 238  
 longus pollicis, 233  
 minimi digiti manus, 238, 240, 276  
 minimi digiti pedis, 270  
 ossis metatarsi quinti, 271  
 pollicis, 236, 239, 276  
 pollicis pedis, 270  
 accessorius ad ilio-costalem, 314  
 accessorius tricipitis, 221  
 adductor brevis, 255, 257, 274  
 gracilis, 255, 257, 274, 348

## MUSCLES—continued.

adductor hallucis obliquus, 271, 276  
 transversus, 272, 276  
 longus, 255, 257, 274  
 magnus, 256, 257, 275  
 minimus, 257  
 pollicis obliquus, 237, 239, 276  
 pedis, 271  
 transversus, 237, 276  
 agitator cordis, 246  
 amygdalo-glossus, 307  
 anconeus, 221  
 anomalus, 284  
 atlanto-mastoid, 319  
 attollens auriculam, 280, 350  
 attrahens auriculam, 281, 350  
 auricularis, superior, anterior, et posterior, 280, 281  
 azygos pharyngis, 307  
 azygos uvulæ, 308  
 biceps flexor cruris, 250, 251  
 flexor cubiti, 219, 222  
 biverter cervicis, 317  
 brachialis anticus, 220, 222  
 brachio-radialis, 229  
 buccinator, 286, 288, 350  
 bulbo-cavernosus, 345, 346, 349  
 caninus, 286  
 cervicalis ascendens, 314  
 chondro-epitrochlearis, 209, 274  
 chondro-glossus, 304  
 circumflexus palati, 308  
 cleido-hyoid, 299  
 cleido-mastoid, 298, 274  
 cleido-occipitalis, 299  
 coccygeus, 344, 349  
 complexus, 316, 319, 347  
 compressor hemisphaerium bulbi, 345  
 compressor naris, 284, 350  
 urethrae, 345, 346  
 constrictor of pharynx, inferior, 305, 349  
 middle, 306, 349  
 superior, 306, 349  
 isthmi faucium, 307  
 urethrae, 345, 346  
 coraco-brachialis, 218, 222, 275  
 corrugator supercilii, 283, 350  
 costo-coracoidæus, 205, 209  
 costo-fascialis, 299  
 cremaster, 332  
 crureus, 254  
 cucullaris (like a hood), 203  
 curvator coccygis, 344  
 deltoid, 214, 218, 274, 275  
 depressor alæ nasi, 284, 350  
 anguli oris, 287, 350  
 labii inferioris, 287, 350  
 diaphragm, 322. See DIAPHRAGM.  
 diaphragma oris, 302  
 digastric, 301, 349  
 dilatator uaris anterior, 284  
 naris posterior, 284  
 dorso-epitrochlearis, 206, 221, 275  
 ejaculator urinae, 345  
 epitrochleo-anconeus, 225  
 erector clitoridis, 346  
 penis, 344, 346  
 spiurae, 314, 347  
 extensor brevis digitorum manus, 234  
 extensor brevis digitorum pedis, 269  
 brevis hallucis, 269  
 brevis pollicis, 233

MUSCLES—*continued.*

*extensor carpi radialis accessorius*, 230  
*extensor carpi radialis brevior*, 229, 240  
     *intermedius*, 230  
     *longior*, 229, 240  
*carpi ulnaris*, 232, 240  
*coecygis*, 316  
*communis digitorum*, 230, 240  
*iudicis*, 234  
*longus digitorum pedis*, 259, 274  
*longus pollicis*, 234, 240  
*medii digiti*, 234  
*minimi digiti*, 232, 240  
*ossis metacarpi pollicis*, 233, 240  
*ossis metatarsi hallucis*, 259  
*primi internodii hallucis*, 259  
*primi internodii pollicis*, 233  
*proprius hallucis*, 259  
*secundi internodii pollicis*, 234, 240  
*flexor accessorius*, 266, 274  
     *accessorius longus digitorum*, 265  
     *brevis digitorum pedis*, 269, 274  
     *brevis hallucis*, 271, 276  
     *brevis minimi digiti manûs*, 238, 241, 276  
     *brevis minimi digiti pedis*, 272, 276  
     *brevis pollicis*, 236, 239, 241, 276  
     *brevis pollicis pedis*, 271  
     *carpi radialis*, 224, 240  
     *carpi radialis brevis*, 228  
     *carpi ulnaris*, 225, 240  
     *longus digitorum pedis*, 265, 274  
     *longus hallucis*, 266, 274  
     *longus pollicis*, 228  
     *longus pollicis pedis*, 266  
     *perforans digitorum manûs*, 226  
     *perforans digitorum pedis*, 265  
     *perforatus digitorum manûs*, 225  
     *perforatus digitorum pedis*, 269  
     *profundus digitorum*, 226, 240  
     *sublimis digitorum*, 225, 240  
*frontalis*, 280, 350  
*gastrocnemius*, 262, 267, 273  
*gemelli*, 248, 275  
*genio-glossus*, 303, 348  
*genio-hyo-glossus*, 303  
*genio-hyoid*, 302, 348  
*gluteo-perinealis*, 344  
*gluteus maximus*, 245, 249, 274  
     *medius*, 246, 250, 275  
     *minimus*, 246, 250, 275  
*gracilis*, 255, 257, 274, 348  
*hyo-glossus*, 303  
*iliacus*, 243, 249, 275  
     *minor*, 245  
*ilio-aponeurotic*, 247  
*ilio-capsularis*, 245  
*ilio-costalis*, 314  
*ilio-psoas*, 243, 249  
*incisivus inferior*, 288  
     *superior*, 288  
*indicator*, 234  
*infraspinatus*, 215, 218, 275  
*interclavicular*, 212  
*intercostals*, 319, 349  
     *action of*, 325  
*interosseous*, of hand, 238, 240, 276  
     of foot, 272, 274, 276  
*interspinales*, 318, 347  
*intertransversales*, 318, 347, 349  
*ischio-aponeuroticus*, 251  
*ischio-cavernosus*, 344, 346, 349

VOL. II.

MUSCLES—*continued.*

*labii proprius*, 288  
*latissimus dorsi*, 205, 208, 213, 274, 347, 349  
*levator anguli oris*, 286, 350  
     *anguli scapulae*, 207, 208, 213, 274, 349  
     *ani*, 343, 349  
     *claviculae*, 208  
     *coecygis*, 344  
     *labii inferioris*, 287  
     *labii superioris proprius*, 285, 350  
     *labii superioris alaeque nasi*, 284, 350  
     *menti*, 287, 350  
     *palati*, 308, 349  
     *palpebrae superioris*, 283, 289, 340  
     *proprius alae nasi anterior*, 284  
         *posterior*, 284  
*levatores costarum*, 320, 326, 349  
     *longiores costarum*, 321  
*longissimus dorsi*, 314  
*longus colli*, 311, 347  
*lumbrales of hand*, 227, 229, 240  
     of foot, 266, 273, 274  
*malaris*, 281  
*masseter*, 293, 295, 349  
*mento-hyoid*, 301  
*multifidus spinæ*, 317  
*mylo-glossus*, 304  
*mylo-hyoid*, 302, 349  
*naso-labialis*, 288  
*oblique*, of eye, inferior, 290, 348  
     superior, 290, 348  
*obliquus inferior accessorius*, 291  
*obliquus externus abdominis*, 327, 349  
     *internus abdominis*, 329, 349  
     *capitis inferior*, 319, 348  
         *superior*, 319, 348  
*obturato-coecygeus*, 344  
*obturator externus*, 249, 275  
     *internus*, 248, 275  
*occipitalis*, 279, 350  
     *occipitalis minor*, 296, 350  
*occipito-frontalis*, 279  
*occipito-pharyngeus*, 307  
*omo-hyoid*, 300, 303, 348  
*opponens hallucis*, 271  
*opponens minimi digiti manûs*, 238, 240, 276  
     *minimi digiti pedis*, 272  
     *pollicis*, 236, 240, 276  
*orbicularis oris*, 287, 350  
     *palpebrarum*, 281, 350  
*palato-glossus*, 307, 349  
*palato-pharyngeus*, 307, 349  
*palmaris brevis*, 235, 239, 241  
     *longus*, 224, 241  
*pectineus*, 255, 257, 275  
*pectoralis major*, 208, 213, 274, 348, 349  
     *minimus*, 211  
     *minor*, 209, 213, 274, 349  
*peroneo-calcaneus externus*, 261  
     *internus*, 267  
*peroneo-cuboides*, 261  
*peroneo-libialis*, 264  
*peroneus accessorius*, 261  
*peroneus brevis*, 261, 274, 276  
     *longus*, 260, 274, 276  
     *quartus*, 261  
     *quinti digiti*, 261  
     *tertius*, 260, 273  
*petro-pharyngeus*, 307  
*pharyngo-mastoides*, 307  
*psi-annularis*, 240

P P

MUSCLES—*continued.*

*pisi-metacarpeus*, 240  
*pisi-uncinatus*, 240  
 plantaris, 264  
 platysma myoides, 286, 295, 350  
 popliteus, 264, 273, 275  
*popliteus minor*, 264  
 pronator radii quadratus, 228  
 pronator radii teres, 223, 240, 275  
 psoas magnus, 243, 249, 274  
   *parvus*, 245  
 pterygoid, external, 294, 349  
   internal, 294, 349  
*pterygoideus proprius*, 295  
*pterygo-pharyngeus externus*, 307  
*pterygo-spinosus*, 295  
*pubo-coccygeus*, 343  
*pubo-transversalis*, 333  
 pyramidalis abdominis, 335, 348  
 pyramidalis nasi, 283, 350  
 pyriformis, 248, 249, 250, 275  
 quadratus femoris, 249, 250, 275  
   lumborum, 335, 348, 349  
   menti, 287  
 quadriceps extensor cruris, 252  
*radio-carpeus*, 228  
 recti of eye, 289, 348  
 rectus abdominis, 333, 348  
   *abdominis lateralis*, 348  
   capitis anticus major, 310, 347  
   capitis anticus minor, 311  
   capitis lateralis, 311  
   capitis posticus major, 319, 347  
   capitis posticus minor, 319, 347  
   femoris, 252  
 retrahens auriculam, 281, 350  
*rhombo-alloideus*, 314  
 rhomboideus major, 206, 208, 213, 274, 347  
   minor, 206, 208, 213, 274, 347, 349  
*rhomboideus occipitalis*, 207  
 risorius, 286, 350  
 rotatores dorsi, 317  
   *longi*, 317  
 sacci lachrymalis, 283  
*sacro-coccygeus anticus*, 344, 347  
   *posticus*, 316, 348  
 sacro-lumbalis, 314  
 salpingo-pharyngens, 308  
 sartorius, 251, 254, 275  
 scalenus anticus, 309, 349  
   medius, 310, 349  
   *pleuralis*, 310  
   posticus, 310  
*scansorius*, 247  
 semimembranosus, 251  
 semispinalis capitis, 316  
   colli, 317  
   dorsi, 317  
 semitendinosus, 250  
 serratus magnus, 212, 213, 274, 349  
   posticus inferior, 313, 347, 349  
   posticus superior, 312, 347, 349  
 solens, 263, 267, 273  
*spheno-pharyngeus*, 307  
 sphincter ani, external or superficial, 341, 346  
   internal or circular, 341  
   colli, 350  
   vaginae, 346  
*spinalis cervicis*, 316  
 spinalis dorsi, 316  
 splenius capitis, 313, 319, 347  
   *accessorius*, 314

MUSCLES—*continued.*

splenius colli, 313, 319, 347  
   *accessorius*, 314  
 stapedius, 349  
*sternalis*, 209  
*sterno-claviculæ*, 212  
 sterno-cleido-mastoid, 298, 349  
 sterno-hyoid, 299, 348  
 sterno-mastoid, 298  
*sterno-scapular*, 212  
 sterno-thyroid, 299, 348  
*stylo-auricularis*, 304  
 stylo-glossus, 304  
 stylo-hyoid, 301, 349  
*stylo-hyoides alter*, 302  
 stylo-pharyngens, 307, 309, 349  
*subanconeus*, 221  
 subclavius, 211, 213, 274  
 subcostal, 321, 349  
 subcrureus, 254  
 subscapularis, 217, 218, 275  
   *minor*, 218  
*subscapulo-capsularis*, 218  
 spinator radii brevis, 232, 235, 240  
   longus, 229, 235, 240, 276  
*supraclaviculæ*, 299  
   *proprius*, 299  
*supracostalis*, 320  
 supraspinatus, 214, 218, 275  
*syndesmo-pharyngeus*, 306  
 temporal, 294, 349  
 tensor palati, 308, 349  
   tarsi, 283  
   tympani, 349  
   vaginae femoris, 247, 250  
*tensor of capsule of ankle*, 267  
   *fasciæ suralis*, 251  
   *plæce alaris*, 214  
   *trochleæ*, 291  
 teres major, 216, 218, 274  
   minor, 215, 218, 275  
 thyro-hyoid, 299, 348  
 tibialis anticus, 259, 260, 273  
   posticus, 267, 273  
*tibialis secundus*, 267  
*tibio-fascialis anticus*, 259  
 trachelo-mastoid, 316  
 transversalis abdominis, 332, 349  
   capitis, 316  
   cervicis, 316  
   *anticus*, 311  
   *dorsi*, 316  
 transverso-spinales, 316, 347  
*transversus menti*, 287, 350  
   *nuchæ*, 299  
   *orbitæ*, 291  
 transversus pedis, 272  
   perinei, 344, 346, 349  
   profundus, 345, 346  
   thoracis anterior, 322  
   posterior, 321  
 trapezius, 203, 208, 213, 274, 347, 349  
 triangularis menti, 287  
 sterni, 322, 349  
 triceps extensor cubiti, 221  
   suræ, 264  
*tritico-glossus*, 304  
 trochlearis, 290  
*ulnaris quinti digiti*, 232  
 vastus externus, 253  
   internus, 254  
 Wilson's, 345

MUSCLES—*continued.*

- zygomaticus major, 286, 350  
 minor, 286, 350
- MUSCLES of abdomen, 327  
 action of, 336
- anal, 341, 346
- of arm, upper, 218  
 action of, 222
- auricular, 280, 349, 350
- of back, 311  
 action of, 319
- claviculo-humeral, 275
- coraco-humeral, 275
- cranio-vertebral, short posterior, 318
- dorsal, 311
- dorso-lateral (morphol.), 201, 347
- epicranial, 279, 349  
 action of, 280
- of eyelids and eyebrows, 281  
 action of, 283
- of face (morphol.), 349
- femoral, anterior, 251  
 action of, 254  
 internal, 255  
 action of, 257  
 posterior, 250  
 action of, 251
- of foot, 268  
 action of, 273
- of forearm, 223  
 action of, 240
- genito-urinary, 344, 346
- hamstring, 250
- of hand, 235  
 action of, 240  
 varieties of, 239
- of head and neck, 278
- of hip, 243  
 action of, 249
- of hyoid bone, 299  
 action of, 303
- hypaxial (morphol.), 201, 347
- ilio-femoral, 275
- infrahyoid, 299, 348
- ischio-femoral, 275
- lateral (morphol.), 347
- of leg, anterior, 259  
 external, 260  
 posterior, 261  
 action of, 273
- of limb, lower, 241, 274  
 upper, 203, 274
- of limbs, morphology of, 274  
 table of homologies of, 277
- of little finger, 237
- of lips and mouth, 285, 350  
 action of, 288
- of mastication, 293, 349  
 action of, 295
- of neck, anterior, 298  
 action of, 302  
 lateral and pervertebral, 309  
 action of, 311
- of nose, 283  
 action of, 284
- of orbit, 289, 348  
 action of, 291
- of palate, 307  
 action of, 309
- of perineum, 341, 349  
 action of, 346
- of pharynx, 305

MUSCLES—*continued.*

- of pharynx, action of, 309
- prevertebral, 310
- pronators and flexors, 223  
 action of, 240
- pubo-femoral, 275
- scapulo-humeral, 275
- of shoulder, 214  
 action of, 218
- of sole, 269
- suboccipital, 318, 347
- subvertebral (morphol.), 201, 347
- supinators and extensors, 229  
 action of, 240
- suprahyoid, 301
- of thigh, 250
- of thorax, 319  
 action of, 325
- of thumb, 236  
 action of, 241
- of tongue, 303, 348  
 action of, 304
- of trunk, 311
- of trunk and upper limb, anterior, 208  
 posterior, 203  
 action of, 213
- ventro-lateral (morphol.), 201, 348
- Musculi papillares, 359, 362  
 pectinati, 357, 360
- Musculo-phrenic artery, 428
- Mylo-glossus* (μύλη, mill, jaw ; γλωσσο, tongue)  
*muscle*, 304
- Mylo-hyoid artery, 404  
 groove, 59  
 muscle, 302, 349  
 ridge, 59
- Myocardium (μῦς, muscle ; καρδία, heart), 367,  
 368, 371, 372
- Myocoma (μῦς ; κόμμα, piece, from κόπτω, cut  
 off), 201
- Myoides. *See* Platysma.
- Myology (μῦς ; λόγος, discourse), 199
- Myomere (μῦς ; μέρος, part), 201
- Myotome (μῦς ; τέμνω, divide), 201
- Myrtiform (μύρτον, myrtle-berry ; *forma*, shape)  
 fossa, 50
- NARES (nostrils), posterior, 68
- Nasal (*nasus*, nose) aperture, anterior, 62  
 arteries, 398, 406, 410, 411  
 bone, 56, 80  
 ossification of, 77  
 crest, 52, 53, 57, 71  
 duct, 51, 57, 72  
 fossæ, or cavities, 71, 82  
 index, 85  
 notch. *See* Notch.  
 point, 83  
 process. *See* Process.  
 spine. *See* Spine.  
 veins, 514
- Nasion, 83
- Naso-palatine artery, 406
- Navicular (*navicula*, small ship or boat) bone of  
 foot, 131, 138  
 articulations of, 192, 194, 195  
 homology of, 144  
 fossa, 47
- Naviculo-cuboid articulation, 194
- Naviculo-cuneiform articulation, 195
- Neck, of a bone, 4

- Neck, fasciæ of, 296  
 lymphatics of, 558  
 muscles of, anterior, 298  
   lateral and prevertebral, 309  
 veins of, 513
- Nerves of heart, 372
- Neural (*νεῦρον*, nerve) anastomoses, 505  
 arches of vertebræ, 5, 21  
 canal, 6  
 septum, 347  
 spines of vertebræ, 5, 21
- Neuro-central synchondrosis, 19
- Nodus Arantii, 364
- Nose, arteries of, 398, 406, 410  
 cavities or fossæ of, 71, 82  
 meatuses of, 48, 51, 53, 72  
 muscles of, 283  
 septum of, 71  
 veins of, 514, 517
- Notch, acromio-scapular, 90  
 of bone, 4  
 clavicular, 25  
 coraco-scapular, 90  
 cotyloid, 115  
 ethmoidal, 36  
 ilio-sciatic, 110, 114  
 interclavicular, 25  
 intercondylar, 121  
 jugular, 34  
 lachrymal, 51  
 nasal, of frontal bone, 37  
   of upper jaw, 50  
 popliteal, 126  
 pterygoid, 47  
 sacro-sciatic, 116  
 scapular, great, 90  
 sciatic, 110, 114  
 sigmoid, 59  
 spheno-palatine, 55  
 supraorbital, 37, 63, 64  
 suprascapular, 90  
 suprasternal, 25
- Notches of vertebræ, 5
- Nucha (from Arabic *nugrah*, hollow at nape of neck—Hyrthl), ligament of, 154
- Number of bones, 4  
 of muscles, 199
- OBELION (*ὀβελίος*, arrow; *ὀβελία βραχί*, sagittal suture), 83
- Oblique ligament, 170  
 lines, of lower jaw, 58, 59  
   of radius, 98  
   of tibia, 126  
 sacro-sciatic ligament, 179  
 vein of Marshall, 358, 510, 544
- Obliquus. *See* MUSCLES.
- Obturator-coecygeus muscle, 344
- Obturator (*ὀβτιν*, stop up) artery, 475, 506  
 relation to hernia, 477  
 crest, 113  
 groove, 113  
 fascia, 339  
 foramen, 110, 115  
 membrane or ligament, 180  
 muscles, 248, 249, 275  
 vein, 540
- Occipital (*occiput*, back of head) artery. *See* ARTERY.  
 bone, 31, 79  
 ossification of, 73
- Occipital—*continued*.  
 crest, external and internal, 32, 33  
 emissary vein, 526  
 foramen, 31, 68, 71  
 fossæ, 33  
 groove, 41, 68  
 lymphatics, 559  
 point, 83  
 protuberances, 31, 33  
 sinus, 523  
 veins, 517  
   of diploe, 526
- Occipitalis. *See* MUSCLES.
- Occipito-atlantal ligaments, 157
- Occipito-axial ligaments, 157
- Occipito-frontal aponeurosis, 280
- Occipito-frontalis muscle, 279
- Occipito-mastoid suture, 62
- Occipito-parietal suture, 61
- Occipito-pharyngeus muscle*, 307
- Odontoid (*ὀδόντος*, gen. *ὀδόντος*, tooth; *εἶδος*, shape) ligaments, 156  
 process of axis, 8, 20, 21
- Œsophageal arteries, 424, 454, 459, 467, 507
- Œsophagus, foramen for, in diaphragm, 324  
 lymphatics of, 556
- Olecranon (*ὀλέκρνον*, point of elbow: from *ὀλένη*, elbow; *κρῆνιον*, head), 95  
 fossa of, 94
- Olfactory groove, 49, 69
- Olivary eminence, 43, 70
- Omo-hyoid (*ὀμος*, shoulder; *hyoid* bone) muscle, 300, 303, 348
- Omphalo-mesenteric (*ὀμφαλός*, navel; *mesentery*) artery, 463  
 veins, 544
- Ophryon (*ὄφρυς*, eyebrow), 83
- Ophthalmic (*ὀφθαλμός*, eye) artery, 408  
 veins, 524
- Opisthion (*ὀπισθίος*, hinder), 84
- Opisthotic (*ὀπισθεν*, behind; *ὀς*, gen. *ὀτός*, ear) portion of temporal bone, 75
- Opponens. *See* MUSCLES.
- Optic foramen, 47, 63, 70  
 groove, 43
- Orbicular ligament, 169
- Orbicularis. *See* MUSCLES.
- Orbit (*ὀρβίτα*, circle), 63  
 fasciæ of, 292  
 muscles of, 289, 348
- Orbital arch, 37  
 artery, 403, 404  
 canals, internal, 38, 49, 64, 69  
 index, 85  
 plate. *See* Plate.  
 process. *See* Process.  
 vein, 515  
 wing of sphenoid, 45, 76, 80
- Orbitosphenoid, 76, 80
- Origin of muscles, 200
- Orthognathous (*ὀρθός*, upright; *γνάθος*, jaw) skulls, 85
- Os acetabuli, 136  
 calcis, 129  
 articulations of, 192, 193  
 homology of, 144  
 ossification of, 138  
 centrale, 103, 143  
 cordis, 368  
 coxæ (bone of hip), 110  
 innominatum, 110  
 linguae, 61



Os—*continued.*

- magnum, 102, 108  
 homology of, 144  
 planum, 48  
 pubis, 110  
 homology of, 140, 144  
 ossification of, 136  
*trigonum*, 133, 144  
 unguis, 57  
*Ossa suprasternalia* (bones above sternum), 25  
*Ossa suturarum*, 62  
*Ossa triquetra* (triangular bones), 62  
 Ossification, 3  
 of bones of head, 73  
 of bones of lower limb, 136  
 of bones of upper limb, 106  
 of ribs and sternum, 30  
 of vertebrae, 19  
 Osteology (*δοτέον*, bone; *λόγος*, discourse), 3  
 Outlet of pelvis, 116  
 Ovarian artery, 466  
 plexus, 535  
 veins, 535
- PACCHIONIAN fossæ, 36, 38, 68  
 Palatals, 80  
 Palate bone, 53, 80  
 ossification of, 77  
 hard, 52, 53, 67  
 plate of palate bone, 53, 72  
 superior maxilla, 50, 52, 72  
 soft, muscles of, 307  
 Palatine arteries, 397, 402, 406  
 canal, accessory, 54, 67  
 anterior, 52, 67  
 posterior, 51, 54, 67  
 small, 54, 67  
 fossa, anterior, 52, 67  
 groove, 52, 67  
 spine, 53  
 veins, 515, 517  
 Palato-glossus muscle, 307, 349  
 Palato-pharyngeus muscle, 307, 349  
 Palato-maxillary canal, 51, 54, 67  
 Palmar arches, 446, 451, 452, 507  
 fascia, 235  
 ligaments, carpal, 174  
 carpo-metacarpal, 175  
 metacarpal, 175  
 muscles, 235  
 Palmaris. *See* MUSCLES.  
 Palpebral arteries, 409, 410  
 fascia, 281  
 ligament, 281  
 veins, 514, 515  
 Pampiniform (*pampinūs*, tendril; *forma*, shape) plexus, 535  
 Pancreas, lymphatics of, 553  
 Pancreatic arteries, 461  
 veins, 543  
 Pancreatico-duodenal arteries, 460, 462, 507  
 Panniculus (membrane) adiposus, 202  
 carnosus, 202, 205, 296, 349  
 Papillares, musculi, 359, 362  
*Paramastoid* (*παρά*, beside; *mastoid* process), process, 35  
 Parapophysis (*παρά*; *apophysis*), 23  
 Parietal artery, 413  
 bone, 35, 80  
 ossification of, 74  
 branches of abdominal aorta, 467

Parietal—*continued.*

- eminence, 35, 82  
 emissary vein, 526  
*fissure*, 74  
 foramen, 35, 68  
 fossa, 35  
 Parieto-mastoid suture, 62  
 Parieto-temporal artery, 414  
 Parotid (*παρά*; *οὖς*, gen. *οὐρός*, ear) fascia, 293, 296  
 lymphatic glands, 558  
 veins, 515, 516  
 Pars membranacea septi, 365  
 Parumbilical veins, 543  
 Patella (dish or plate), 124, 138, 144  
 ligament of, 184  
 lateral, 187  
 movement of, on femur, 188  
 ossification of, 138  
 Pectinati (*pecten*, comb) musculi, 357, 360  
 Pectineal fascia, 242  
 Pectineus muscle, 255, 257, 275  
 Pectoral region, fascia of, 208  
 lymphatic glands, 556  
 ridge, 93  
 Pectoralis major muscle, 208, 213, 274  
*minimus*, 211  
 minor, 209, 213, 274  
 Pedicles of vertebrae, 5  
 Pelvic fascia, 339  
 girdle, 140  
 index, 118  
 Pelvic and thoracic limbs, homologous bones in, 142  
 diaphragm, 344  
 Pelvis (basin), 110, 115  
 articulations of, 177  
 axis of, 117  
 brim or inlet of, 115  
 compared with shoulder, 140  
 differences in the sexes, 118  
 dimensions of, 118  
 distinctive characters of, in man, 118, 145  
 fascia of, 339  
 in child, 137  
 lower or true, 116  
 lymphatics of, 550  
 mechanism of, 180  
 muscles of, 341  
 outlet of, 116  
 position of, 117  
 upper or false, 116  
 veins of, 539  
 Penis, dorsal artery of, 479  
 vein of, 540  
 lymphatics of, 550  
 suspensory ligament of, 327  
 Perforans muscle of fingers, 226  
 of toes, 265  
 Perforating arteries. *See* ARTERIES.  
 Perforatus muscle of fingers, 225  
 of toes, 269  
 Pericardial arteries, 428, 454  
 Pericardium (*περί*, around, about; *καρδία*, heart), 352, 372  
 ligaments of, 352  
 transverse sinus of, 353  
 vessels and nerves of, 353  
 Perimysium (*περί*; *μύς*, muscle), 199  
 Perineum (*περί*; *ναίω*, am situated), central  
 point of, 342  
 fascia of, 337  
 lymphatics of, 550

- Perineum—*continued*.  
 muscles of, 341, 349  
 in female, 346
- Perineal artery, superficial, 478  
 transverse, 479  
 fascia, 337
- Petiotic (περί; οὖς, ὠτός, ear) portion of temporal bone, 75, 80
- Periosteum (περί; ὀστέον, bone), 3
- Peroneal (περόνη, pin of buckle, the fibula) arteries, 497, 498, 507  
 bone, 127  
 spine, 130  
 veins, 538
- Peroneus. *See* MUSCLES.
- Petit, triangle of, 329
- Petro-basilar fissure, 68
- Petro-mastoid portion of temporal bone, 75, 80
- Petro-pharyngeus muscle, 307
- Petro-sphenoidal fissure, 68  
 ligament, 43, 47
- Petro-squamous fissure, 42  
 sinus, 524
- Petrosal artery, 404  
 process of sphenoid, 44  
 superior, 47  
 sinuses, 518, 523
- Petrus (πέτρα, rock) portion of temporal bone, 39, 41, 75, 80, 82
- Phalanges (φάλαγξ, column of soldiers, originally used for the series of phalanges or *internodia*; or possibly from φάλαγξ, a cylindrical roller) of fingers, 105  
 articulations of, 176  
 cutaneous ligament of, 235  
 ossification of, 109  
 of toes, 135  
 articulations of, 197  
 ossification of, 139
- Pharyngeal artery, 401  
 lymphatics, 560  
 tubercle, 34  
 veins, 518
- Pharyngo-mastoides muscle, 307
- Pharynx (φάρυγξ), muscles of, 305
- Phrenic (φρήν, diaphragm) artery, inferior, 467, 508  
 superior, 428, 508  
 veins, 535
- Pia mater, lymphatics of, 559
- Pilastered femur, 123
- Pillars of abdominal ring, 329  
 of diaphragm, 323  
 of fauces, 307
- Pisi-annularis muscle, 240
- Pisi-metacarpal ligament, 174
- Pisi-metacarpus muscle, 240
- Pisi-uncinate ligament, 174
- Pisi-uncinatus muscle, 240
- Pisiform (πισυμ, pea; *forma*, shape) bone, 101, 144  
 articulation of, 174  
 ossification of, 108
- Pituitary (πιτυϊτα, phlegm or mucus) fossa, 43, 70
- Pivot-joint, 149
- Plagiocephaly (πλάγιος, oblique; κεφαλή, head), 86
- Plantar (*planta*, sole of foot) arch, 499, 507  
 arteries. *See* ARTERIES.  
 fascia, 268  
 ligaments, 194  
 muscles, 269
- Plantaris muscle, 264
- Plate, cribriform, 48, 49, 69, 71  
 orbital of ethmoid, 48, 63  
 of frontal bone, 36, 63, 69
- palate, of palate bone, 53, 72  
 of superior maxilla, 52, 72
- pterygoid, internal and external, 46, 47, 64, 76, 80  
 tympanic, 41, 75, 80  
 vertical of ethmoid, 48, 71, 76, 80  
 of palate bone, 53, 65, 72
- Platygnemius (πλατύς, broad; κνήμη, tibia) *tibia*, 127
- Platypellie (πλατύς; πέλλα, bowl) pelvis, 118
- Platyrhine (πλατύς; ρίς, ῥινός, nose) skulls, 85
- Platysma myoides (πλατύσμα, plate, from *πλάτυνω*, extend; *μύς*, muscle; *εἶδος*, shape), 286, 295, 350
- Platysma-sheet, of muscle, 349
- Plexus, arterial, subperitoneal, 469  
 subpleural mediastinal, 428
- Plexuses of nerves, coronary, of heart, 372
- PLEXUSES of veins, basilar, 523  
 carotid, 526  
 hæmorrhoidal 541  
 ovarian, 535  
 pampiniform, 535  
 prostatic, 541  
 pterygoid, 516  
 spermatic, 535  
 uterine, 541  
 vaginal, 541  
 vesical, 541
- Point, alveolar, 83  
 auricular, 84  
 central, of perineum, 342  
 nasal, 83  
 occipital, 83  
 spinal, or subnasal, 83  
 supraorbital, 83
- Popliteal (*poples*, ham) artery, 493, 506  
 line, 126  
 lymphatic glands, 548  
 notch, 126  
 space, 251  
 surface, of femur, 121  
 vein, 538
- Popliteus. *See* MUSCLES.
- Portal (*porta*, gate, entrance) vein, 541, 544
- Postauditory process, 74
- Postaxial (*post*, behind; *axis*) borders of limbs, 2, 142
- Postcostal anastomosis, 505
- Postglenoid process, 41
- Postscapula, 91
- Postsphenoid, 75
- Postvertebral anastomosis, 505
- Poupart's ligament, 328
- Preaxial (*præ*, before; *axis*) borders of limbs, 2, 142
- Precoastal anastomosis, 505
- Prehallux, 144
- Prelaryngeal lymphatic gland, 560
- Premaxillary bone, 77, 80
- Prepollex, 144
- Prescapula, 91
- Presphenoid, 75, 80
- Presternum, 24
- Prevertebral fascia, 298  
 muscles of neck, 310
- Process of bone, 4  
 acromion, 90  
 alar, of ethmoid, 48

Process of bone—*continued*.

alveolar, of superior maxilla, 50, 52  
 angular, of frontal bone, 37  
 auditory, external, 41  
 basilar, 31, 34, 67  
 clinoid, anterior, 45  
     middle, 47  
     posterior, 44  
 cochleariform, 42  
 coracoid, 90, 106, 140  
 coronoid of lower jaw, 60, 64, 78  
     of ulna, 95  
 descending, of lachrymal bone, 57  
 ensiform, 23, 25  
 ethmoidal, of inferior turbinate bone, 58  
 falciform, 179  
 frontal, of malar bone, 56  
 hamular, of lachrymal bone, 57  
     of sphenoid bone, 47  
*infrajugular*, of occipital bone, 34, 71  
 jugular, of occipital bone, 34, 68  
 lachrymal, of inferior turbinate bone, 58  
 malar, of upper jaw, 50, 52  
*marginal*, of malar bone, 56  
 mastoid, 41, 64, 68, 75, 82  
 maxillary, of inferior turbinate bone, 58  
     of palate bone, 54  
 nasal, of frontal bone, 37  
     of upper jaw, 50, 51  
 odontoid, 8, 20, 21  
 orbital, of malar bone, 56, 63  
     of palate bone, 53, 54, 63, 65  
 palate, of upper jaw, 50, 52, 72  
*paramastoid*, 35  
 petrosal, of sphenoid, 44  
     *superior*, 47  
 postauditory, 74  
 postglenoid, 41  
 pterygoid, 43, 46, 65  
 pyramidal, of palate bone, 53, 54, 65, 68  
 sphenoidal, of palate bone, 53, 54, 65, 72  
 spinous, of sphenoid bone, 45  
 styloid, of fibula, 127  
     of radius, 99  
     of temporal bone, 42, 68, 75, 80  
     of ulna, 97  
*supracondylar*, 94, 439, 440  
 temporal, of malar bone, 56  
 turbinate, superior and inferior, 48, 49  
 uncinatè, of ethmoid bone, 48, 53  
 ungual, of phalanges, 105  
 vaginal, of sphenoid, 47  
     of temporal bone, 42, 68  
 xiphoid, 25  
 zygomatic, 40

Processes, accessory, of lumbar vertebræ, 11, 23  
 capitular, of dorsal vertebræ, 23  
 mamillary, of lumbar vertebræ, 12, 23  
 tubercular, of dorsal vertebræ, 23  
 of vertebræ, articular, 5, 6, 7, 8, 9, 11  
     spinous, 5, 6, 7, 8, 9, 11  
     transverse, 5, 6, 8, 9, 11, 16  
     serial relations of, 21, 23

Processus cochleariformis (spoon-shaped process), 42  
 dentatus, 8

Profunda arteries. *See* ARTERIES.  
 vein, 539

Prognathous (*πρό*, forward; *γνάθος*, jaw) skulls, 85

Promontory of sacrum, 13, 115

Pronation (*pronus*, having the face downward), 170, 240  
 Pronator and flexor muscles, 223  
 Pronator. *See* MUSCLES.  
     ridge, 97  
 Prootic (*πρό*, before; *ὄδς*, gen. *ὠτός*, ear) centre, 75  
 Prostate, lymphatics of, 551  
 Prostatic plexus (veins), 541  
 Protuberance, occipital, external, 31  
     internal, 33, 70  
     mental, 58  
 Pseudo-sacral vertebræ, 23  
 Psoas (*ψόα*, loin) muscles, 243, 245, 249, 274  
 Pterion (*πτέρον*, wing), 84  
 Pterotic centre, 75  
 Pterygoid (*πτέρυξ*, wing; *εἶδος*, shape) arteries, 405  
     bones, 76, 80  
     canal, 47  
     fossa, 46, 68  
     muscles, 294, 349  
     notch, 47  
     plates, 46, 47, 64, 76, 80  
     plexus, 516  
     process, 43, 46, 65  
     tubercle, 47  
*Pterygoideus proprius* muscle, 295  
 Pterygo-maxillary fissure, 65  
     ligament, 286  
 Pterygo-palatine artery, 406  
     canal, 47, 54, 65  
*Pterygo-pharyngeus externus*, 307  
*Pterygo-spinosus* muscle, 295  
*Pterygo-spinosus* ligament, 47, 295  
 Pubic (*pubes*, hair of the genitals, &c., which appears at the period of "puberty")  
     arteries, 476, 484  
     articulation, 180  
     bone. *See* Os Pubis.  
     crest, 113  
     ligaments, 180  
     portion of fascia lata, 242  
     spine, 113  
     vein, 539  
 Pubo-coccygeus muscle, 343  
 Pubo-femoral ligament, 182  
     muscles, 275  
 Pubo-prostatic ligaments, 339  
*Pubo-transversalis* muscle, 333  
 Pudic (*pudeo*, am ashamed) arteries. *See* ARTERIES.  
     veins, 537, 540  
 Pulmonary artery, 358, 378, 504  
     varieties of, 384  
     orifice, 358, 367, 375  
     fibrous ring of, 368  
     valve, 360  
     veins, 379  
         orifices of, 360  
 Pulmonic circulation, 378  
 Purkinje, fibres of, 373  
 Pyloric artery, 460, 508  
     vein, 543  
 Pyramidal bone, 101  
     homology of, 143, 144  
     ossification of, 108  
     process of palate bone, 53, 54, 65, 68  
 Pyramidalis. *See* MUSCLES.  
 Pyriformis (more correctly *piriformis*, from *πίριον*, pear, and *forma*) muscle, 248, 249, 250, 275  
     fascia, 339

- QUADRATUS. *See* MUSCLES.  
 Quadriceps extensor muscle, 252
- RADIAL artery, 447, 506  
     of forefinger, 450  
     fossa, 94  
     vein, 527, 546  
 Radiale, 143  
     sesamoideum, 144  
 Radio-carpal articulation, 172  
*Radio-caryeus muscle*, 228  
 Radio-ulnar articulations, 169  
 Radius (ray, or spoke of wheel), 97  
     artery of, 443  
     homology of, 142, 144  
     movement of on ulna, 170  
     ossification of, 107  
 Ramus (branch; pl. *rami*) of ischium, 113  
     of lower jaw, 59  
     of pubic bone, 113  
     cervicalis princeps (art.), 399  
 Ranine (*rana*, frog, also a swelling under  
     tongue) artery, 395, 396  
     vein, 518  
 Receptaculum chyli, 547  
 Recess, sphenoid-ethmoidal, 72  
     supraclavicular, 297  
 Recto-vesical fascia, 339  
 Rectum, ligament of, 340  
     lymphatics of, 551  
 Rectus. *See* MUSCLES.  
 Recurrent arteries. *See* ARTERIES.  
 Renal (*ren*, kidney) artery, 465, 508  
     vein, 535, 544  
 Respiration, movements of, 325  
 Retina, central artery of, 408  
 Retinacula (restraining bands) of tendons,  
     202  
     of hip, 183  
 Retrahens auriculam muscle, 281, 350  
 Retropharyngeal space, 298  
 Rhomboid (*ῥόμβος*, rhomb; *εἶδος*, shape) liga-  
     ment, 164  
 Rhomboideus. *See* MUSCLES.  
 Ribs, 25  
     articulations of, 158  
     cartilages of, 25, 28  
     ossification of, 31  
     movements of, 161  
 Ridge of bone, 4  
     gluteal, 121  
     interosseous, of fibula, 128  
     of tibia, 126  
     intertrochanteric, 120  
     mylo-hyoid, 59  
     pectoral, 93  
     pronator, 97  
     superciliary, 37, 82  
     supinator, 97  
 Ridges, supracondylar, 93  
 Ring, abdominal, external or superficial, 328  
     internal or deep, 336  
     crural or femoral, 336  
     fibrous, of heart-orifices, 368  
 Risorius (*rideo*, laugh) muscle, 286, 350  
 Root, posterior aortic, 386  
     condition of thoracic duct with persistence  
     of, 548  
 Root-origin of subclavian artery, 386  
 Rostrum (beak) of sphenoid bone, 44  
 Rotation, 151
- Rotatores dorsii, 317  
     *longi*, 317  
 Rotula (dim. of *rota*, wheel), 124  
 Round ligament of hip, 182
- SACRAL arteries, middle, 469, 506  
     lateral, 482, 506  
     canal, 15  
     cornua, 14  
     foramina, 14  
     index, 15  
     lymphatic glands, 551  
     veins, lateral, 540  
     middle, 536  
     vertebræ, 5, 13, 20, 21  
     pseudo and true, 23  
 Sacro-coccygeal articulation, 178  
*Sacro-coccygeus anticus muscle*, 344, 347  
     *posticus muscle*, 316, 348  
 Sacro-iliac articulation, 178  
 Sacro-lumbalis muscle, 314  
 Sacro-sciatic foramina, 179  
     ligaments, 117, 179  
     notch, 116  
 Sacro-vertebral angle, 18  
     articulation, 177  
 Sacrum (*os sacrum*, translation of *ἱερὸν ὀστέον*,  
     great bone, also called *ἱερός σπόνδυλος*,  
     great vertebra, *e.g.*, in Galen), 5, 13  
     articulations of, 177  
     ossification of, 20  
 Saddle-joint, 149  
 Sagittal (*sagitta*, arrow) suture, 61  
     fontanelle, 74  
 Salpingo-pharyngeus (*σάλπιγξ*, trumpet; *φάρυγξ*,  
     pharynx) muscle, 308  
 Saphenous (from Arabic *safin* or *saferi* in Avi-  
     cenna, probably meaning hidden—*ἤνθη*,  
     originally applied to the vein),  
     artery, *great*, 492  
     *small*, 495  
     opening, 242  
     veins. *See* VEINS.  
 Sartorius (*sartor*, tailor) muscle, 251, 254, 275  
 Scalene tubercle, 27  
 Scalenus (*σκαληνός*, with unequal sides) muscles,  
     309, 310, 349  
 Scalp, lymphatics of, 559  
 Scaly suture, 147  
*Scansorius muscle*, 247  
 Scaphocephaly (*σκάφη*, boat; *κεφαλή*, head), 86  
 Scaphoid (*σκάφη*; *εἶδος*, shape) bone of foot, 131  
     bone of hand, 101, 108  
     homology of, 143, 144  
     fossa, 47  
 Scapula (*scapula*, back of shoulders), 87  
     compared with ilium, 140, 145  
     ligaments of, 166  
     ossification of, 106  
 Scapular artery, dorsal, 434  
     posterior, 426  
     index, 91  
     notch, *great*, 90  
 Scapulo-clavicular articulation, 164  
     arch, 164  
 Scapulo-humeral muscles, 275  
 Scarpa, fascia of, 242  
     foramina of, 52  
     triangle of, 252  
 Schindylesis (*σχινδύλεω* = *σχίζω*, split), 148  
 Sciatic (*ισχίον*, hip) artery, 480, 506

- Sciatic notches, 110, 114  
   veins, 540  
 Sclerotome (*σκληρός*, hard; *τέμνω*, cut), 201  
 Scrotum (hide), lymphatics of, 550  
 Segmentation of muscles, 201  
 Sella Turcica (Turkish saddle), 43, 70  
 Semilunar bone, 101, 108  
   homology of, 143, 144  
   fascia, 219  
   fibro-cartilages of knee, 185  
   flaps, 360, 364, 365  
   fold of Douglas, 331  
 Semimembranosus muscle, 251  
 Semispinalis muscle, 317  
 Semitendinosus muscle, 250, 251  
 Sense-capsules or cavities, 81  
 Septa, neural, hæmal, and lateral, 347  
   intermuscular, of arm, 218  
   of foot, 268  
   of forearm, 222  
   of leg, 257  
   of thigh, 243  
 Septal flap of tricuspid valve, 359  
 Septum (partition, from *sepio*, hedge in) auricularum, 357  
   interventricular, 365  
   pars membracea of, 365  
   narium, artery of, 398  
   nasi, 71  
   artery of, 406  
   sphenoidal, 43  
 Serial homology of vertebræ, 21  
 Serous pericardium, 353, 372  
 Serrated (*serra*, saw) suture, 147  
 Serratus. *See* MUSCLES.  
 Sesamoid (*σάσαμον*, a kind of small grain; *ἕδος*, shape) bones, 4, 200  
   fibular, 144  
   of foot, 135, 197, 261, 267, 271  
   of hand, 105, 176, 236, 237  
   radial, 144  
   tibial, 144  
   ulnar, 144  
 Sexual differences in skull, 82  
   in femur, 123  
   in pelvis, 118  
   in sacrum, 15  
 Sheath, axillary, 298  
   carotid, 298, 391  
   femoral, 243, 336  
   of flexor tendons, 228  
   of rectus muscle, 330, 348  
 Shin-bone, 124  
 Short bones, 4  
 Shoulder, articulation of, 166  
   compared with pelvis, 140  
   fascia of, 214  
   ligaments of, 166  
   muscles of, 214  
 Sibson, aortic vestibule of, 365  
 Sigmoid (C, a form of the letter *σίγμα*, *sigma*; *ἕδος*, shape) artery, 464  
   cavity, of radius, 99  
   cavities of ulna, 95  
   flaps, 360, 364  
   notch, lower jaw, 59  
 Sinus (hollow) of aorta, 381  
   basilar, 523  
   of bone, 4  
   cavernous, 523  
   circular, 523  
   coronary, of heart, 358, 510, 544  
   Sinus—*continued*.  
   frontal, 38, 72, 73, 74, 82  
   intercavernous, 523  
   of jugular vein, 518  
   lateral, 522  
   longitudinal, inferior and superior, 521  
   maxillary (or antrum), 50, 53, 72, 77  
   occipital, 523  
   petrosal, inferior, 518, 523  
   superior, 523  
   *petro-squamous*, 524  
   of portal vein, 542  
   sphenoidal, 43, 72, 73, 76  
   spheno-parietal, 523  
   straight, 522  
   tarsi, 193  
   tentorii, 522  
   transverse, of dura mater, 523  
   of pericardium, 353  
   venous, 356  
 Sinuses, air, in bones of head, 71, 82  
   confluence of, 521  
   ethmoidal, 48, 72, 77  
   of Valsalva, 364, 381  
   venous, of cranium, 521  
*Situs inversus*, 386  
 Skeleton (*σκέλλω*, dry), 3  
   adapted to erect attitude, 145  
 SKULL, anterior region of, 62  
   as a whole, 61  
   base of, external, 67  
   internal, 68  
   bones of, 31  
   difference from animals, 78, 145  
   differences in from age, 82  
   race, 82  
   sex, 82  
   external surface, 62  
   forms of, 82  
   irregular, 85  
   fossæ of base of, 68  
   grooves for blood-vessels in, 71  
   homologies of, 79  
   interior of, 68  
   lateral region of, 64  
   measurement of, 82  
   morphology of, 78  
   ossification of bones of, 73  
   superior region of, 62  
   sutures of, 61  
   vertebrate theory of, 81  
 Sole, fascia of, 268  
   muscles of, 269  
 Solcus (*solea*, sole fish) muscle, 263, 267, 273  
 Somatic (*σώμα*, body) arteries, 505  
 Space, intercostal, 30  
   popliteal, 251, 263  
   retropharyngeal, 298  
   suprasternal, 297  
 Spheno-ethmoidal recess, 72  
 Spermatie artery, 466, 508  
   fascia, 329  
   plexus (veins), 535  
   veins, 535, 545  
 Sphenoid (*σφήν*, wedge; *ἕδος*, shape) bone, 43, 80  
   articulations of, 43  
   ossification of, 75  
 Sphenoidal crest, 44  
   fissure, 47, 63, 70  
   foramen, 76  
   process of palate bone, 53, 54, 65, 72  
   septum, 43

- Sphenoidal sinns, 43, 72, 73, 76  
 spongy bones, 44, 76, 80  
 turbinals, 80  
 turbinate bones, 44  
 Spheno-maxillary fissure, 63, 65  
 fossa, 65  
 Spheno-palatine artery, 406  
 foramen, 55, 67, 72  
 notch, 55  
 Spheno-palatine veins, 517  
 Spheno-parietal sinus, 523  
 suture, 62  
*Spheno-pharyngeus muscle*, 307  
 Sphenotic (*σφήν*; *ὄψ*, gen. *ὄπός*, ear), 76  
 Sphincter (*σφιγγω*, bind). See MUSCLES.  
 Spinal arteries. See ARTERIES.  
 canal, 6  
 furrow, 18  
 point, 83  
 veins. See VEINS.  
 Spinalis. See MUSCLES.  
 Spindle, aortic, 384  
 Spine. See VERTEBRAL COLUMN.  
 Spine of bone, 4  
 ethmoidal, 44  
 of ilium, anterior and posterior, 110  
 of ischium, 114  
 nasal, of frontal bone, 38, 71  
 of palate bone, 53  
 of upper jaw, 50, 62  
 neural, 5  
 palatine, 53  
 peroneal, 130  
 of os pubis, 113  
 of scapula, 89  
 of tibia, 126  
*trochlear*, of frontal bone, 39  
 Spines, mental, 59  
 Spino-glenoid ligament, 166  
 Spinous processes of vertebræ. See PROCESSES.  
 of sphenoid bone, 45  
 Spiral groove, 93  
 line of femur, 120, 121  
 Splanchnic (*σπλάγχνον* = *viscus*, internal organ)  
 anastomoses, 507  
 arteries, 507  
 Spleen, lymphatics of, 553  
 Splenial bone, 78  
 Splenic artery, 460, 508  
 vein, 543  
 Splenius (*σπληνιον*, bandage, pad) muscle,  
 313, 319, 347  
 Spongy bones, ethmoidal, 49, 72, 80  
 inferior, 58, 72, 78, 80  
 sphenoidal, 44, 76, 80  
 Squamosals, 80  
 Squamous (*squama*, scale) portion of temporal  
 bone, 39, 74, 80  
 suture, 62, 147  
 Squamo-zygomatic, 39, 74, 80  
 Stapes (stirrup), 80  
 Stellate ligament, 158  
 Stensen, foramina of, 52  
 Stephanion (*στέφανος*, crown), 84  
 Sternal arteries, 428  
*foramen*, 25, 31  
 furrow or groove, 25  
 lymphatic glands, 554  
 ribs, 25  
*Sternalis muscle*, 209  
 Sterno-clavicular articulation, 164  
*Sterno-clavicularis muscle*, 212  
 Sterno-cleido-mastoid muscle, 298, 302, 349  
 Sterno-hyoid muscle, 299, 348  
 Sterno-mastoid arteries, 394, 399  
 muscle, 298  
*Sterno-scapular muscle*, 212  
 Sterno-thyroid muscle, 299, 348  
 Sterno-pericardial ligaments, 352  
 Sternum (*στέθρον*, breast or chest), 23  
 cleft, 25  
 ligaments of, 161  
 ossification of, 30  
 varieties of, 25  
 Stomach, lymphatics of, 553  
 Straight sinus, 522  
 Striate veins, 520  
*Stylo-auricularis muscle*, 304  
 Stylo-glossus muscle, 304  
 Stylo-hyal, 75, 80  
 Stylo-hyoid ligament, 61, 78, 80, 163  
 muscle, 301, 349  
*Stylo-hyoideus alter muscle*, 302  
 Styloid (*στυλοσ*, style or pen; *εἶδος*, shape)  
 process of fibula, 127  
 of radius, 99  
 of temporal bone, 42, 68, 75, 80  
 of ulna, 97  
 Stylo-mastoid artery, 401  
 foramen, 42, 68  
 Stylo-maxillary ligament, 163, 293, 296  
 Stylo-pharyngeus muscle, 307, 309, 349  
 Subacromial bursa, 168  
*Subanconeus muscle*, 221  
 Subclavian artery, 384, 386, 415, 504; 505  
 branches of, 418, 419  
 vein, 530, 545  
 Subclavius muscle, 211, 213, 274  
 Subcoracoid ossification of scapula, 105  
 Subcostal angle, 29  
 groove, 26  
 muscles, 321, 349  
 Subcrureus muscle, 254  
 Subcutaneous fasciæ, 202  
 Sublingual artery, 396  
 Submaxillary lymphatic glands, 558  
 triangle, 301  
 veins, 515  
 Submental artery, 398  
 vein, 515  
 Subnasal point, 83  
 Suboccipital lymphatic glands, 558  
 muscles, 318, 347  
 triangle, 319  
 Subperitoneal arterial plexus, 469  
 Subpleural mediastinal plexus, 428  
 Subpubic arch, 116, 118  
 fascia, 338  
 ligament, 180  
 Subscapular arteries, 425, 434  
 fossa, 88  
 lymphatic glands, 556  
 muscle, 217, 218, 275  
 vein, 529  
*Subscapularis minor muscle*, 218  
*Subscapulo-capsularis muscle*, 218  
 Subvertebral muscles, 201, 347  
 Sulcus of bone, 4  
 frontal, 38  
 terminalis, 357  
 Superciliary (*supercilium*, eyebrow: *super*,  
 above; *cilium*, eyelid) ridge, 37, 82  
 Superficial fascia, 202  
 Supination (*supinus*, lying on back), 170, 240

Supinator and extensor muscles, 229  
 Supinator. *See* MUSCLES.  
   ridge, 97  
 Supraacromial artery, 425  
 Supraclavicular fossa, 87  
   recess, 297  
*Supraclavicularis muscle*, 299  
   *proprius muscle*, 299  
 Supracondylar lines of femur, 121  
   *process*, 94, 439, 440  
   ridges of humerus, 93  
*Supracostalis muscle*, 320  
 Suprahyoid lymphatic glands, 558  
   muscles, 301  
 Supramastoid crest, 40  
 Supraoccipital bone, 73, 79  
 Supraorbital artery, 409  
   foramen, 37, 63, 64  
   notch. *See* Foramen.  
   point, 83  
   vein, 514  
 Suprapatellar tendon, 254  
 Suprarenal arteries, 465, 508  
   lymphatics, 552  
   vein, 535  
 Suprascapular artery, 425  
   cartilage or bone, 107  
   ligament, 166  
   notch, 90  
   vein, 517  
 Supraspinatus muscle, 214, 218, 275  
 Supraspinous artery, 426  
   fossa, 88  
   ligament, 154, 347  
 Suprasternal artery, 425  
   notch, 25  
   space, 297  
*Supratrochlear foramen*, 95  
 Sural (*sura*, calf) arteries, 494  
 SURGICAL ANATOMY OF ARTERIES, axillary, 435  
   brachial, 441  
   carotid, common, 392  
   dorsal of foot, 504  
   femoral, 492  
   iliac, common, 471  
   external, 485  
   lingual, 396  
   peroneal, 504  
   popliteal, 496  
   radial, 453  
   subclavian, 429  
   tibial, 504  
   ulnar, 453  
 Suspensory ligament. *See* LIGAMENTS.  
 Sustentaculum tali (support of astragalus), 129  
 SUTURES (*sutura*, seam), 61, 147  
   closure of, 62  
   coronal, 61  
   forms of, 147  
   frontal, 39, 62, 74  
   fronto-parietal, 61  
   *fronto-temporal*, 84  
   interparietal, 61  
   lamiboid, 61  
   *metopic*, 39  
   occipito-mastoid, 61  
   occipito-parietal, 61  
   parieto-mastoid, 62  
   sagittal, 61  
   spheno-parietal, 62  
   squamous, 62, 147  
   temporo-parietal, 62

Sylvian vein, deep, 520  
   superficial, 519  
 Symphysis (*σύν*, with, together; *φύω*, grow), 148  
   of lower jaw, 58  
   pubis, 113, 180  
 Synarthrosis (*συνάρθρωσις*—Galen, immoveable articulation: from *σύν*; *ἄρθρον*, joint), 147  
 Synchondrosis (*σύν*; *χόνδρος*, cartilage), 147  
*Syndesmo-pharyngeus muscle*, 306  
 Syndesmosis (*σύνδεσμος*, ligament), 148  
 Synostosis (*σύν*; *ὀστέον*, bone), 85, 147  
 Synovial bursa and sheaths, 202  
   subacromial, 168  
 SYNOVIAL MEMBRANES AND CAVITIES, 148  
   acromio-clavicular, 165  
   of ankle, 191  
   of atlas, 155, 156  
   of axis, 155, 156  
   carpal, 174  
   chondro-sternal, 159  
   costo-central, 158  
   costo-transverse, 159  
   of elbow-joint, 172  
   of hip, 183  
   interchondral, 160  
   of knee-joint, 187  
   metacarpal, 175  
   metacarpo-phalangeal, 176  
   metatarsal, 196  
   metatarso-phalangeal, 197  
   radio-carpal, 173  
   radio-ulnar, 169  
   of shoulder-joint, 168  
   sterno-clavicular, 164  
   tarsal, 193, 194, 195  
   tarsometatarsal, 196  
   of temporo-maxillary articulation, 163  
   tibio-fibular, 189, 190  
   of vertebræ, articulating, 153  
 Systemic arteries, 380  
   veins, 508

## TABLES of skull, 68

Tabular bones, 4

portion of occipital bone, 31

Talus (die). *See* Astragalus.Tarsal (*tarsus*) artery, 502

articulations, 192

ligaments of eyelids, 281, 283

Tarsalia, 143

Tarsometatarsal articulations, 195

Tarsus (*ταρσός*, upper surface of foot), 129

homologies of, 143, 144

ligaments of, 192

movements of, 197

ossification of, 138

Tegmen (cover) tympani, 42

Temporal (*tempora*, temples) arteries. *See*

## ARTERIES.

bone, 39, 80

articulations of, 39

ossification of, 74

canal of malar bone, 56, 64

crest, 37, 64

fascia, 64, 293

fossa, 64

lines, 35, 64

lymphatics, 558

muscle, 294, 349

process, of malar bone, 56

surface, of frontal bone, 37

- Temporal—*continued*.  
 surface, of parietal bone, 35  
 of sphenoid bone, 46  
 veins. *See* VEINS.  
 wings of sphenoid, 45  
 Temporo-maxillary articulation, 162  
 vein, 515  
 Temporo-parietal suture, 62  
 Tendinous rings of orifices of heart, 368  
 Tendo Achillis, 264  
 palpebrarum, 281  
 Tendon, central or cordiform, of diaphragm, 324  
 conjoined, of abdominal muscles, 330  
 infrapatellar, 184  
 suprapatellar, 254  
 Tenon, capsule or fascia of, 292  
 Tensor. *See* MUSCLES.  
 Teres (round, cylindrical). *See* MUSCLES.  
 Terms, descriptive, 1  
 Testis, lymphatics of, 552  
 Thebesius, foramina of, 358  
 valve of, 358  
 Thenar (*θέναρ*, palm of hand) eminence, 236  
 Thigh, bone of, 118  
 fasciæ of, 241  
 muscles of, anterior, 251  
 internal, 255  
 posterior, 250  
 Thoracic (*thorax*) aorta, descending, 380, 454  
 arteries. *See* ARTERIES.  
 axis, 435  
 duct, 546, 547  
 veins, 530  
 vertebræ, 9  
 Thorax (*θώραξ*, breast-plate), 23  
 as a whole, 29, 145  
 lymphatics of, 554, 557  
 muscles of, 319  
 Thumb, arteries of, 450  
 short muscles of, 236, 276  
 Thymus gland, lymphatics of, 556  
 Thyrohyals, 80  
 Thyro-hyoid muscle, 299, 348  
 Thyroid artery, inferior, 424, 504  
 lowest, 388, 425  
 superior, 394, 504  
 axis, 423  
 foramen, 115  
 veins, 512, 519  
 Tibia (pipe or flute), 124  
 artery of, 496  
 homology of, 142, 144  
 ossification of, 138  
 Tibial arteries. *See* ARTERY.  
 lymphatic gland, anterior, 550  
 veins, 538  
 Tibiale, 143  
 sesamoideum, 144  
 Tibialis. *See* MUSCLES.  
*Tibio-fascialis anticus muscle*, 259  
 Tibio-fibular articulations, 189, 190  
 Toes, bones of, 135, 138  
 movements of, 198  
 transverse ligament of, 269  
 Tongue, arteries of, 395  
 lymphatics of, 560  
 muscles of, 303, 348  
 veins of, 518  
 Tonsillar artery, 398  
 Torcular (wine or oil-press, transl. of *ληρός* of Herophilus, meaning cistern) Herophili, 33, 521  
 Torsion of femur, 123  
 of humerus, 94  
 of tibia, 127  
*Torus* (elevation) *occipitalis transversus*, 34  
 Trabeculæ of ventricles of heart, 359  
 Tracheal arteries, 424  
 Trachelo-mastoid (*τράχηλος*, neck; *mastoid*)  
 muscle, 316  
 Tractus spiralis foraminulentus, 43  
*Transposition of viscera*, 386  
 Transversalis fascia, 336, 347  
 muscle. *See* MUSCLES.  
 Transverse arteries. *See* ARTERIES.  
 carpal articulation, 173  
 ligament. *See* LIGAMENT.  
 processes of vertebræ, 5, 6, 8, 9, 11, 16, 21, 23  
 sinus, 523  
 of pericardium, 353  
 tarsal articulation, 194  
 Transverso-spinales, 316  
 Transversus. *See* MUSCLES.  
 Trapezium (*τραπεζιον*, a geometrical figure, dim. of *τράπεζα*, table or board), 102, 108, 144  
 Trapezium muscle, 203, 208, 213, 274, 349  
 Trapezoid bone, 102, 108, 144  
 ligament, 165  
 line, 87  
 Trefoil tendon of diaphragm, 324  
 Triangle, carotid, 391  
 of Petit, 329  
 Scarpa's, 252  
 submaxillary, 301  
 suboccipital, 319  
 Triangular fascia, 329  
 ligament of urethra, 338  
 Triangularis. *See* MUSCLES.  
 Triceps (three-headed) muscles, 221, 264  
 Tricuspid (*tres*, three; *cuspis*, point) valve, 359  
*Triticeo-glossus muscle*, 304  
 Trochanter (*τροχαντήρ*, runner, that which revolves, connected with *τροχάω* or *τροχάω*, run along, revolve), great, 119  
 small, 120  
 third, 123  
 Trochanteric fossa, 119  
 Trochlea (*τροχιλία*, pulley) of humerus, 94  
 of orbit, 290  
 Trochlear fossa, 37  
 surface, of femur, 121, 188  
 Trochlearis muscle, 290  
 Trochoides (*τροχοειδής*, wheel-like), 149  
 True ribs, 25  
 vertebræ, 5  
 Trunk, articulations of, 151  
 fasciæ of, anterior, 208  
 posterior, 203  
 morphology of, 347  
 lymphatics of, 550  
 muscles of, abdominal, 327  
 dorsal, 311  
 perineal, 341  
 thoracic, 319  
 morphology of, 347  
 Tubercle of bone, 4  
 adductor, 121  
 of astragalus, 131  
 conoid, of clavicle, 87  
*deltoid*, of clavicle, 87  
 of femur, 119  
 of Lower, 358



- Tubercle of bone—*continued*.  
 mental, 58  
 of os calcis, 129  
 pharyngeal, 34  
 pterygoid, 47  
 of quadratus, 120  
 of radius, 99  
 scalene, 27  
 of scaphoid bone, 101  
 of tibia, 126  
 of twelfth dorsal vertebra, external, inferior  
 and superior, 11  
 of zygoma, 40
- Tubercular processes of dorsal vertebræ, 23
- Tuberosity of bone, 4  
 of cuboid, 132  
 of humerus, 91  
 bicipital, 98  
 of femur, 122  
 fifth metatarsal bone, 135  
 first metatarsal bone, 133  
 ischium, 113  
 malar, 55  
 of olecranon, 95  
 os calcis, 129  
 palate bone, 53, 54  
 ribs, 26  
 scaphoid, 131  
 superior maxillary bone, 50  
 tibia, 124, 126  
 ulna, 95
- Tunica abdominalis, 327
- Turbinate (coiled, from *turbo*, whirl) bones. *See*  
 Spongy bones.  
 crest, 51, 53  
 processes, inferior and superior, 48, 49
- Tympanic (*tympanum*, drum of ear) arteries,  
 402, 404, 408  
 bone, 74, 80  
 plate, 41, 75, 80  
 ring, 75
- Tympanohyal, 75, 80
- Tympanum, 41
- ULNA (*ἄλεια*, elbow), 95  
 artery of, 443  
 compared with bones of leg, 142  
 ossification of, 108
- Ulnar artery, 442  
 veins, 527, 545
- Ulnare, 143  
 sesamoideum, 144
- Ulnaris quinti digiti*, 232
- Umbilical artery, 473  
 veins, 544
- Umbilicus (navel), 335
- Unciform (*uncus*, hook; *forma*, shape) bone,  
 103, 108, 143
- Uncinate (*uncus*) process of ethmoid bone, 48,  
 53
- Undefended space, 365
- Ungual (*unguis*, nail) phalanges, 105, 109
- Urethra, lymphatics of, 550  
 triangular ligament of, 338
- Uterine artery, 475, 508  
 plexus of veins, 541
- Uterus (womb), lymphatics of, 551
- Uvula (dim. of *uva*), 307  
 muscle of, 308
- VAGINAL (*vagina*, sheath) artery, 474, 508  
 lymphatics, 551  
 plexus (veins), 541  
 process of sphenoid bone, 47  
 of temporal bone, 42, 68
- Valsalva, sinuses of, 364, 381
- Valve, aortic, 364  
 bicuspid or mitral, 362  
 Eustachian, 358, 534  
 ilio-femoral, 539  
 pulmonary, 360  
 of Thebesius, 358  
 tricuspid, 359
- Vas deferens, artery of, 474  
 lymphatics of, 551
- Vasa aberrantia*, *brachial*, 440, 451  
*in lower limb*, 492, 495  
*subclavian*, 419
- Vasa brevia of stomach, arteries, 461, 508  
 veins, 543
- Vastus muscle. *See* MUSCLES.
- Veins, pulmonary, 360, 379
- VEINS, Systemic, Descriptive Anatomy of, 508  
 acromio-thoracic, 530  
 alveolar, 517  
 anastomotic of brain, great, 519  
 posterior, 519  
 angular, 514  
 ascending lumbar, 530  
 auditory, 523  
 auricular, anterior, 515  
 posterior, 517  
 axillary, 529, 545  
 azygos, left or small, 531, 544  
 right, or large, 530, 544  
 basilar, 520  
 basilic, 528, 545  
 brachial, 529  
 brachio-cephalic, 510, 544  
 of brain, 519  
 bronchial, 532  
 buccal, 515  
 of bulb, 540  
 capsular, 535  
 cardiac, 358, 509, 510  
 cardinal, 544  
 central, of retina, 524  
 cephalic, 528, 546  
 of cerebellum, 520  
 of cerebrum, 519  
 cervical, deep, 512  
 transverse, 517  
 choroid, 519  
 ciliary, 524  
 circumflex of shoulder, 509  
 iliac, deep, 539  
 superficial, 537  
 colico-spermatic, 535  
 condylar emissary, 526  
 coronary, of heart, 509  
 of stomach, 543  
 of corpus cavernosum, 540  
 of corpus striatum, 519, 520  
 of cranium, 519. *See also* Sinuses.  
 crico-thyroid, 519  
 cystic, 542  
 dental, inferior, 517  
 posterior, 517  
 deep cervical, 512  
 of diploe, 525  
 dorsal, spinal, 532  
 of clitoris, 541

VEINS—*continued.*

- dorsal, of penis, 540
- of tongue, 519
- emissary, 526
- emalgent, 535
- epigastric, deep, 484, 539
- superficial, 537
- ethmoidal, 524
- facial, anterior, 513, 518
- deep, 515
- posterior, 515
- common, 513, 519
- transverse, 516
- femoral, 539
- of forearm, 527
- frontal, 513
- of diploe, 525
- of Gaien, 519
- gastric, 543
- gastro-epiploic, 543
- gluteal, 540
- hæmorrhoidal, 541
- of head and neck, 513
- of heart, 509
- hepatic, 535, 544
- iliae, common, 536, 545
- external, 539, 544
- internal, 539, 544
- transverse, 544
- ilio-lumbar, 536
- infraorbital, 517
- innominate, 510, 544
- intercostal, 531
- superior, 512, 531, 544
- jugular, anterior, 517
- external, 517, 545
- internal, 518, 545
- posterior external, 517
- primitive, 544
- transverse, 544
- jugulo-cephalic*, 528, 546
- labial, 515
- lachrymal, 524
- laryngeal, 512, 519
- lingual, 518
- longitudinal, inferior, 521
- of lower limb, 536
- deep, 538
- superficial, 537
- lumbar, 534, 544
- ascending, 530, 534, 544
- mammary, internal, 512
- marginal, of limbs, 545
- masseteric, 515
- mastoid emissary, 526
- maxillary, internal (posterior), 516
- anterior, 515
- median-basilic, 528
- cephalic, 528
- median, 527
- deep, 528
- mediastinal, 511, 531
- meningeal, middle, 517
- mesenteric, inferior, 543
- superior, 542, 544
- morphology of, 544
- nasal, 514
- oblique, of Marshall, 358, 510, 544
- obturator, 540
- occipital, 517
- of diploe, 526
- emissary, 526

VEINS—*continued.*

- oesophageal, 531
- omphalo-mesenteric, 544
- ophthalmic, 524
- orbital, 515
- ovarian, 535
- palatine, 515, 517
- palpebral, external, 515
- inferior, 515
- superior, 514
- pancreatic, 543
- parietal, emissary, 526
- parotid, 515, 516
- parumbilical, 543
- of pelvis, 539
- pericardial, 511, 531
- perineal, superficial, 540
- peroneal, 538
- pharyngeal, 518
- phrenic, 535
- popliteal, 538
- portal, 541, 544
- accessory, 543
- profunda, 539
- pubic, 539
- pubic, external, 537
- internal, 540
- pulmonary, 360, 379
- pyloric, 543
- radial, 527, 546
- ramine, 518
- renal, 535, 544
- sacral, lateral, 540
- middle, 536
- saphenous, long, or internal, 537, 546
- short, or external, 538, 546
- sciatic, 540
- spermatic, 535, 545
- spheno-palatine, 517
- spinal, 532
- anterior longitudinal, 533
- dorsal, 532
- posterior longitudinal, 533
- of spinal cord, 533
- splenic, 543
- striate, inferior, 520
- subclavian, 530, 545
- submaxillary, 515
- submental, 515
- subscapular, 529
- supraorbital, 514
- suprarenal, 535
- suprascapular, 517
- Sylvian, deep, 520
- superficial, 519
- temporal, common, 515
- deep, 517
- middle, 515
- superficial, 515
- of diploe, 526
- temporo-maxillary, 515, 518
- thoracic, alar, 530
- long, 530
- superior, 530
- thymic, 511
- thyroid, superior, 519
- middle, 519
- inferior, 512
- tibial, 538
- transverse, cervical, 517, 518, 530
- facial, 516
- nasal, 514

**VEINS**—*continued*.  
 tympanic, 516, 523  
 ulnar, 527, 545  
 umbilical, 543, 544  
 of upper limb, 526  
     deep, 529  
     superficial, 527  
 of vertebræ (bodies), 533  
 vertebral, 511, 512  
     anterior, 512  
     posterior, 512  
 vitelline, 544  
 Veins, plexuses of. *See* PLEXUSES.  
 Velum pendulum palati, 307  
 Vena azygos major, 530, 544  
     cava (transl. of Galen's φλέψ κοίλη, capacious vein) inferior, 534, 544  
         opening in diaphragm for, 324  
     superior, 510, 513, 544  
 hemiazygos, 531  
     accessoria, 531  
     magna Galeni, 520  
     portæ, 541  
 Venæ comites, 529, 538  
     cordis minimæ, 358, 510  
 Venter (belly) of scapula, 88  
 Ventral somatic anastomosis, 505  
 Ventricles of heart. *See* HEART.  
 Vento-lateral muscle, 201, 348  
 Vertebra dentata, 8  
     prominens, 9  
**VERTEBRÆ** (*verte*, turn), 5  
     cervical, 6  
         first, 7  
         second, 8  
         seventh, 8  
     coccygeal, 16  
     dorsal, 9  
     false or fixed, 5  
     general characters of, 5  
     groups of, 6  
     homology of, 21  
     lumbar, 11  
     moveable, 5  
     number of, 5  
         varieties in, 12  
     ossification of, 19  
     pseudo-sacral, 23  
     sacral, 13  
     thoracic, 9  
     true, 5  
     veins of bodies of, 533  
 Vertebral aponeurosis, 313, 347  
     artery, 419, 505  
     column, 5  
         as a whole, 18  
         articulations of, 151  
         in child and in adult, 145  
         curves of, 18  
         movements of, 154  
         ossification of, 19

**Vertebral**—*continued*.  
     grooves, 18  
     groove of atlas, 8  
     notches, 5  
     veins, 511, 512  
 Vertebrarterial foramen, 6  
 Vertebrate theory of skull, 81  
 Vertical plate of ethmoid, 48, 71  
     of palate, 53, 65, 72  
*Vesalius*, foramen of, 47, 526  
 Vesical (*vesica*, bladder) arteries. *See* ARTERIES.  
     ligaments, 339  
     plexus (veins), 541  
 Vesico-prostatic artery, 473  
 Vesico-vaginal artery, 474  
 Vesicula seminalis, lymphatics of, 551  
 Vessels. *See* ARTERIES, VEINS, and LYMPHATICS.  
 Vestibule, aqueduct of, 42  
     aortic, 365  
 Vestigial fold of Marshall, 353  
 Vestigium foraminis ovalis, 358, 360  
 Vidiau artery, 406  
     canal, 47, 65, 70  
 Vieussens, isthmus of, 358  
 Vincula accessoria tendinum, 228  
 Vinculum subflavum, 228  
 Visceral branches of abdominal aorta, 458  
     compartment of neck, 298  
 Vitelline veins, 544  
 Vitreous (*vitrum*, glass) table of skull, 68  
 Volar (*vola*, palm of hand) artery, superficial, 449  
 Vomer (ploughshare), 55, 71, 80  
     ossification of, 77  
 Vortex of heart, 369  
 Vulva, lymphatics of, 550

WHITE LINE, of pelvic fascia, 340  
 Willis, circle of, 412  
*Wilson's muscle*, 345  
 Wings of sphenoid bone, 43, 45  
 Wormian bones, 62, 68, 74  
 Wrist, articulation of, 172  
     movements of, 176, 240

**XIPHISTERNUM** (ξίφος, sword; στέρνον, breast)  
 25

**ZYGAPOPHYSES** (ζυγ, root of ζεύγνυμι, yoke, or join together; *apophysis*), 5, 21  
*Zygoma* (cross-bar or bolt, from root above given), 40  
 Zygomatic arch, 64  
     fossa, 64  
 Zygomatici muscles, 286, 350

END OF VOLUME II.



A LIST OF WORKS ON  
MEDICINE, SURGERY  
AND  
GENERAL SCIENCE,  
PUBLISHED BY  
LONGMANS, GREEN & CO.,  
LONDON, NEW YORK, AND BOMBAY.

---

Medical and Surgical Works.

---

**ASHBY.** NOTES ON PHYSIOLOGY FOR THE USE OF STUDENTS PREPARING FOR EXAMINATION. By HENRY ASHBY, M.D. Lond., F.R.C.P., Physician to the General Hospital for Sick Children, Manchester; formerly Demonstrator of Physiology, Liverpool School of Medicine. Sixth Edition, thoroughly revised. With 141 Illustrations. Fcap. 8vo, price 5s.

---

**ASHBY AND WRIGHT.** THE DISEASES OF CHILDREN, MEDICAL AND SURGICAL. By HENRY ASHBY, M.D. Lond., F.R.C.P., Physician to the General Hospital for Sick Children, Manchester; Lecturer and Examiner in Diseases of Children in the Victoria University; and G. A. WRIGHT, B.A., M.B. Oxon., F.R.C.S. Eng., Assistant Surgeon to the Manchester Royal Infirmary and Surgeon to the Children's Hospital; formerly Examiner in Surgery in the University of Oxford. Enlarged and Improved Edition. With 192 Illustrations. 8vo, price 25s.

---

**BENNETT.**—*WORKS* by WILLIAM H. BENNETT, F.R.C.S., Surgeon to St. George's Hospital; Member of the Board of Examiners, Royal College of Surgeons of England.

CLINICAL LECTURES ON VARICOSE VEINS OF THE LOWER EXTREMITIES. With 3 Plates. 8vo. 6s.

ON VARICOCELE: A PRACTICAL TREATISE. With 4 Tables and a Diagram. 8vo. 5s.

CLINICAL LECTURES ON ABDOMINAL HERNIA: chiefly in relation to Treatment, including the Radical Cure. With 12 Diagrams in the Text. 8vo. 8s. 6d. \*

**BENTLEY. A TEXT-BOOK OF ORGANIC MATERIA MEDICA.**

Comprising a Description of the Vegetable and Animal Drugs of the British Pharmacopœia, with some others in common use. Arranged Systematically, and Especially Designed for Students. By ROBERT BENTLEY, M.R.C.S. Eng., F.L.S. With 62 Illustrations on Wood. Crown 8vo, price 7s. 6d.

**COATS. A MANUAL OF PATHOLOGY.** By JOSEPH COATS,

M.D., Professor of Pathology in the University of Glasgow. Third Edition. Revised throughout. With 507 Illustrations. 8vo, 31s. 6d.

**COOKE.**—*WORKS* by THOMAS COOKE, F.R.C.S. Eng., B.A., B.Sc., M.D. Paris, Senior Assistant Surgeon to the Westminster Hospital.

**TABLETS OF ANATOMY.** Being a Synopsis of Demonstrations given in the Westminster Hospital Medical School in the years 1871-75. Tenth Thousand, being a selection of the Tablets believed to be most useful to Students generally. Post 4to, price 10s. 6d.

**APHORISMS IN APPLIED ANATOMY AND OPERATIVE SURGERY.** Including 100 Typical *vivâ voce* Questions on Surface Marking, &c. Crown 8vo, 3s. 6d.

**DISSECTION GUIDES.** Aiming at Extending and Facilitating such Practical Work in Anatomy as will be specially useful in connection with an ordinary Hospital Curriculum. 8vo, 10s. 6d.

**DICKINSON.**—*WORKS* by W. HOWSHIP DICKINSON, M.D. Cantab., F.R.C.P., Physician to, and Lecturer on Medicine at, St. George's Hospital; Consulting Physician to the Hospital for Sick Children.

**ON RENAL AND URINARY AFFECTIONS.** Complete in Three Parts, 8vo, with 12 Plates and 122 Woodcuts. Price £3 4s. 6d. cloth.

\* \* The Parts can also be had separately, each complete in itself, as follows :—

PART I.—*Diabetes*, price 10s. 6d. sewed, 12s. cloth.

„ II.—*Albuminuria*, price £1 sewed, £1 1s. cloth.

„ III.—*Miscellaneous Affections of the Kidneys and Urine*, price £1 10s. sewed, £1 11s. 6d. cloth.

**THE TONGUE AS AN INDICATION OF DISEASE;** being the Lumleian Lectures delivered at the Royal College of Physicians in March, 1888. 8vo, price 7s. 6d.

**THE HARVEIAN ORATION ON HARVEY IN ANCIENT AND MODERN MEDICINE.** Crown 8vo, 2s. 6d.

**OCCASIONAL PAPERS ON MEDICAL SUBJECTS, 1855-1896.** 8vo, 12s.

**ERICHSEN.**—*WORKS* by Sir JOHN ERIC ERICHSEN, *Bart.*, *F.R.S.*, *LL.D.* (*Edin.*), *Hon. M. Ch.* and *F.R.C.S. (Ireland)*, *Surgeon Extraordinary to H.M. the Queen*; *President of University College, London*; *Fellow and Ex-President of the Royal College of Surgeons of England*; *Emeritus Professor of Surgery in University College*; *Consulting-Surgeon to University College Hospital, and to many other Medical Charities.*

THE SCIENCE AND ART OF SURGERY; A TREATISE ON SURGICAL INJURIES, DISEASES, AND OPERATIONS. Tenth Edition. Revised by the late MARCUS BECK, *M.S. & M.B. (Lond.)*, *F.R.C.S.*, *Surgeon to University College Hospital, and Professor of Surgery in University College, London*; and by RAYMOND JOHNSON, *M.B. & B.S. (Lond.)*, *F.R.C.S.*, *Assistant Surgeon to University College Hospital, &c.* Illustrated by nearly 1,000 Engravings on Wood. 2 Vols. royal 8vo, 48s.

**FRANKLAND.** MICRO-ORGANISMS IN WATER, THEIR SIGNIFICANCE, IDENTIFICATION, AND REMOVAL. Together with an Account of the Bacteriological Methods Involved in their Investigation. Specially Designed for the Use of those connected with the Sanitary Aspects of Water Supply. By Professor PERCY FRANKLAND, *Ph.D.*, *B.Sc. (Lond.)*, *F.R.S.*, *Fellow of the Chemical Society*; and Mrs. PERCY FRANKLAND, Joint Author of "Studies on Some New Micro-Organisms Obtained from Air." With 2 Plates and numerous Diagrams. 8vo. 16s. net.

**GAIRDNER AND COATS.** ON THE DISEASES CLASSIFIED by the REGISTRAR-GENERAL as TABES MESENTERICA. LECTURES TO PRACTITIONERS. By W. T. GAIRDNER, *M.D.*, *LL.D.* On the PATHOLOGY of PHTHISIS PULMONALIS. By JOSEPH COATS, *M.D.* With 28 Illustrations. 8vo, price 12s. 6d.

**GARROD.**—*WORKS* by Sir ALFRED BARING GARROD, *M.D.*, *F.R.S.*, &c.; *Physician Extraordinary to H.M. the Queen*; *Consulting Physician to King's College Hospital*; *late Vice-President of the Royal College of Physicians.*

A TREATISE ON GOUT AND RHEUMATIC GOUT (RHEUMATOID ARTHRITIS). Third Edition, thoroughly revised and enlarged; with 6 Plates, comprising 21 Figures (14 Coloured), and 27 Illustrations engraved on Wood. 8vo, price 21s.

THE ESSENTIALS OF MATERIA MEDICA AND THERAPEUTICS. The Thirteenth Edition, revised and edited, under the supervision of the Author, by NESTOR TIRARD, *M.D. Lond.*, *F.R.C.P.*, *Professor of Materia Medica and Therapeutics in King's College, London, &c.* Crown 8vo, price 12s. 6d.

**GRAY.** ANATOMY, DESCRIPTIVE AND SURGICAL. By HENRY GRAY, F.R.S., late Lecturer on Anatomy at St. George's Hospital. The Thirteenth Edition, re-edited by T. PICKERING PICK, Surgeon to St. George's Hospital; Member of the Court of Examiners, Royal College of Surgeons of England. With 636 large Woodcut Illustrations, a large proportion of which are Coloured, the Arteries being coloured red, the Veins blue, and the Nerves yellow. The attachments of the muscles to the bones, in the section on *Ostéology*, are also shown in coloured outline. Royal 8vo, price 36s.

---

**HALLIBURTON.**—*WORKS by W. D. HALLIBURTON, M.D., F.R.S., M.R.C.P., Professor of Physiology in King's College, London; Lecturer on Physiology at the London School of Medicine for Women.*

A TEXT-BOOK OF CHEMICAL PHYSIOLOGY AND PATHOLOGY. With 104 Illustrations. 8vo, 28s.

ESSENTIALS OF CHEMICAL PHYSIOLOGY. Second Edition. 8vo, 5s.

\* \* This is a book suitable for medical students. It treats of the subject in the same way as Prof. SCHÄFER'S "Essentials" treats of *Histology*. It contains a number of elementary and advanced practical lessons, followed in each case by a brief descriptive account of the facts related to the exercises which are intended to be performed by each member of the class.

---

**LANG.**—THE METHODICAL EXAMINATION OF THE EYE. Being Part I. of a Guide to the Practice of *Ophthalmology* for Students and Practitioners. By WILLIAM LANG, F.R.C.S. Eng., Surgeon to the Royal London Ophthalmic Hospital, Moorfields, &c. With 15 Illustrations. Crown 8vo, 3s. 6d.

---

**LANGTON.** ABDOMINAL HERNIA. By JOHN LANGTON, F.R.C.S., Surgeon to St. Bartholomew's Hospital, Senior Surgeon to the City of London Truss Society, Member of the Council and Court of Examiners of the Royal College of Surgeons of England. With numerous Illustrations. [*In the press.*]



**LIVEING.**—*WORKS* by *ROBERT LIVEING, M.A. & M.D. Cantab., F.R.C.P. Lond., &c., Physician to the Department for Diseases of the Skin at the Middlesex Hospital, &c.*

**HANDBOOK ON DISEASES OF THE SKIN.** With especial reference to Diagnosis and Treatment. Fifth Edition, revised and enlarged. Fcap. 8vo, price 5s.

**ELEPHANTIASIS GRÆCORUM, OR TRUE LEPROSY;**  
Being the Goulstonian Lectures for 1873. Cr. 8vo, 4s. 6d.

**LONGMORE.**—*WORKS* by *Surgeon-General Sir T. LONGMORE (Retired), C.B., F.R.C.S., late Professor of Military Surgery in the Army Medical School; Officer of the Legion of Honour.*

**THE ILLUSTRATED OPTICAL MANUAL; OR, HANDBOOK OF INSTRUCTIONS FOR THE GUIDANCE OF SURGEONS IN TESTING QUALITY AND RANGE OF VISION, AND IN DISTINGUISHING AND DEALING WITH OPTICAL DEFECTS IN GENERAL.** Illustrated by 74 Drawings and Diagrams by Inspector-General Dr. MACDONALD, R.N., F.R.S., C.B. Fourth Edition. 8vo, price 14s.

**GUNSHOT INJURIES.** Their History, Characteristic Features, Complications, and General Treatment; with Statistics concerning them as they have been met with in Warfare. With 78 Illustrations. 8vo, price 31s. 6d.

**LUFF.** **TEXT-BOOK OF FORENSIC MEDICINE AND TOXICOLOGY.** By *ARTHUR P. LUFF, M.D., B.Sc. (Lond.), Physician in Charge of Out-Patients and Lecturer on Medical Jurisprudence and Toxicology in St. Mary's Hospital; Examiner in Forensic Medicine in the University of London; External Examiner in Forensic Medicine in the Victoria University; Official Analyst to the Home Office.* With numerous Illustrations. 2 vols., crown 8vo, 24s.

**MUNK.** **THE LIFE OF SIR HENRY HALFORD, Bart., G.C.H., M.D., F.R.S.,** President of the Royal College of Physicians, Physician to George III., George IV., William IV., and to Her Majesty Queen Victoria. By *William MUNK, M.D., F.S.A., Fellow and late Vice-President of the Royal College of Physicians of London.* With 2 Portraits. 8vo, 12s. 6d.

---

**NEWMAN.** ON THE DISEASES OF THE KIDNEY AMENABLE TO SURGICAL TREATMENT. Lectures to Practitioners. By DAVID NEWMAN, M.D., Surgeon to the Western Infirmary Out-Door Department; Pathologist and Lecturer on Pathology at the Glasgow Royal Infirmary; Examiner in Pathology in the University of Glasgow; Vice-President Glasgow Pathological and Clinical Society. 8vo, price 16s.

---

**NOTTER AND FIRTH.** HYGIENE. By J. L. NOTTER, M.A., M.D., Fellow and Member of Council of the Sanitary Institute of Great Britain, Examiner in Hygiene, Science and Art Department, etc.; and R. H. FIRTH, F.R.C.S., Assistant Examiner in Hygiene, Science and Art Department. With 93 Illustrations. Crown 8vo, 3s. 6d.

---

**OWEN.** A MANUAL OF ANATOMY FOR SENIOR STUDENTS. By EDMUND OWEN, M.B., F.R.S.C., Senior Surgeon to the Hospital for Sick Children, Great Ormond Street, Surgeon to St. Mary's Hospital, London, and co-Lecturer on Surgery, late Lecturer on Anatomy in its Medical School. With 210 Illustrations. Crown 8vo, price 12s. 6d.

---

**POOLE.** COOKERY FOR THE DIABETIC. By W. H. and Mrs. POOLE. With Preface by Dr. PAVY. Fcap. 8vo. 2s. 6d.

---

**POORE.** ESSAYS ON RURAL HYGIENE. By GEORGE VIVIAN POORE, M.D., F.R.C.P. Crown 8vo, 6s. 6d.

---

**QUAIN.** A DICTIONARY OF MEDICINE; Including General Pathology, General Therapeutics, Hygiene, and the Diseases of Women and Children. By Various Writers. Edited by RICHARD QUAIN, Bart., M.D.Lond., LL.D.Edin. (Hon.) F.R.S., Physician Extraordinary to H.M. the Queen, President of the General Medical Council, Member of the Senate of the University of London, &c. Assisted by FREDERICK THOMAS ROBERTS, M.D.Lond., B.Sc., Fellow of the Royal College of Physicians, Fellow of University College, Professor of Materia Medica and Therapeutics, University College, &c.; and J. MITCHELL BRUCE, M.A.Abdn., M.D.Lond., Fellow of the Royal College of Physicians of London, Physician and Lecturer on the Principles and Practice of Medicine, Charing Cross Hospital, &c. New Edition, Revised throughout and Enlarged. In 2 Vols. medium 8vo, cloth, red edges, price 40s. net.

**QUAIN. QUAIN'S (JONES) ELEMENTS OF ANATOMY.**

The Tenth Edition. Edited by EDWARD ALBERT SCHÄFER, F.R.S., Professor of Physiology and Histology in University College, London; and GEORGE DANCER THANE, Professor of Anatomy in University College, London. In 3 Vols.

\* \* The several parts of this work form COMPLETE TEXT-BOOKS OF THEIR RESPECTIVE SUBJECTS. They can be obtained separately as follows:—

VOL. I., PART I. EMBRYOLOGY. By E. A. SCHÄFER, F.R.S. With 200 Illustrations. Royal 8vo, pp. 184, price 9s.

VOL. I., PART II. GENERAL ANATOMY OR HISTOLOGY. By E. A. SCHÄFER, F.R.S. With 291 Illustrations. Royal 8vo, pp. 278, price 12s. 6d.

VOL. II., PART I. OSTEOLOGY. By G. D. THANE. With 168 Illustrations. Royal 8vo, 9s.

VOL. II., PART II. ARTHROLOGY — MYOLOGY — ANGEIOLOGY. By G. D. THANE. With 255 Illustrations. Royal 8vo, 18s.

VOL. III., PART I. THE SPINAL CORD AND BRAIN. By E. A. SCHÄFER, F.R.S. With 139 Illustrations. Royal 8vo, 12s. 6d.

VOL. III., PART II. THE NERVES. By G. D. THANE. With 102 Illustrations. Royal 8vo, 9s.

VOL. III., PART III. THE ORGANS OF THE SENSES. By E. A. SCHÄFER, F.R.S. With 178 Illustrations. Royal 8vo, 9s.

VOL. III., PART IV. SPLANCHNOLOGY. By E. A. SCHÄFER, F.R.S., and JOHNSON SYMINGTON, M.D. With 337 Illustrations. Royal 8vo, 16s.

APPENDIX. SUPERFICIAL AND SURGICAL ANATOMY. By Professor G. D. THANE and Professor R. J. GODLEE, M.S. With 29 Illustrations. Royal 8vo, 6s. 6d.

**RICHARDSON. THE ASCLEPIAD.** A Book of Original Research in the Science, Art, and Literature of Medicine. By BENJAMIN WARD RICHARDSON, M.D., F.R.S. Published Quarterly, price 2s. 6d. Volumes 1—10. 8vo, price 12s. 6d. each.

**SCHÄFER. THE ESSENTIALS OF HISTOLOGY: Descriptive and Practical.** For the Use of Students. By E. A. SCHÄFER, F.R.S., Jodrell Professor of Physiology in University College, London; Editor of the Histological Portion of Quain's "Anatomy." Illustrated by more than 300 Figures, many of which are new. Fourth Edition, Revised and Enlarged. 8vo, 7s. 6d. (Interleaved, 10s.)

**SCHENK.** MANUAL OF BACTERIOLOGY. For Practitioners and Students. With especial reference to Practical Methods. By Dr. S. L. SCHENK, Professor (Extraordinary) in the University of Vienna. Translated from the German, with an Appendix, by W. R. DAWSON, B.A., M.D., Univ. Dub. ; late University Travelling Prizeman in Medicine. With 100 Illustrations, some of which are coloured. 8vo, 10s. net.

**SMALE AND COLYER.** DISEASES AND INJURIES OF THE TEETH, including Pathology and Treatment : a Manual of Practical Dentistry for Students and Practitioners. By MORTON SMALE, M.R.C.S., L.S.A., L.D.S., Dental Surgeon to St. Mary's Hospital, Dean of the School, Dental Hospital of London, &c. ; and J. F. COLYER, L.R.C.P., M.R.C.S., L.D.S., Assistant Dental Surgeon to Charing Cross Hospital, and Assistant Dental Surgeon to the Dental Hospital of London. With 334 Illustrations. Large Crown 8vo, 15s.

**SMITH (H. F.).** THE HANDBOOK FOR MIDWIVES. By HENRY FLY SMITH, B.A., M.B. Oxon., M.R.C.S. Second Edition. With 41 Woodcuts. Crown 8vo, price 5s.

**STEEL.**—*WORKS* by JOHN HENRY STEEL, F.R.C.V.S., F.Z.S., A.V.D., late Professor of Veterinary Science and Principal of Bombay Veterinary College.

A TREATISE ON THE DISEASES OF THE DOG ; being a Manual of Canine Pathology. Especially adapted for the use of Veterinary Practitioners and Students. 88 Illustrations. 8vo, 10s. 6d.

A TREATISE ON THE DISEASES OF THE OX ; being a Manual of Bovine Pathology. Especially adapted for the use of Veterinary Practitioners and Students. 2 Plates and 117 Woodcuts. 8vo, 15s.

A TREATISE ON THE DISEASES OF THE SHEEP ; being a Manual of Ovine Pathology for the use of Veterinary Practitioners and Students. With Coloured Plate, and 99 Woodcuts. 8vo, 12s.

OUTLINES OF EQUINE ANATOMY ; a Manual for the use of Veterinary Students in the Dissecting Room. Crown 8vo, 7s. 6d.

**"STONEHENGE."** THE DOG IN HEALTH AND DISEASE. By "STONEHENGE." With 84 Wood Engravings. Square crown 8vo, 7s. 6d.

**THORNTON.** HUMAN PHYSIOLOGY. By JOHN THORNTON, M.A., Author of "Elementary Physiography," "Advanced Physiography," &c. With 267 Illustrations, some of which are Coloured. Crown 8vo, 6s.

**WALLER.** AN INTRODUCTION TO HUMAN PHYSIOLOGY.

By AUGUSTUS D. WALLER, M.D., Lecturer on Physiology at St. Mary's Hospital Medical School, London; late External Examiner at the Victorian University. Second Edition, Revised. With 305 Illustrations. 8vo, 18s.

**WEICHSELBAUM.** THE ELEMENTS OF PATHOLOGICAL HISTOLOGY, With Special Reference to Practical Methods.

By Dr. ANTON WEICHSELBAUM, Professor of Pathology in the University of Vienna. Translated by W. R. DAWSON, M.D. (Dub.), Demonstrator of Pathology in the Royal College of Surgeons, Ireland, late Medical Travelling Prizeman of Dublin University, &c. With 221 Figures, partly in Colours, a Chromo-lithographic Plate, and 7 Photographic Plates. Royal 8vo, 21s. net.

**WILKS AND MOXON.** LECTURES ON PATHOLOGICAL ANATOMY.

By SAMUEL WILKS, M.D., F.R.S., Consulting Physician to, and formerly Lecturer on Medicine and Pathology at, Guy's Hospital, and the late WALTER MOXON, M.D., F.R.C.P., Physician to, and some time Lecturer on Pathology at, Guy's Hospital. Third Edition, thoroughly Revised. By SAMUEL WILKS, M.D., LL.D., F.R.S. 8vo, 18s.

**YOUATT.**—*WORKS* by WILLIAM YOUATT.

THE HORSE. Revised and Enlarged by W. WATSON, M.R.C.V.S. With 52 Woodcuts. 8vo, 7s. 6d.

THE DOG. Revised and Enlarged. With 33 Woodcuts. 8vo, 6s.

---

### General Scientific Works.

**BENNETT AND MURRAY.** A HANDBOOK OF CRYPTOGAMIC BOTANY.

By A. W. BENNETT, M.A., B.Sc., F.L.S., and GEORGE R. MILNE MURRAY, F.L.S. With 378 Illustrations. 8vo, 16s.

**CARNEGIE.** LAW AND THEORY IN CHEMISTRY: A COMPANION BOOK FOR STUDENTS.

By DOUGLAS CARNEGIE, sometime Scholar and Demonstrator in Chemistry of Gonville and Caius, Cambridge. Crown 8vo, 6s.

**CLERKE.** THE SYSTEM OF THE STARS.

By AGNES M. CLERKE, Author of "A History of Astronomy during the Nineteenth Century." With 6 Plates and Numerous Illustrations. 8vo, 21s.

**CLODD.**—*WORKS* by EDWARD CLODD, *Author of "The Childhood of the World," &c.*

THE STORY OF CREATION. A Plain Account of Evolution. With 77 Illustrations. Crown 8vo, 3s. 6d.

A PRIMER OF EVOLUTION: being a Popular Abridged Edition of "The Story of Creation." With Illustrations. Fcp. 8vo, 1s. 6d.

**CROOKES.** SELECT METHODS IN CHEMICAL ANALYSIS (chiefly Inorganic). By W. CROOKES, F.R.S., V.P.C.S., Editor of "The Chemical News." Third Edition, re-written and enlarged. Illustrated with 67 Woodcuts. 8vo, 21s. net.

**CULLEY.** A HANDBOOK OF PRACTICAL TELEGRAPHY. By R. S. CULLEY, M.I.C.E., late Engineer-in-Chief of Telegraphs to the Post Office. With 135 Woodcuts and 17 Plates, 8vo, 16s.

**DU BOIS.** THE MAGNETIC CIRCUIT IN THEORY AND PRACTICE. By Dr. H. DU BOIS, Privat-docent in the University of Berlin. Translated from the German by Dr. E. ATKINSON. With numerous Illustrations. 8vo, 12s. net.

**GANOT.** ELEMENTARY TREATISE ON PHYSICS; Experimental and Applied, for the use of Colleges and Schools. Translated and edited from GANOT's *Éléments de Physique* (with the Author's sanction) by E. ATKINSON, Ph.D., F.C.S., formerly Professor of Experimental Science, Staff College, Sandhurst. Fourteenth Edition, revised and enlarged, with 9 Coloured Plates and 1,028 Woodcuts. Large crown 8vo, 15s.

NATURAL PHILOSOPHY FOR GENERAL READERS AND YOUNG PERSONS; Translated and Edited from GANOT's *Cours Élémentaire de Physique* (with the Author's sanction) by E. ATKINSON, Ph.D., F.C.S. Eighth Edition, carefully revised; with 7 Plates, 624 Woodcuts, and an Appendix of Questions. Crown 8vo, 7s. 6d.

**GOODEVE.**—*WORKS* by T. M. GOODEVE, M.A., *Barrister-at-Law; formerly Professor of Mechanics at the Normal School of Science and the Royal School of Mines.*

PRINCIPLES OF MECHANICS. New Edition, re-written and enlarged. With 253 Woodcuts and numerous Examples. Crown 8vo, 6s.

THE ELEMENTS OF MECHANISM. New Edition, re-written and enlarged. With 342 Woodcuts. Crown 8vo, 6s.

A MANUAL OF MECHANICS: an Elementary Text-Book for Students of Applied Mechanics. With 138 Illustrations and Diagrams, and 141 Examples taken from the Science Department Examination Papers, with Answers. Fcp. 8vo, 2s. 6d.

**HELMHOLTZ.**—*WORKS* by **HERMANN L. F. HELMHOLTZ**,  
*M.D., late Professor of Physics in the University of Berlin.*

**ON THE SENSATIONS OF TONE AS A PHYSIOLOGICAL BASIS FOR THE THEORY OF MUSIC.** Second English Edition; with numerous additional Notes, and a new Additional Appendix, bringing down information to 1885, and specially adapted to the use of Musical Students. By **ALEXANDER J. ELLIS**, B.A., F.R.S., F.S.A., &c., formerly Scholar of Trinity College, Cambridge. With 68 Figures engraved on Wood, and 42 Passages in Musical Notes. Royal 8vo, 28s.

**POPULAR LECTURES ON SCIENTIFIC SUBJECTS.** With 68 Woodcuts. 2 Vols. crown 8vo, 3s. 6d. each.

**HERSCHEL.** **OUTLINES OF ASTRONOMY.** By Sir **JOHN F. W. HERSCHEL**, Bart., K.H., &c., Member of the Institute of France. Twelfth Edition, with 9 Plates, and numerous Diagrams. 8vo, 12s.

**HUDSON AND GOSSE.** **THE ROTIFERA OR 'WHEEL ANIMALCULES.'** By **C. T. HUDSON**, LL.D., and **P. H. GOSSE**, F.R.S. With 30 Coloured and 4 Uncoloured Plates. In 6 Parts. 4to, price 10s. 6d. each; Supplement, 12s. 6d. Complete in Two Volumes, with Supplement, 4to, £4 4s.

\* \* The Plates in the Supplement contain figures of almost all the Foreign Species, as well as of the British Species, that have been discovered since the original publication of Vols. I. and II.

**JOUBERT.** **ELEMENTARY TREATISE ON ELECTRICITY AND MAGNETISM.** Founded on **JOUBERT'S** "*Traité Élémentaire d'Électricité.*" By **G. C. FOSTER**, F.R.S., Quain Professor of Physics in University College, London; and **E. ATKINSON**, Ph.D., formerly Professor of Experimental Science in the Staff College. With 381 Illustrations. Crown 8vo, 7s. 6d.

**KOLBE.** **A SHORT TEXT-BOOK OF INORGANIC CHEMISTRY.** By **Dr. HERMANN KOLBE**, late Professor of Chemistry in the University of Leipzig. Translated and Edited by **T. S. HUMPIDGE**, Ph.D., B.Sc. (Lond.), late Professor of Chemistry and Physics in the University College of Wales, Aberystwyth. New Edition. Revised by **H. LLOYD-SNAPE**, Ph.D., D.Sc. (Lond.), Professor of Chemistry in the University College of Wales, Aberystwyth. With a Coloured Table of Spectra and 66 Woodcuts. Crown 8vo, 8s. 6d.

**LARDEN.** **ELECTRICITY FOR PUBLIC SCHOOLS AND COLLEGES.** With numerous Questions and Examples with Answers, and 214 Illustrations and Diagrams. By **W. LARDEN**, M.A. Crown 8vo, 6s.

**LADD.**—*WORKS* by *GEORGE T. LADD*, *Professor of Philosophy in Yale University.*

ELEMENTS OF PHYSIOLOGICAL PSYCHOLOGY: A TREATISE OF THE ACTIVITIES AND NATURE OF THE MIND FROM THE PHYSICAL AND EXPERIMENTAL POINT OF VIEW. With 113 Illustrations. 8vo, price 21s.

PSYCHOLOGY, DESCRIPTIVE AND EXPLANATORY: A Treatise of the Phenomena, Laws, and Development of Human Mental Life. 8vo. 21s.

OUTLINES OF PHYSIOLOGICAL PSYCHOLOGY. With numerous Illustrations. 8vo. 12s.

PHILOSOPHY OF MIND: an Essay on the Metaphysics of Psychology. 8vo. 16s.

PRIMER OF PSYCHOLOGY. Crown 8vo. 5s. 6d.

**LOWELL.** MARS. By *PERCIVAL LOWELL*, Fellow American Academy, Member Royal Asiatic Society, Great Britain and Ireland, &c. With 24 Plates. 8vo, 12s. 6d.

\* \* The book is written in a style suitable for the general reader, and the most recent speculations as to the planet being inhabited, the possible canals, oases, &c., are discussed.

**MARTIN.** NAVIGATION AND NAUTICAL ASTRONOMY.

Compiled by Staff-Commander *W. R. MARTIN*, R.N., Instructor in Surveying, Navigation, and Compass Adjustment; Lecturer on Meteorology at the Royal Naval College, Greenwich. Sanctioned for use in the Royal Navy by the Lords Commissioners of the Admiralty. Royal 8vo, 18s.

**MENDELÉEFF.** THE PRINCIPLES OF CHEMISTRY. By

*D. MENDELÉEFF*, Professor of Chemistry in the University of St. Petersburg. Translated by *GEORGE KAMENSKY*, A.R.S.M. of the Imperial Mint, St. Petersburg, and Edited by *A. J. GREENAWAY*, F.I.C., Sub-Editor of the Journal of the Chemical Society. With 97 Illustrations. 2 Vols. 8vo, 36s.

**MEYER.** OUTLINES OF THEORETICAL CHEMISTRY.

By *LOTHAR MEYER*, Professor of Chemistry in the University of Tübingen. Translated by Professors *P. PHILLIPS BEDSON*, D.Sc., and *W. CARLETON WILLIAMS*, B.Sc. 8vo, 9s.

**MITCHELL.** MANUAL OF PRACTICAL ASSAYING. By *JOHN MITCHELL*, F.C.S. Sixth Edition. Edited by *W. CROOKES*, F.R.S. With 201 Woodcuts. 8vo, 31s. 6d.

**MORGAN.** ANIMAL BIOLOGY. An Elementary Text Book. By *C. LLOYD MORGAN*, Principal of University College, Bristol. With numerous Illustrations. Crown 8vo, 8s. 6d.



**MOSSO. FEAR.** By ANGELO MOSSO. Translated from the Fifth Edition of the Italian by E. LOUGH and F. KIESOW. With 8 Illustrations. Crown 8vo, 7s. 6d.

\* \* This book deals with much more than is conveyed by the title. It is, in fact, a series of essays on the expression of the emotions, dealing more especially with the painful emotions. Although the subject is treated in a measure scientifically, *i.e.*, physiologically, the book is not intended solely for the scientific public.

**MUIR. THE ALCHEMICAL ESSENCE AND THE CHEMICAL ELEMENT:** an Episode in the Quest of the Unchanging. By M. M. PATTISON MUIR, Fellow of Gonville and Caius College, Cambridge. 8vo. 4s. 6d.

**ODLING. A COURSE OF PRACTICAL CHEMISTRY,** Arranged for the use of Medical Students, with express reference to the Three Months' Summer Practice. By WILLIAM ODLING, M.A., F.R.S. With 71 Woodcuts. Crown 8vo, 6s.

**OSTWALD. SOLUTIONS.** By W. OSTWALD, Professor of Chemistry in the University of Leipzig. Being the Fourth Book, with some additions, of the Second Edition of Ostwald's "*Lehrbuch der Allgemeinen Chemie.*" Translated by M. M. PATTISON MUIR, Professor of Gonville and Caius College, Cambridge. 8vo, 10s. 6d.

**PAYEN. INDUSTRIAL CHEMISTRY;** A Manual for use in Technical Colleges or Schools, also for Manufacturers and others, based on a Translation of Stohmann and Engler's German Edition of PAYEN'S *Précis de Chimie Industrielle*. Edited and supplemented with Chapters on the Chemistry of the Metals, &c., by B. H. PAUL, Ph.D. With 698 Woodcuts. 8vo, 42s.

**PROCTOR.—WORKS** by RICHARD A. PROCTOR.

**OLD AND NEW ASTRO-NOMY.** By RICHARD A. PROCTOR and A. COWPER RANYARD. With 31 Plates and 472 Illustrations. Text. 4to, 21s.

**LIGHT SCIENCE FOR LEISURE HOURS;** Familiar Essays on Scientific Subjects, Natural Phenomena, &c. 3 Vols. crown 8vo, 5s. each.

**THE ORBS AROUND US;** a Series of Essays on the Moon and Planets, Meteors, and Comets. With Chart and Diagrams, crown 8vo, 5s. Cheap Edition, crown 8vo, 3s. 6d.

**OTHER WORLDS THAN OURS;** The Plurality of Worlds Studied under the Light of Recent Scientific Researches. With 14 Illustrations, crown 8vo, 5s. Cheap Edition, crown 8vo, 3s. 6d.

**THE MOON;** her Motions, Aspects, Scenery, and Physical Condition. With Plates, Charts, Woodcuts, and Lunar Photographs, crown 8vo, 5s.

**UNIVERSE OF STARS;** Presenting Researches into and New Views respecting the Constitution of the Heavens. With 22 Charts and 22 Diagrams, 8vo. 10s. 6d.

**LARGER STAR ATLAS** for the Library, in 12 Circular Maps, with Introduction and 2 Index Pages. Folio, 15s., or Maps only, 12s. 6d.

**NEW STAR ATLAS** for the Library, the School, and the Observatory, in 12 Circular Maps (with 2 Index Plates). Crown 8vo, 5s.

[Continued.]

PROCTOR.—WORKS by RICHARD A. PROCTOR—continued.

THE STUDENT'S ATLAS.

In 12 Circular Maps on a Uniform Projection and 1 Scale, with 2 Index Maps. Intended as a *vade-mecum* for the Student of History, Travel, Geography, Geology, and Political Economy. With a letter-press Introduction illustrated by several cuts. 5s.

OTHER SUNS THAN OURS :

a Series of Essays on Suns—Old, Young, and Dead. With other Science Gleanings, Two Essays on Whist, and Correspondence with Sir John Herschel. With 9 Star-Maps and Diagrams. Crown 8vo, 6s.

HALF-HOURS WITH THE

TELESCOPE : a Popular Guide to the Use of the Telescope as a Means of Amusement and Instruction. With 7 Plates. Fcap. 8vo, 2s. 6d.

THE SOUTHERN SKIES :

a Plain and Easy Guide to the Constellations of the Southern Hemisphere. Showing in 12 Maps the position of the principal Star-Groups night after night throughout the year. With an Introduction and a separate Explanation of each Map. True for every Year. 4to, 5s.

HALF-HOURS WITH THE

STARS : a Plain and Easy Guide to the Knowledge of the Constellations. Showing in 12 Maps the position of the principal Star-Groups night after night throughout the Year. With Introduction and a separate Explanation of each Map. True for every Year. 4to, 3s. 6d.

ELEMENTARY PHYSICAL

GEOGRAPHY. With 33 Maps and Woodcuts. Fcp. 8vo, 1s. 6d.

LESSONS IN ELEMENTARY

ASTRONOMY ; with Hints for Young Telescopists. With 47 Woodcuts. Fcp. 8vo, 1s. 6d.

EASY LESSONS IN THE

DIFFERENTIAL CALCULUS : indicating from the Outset the Utility of the Processes called Differentiation and Integration. Fcp. 8vo, 2s. 6d.

THE STARS IN THEIR SEA-

SONS. An Easy Guide to a Knowledge of the Star Groups, in 12 Large Maps. Imperial 8vo, 5s.

STAR PRIMER. Showing the

Starry Sky Week by Week, in 24 Hourly Maps. Crown 4to, 2s. 6d.

ROUGH WAYS MADE

SMOOTH. Familiar Essays on Scientific Subjects. Crown, 3s. 6d.

HOW TO PLAY WHIST :

WITH THE LAWS AND ETIQUETTE OF WHIST. Crown 8vo, 3s. 6d.

HOME WHIST : an Easy Guide

to Correct Play. 16mo, 1s.

OUR PLACE AMONG INFI-

NITIES. A Series of Essays contrasting our Little Abode in Space and Time with the Infinities around us. Crown 8vo, 5s.

STRENGTH AND HAPPI-

NESS. Crown 8vo, 5s.

STRENGTH : How to get Strong

and keep Strong, with Chapters on Rowing and Swimming, Fat, Age, and the Waist. With 9 Illustrations. Crown 8vo, 2s.

THE EXPANSE OF HEAVEN.

Essays on the Wonders of the Firmament. Crown 8vo, 5s. Cheap Edition, crown 8vo, 3s. 6d.

THE GREAT PYRAMID, OB-

SERVATORY, TOMB, AND TEMPLE. With Illustrations. Crown 8vo, 5s.

PLEASANT WAYS IN

SCIENCE. Crown 8vo, 5s. Cheap Edition, crown 8vo, 3s. 6d.

[Continued.]

**PROCTOR.**—*WORKS* by **RICHARD A. PROCTOR**—*continued.*

**MYTHS AND MARVELS OF ASTRONOMY.** Crown 8vo, 5s.  
Cheap Edition, crown 8vo, 3s. 6d.

**CHANCE AND LUCK ;** a Discussion of the Laws of Luck, Coincidences, Wagers, Lotteries, and the Fallacies of Gambling, &c. Crown 8vo, 2s. boards, 2s. 6d. cloth.

**NATURE STUDIES.** By GRANT ALLEN, A. WILSON, T. FOSTER, E. CLODD, and R. A. PROCTOR. Crown 8vo, 5s.  
Cheap Edition, crown 8vo, 3s. 6d.

**LEISURE READINGS.** By E. CLODD, A. WILSON, T. FOSTER, A. C. RUNYARD, and R. A. PROCTOR. Crown 8vo, 3s. 6d.

**REYNOLDS.** **EXPERIMENTAL CHEMISTRY** for Junior Students. By J. EMERSON REYNOLDS, M.D., F.R.S., Professor of Chemistry, Univ. of Dublin. Fcp. 8vo, with numerous Woodcuts.

PART I.—*Introductory*, 1s. 6d. PART III.—*Metals and Allied Bodies*, 3s. 6d.

PART II.—*Non-Metals*, 2s. 6d. PART IV.—*Chemistry of Carbon Compounds*, 4s.

**SLINGO AND BROOKER.** **ELECTRICAL ENGINEERING FOR ELECTRIC-LIGHT ARTISANS AND STUDENTS.** (Embracing those branches prescribed in the Syllabus issued by the City and Guilds Technical Institute.) By W. SLINGO and A. BROOKER. With 346 Illustrations. Crown 8vo, 12s.

**SMITH.** **GRAPHICS ; OR, THE ART OF CALCULATION BY DRAWING LINES,** applied to Mathematics, Theoretical Mechanics and Engineering, including the Kinetics and Dynamics of Machinery, and the Statics of Machines, Bridges, Roofs, and other Engineering Structures. By ROBERT H. SMITH, Professor of Civil and Mechanical Engineering, Mason Science College, Birmingham.

PART I. Text, with separate Atlas of Plates—Arithmetic, Algebra, Trigonometry, Vector, and Locor Addition, Machine Kinematics, and Statics of Flat and Solid Structures. 8vo, 15s.

**SORAUER.** **A POPULAR TREATISE ON THE PHYSIOLOGY OF PLANTS.** For the Use of Gardeners, or for Students of Horticulture and of Agriculture. By Dr. PAUL SORAUER, Director of the Experimental Station at the Royal Pomological Institute in Proskan (Silesia). Translated by F. E. WEISS, B.Sc., F.L.S., Professor of Botany at the Owens College, Manchester. With 33 Illustrations. 8vo, 9s. net.

**THORPE.** **A DICTIONARY OF APPLIED CHEMISTRY.** By T. E. THORPE, B.Sc. (Vict.), Ph.D., F.R.S., Treas. C.S., Professor of Chemistry in the Royal College of Science, London. Assisted by Eminent Contributors. To be published in 3 vols. 8vo. Vols. I. and II. £2 2s. each, Vol. III. £3 3s.

**TUBEUF.** **DISEASES OF PLANTS DUE TO CRYPTO-GAMIC PARASITES.** Translated from the German of DR. CARL FREIHERR VON TUBEUF, of the University of Munich, by WILLIAM G. SMITH, B. Sc., Ph.D., Lecturer on Plant Physiology to the University of Edinburgh. With over 300 Illustrations. [*In preparation.*]

**TYNDALL.**—WORKS by JOHN TYNDALL, F.R.S., &c.

- FRAGMENTS OF SCIENCE. 2 Vols. Crown 8vo, 16s.  
 NEW FRAGMENTS. Crown 8vo, 10s. 6d.  
 HEAT A MODE OF MOTION. Crown 8vo, 12s.  
 SOUND. With 204 Woodcuts. Crown 8vo, 10s. 6d.  
 RESEARCHES ON DIAMAGNETISM AND MAGNE-CRYSTALLIC ACTION, including the question of Diamagnetic Polarity. Crown 8vo, 12s.  
 ESSAYS ON THE FLOATING-MATTER OF THE AIR in relation to Putrefaction and Infection. With 24 Woodcuts. Crown 8vo, 7s. 6d.  
 LECTURES ON LIGHT, delivered in America in 1872 and 1873. With 57 Diagrams. Crown 8vo, 5s.  
 LESSONS IN ELECTRICITY AT THE ROYAL INSTITUTION, 1875-76. With 58 Woodcuts. Crown 8vo, 2s. 6d.  
 NOTES OF A COURSE OF SEVEN LECTURES ON ELECTRICAL PHENOMENA AND THEORIES, delivered at the Royal Institution. Crown 8vo, 1s. 6d.  
 NOTES OF A COURSE OF NINE LECTURES ON LIGHT, delivered at the Royal Institution. Crown 8vo, 1s. 6d.  
 FARADAY AS A DISCOVERER. Crown 8vo, 3s. 6d.  
 THE GLACIERS OF THE ALPS : being a Narrative of Excursions and Ascents. An Account of the Origin and Phenomena of Glaciers, and an Exposition of the Physical Principles to which they are related. With numerous Illustrations. Crown 8vo, 6s. 6d. net.

**WATTS' DICTIONARY OF CHEMISTRY.** Revised and entirely Re-written by H. FORSTER MORLEY, M.A., D.Sc., Fellow of, and lately Assistant-Professor of Chemistry in, University College, London ; and M. M. PATTISON MUIR, M.A., F.R.S.E., Fellow, and Prælector in Chemistry, of Gonville and Caius College, Cambridge. Assisted by Eminent Contributors. To be Published in 4 Vols. 8vo. Vols. I. & II. 42s. each. Vol. III. 50s. Vol. IV. 63s.

**WEBB. CELESTIAL OBJECTS FOR COMMON TELESCOPES.**  
 By the Rev. T. W. WEBB, M.A., F.R.A.S., Vicar of Hardwick, Herefordshire. Fifth Edition, Revised and greatly Enlarged by the Rev. T. E. ESPIN, M.A., F.R.A.S. (Two Volumes.)  
 VOL. I. With Portrait and a Reminiscence of the Author, 2 Plates, and numerous Illustrations. Crown 8vo, 6s.  
 VOL. II. With Illustrations and Map of Star Spectra. Crown 8vo, 6s. 6d.

**WRIGHT. OPTICAL PROJECTION : A Treatise on the Use of the Lantern in Exhibition and Scientific Demonstration.** By LEWIS WRIGHT, Author of "Light : a Course of Experimental Optics." With 232 Illustrations. Crown 8vo, 6s.







